LANE MEDICAL LIBRARY STANFORD
E531 .D285 3 OLD
Surgical anatomy of the human body.
24503096665

LANE

MEDICAL LIBRARY

AMERICAN BANK NOTE CO. LITHO.

Digitized by the Internet Archive
in 2025

https://archive.org/details/surgicalanatomyo0003john

SURGICAL ANATOMY OF THE HUMAN BODY

DEAVER

GENERAL ARRANGEMENT OF CONTENTS

VOLUME I.—Scalp—Cranium—Brain—Face—Mouth—Throat—Organs of Special Senses.

VOLUME II.—Upper Extremities—Neck—Shoulders—Back—Lower Extremities.

VOLUME III.—Joints of the Lower Extremities—Chest—Thorax—Abdomen—Pelvis—Perineum.

SURGICAL ANATOMY OF THE HUMAN BODY

BY

JOHN B. DEAVER, M.D., SC.D., LL.D., F.A.C.S.

SURGEON-IN-CHIEF TO THE LANKENAU HOSPITAL, PHILADELPHIA, EMERITUS
JOHN RHEA BARTON PROFESSOR OF SURGERY, UNIVERSITY OF PENNSYLVANIA

SECOND EDITION. IN THREE VOLUMES
THOROUGHLY REVISED AND REARRANGED

PROFUSELY ILLUSTRATED WITH DRAWINGS FROM ORIGINAL DISSECTIONS MADE ESPECIALLY FOR THIS WORK

VOLUME III

JOINTS OF THE LOWER EXTREMITIES, CHEST, THORAX, ABDOMEN, PELVIS, PERINEUM

PHILADELPHIA
P. BLAKISTON'S SON & CO.
1012 WALNUT STREET

MP

LANE LIBRARY

Copyright, 1927, by P. Blakiston's Son & Co.

PRINTED IN U. S. A.
BY THE MAPLE PRESS COMPANY, YORK, PA.

LANE LIBRARY

V.3
1927

CONTENTS OF VOLUME III

	Page
LOWER EXTREMITY	1
Joints of the Lower Extremity	1
The Hip-joint	1
The Knee-joint	6
The Tibio-fibular Joints	16
The Ankle-joint, or Talo-crural Articulation	18
The Intertarsal Articulations	23
The Tarso-metatarsal Articulations	29
The Intermetatarsal Articulations	30
The Metatarso-phalangeal Articulations	31
The Interphalangeal Articulations	31
The Foot as a Whole	32
Dislocations	37
Excisions of the Lower Extremity	45
Development of the Bones of the Lower Extremity	52
Fractures	54
Amputations	62
Ligations of the Arteries	81
THE THORAX	94
The Thoracic Wall	112
The Thoracic Cavity	138
The Pleura	145
The Superior Mediastinum	151
The Middle Mediastinum	179
The Fetal Circulation	201
The Lungs	211
The Posterior Mediastinum	216
THE ABDOMEN	233
Surface Anatomy of the Abdomen	234
The Abdominal Parietes	256
Dissection of the Abdominal Cavity	327
The Liver	378
The Stomach	387
The Spleen	392
The Small Intestine	399
The Large Intestine	401
The Vermiform Appendix	402
The Kidneys	410
The Pancreas	458
The Diaphragm	532
The Pelvic Cavity	543
The Rectum	580
The Bladder	587
The Prostate	593
The Uterus	608
The Vagina	621
The Fallopian (*Uterine*) Tubes	630
The Lymphatics of the Abdomen and Pelvis	638
MALE PERINEUM	645
THE EXTERNAL GENITALS OF THE MALE	683
THE SCROTUM AND TESTICLE	696
FEMALE PERINEUM	713
INDEX	735

66351

LIST OF ILLUSTRATIONS

Plate		Page
CCCXXI.	Anterior View and Longitudinal Section of the Hip-joint	3
CCCXXII.	Anterior View and Longitudinal Section of the Knee-joint	7
CCCXXIII.	Posterior View of the Knee-joint	10
CCCXXIV.	Ligaments of Tarsus—Lateral and Medial Views	22
CCCXXV.	(*a*) Ligaments of the Foot, Plantar Surface	27
	(*b*) Section Showing the Synovial Cavities of the Foot	27
CCCXXVI.	Lines of Excisions	44
CCCXXVII.	Lines of Excisions	47
CCCXXVIII.	Lines of Excisions	50
CCCXXIX.	Fractures of the Shaft of the Femur	56
CCCXXX.	(*a*) Fracture of Both Bones of the Leg	60
	(*b*) Fracture of Both Malleoli	60
CCCXXXI.	Amputation of Leg, Proximal Third	70
CCCXXXII.	Amputation at the Proximal Third of the Thigh	73
CCCXXXIII.	Amputation at the Distal Third of the Thigh	75
CCCXXXIV.	Lines of Incisions for Exposure Arteries and Nerves	80
CCCXXXV.	Ligation of Femoral Artery in Scarpa's (*Femoral*) Triangle and in Hunter's (*Adductor*) Canal	83
CCCXXXVI.	Ligation of the Posterior Tibial Artery in the Proximal, Middle, and Distal Thirds of the Leg	88
CCCXXXVII.	Ligation of the Anterior Tibial Artery in the Proximal, Middle, and Distal Thirds of the Leg	91
CCCXXXVIII.	Ligation of Internal Mammary Artery	100
CCCXXXIX.	Position of the Heart and Lungs	104
CCCXL.	Diagram of Position of Heart and Location of Cardiac Valves	107
CCCXLI.	Points for Aspiration of Pleura and Pericardium	110
CCCXLII.	The Intercostal Muscles	117
CCCXLIII.	The Internal Mammary Artery	121
CCCXLIV.	Intercostal, Epigastric, and Deep Circumflex Iliac Arteries	126
CCCXLV.	Diagram of Upper Intercostal Nerve	132
CCCXLVI.	Diagram of Lower Intercostal Nerve	134
CCCXLVII.	Anterior Mediastinum	139
CCCXLVIII.	Cross-section of the Thorax Through the Superior Mediastinum (*a*) From Below. (*b*) From Above	143
CCCXLIX.	Structures in the Superior Mediastinum, and the Pericardium and Roots of the Lungs	150
CCCL.	Structures in the Superior Mediastinum, and the Heart and Lungs	157
CCCLI.	Posterior Mediastinum, View of Trachea, Bronchi, Lungs, and Heart from Behind	170
CCCLII.	Cross Sections of the Thorax (*a*) Through the Roots of the Lungs. (*b*) Below the Roots of the Lungs	173
CCCLIII.	Pericardium and Roots of the Lungs	178
CCCLIV.	Anterior View of the Heart and Its Vessels	183
CCCLV.	Posterior View of the Heart and Its Vessels	185
CCCLVI.	Right Auricle (*Atrium*) and Ventricle	190
CCCLVII.	Left Auricle (*Atrium*) and Ventricle	196
CCCLVIII.	Aortic Semilunar Valves	199
CCCLIX.	Anterior View of Trachea and Lungs	204
CCCLX.	Posterior View of Trachea and Lungs	206

Plate		Page
CCCLXI.	Mediastinal Surface of Right Lung	208
CCCLXII.	Mediastinal Surface of Left Lung	210
CCCLXIII.	The Posterior Mediastinum, Viewed from the Front	217
CCCLXIV.	The Posterior Mediastinum, Viewed from the Right Side	219
CCCLXV.	The Posterior Mediastinum, Viewed from the Left Side	221
CCCLXVI.	The Venae Azygos, Thoracic Duct, Intercostal Vessels and Nerves	226
CCCLXVII.	Surface Anatomy of Anterior Abdominal Wall	235
CCCLXVIII.	Lines of Arteries	241
CCCLXIX.	Diagram of Abdominal Viscera and Lungs,—Anterior View	243
CCCLXX.	Diagram of Abdominal Viscera and Lungs,—Posterior View	245
CCCLXXI.	Diagram of Abdominal Viscera and Lungs,—Right Side	247
CCCLXXII.	Diagram of Abdominal Viscera and Lungs,—Left Side	249
CCCLXXIII.	Incisions for Dissection	257
CCCLXXIV.	Superficial Fascia of the Abdomen and Superficial Vessels	260
CCCLXXV.	Deep Fascia, Cutaneous Nerves, External Oblique Muscle and Its Aponeurosis.	266
CCCLXXVI.	External Oblique and Latissimus Dorsi Muscles, and Triangle of Petit (*Lumbar Triangle*)	268
CCCLXXVII.	External Abdominal (*Subcutaneous Inguinal*) Ring, Intercolumnar (*External Spermatic*) Fascia, Spermatic Cord, and Ilio-inguinal Nerve	271
CCCLXXVIII.	Poupart's (*Inguinal*) and Gimbernat's Ligaments (*Ligamentum Lacunare*)	275
CCCLXXIX.	Internal Oblique Muscle	278
CCCLXXX.	Transverse Sections of Abdominal Wall and Sheath of Rectus Abdominis Muscle	281
CCCLXXXI.	Diagram of a Lower Intercostal Nerve	285
CCCLXXXII.	Lower Intercostal Nerves, Transversalis (*Transversus Abdominis*) and Rectus Abdominis Muscles	287
CCCLXXXIII.	Transversalis (*Transversus Abdominis*) Muscle and Sheath of Rectus Abdominis Muscle	290
CCCLXXXIV.	Epigastric and Deep Circumflex Iliac Arteries	293
CCCLXXXV.	Inguinal Canal, Cremaster Muscle, Spermatic Cord, and Ilio-inguinal Nerve	295
CCCLXXXVI.	Inguinal Canal, Conjoined Tendon (*Falx Inguinalis*), and Triangular (*Reflected Inguinal*) Ligament	297
CCCLXXXVII.	Inguinal Canal, Conjoined Tendon (*Falx Inguinalis*), Infundibuliform (*Internal Spermatic*) Fascia	299
CCCLXXXVIII.	Inguinal Canal, Poupart's (*Inguinal*) Ligament, Spermatic Cord, and Cremaster Muscle	303
CCCLXXXIX.	Diagrams of the Varieties of Congenital Hernia	310
CCCXC.	An Acquired Oblique Inguinal Hernia	314
CCCXCI.	Inguinal Fossae	329
CCCXCII.	Diagram of Abdominal Viscera and Lungs. Regions of the Abdomen	334
CCCXCIII.	Peritoneum Traced Vertically in the Fetus and the Adult	340
CCCXCIV.	Peritoneum Traced Below the Level of the Transverse Colon	343
CCCXCV.	Peritoneum Traced Above the Level of the Transverse Colon	346
CCCXCVI.	Peritoneum Traced at the Level of the Foramen of Winslow (*Epiploic Foramen*)	348
CCCXCVII.	Abdominal Viscera and Greater Omentum	355
CCCXCVIII.	Right Side of Mesentery, Cecum, and Ascending Colon	359
CCCXCIX.	Left Side of Mesentery, and Descending Colon	361
CCCC.	Attachments of Mesentery and Mesocolon	366
CCCCI.	Duodeno-jejunal Fossa	372
CCCCII.	Ileo-colic Fossa (*Superior Ileo-cecal Recess*)	374
CCCCIII.	Ileo-cecal Fossa (*Inferior Ileo-cecal Recess*)	376
CCCCIV.	Subcecal (*Retrocecal*) Fossa	379
CCCCV.	Superior Surface of Liver	381
CCCCVI.	Inferior Surface of Liver	383
CCCCVII.	The Lateral Surface of the Spleen	393
CCCCVIII.	The Medial Surface of the Spleen	395
CCCCIX.	Diagram of Positions of the Vermiform Appendix	403

Plate		Page
CCCCX.	Structures in Greater Omentum and Lesser Omentum	412
CCCCXI.	Vasa Brevia. Structures in the Gastro-splenic Omentum (*Gastro-splenic Ligament*)	420
CCCCXII.	Structures Behind the Posterior Parietal Layer of Peritoneum. The Lesser Omentum	422
CCCCXIII.	Superior Mesenteric Vessels	424
CCCCXIV.	Inferior Mesenteric Vessels	429
CCCCXV.	Internal Surface of Small Intestine Showing Valvulae Conniventes	433
CCCCXVI.	Internal Surface of Ileum Showing Peyer's Patches (*Aggregated Lymphatic Nodules*)	436
CCCCXVII.	Ileo-cecal Valve—External View	443
CCCCXVIII.	Ileo-cecal Valve—Internal View	445
CCCCXIX.	Section Through Ileo-cecal Valve	447
CCCCXX.	Duodenum and Pancreas	454
CCCCXXI.	Pancreatic and Common Bile-ducts	459
CCCCXXII.	Pancreas and Duodenum, with Pancreatic and Common Bile Ducts	461
CCCCXXIII.	Portal Vein, Superior and Inferior Mesenteric Veins and Splenic Vessels	466
CCCCXXIV.	Superior Surface of Liver	469
CCCCXXV.	Inferior Surface of Liver	471
CCCCXXVI.	The Stomach and Its Arteries	482
CCCCXXVII.	Incision and Sutured Wound in Pyloroplasty	487
CCCCXXVIII.	Abdominal Aorta, Inferior Vena Cava, Kidneys, and Ureters in Situ	491
CCCCXXIX.	Diagram of Kidney, Renal Vessels, and Ureter	494
CCCCXXX.	Types of Sinuses of Kidney	497
CCCCXXXI.	Sections of Kidney	499
CCCCXXXII.	Kidney, Renal Vessels, and Ureters	502
CCCCXXXIII.	Stomach, Liver, Pancreas, Celiac Axis (*Celiac Artery*), Hepatic, Pyloric (*Right Gastric*), and Gastric, or Coronary (*Left Gastric*) Arteries, and Portal Vein	514
CCCCXXXIV.	Abdominal Sympathetic Nerves	518
CCCCXXXV.	Cervical and Thoracic Sympathetic Trunks	520
CCCCXXXVI.	The Lumbar Plexus	525
CCCCXXXVII.	Diagram of the Lumbar and Sacral Plexuses	527
CCCCXXXVIII.	The Diaphragm	533
CCCCXXXIX.	Quadratus Lumborum, Psoas, and Iliacus Muscles	540
CCCCXL.	Pelvic Cavity of Male—Superior View	547
CCCCXLI.	Male Pelvis and Perineum—Sagittal Section	549
CCCCXLII.	Pelvic Cavity of Female—Superior View	552
CCCCXLIII.	Female Pelvis and Perineum—Sagittal Section	554
CCCCXLIV.	Diagram of Pelvic Fascia	558
CCCCXLV.	Ligation of External Iliac Artery (*a*) Extraperitoneal Method. (*b*) Transperitoneal Method	564
CCCCXLVI.	Internal Iliac (*Hypogastric*) Artery and Its Branches	568
CCCCXLVII.	Uterus, Broad Ligament, Uterine Artery, and Ureter	571
CCCCXLVIII.	Male Pelvis and Perineum—Sagittal Section	581
CCCCXLIX.	Bladder, Prostate, Seminal Vesicles, Vasa Deferentia (*Ductus Deferentes*)	586
CCCCL.	Sympathetic Plexus	598
CCCCLI.	Diagram of the Lumbar and Sacral Plexuses	603
CCCCLII.	The Sacral Plexus	605
CCCCLIII.	Sections of Uterus and Vagina	609
CCCCLIV.	Uterus, Broad Ligament, Uterine Artery, and Ureter	615
CCCCLV.	External Genitals of Virgin	624
CCCCLVI.	Pelvic Cavity of Female—Superior View	627
CCCCLVII.	Ligation of External Iliac Artery (*a*) Extraperitoneal Method. (*b*) Transperitoneal Method	633
CCCCLVIII.	Muscles in Floor of Pelvis—Superior View	636
CCCCLIX.	Surface of Male Perineum	644
CCCCLX.	Superficial Fascia of Male Perineum	650

Plate		Page
CCCCLXI.	Ischio-rectal Fossae and Fascia of Colles (*Membranous Layer, Superficial Fascia*) of Male Perineum	654
CCCCLXII.	Superficial Muscles, Arteries, and Nerves of Male Perineum	658
CCCCLXIII.	Superficial Layer of Triangular Ligament of Male Perineum (*Inferior Fascia of Urogenital Diaphragm of Male Perineum*)	663
CCCCLXIV.	Triangular Ligament (*Urogenital Diaphragm*) and Compressor Urethrae (*Sphincter Urethrae*) Muscle	665
CCCCLXV.	Deep Vessels and Nerves of Male Perineum	671
CCCCLXVI.	Levator Ani Muscle of Male Perineum	675
CCCCLXVII.	Pelvic Organs Seen in Dissection of Male Perineum	678
CCCCLXVIII.	Bodies of Penis Distended	682
CCCCLXIX.	Sections of Penis	685
CCCCLXX.	Sagittal Section of Anterior Portion of Penis	688
CCCCLXXI.	Male Urethra Cleft Dorsally	690
CCCCLXXII.	Right Testicle and Spermatic Cord—Anterior View	700
CCCCLXXIII.	Transverse Section of Testicle and Scrotum	702
CCCCLXXIV.	Testicle and Epididymis	706
CCCCLXXV.	Surface of Female Perineum	712
CCCCLXXVI.	Superficial Perineal Interspace of Female Perineum	718
CCCCLXXVII.	Triangular Ligament (*Urogenital Diaphragm*) and Superficial Perineal Interspace of Female	720
CCCCLXXVIII.	Deep Perineal Interspace of Female Perineum	725
CCCCLXXIX.	Inferior Surface of Levator Ani Muscle of Female	728
CCCCLXXX.	Muscles in Floor of Pelvis—Superior View	730

SURGICAL ANATOMY

JOINTS OF THE LOWER EXTREMITY

THE HIP-JOINT (Plate CCCXXI)

The **Hip-joint** is formed by the reception of the head of the femur into the acetabulum of the innominate bone. The articulating surfaces of both bones are covered with cartilage; the cartilage of the femur covers the entire head of the bone, with the exception of a small place at the center, where the ligamentum teres is attached, while that of the acetabulum is absent at the cotyloid (*acetabular*) notch, thus giving the cartilage a horseshoe shape. The covering of the head of the femur is thicker at the center, where it bears the greatest amount of strain, than at the circumference; that of the acetabulum is thicker above than below.

The ligaments of the hip-joint are the capsular (*articular capsule*), the cotyloid (*labrum glenoidale*), the transverse, and the ligamentum teres.

The **capsular ligament** (**articular capsule**) is a dense and strong capsule which is attached to the margin of the acetabulum, or glenoid cavity, above, and to the neck of the femur below. It is attached at the upper and posterior part of the acetabulum to the bone close to the cotyloid ligament (*labrum glenoidale*); in front, it is connected with the cotyloid ligament (*labrum glenoidale*); below, at the notch, it is attached to the transverse ligament and, by a few fibers, to the margin of the obturator foramen. Its attachment to the neck of the femur varies in different parts: posteriorly, it is attached to the posterior part of the neck at its middle; superiorly, to the base, and anteriorly, to the intertrochanteric ridge (spiral ridge). Over the anterior and lateral parts of the joint, where the greatest amount of resistance is required, the capsule is much thicker and stronger than inferiorly and posteriorly, where it is thin, loose, and longer. It is composed of circular and longitudinal fibers. The circular fibers are most abundant at the posterior and inferior parts of the capsule, and near the middle of the inferior wall form a thick band, known as the zona orbicularis (of Henle). The longitudinal fibers are most abundant at the anterior and superior part, where they form accessory ligaments which tend to strengthen the capsule where the most strain is exerted. These accessory ligaments are the ilio-femoral, the pubo-

femoral (*pubo-capsular*), and the ischio-capsular. The *ilio-femoral*, or Y ligament of Bigelow, is placed anterior to the joint and constitutes the thickest and most powerful part of the capsule. It is attached superiorly to the anterior inferior spine of the ilium, and passes downward in front of the joint. In its downward course, it splits into two divisions which gradually diverge, thus giving the ligament an inverted Y appearance. The lateral limb of the Y is attached to the anterior intertrochanteric line, close to the greater trochanter, and the medial limb to the lower end of the same line. The *pubo-femoral band* (*pubo-capsular ligament*) consists of several fasciculi which pass from the ilio-pectineal eminence to the front of the capsule. The fibers of this ligament often blend with those of the ilio-femoral ligament. The *ischio-capsular* ligament, a broad band of short, strong, longitudinal fibers, arises from the ischium below the acetabulum and along the lower margin of the groove for the obturator externus muscle. It passes to the inferior anterior part of the capsule, where it blends with the band of circular fibers.

The **cotyloid ligament** (**labrum glenoidale**) is a fibrocartilaginous ring attached to the margin of the acetabulum within the capsule. It tends to deepen the cotyloid (*acetabular*) cavity and to protect its edges and the head of the femur from injury due to sudden or extreme pressure. At the inferior part of the acetabulum it blends with the transverse ligament. On transverse section the ligament is prismoidal in shape, being much thicker at its attachment to the margin of the cotyloid (*acetabular*) cavity than at its free margin. Its two surfaces are lined with a synovial membrane, that of the lateral surface being in contact with the capsule, while the medial is inclined medialward, thus lessening the cotyloid (*acetabular*) cavity and becoming attached to the fibrocartilage covering the head of the femur. The cotyloid ligament (*labrum glenoidale*) is composed of dense, strong fibers which arise from the rim of the acetabulum and then interlace at acute angles. It is stronger superoposteriorly than inferiorly and anteriorly.

The **transverse ligament** is practically a portion of the cotyloid ligament (*labrum glenoidale*), as it is so closely blended with the latter that their fibers cannot be separated. It consists of broad, flat bands which stretch across the cotyloid (*acetabular*) notch, thus converting it into a foramen for the passage of the vessels to the joint.

The **ligamentum teres femoris,** or round ligament, is a band about three and three-quarter centimeters (one and a half inches) long which extends from the cotyloid (*acetabular*) notch to the head of the femur, thus being entirely interarticular. The pelvic end of the ligament is attached to the rough surfaces on either side of the cotyloid (*acetabular*) notch, and to the transverse ligament; the femoral

PLATE CCCXXI.

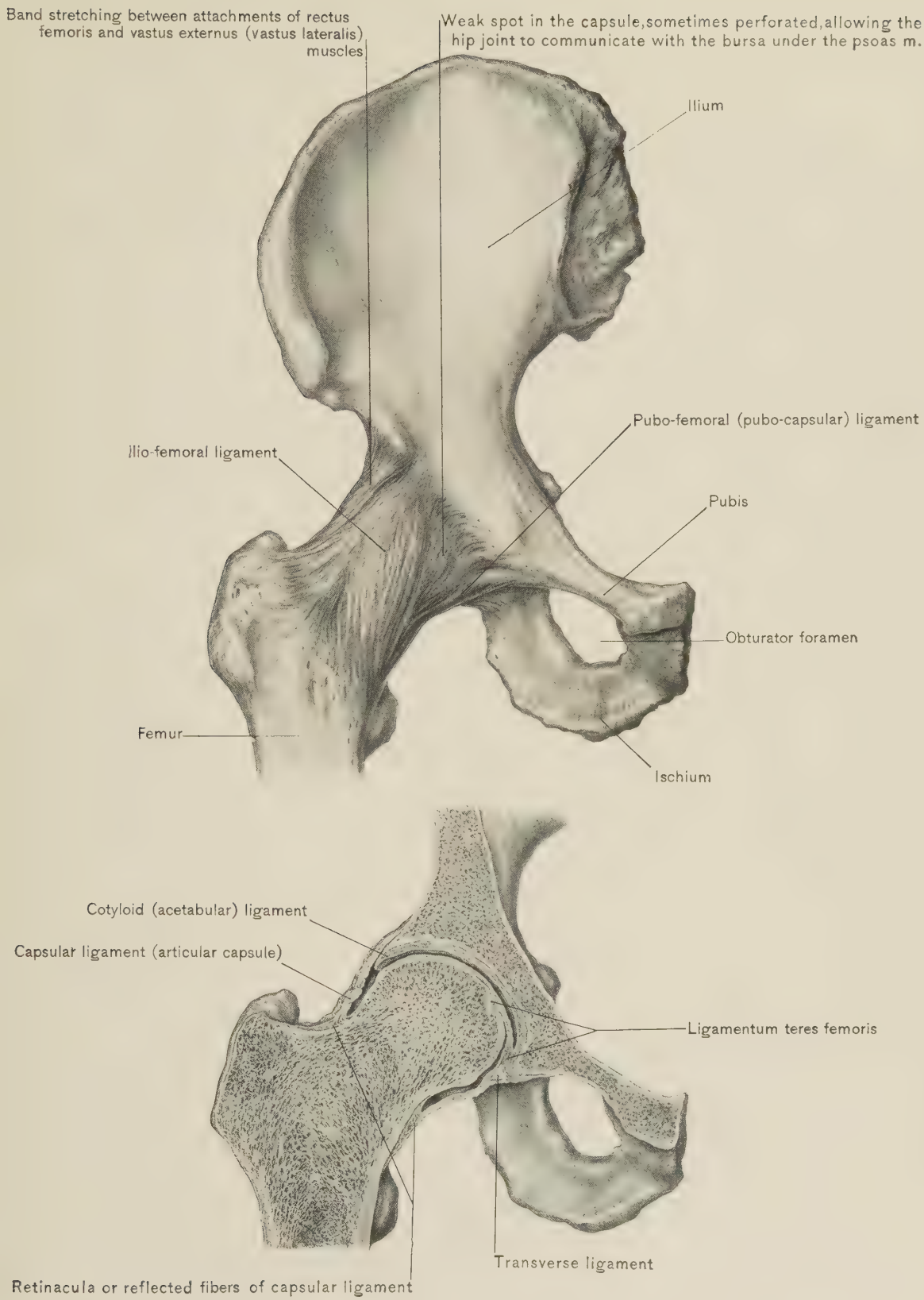
Band stretching between attachments of rectus femoris and vastus externus (vastus lateralis) muscles
Weak spot in the capsule, sometimes perforated, allowing the hip joint to communicate with the bursa under the psoas m.
Ilium
Pubo-femoral (pubo-capsular) ligament
Ilio-femoral ligament
Pubis
Obturator foramen
Femur
Ischium
Cotyloid (acetabular) ligament
Capsular ligament (articular capsule)
Ligamentum teres femoris
Transverse ligament
Retinacula or reflected fibers of capsular ligament

ANTERIOR VIEW AND LONGITUDINAL SECTION OF THE HIP-JOINT.

end is attached to the rough depression just below the center of the head of the bone and to the fibrocartilage investment of this portion of the femur. The ligament is entirely enveloped by synovial membrane, and conveys an artery to the head of the femur. It is occasionally absent, and plays an unimportant rôle in the mechanism of the hip-joint. However, the blood supply of the head of the bone is partly derived from the artery of the ligament.

The *synovial membrane of the hip-joint* lines the capsule and covers the cotyloid ligament (*labrum glenoidale*) and the ligamentum teres, being reflected from these upon the intracapsular bone surfaces as far as the edges of the articular cartilage. At the bottom of the acetabulum it passes over some vessels and fat upon the ligamentum teres at the head of the bone, and in doing so covers the fat in the rough hollow at the bottom of the cotyloid (*acetabular*) cavity.

Relations.—The relations of the hip-joint are: anteriorly, the iliacus and psoas magnus muscles, with an intervening bursa; superiorly, the short head of the rectus femoris and the closely adherent gluteus minimus; medially, the pectineus and obturator externus; posteriorly the short lateral rotators, the pyriformis, the obturator internus and the two gemelli, the obturator externus, and the quadratus femoris.

Blood Supply.—It is supplied by the obturator and internal (*medial*) circumflex inferiorly, the gluteal (*superior gluteal*) superiorly, and the sciatic (*inferior gluteal*) arteries posteriorly.

Nerve Supply.—It receives articular branches from the sacral plexus, great sciatic (*sciatic*), obturator, and accessory obturator nerves.

Movements.—The hip-joint is a ball-and-socket joint (enarthrodial diarthrosis) and is capable of very free motion, but not so much as the shoulder-joint; like the latter, it abducts, adducts, anteducts (flexes), retroducts (extends), circumducts, and rotates. The thickened anterior capsule and the ilio-femoral ligament limit extension, and are aided in this by the ilio-psoas and pectineus muscles. Flexion is free, its only limit being contact between the neck of the femur and the margin of the acetabulum. Abduction is limited by the pubo-femoral (*pubo-capsular*) ligaments and the lower part of the capsule, and adduction is checked by the ischio-capsular fibers and the top of the capsule. Combined flexion and adduction stretch the ligamentum teres, which thus resists dislocation upon the dorsum of the iliac bones. The shortness and strength of the anterior capsule, by preventing over-extension, assist materially in maintaining the erect attitude while walking and standing.

The **femoral artery** passes directly over the head of the bone, but is separated from it by the ilio-psoas muscle, where it is readily compressed, the vein being close upon its medial side, and the anterior crural (*femoral*) nerve separated by

about one and a quarter centimeters (half an inch) from its lateral side. The great sciatic (*sciatic*) nerve and vessels are separated from the joint by the short external rotators.

In **synovitis of the hip** with considerable effusion, the capsule may become sufficiently distended to push forward in Scarpa's (*femoral*) triangle, causing bulging of the structures composing the floor, and carrying the femoral artery close against the skin, where it is readily seen pulsating. Posteriorly, it may obliterate the gluteal fold. The tension in the joint, increased by the action of the muscles that cross it, limits movements of the hip. Flexion, adduction, and medial rotation is the favorite attitude of the thigh in hip-joint hydrarthrosis, probably due to the maximum laxity of the capsule produced by this position. The earliest pain in hip-joint disease is felt upon the medial side of the thigh or knee, or in the popliteal space, along the terminal distribution of the obturator nerve, and is pain referred from irritation of the hip-joint articular fibers of this nerve to the distal area of distribution. It is analogous to the pain felt in the glans penis from vesical irritation due to stone in the bladder, or to earache due to dental nerve irritation from decayed teeth.

Pyarthrosis of the hip-joint opens posteriorly, if at all, through the thinnest part of the capsule. Hence it may burrow in various directions between the muscles and fascial septa. It may perforate the acetabulum to gain access to the pelvis, eventually to form an ischio-rectal abscess which may open either upon the perineum or into the rectum. It may also perforate the anterior portion of the capsular ligament in the fork of the femoral (Y) ligament, and enter the bursa between the joint and the ilio-psoas muscle, thence extending upward to form a pelvic abscess.

THE KNEE-JOINT (Plate CCCXXII)

The **Knee-joint,** the largest joint in the body, is formed by the articulation of the tibia, femur, and patella. It is a ginglymus, or hinge, joint, although there is a slight rotary motion around a vertical axis. In some respects it is the weakest joint in the body, as the bony surfaces forming it are never in complete contact. The true strength of the articulation depends upon the number, size, and arrangement of its ligaments, together with the strong muscles and expansions of fascia which pass over the joint. An analysis of the articulating surfaces shows that the joint consists of three separate articulations, each condyle of the femur articulating separately with the corresponding tuberosity (*condyle*) of the tibia and the patella with the femur. These articulations have a common synovial membrane.

The ligaments of the knee-joint are divided into an external, or superficial, and an internal, or deep, set. The former includes the fibrous expansion of the

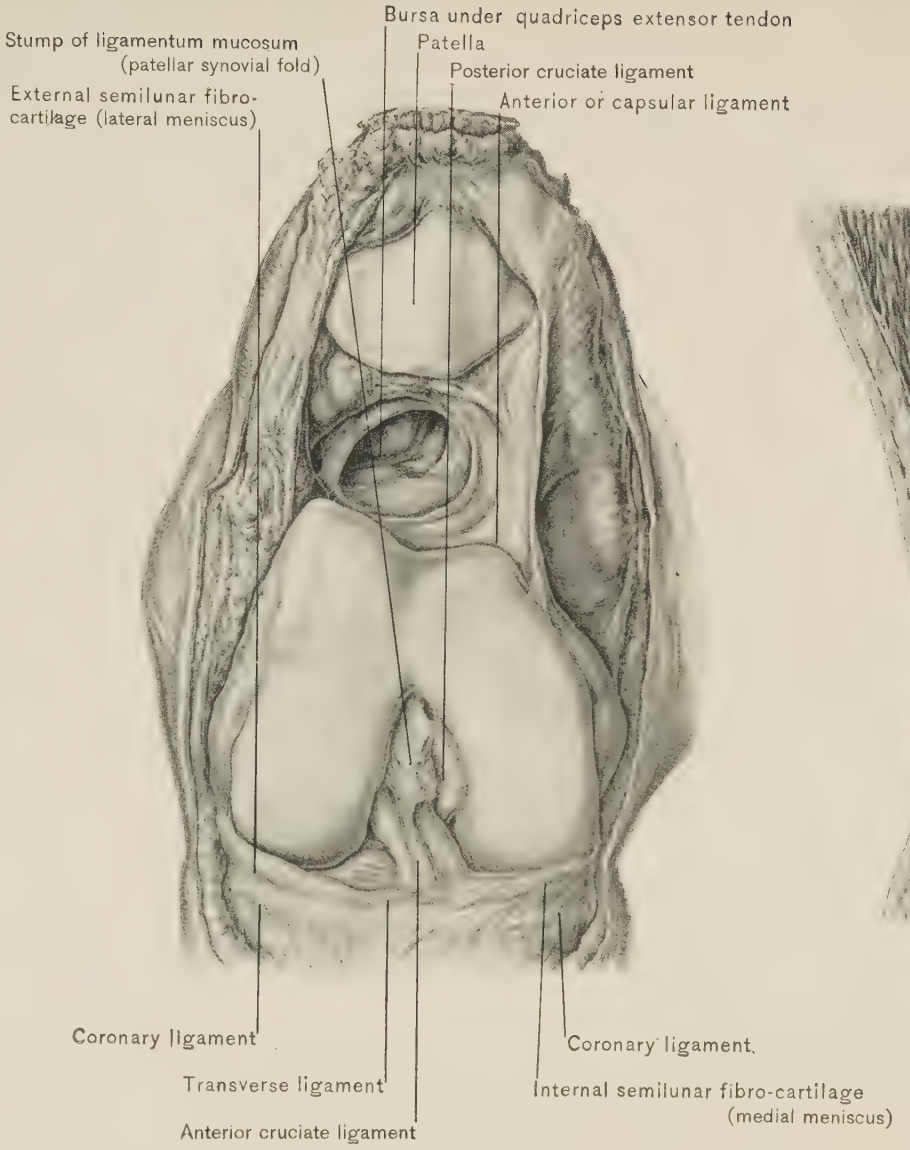

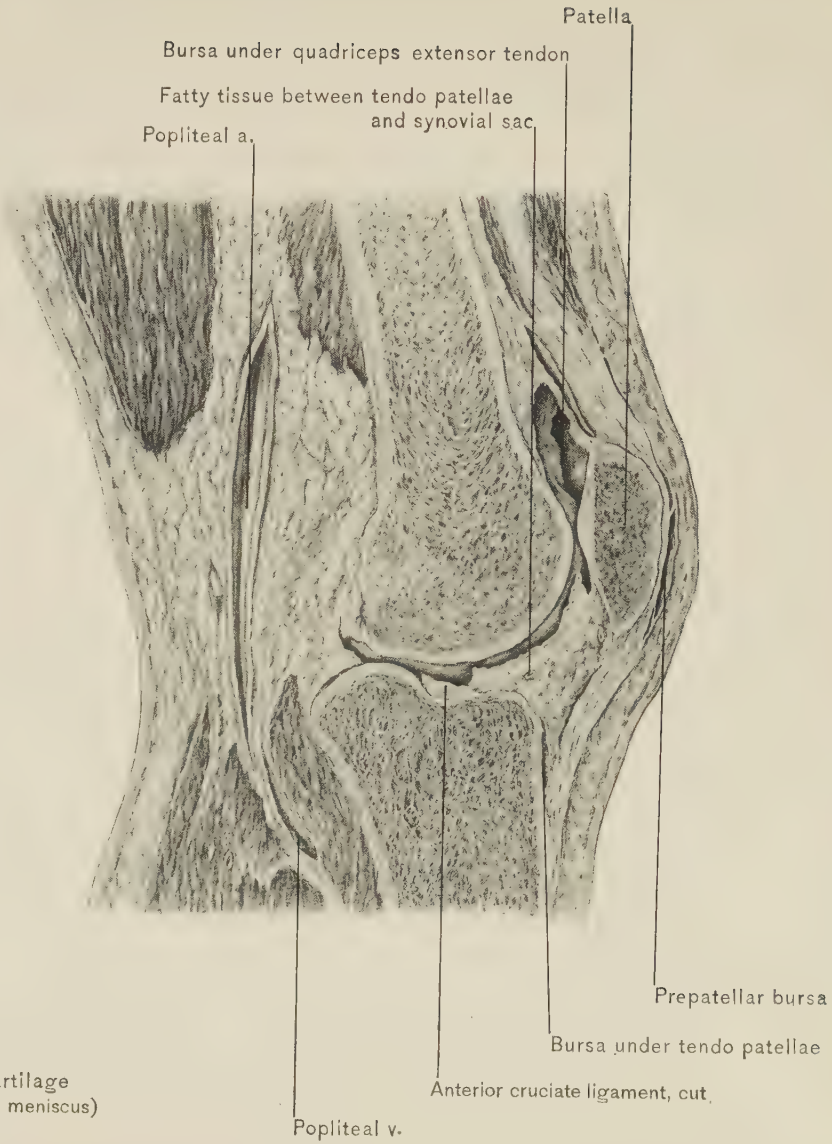

ANTERIOR VIEW AND LONGITUDINAL SECTION OF THE KNEE-JOINT.

PLATE CCCXXIII.

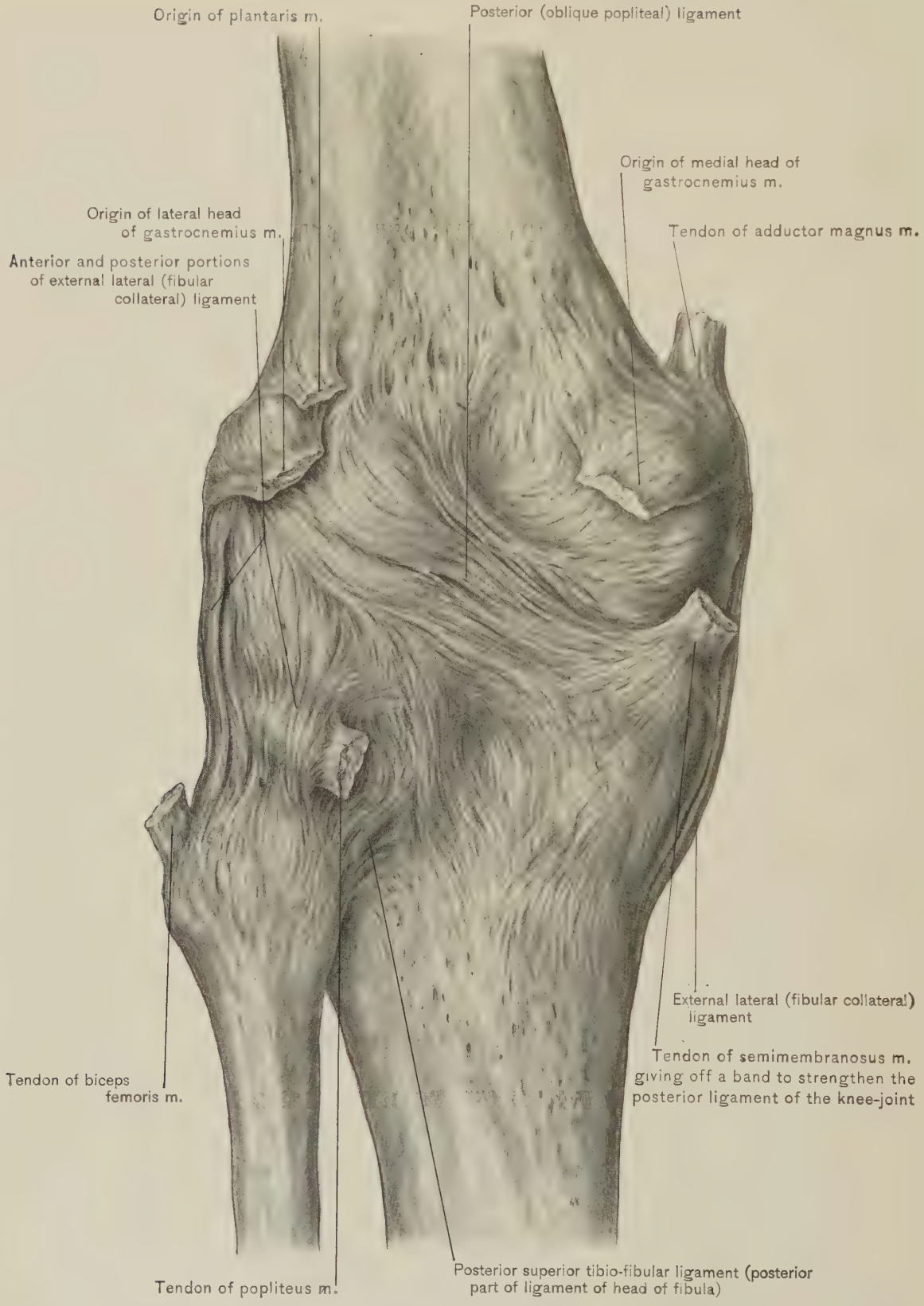
Origin of plantaris m.
Posterior (oblique popliteal) ligament
Origin of medial head of gastrocnemius m.
Origin of lateral head of gastrocnemius m.
Tendon of adductor magnus m.
Anterior and posterior portions of external lateral (fibular collateral) ligament
External lateral (fibular collateral) ligament
Tendon of semimembranosus m. giving off a band to strengthen the posterior ligament of the knee-joint
Tendon of biceps femoris m.
Tendon of popliteus m.
Posterior superior tibio-fibular ligament (posterior part of ligament of head of fibula)

POSTERIOR VIEW OF THE KNEE-JOINT.

quadriceps extensor (*quadriceps femoris*) tendon, the ligamentum patellæ, the posterior (*oblique popliteal*) ligament, the external lateral (*fibular collateral*), internal lateral (*tibial collateral*) and the capsular ligaments. The internal set includes the anterior cruciate, the posterior cruciate, the internal and external semilunar fibrocartilages (*medial and lateral menisci*), the coronary, the transverse ligaments, and folds of the synovial membrane known as the ligamentum mucosa (*patellar synovial folds*) and ligamenta alaria (*alar folds*).

The **fibrous expansion of the extensor tendons** consists of three portions: an anterior and two lateral. The *anterior portion* is inserted into the proximal portion of the patella, some of its superficial fibers passing over the bone to become part of the ligamentum patellæ. The *lateral portions* are attached to the sides of the patella, and to the anterior aspect on either side of the central portion; some of the fibers extend to the oblique lines running from the tubercle (*tuberosity*) of the tibia to its tuberosities (*condyles*). Medially the fibers blend with the periosteum of the tibia, and laterally with the ilio-tibial band, thus forming an anterior cap which adds greatly to the strength of the joint, and which is separated from the synovial membrane by a layer of fatty tissue.

The **ligamentum patellæ,** or **tendo patellæ,** consists of that portion of the quadriceps extensor (*quadriceps femoris*) tendon between the distal end of the patella and the tibia. It is a powerful, broad, flat tendon, about seven and a half centimeters (three inches) long, extending from the distal end of the patella to the bottom of the tubercle (*tuberosity*) upon the front of the proximal end of the tibia. A small bursa exists between the distal end of the back of this tendinous ligament and the front of the head of the tibia above the tubercle (*tuberosity*) into which it is inserted, and another exists between the patella and skin. The ligament is separated from the knee-joint between the patella and tibia by a cushion of fat; its sides are connected with the vasti aponeurosis.

The **internal lateral** (**tibial collateral**) **ligament** is a broad band which is situated on the posterior aspect of the medial side of the knee. It is thickest in its posterior part. It arises from the medial tuberosity (*medial epicondyle*) of the femur just distal to the adductor tubercle and extends to the medial tuberosity (*medial condyle*) and posterior border of the tibia, and several centimeters down the shaft. Its joint surface rests against the articular synovial membrane above, at its middle it is intimately united to the semilunar fibro-cartilage (*medial meniscus*), and below it is separated from the bone by the anterior slip of the insertion of the semimembranosus muscle.

The **posterior** (**oblique popliteal**) **ligament** (Plate CCCXXIII), or ligament of Winslow, is a dense fibrous mass connecting the adjoining ends of the femur and tibia posteriorly. It is composed essentially of two parts, a superficial and a

deep. The *superficial portion* is a thick, heavy fibrous band passing obliquely upward and lateralward from the insertion of the semimembranosus along the posterior surface of the medial tuberosity (*medial condyle*) of the tibia to the lateral condyle under and alongside the origin of the lateral head of the gastrocnemius. It is virtually an extension of the semimembranosus tendon reinforced above the lateral head of the gastrocnemius. The *deep portion* consists of vertical fibers that pass upward from the back of the tibia below, to unite with the oblique superficial band, and of vertical and oblique fibers coming down the back of the medial condyle and intercondyloid fossa above, the oblique fibers passing downward and lateralward, and being partly derived from the medial head of the gastrocnemius. This is the strongest, densest, and tightest ligament of the joint; it prevents hyperextension of the knee and guards against posterior swellings from joint effusion, which might cause serious complications by compression of the popliteal vessels and nerves, since it forms part of the floor of the popliteal space and has resting directly upon it the popliteal artery. This ligament is pierced by the azygos articular (*middle genicular*) artery, a branch of the popliteal.

Two external lateral (fibular collateral) ligaments guard this joint upon its lateral side: a posterior short, and an anterior long ligament. The *posterior*, or *short lateral*, *portion* extends from the back of the lateral surface of the lateral condyle, where it is blended with the proximal end of the oblique fasciculus of the posterior (*oblique popliteal*) ligament under the lateral head of the gastrocnemius, to the tip of the styloid process of the fibula. Beneath and adherent to it is the tendon of the popliteus muscle; it is also intimately adherent to the capsule of the joint. The *anterior*, or *long*, *portion* extends from the lateral tuberosity (*lateral epicondyle*) of the femur to the head of the fibula. This ligament is intimately adherent to the capsule; the tendon of the popliteus muscle and the lateral articular vessels pass between it and the joint, while laterally it is crossed by the biceps tendon which is sometimes divided by this ligament previous to its insertion.

The **capsular ligament** (**articular capsule**) is a very thin, but strong and loose fibrous pouch filling the intervals between the preceding ligaments. It is attached to the osseous margins of the joint surfaces of the femur, tibia, and patella, and joins the margins of the lateral (*collateral*) ligaments. Upon each side of the patella, under the vasti muscles, where it crosses from the tibia to the patella, it is sometimes known as the **collateral patellar ligament.**

Dissection.—If care has been taken during the preceding dissection not to enter the joint cavity, a hole should be bored with a gimlet through the patella, into which a blow-pipe should be introduced and the joint fully distended with air. The extent of the synovial sac can thus be effectively demonstrated. The

proximal attachments of the patella should then be divided and the bone turned down, when the study of the internal ligaments may be begun.

As the patella is pulled downward, three folds of the synovial membrane will be observed: one extending from the front of the joint below the patella to the front of the intercondyloid fossa, called the **ligamentum mucosum** (**patellar synovial fold**), and two fringe-like folds extending upward and laterally from its sides to the lateral edges of the patella, called the **ligamenta alaria** (**alar folds**). These and the lateral attachments of the patellar tendon should be severed, the tendon turned down, and the bursa between it and the tibia exposed. Flexion of the joint will now expose, from the front, the two cruciate ligaments, an anterior and a posterior.

The **anterior cruciate ligament,** the smaller, extends from a depression in front of the tibial spine (*intercondyloid eminence*) where it is blended with the anterior extremity of the external semilunar fibrocartilage (*lateral meniscus*), to the back part of the medial side of the lateral condyle, its direction being upward, backward, and lateralward.

The **posterior cruciate ligament,** the larger and less oblique of the two, is attached to a depression behind the tibial spine (*intercondyloid eminence*), where it blends with the posterior extremity of the external semilunar fibrocartilage (*lateral meniscus*), whence it passes upward, forward, and medialward to the front of the lateral side of the medial condyle. A small fibrous fasciculus connects the two ligaments where they cross. The relative positions of these ligaments are readily remembered since they occupy the same relative position as a pair of crossed legs, which arrangement always represents the position of the ligaments of the anterior knee.

The **semilunar cartilages** (**menisci**) are two crescentic fibrocartilages that lie upon the tops of the two tibial tuberosities (*condyles*) deepening the joint surface; the lateral margin is thick, the medial concave edge thin and sharp; the superior surface is concave for the femoral condyle, and the inferior flat to rest upon the top of the tibia. The *internal semilunar fibrocartilage* (*medial meniscus*) is almost semilunar; it is attached in front to the medial side of the articular surface of the lateral tibial tuberosity (*lateral condyle*), and behind to the medial side of the depression behind the tibial spine (*intercondyloid eminence*), where it blends with the posterior cruciate ligament. Its edge is united to the internal lateral (*tibial collateral*) ligament and head of the tibia by the coronary ligaments. The *external semilunar fibrocartilage* (*lateral meniscus*) is almost circular and is attached by its anterior and posterior extremities to the front and back of the base of the tibial spine (*intercondyloid eminence*), respectively. Its circumference is held to the tibial head by the coronary ligaments, and its lateral

border is grooved for the lodgment of the popliteus tendon, which separates it from the capsule. From its anterior edge it gives off the transverse ligament, and its anterior extremity blends with the anterior cruciate ligament. Its posterior extremity has three divisions: one blending with the back of the anterior cruciate ligament, the other two passing upward and forward to be inserted in the lateral side of the medial tibial tuberosity (*medial condyle*) in front of, and behind the attachment of the posterior cruciate ligament. It forms the *accessory band of the posterior cruciate ligament.*

The **transverse ligament** is a fibrous continuation from the anterior convex margin of the external semilunar fibrocartilage (*lateral meniscus*) to the like part of its fellow; it varies much in size and is often absent.

The **coronary ligaments** are parts of the capsule, and are short, straight, fibrous bands connecting the convex margins of the semilunar fibrocartilages (*menisci*) with the adjoining tibial bone and ligaments.

The *synovial membrane of the knee-joint* lines the interarticular surfaces not subject to compression, that is, all the surfaces except those covered by articular cartilage, except the upper and lower surfaces of the semilunar fibrocartilages (*menisci*), which are covered by this membrane. It extends upward under the quadriceps extensor (*quadriceps femoris*) a distance of several centimeters, and laterally from the patella under the vasti muscles, especially under the internus (medialis), and is separated from the patellar ligament by a cushion of fat. Its reflections from the patella, forming the alar and mucous ligaments, have been described. The suprapatellar pouch of this membrane is drawn up when the knee is extended by the subcrureus (*articularis genu*) muscle which is attached to its apex. The knee-joint is subcutaneous in front and upon each side, but behind, where it forms the floor of the popliteal space, it is in close relation with many important structures. The popliteal vessels and internal popliteal (*tibial*) nerve pass downward behind it in the middle of the space, between the two heads of the gastrocnemius, the nerve being most superficial, and the artery hugging the bone and ligament, with the vein between them; lateral to them is the biceps femoris muscle and the external popliteal (*common peroneal*) nerve, while upon their medial side are the semitendinosus and semimembranosus muscles, the internal saphenous (*saphenous*) nerve, the superficial portion of the anastomotica magna (*genu suprema*) artery and the long (*great*) saphenous vein, the popliteus tendon being really within the joint at this point encased in its enveloping synovial sheath.

Blood Supply.—The knee-joint is supplied with blood by branches of the femoral anastomotica magna (*genu suprema*), popliteal articular (*genicular*), and anterior tibial recurrent arteries.

Nerve Supply.—From branches of the obturator, anterior crural (*femoral*), external popliteal (*common peroneal*), and popliteal (*tibial*) nerves.

Movements.—The movements of the knee-joint are: flexion, extension, and rotation, the last being most readily demonstrated upon the living subject with the knee at right angles and the foot upon the floor. Rotation occurs around the axis of the tibia. During flexion and extension the relatively short articular surfaces of the tibia glide over the more extensive ones of the femoral condyles, changing their relations. Thus, in extreme extension the middle of the condylar surfaces are upon the anterior tibial surface and edge; in middle flexion the lower condylar surface rests upon the middle of the tibial surface; and in extreme flexion the back of the condylar surface rests upon the back part of the tibial surface and its posterior edge. This action is identical with that of the phalangeal and knuckle joints. The ligamentum patellæ, being non-elastic, pulls the patella downward over the femoral condyles during flexion of the leg, so that when it is complete this bone lies over the intercondyloid fossa. All the ligaments of the joint, except that of the patella, are relaxed during extreme flexion and during the process of flexion, before it is tense, rotation of the leg at the knee is possible. Flexion is only checked by leg and thigh contact. In extreme extension the patellar ligament is so relaxed as to permit its free lateral movement, but the other true ligaments are tense. Over-extension is prevented by the posterior cruciate and posterior oblique ligaments. The anterior cruciate ligament checks rotation medialward (pronation), which is mainly accomplished by the popliteus muscle. The posterior cruciate ligament checks lateral rotation (supination), which is mainly accomplished by the biceps femoris muscle. The cruciate ligaments hold the tibia and fibula together, and check forward, backward, or lateral displacements. The semilunar fibrocartilages (*menisci*) adapt the top of the tibia to the femoral condyles, and protect the surfaces of both bones from injury due to violent and severe impact.

In most mammals the patellar-condylar and the two tibio-condylar articulations form distinct joints with separate synovial sacs, which, however, sometimes communicate. This division is rudimentarily made in man by the ligamentum mucosum (*patellar synovial fold*), while the cruciates are interarticular lateral ligaments. The patella performs a gliding and coaptating function, the former being self-evident, while the latter is shown by a vertical double row of three facets upon the posterior patellar surface, and a single facet below the last facet of the medial row. During extension the lower facets touch the surface of the condyles of the femur; in semi-flexion the middle facets, and in fuller flexion the upper facets, lie upon the femoral surface; while in extreme flexion the patella,

having been everted by the more prominent medial condyle, rests upon the lateral edge of this condyle by its lowest medial facet.

In affections of the knee-joint the cushion of fat behind the patellar tendon may readily be mistaken for either a serous or purulent accumulation of fluid. Effusions into the joint raise the patella from the condyles and cause slight genu-flexion, whereas effusions into the prepatellar bursa obscure the bone, and the fluctuation is subcutaneous. In distention of the knee-joint with fluid, bulging exists upon each side of the ligamentum patellæ and the patella, and under the quadriceps through the communication of the suprapatellar bursa with the joint. By compressing one or the other of these bulges, the others are exaggerated; and by this means the patella may be rocked upon the imprisoned fluid.

Pain in the knee may indicate early hip-joint disease, as well as affections of any of its supplying nerves anywhere between their distribution and central origin.

The **bursæ** near the knee-joint are numerous. The bursa between the patellar tendon and tibia, and the prepatellar bursa, have been described. A small one exists between the skin and tibial tubercle (*tuberosity*). A bursa is found under each head of the gastrocnemius, the medial one usually opening into the knee-joint and also into another bursa between the head of the tibia and the semimembranosus muscle. This bursa is sometimes distended with synovial fluid, being made hard, tense, painful, and distinctly outlined by extension, but being much less evident during flexion. Sometimes fluctuation can be demonstrated between its contents and that of the knee-joint. If it is carelessly opened without regard to its communication with the knee-joint, irreparable damage may be done by a resultant acute septic arthritis. Other bursæ also exist between the lateral ligaments and the tendons that cross them. There is also a suprapatellar bursa between the subcrureus (*articularis genu*) muscle and the femur, which in the adult communicates with the synovial pouch of the knee-joint. Communication sometimes occurs between the knee-joint and the superior tibio-fibular membrane, through the bursa beneath the popliteal tendon.

THE TIBIO-FIBULAR JOINTS

The **Tibio-fibular Joints** are situated at the two extremities of the tibia and fibula, and are called *proximal*, or *superior*, and *distal*, or *inferior*. The *interosseous membrane* connects the two bones along their shafts.

The **proximal**, or **superior, tibio-fibular joint** consists of the junction of the superomedial surface of the head of the fibula with the inferior surface of the lateral tuberosity (*lateral condyle*) of the tibia, each a flat oval surface. These

surfaces are held together by the capsular and the anterior and posterior superior tibio-fibular ligaments (*ligaments of the head of the fibula*).

The *capsular ligament* (*articular capsule*) is attached close to the articular margins of the fibula and tibia. The capsule and the coronary ligament of the knee separate it from the knee-joint in front; but behind, where it is thin, it may communicate with the bursa under the popliteus tendon.

The *anterior tibio-fibular ligament* (*anterior ligament of the head of the fibula*) consists of two or three flat bands extending across the proximal part of the anterior junction of the bones, extending upward and medialward from the fibular head to the front of the tibial tuberosity (*lateral condyle*), beneath the anterior portion of the biceps femoris tendon.

The *posterior tibio-fibular ligament* (*posterior ligament of the head of the fibula*) is thick and broad, and extends from the back of the fibular head to the external tibial tuberosity (*lateral condyle*). It is covered by the popliteus tendon.

The *superior interosseous ligament* binds the bones together for a distance of about two centimeters (three-fourths of an inch) below their articulation, and is continuous below with the interosseous membrane.

The *biceps femoris tendon* also acts as a ligament to the proximal tibio-fibular joint.

The *synovial membrane* lining this joint is sometimes continuous with that of the knee in its upper posterior part.

The *interosseous membrane* is a fibrous sheet extending across the space between the tibia and fibula, and is attached to their opposed ridges. Most of its fibers are directed downward and lateralward, only a few passing downward and medialward. It separates the front from the back of the leg, and gives attachment to the anterior tibial and the deep posterior tibial muscles. It is widest above, where it contains an oval foramen for the transmission of the anterior tibial vessels; a smaller aperture at its distal end gives passage to the anterior peroneal vessels. It is continuous below with the superior and inferior interosseous ligament.

The **distal,** or **inferior, tibio-fibular joint** is formed by the union of the rough convex medial surface of the lower end of the fibula with a similar surface upon the lateral side of the lower end of the tibia. These surfaces are held together by the following four ligaments:

The *inferior interosseous ligament* is composed of numerous strong short fasciculi extending between the adjacent rough surfaces of these bones, forming their main bond of union, and being continuous with the interosseous membrane above.

The *anterior tibio-fibular ligament* (*anterior ligament of the lateral malleolus*) is triangular, with the base below. It passes inferolaterally from the lateral margin

of the tibia to that of the fibula, the upper fibers being the shortest. In front it is crossed by the peroneus tertius muscle and the deep fascia of the leg.

The *posterior tibio-fibular ligament* (*posterior ligament of the lateral malleolus*) has attachments behind similar to the preceding, but smaller.

The *transverse* (*distal transverse*) *ligament*, long and narrow, and continuous with the posterior ligament, is placed transversely behind the joint from the lateral malleolus to the back of the tibia near its malleolus. At the fibula it is closely connected with the posterior fibulo-astragaloid (*talo-fibular*) ligament.

The *synovial membrane of the joint* is continuous with that of the ankle-joint.

Blood Supply.—The blood supply of the superior tibio-fibular joint is derived from the inferior articular (*middle genicular*) branches of the popliteal artery, and from the anterior tibial recurrent artery. That of the lower joint is derived from the peroneal, anterior peroneal, the anterior tibial, and external (*lateral*) malleolar arteries.

Nerve Supply.—The superior tibio-fibular joint is supplied by the external (*lateral*) inferior articular and the recurrent branch of the external popliteal (*common peroneal*). The inferior joint is supplied by the internal saphenous (*saphenous*), posterior tibial (*tibial*), and anterior tibial (*deep peroneal*) nerves.

Movements.—The movements of the tibio-fibular joints are insignificant, consisting only of a very slight gliding motion and slight rotation of the fibula in its long axis.

THE ANKLE-JOINT OR TALO-CRURAL ARTICULATION

The **Ankle-joint,** which is a ginglymus or hinge joint, is formed by the articulation of the distal ends of the tibia and fibula above, with the top of the astragalus (*talus*) below. The distal end of the tibia and the lateral side of its malleolus, together with the medial side of the lateral malleolus (fibula), form an angular arch that fits upon the upper surface of the astragalus (*talus*), the *mortise* thus formed being broader in front than behind. These bones are held in place by the capsule and the following ligaments: the internal lateral (*deltoid*) and the external lateral (*talo-fibular*) and the middle external (*calcaneo-fibular*).

The capsule, which is in itself especially strong, arises from the lower anterior edge of the tibia about one centimeter (about a half inch) above its distal end, from the lower border of the anterior tibio-fibular ligament, from the anterior surface of both malleoli, and from a portion of the malleolar articulating surfaces. The posterior half above is more adjacent to the articular border of the back of the tibia and of its malleolus. The lateral half arises from the posterior border of the lateral malleolus, leaving a pocket posterior to the lateral articular surface. The capsule inserts below, into the top and sides of the astrag-

alus (*talus*), surrounding its articular surface. Some authors describe an **anterior** and a **posterior ligament.** The **anterior** fibers are longitudinal and thin. The attachments above and below are the same as those of the capsule, and laterally it is attached to the internal lateral (*deltoid*) and external lateral (*talo-fibular*) ligaments. The **posterior** fibers are extremely thin and stretch over the synovial membrane between the back of the tibia and the astragalus (*talus*).

The **internal lateral** (**deltoid**) ligament is an extremely strong portion of the capsule. It arises from the notch on the posterior border and from the tip of the medial malleolus. It runs downward and backward to the astragalus (*talus*) below the medial articular surface, and to the sustentaculum tali. The posterior portion of the ligament is almost one centimeter (one-third of an inch) thick. The thinner anterior portion runs to the inferior calcaneo-scaphoid (*plantar calcaneo-navicular*) ligament and may be traced to the scaphoid (*navicular*) after joining the superior astragalo-scaphoid (*superior talo-navicular*) ligament.

The **external lateral ligament,** owing to the fact that it consists of three distinct fasciculi, each of which takes a separate course, is described by some anatomists as three separate ligaments. The divisions of the ligament are generally classified as anterior, middle, and posterior fasciculi. The *anterior fasciculus* (*anterior talo-fibular ligament*) is the shortest of the three; it extends from the anterior margin of the tip of the fibula to the astragalus (*talus*), anterior to its articular surface. Its direction is almost horizontally forward and medialward. The *middle fasciculus* (*calcaneo-fibular ligament*) is cord-like and long, extending from the apex of the lateral malleolus to the lateral surface of the os calcis (*calcaneus*). Its direction is obliquely downward and slightly backward. The *posterior fasciculus* (*posterior talo-fibular ligament*) is the most deep seated of the three; its fibers extend from the depression in the posterior part of the astragalus (*talus*). Its direction is horizontally lateralward.

The *synovial membrane of the ankle-joint* lines the adjacent surfaces of the ligaments and extends upward into the distal tibio-fibular articulation. It also forms a fold on the inside of the joint above the posterior band (*posterior talo-fibular ligament*) of the external lateral ligament leaving a pouch above this and below the transverse ligament.

The joint is crossed anteriorly, lateromedialward, by the tendons of the peroneus tertius and the extensor digitorum communis muscles, the anterior tibial (*deep peroneal*) nerve, the anterior tibial vessels, and the tendons of the extensor hallucis longus and tibialis anterior muscles, with the annular ligament in front of all. Behind the medial malleolus, the joint is crossed, mediolateralward, by the tendons of the tibialis posterior and flexor digitorum longus, the posterior tibial vessels, the posterior tibial (*tibial*) nerve, and the tendon of the

flexor hallucis longus. These structures are held in place by the **internal annular ligament** (**ligamentum laciniatum**), formed by the blending of the two layers of the deep fascia of the back of the leg and extending from the lateral malleolus to the adjacent surface of the os calcis (*calcaneus*). Behind the lateral malleolus, the joint is crossed by the tendons of the long and short peronei, the latter being the more anterior. These tendons are held in place by the **external annular ligament** (**peroneal retinacula**), which extends from the tip of the lateral malleolus to the os calcis (*calcaneus*).

Blood Supply.—The ankle-joint is supplied by the malleolar branches of the anterior and posterior tibial and the peroneal arteries.

Nerve Supply.—By branches of the anterior tibial (*deep peroneal*) and posterior tibial (*tibial*), and internal saphenous (*saphenous*) nerves.

Movements.—The movements of the ankle-joint consist of flexion and extension, with the possibility of slight lateral motion during extreme extension. This is because the front of the joint is wider than its back part, the astragalus (*talus*) being the same. The fibula moves to some degree on the tibia, and the astragalus (*talus*), which is more closely applied to the fibula, follows the latter in its movements. Therefore, when the ankle is fully extended plantarward, the narrower back part of the top of the astragalus (*talus*) comes forward between the wider front portion of the intermalleolar space, thus permitting slight lateral movement. When, however, the opposite position exists, the intermalleolar ligaments are stretched by the forcing back of the widest surface of the astragalus (*talus*) toward the narrower part of the intermalleolar space. The lateral margin of the upper joint surface of the astragalus (*talus*) is curved and longer than its medial edge, thus accounting for the slight medial movement of the toes when the foot is extended.

The tendo Achillis (*tendo calcaneus*) is behind the ankle-joint, from which it is separated by loose connective tissue often containing an abundance of fat. This powerful structure really performs the retentive function of a posterior ligament to the joint, and accounts for the absence, except in a most rudimentary form, of the posterior fibrous layer. This tendon may require section in contraction of the calf muscles causing talipes equinus, or club-foot, or after osteotomy of a bowed leg. Tenotomy is best performed here by first making the tendon tense by strong dorsi-flexion, pushing the tenotome through the skin under the tendon and cutting from within outward (before backward). By cutting in the other direction, from without inward, the postmalleolar vessels and nerves might be wounded or some of the tendon sheaths be opened. Rupture of the tendon may occur from violent strain, the injured person feeling at the time as if struck violently above the heel. In case of rupture of the tendo

PLATE CCCXXIV.

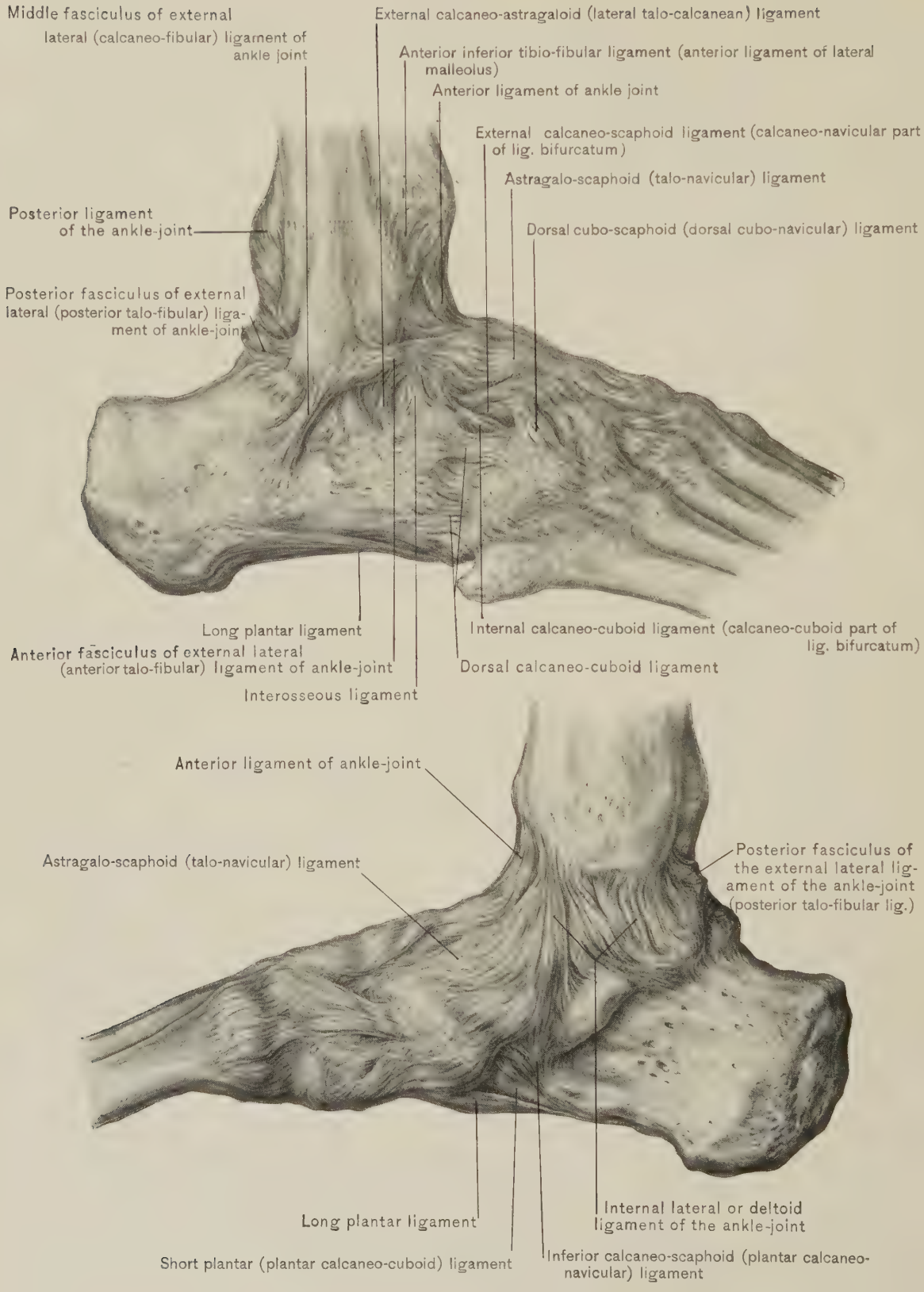
Middle fasciculus of external lateral (calcaneo-fibular) ligament of ankle joint
External calcaneo-astragaloid (lateral talo-calcanean) ligament
Anterior inferior tibio-fibular ligament (anterior ligament of lateral malleolus)
Anterior ligament of ankle joint
External calcaneo-scaphoid ligament (calcaneo-navicular part of lig. bifurcatum)
Astragalo-scaphoid (talo-navicular) ligament
Posterior ligament of the ankle-joint
Dorsal cubo-scaphoid (dorsal cubo-navicular) ligament
Posterior fasciculus of external lateral (posterior talo-fibular) ligament of ankle-joint
Long plantar ligament
Anterior fasciculus of external lateral (anterior talo-fibular) ligament of ankle-joint
Interosseous ligament
Internal calcaneo-cuboid ligament (calcaneo-cuboid part of lig. bifurcatum)
Dorsal calcaneo-cuboid ligament
Anterior ligament of ankle-joint
Astragalo-scaphoid (talo-navicular) ligament
Posterior fasciculus of the external lateral ligament of the ankle-joint (posterior talo-fibular lig.)
Long plantar ligament
Short plantar (plantar calcaneo-cuboid) ligament
Internal lateral or deltoid ligament of the ankle-joint
Inferior calcaneo-scaphoid (plantar calcaneo-navicular) ligament

LIGAMENTS OF TARSUS—LATERAL AND MEDIAL VIEWS.

Achillis (*tendo calcaneus*), the foot must be strongly extended and thus held until union is effected, or the torn ends may be approximated by sutures. In talipes calcaneus, due to paralysis of the calf muscles, a part of the tendon is removed and the cut ends united, so that the heel may be held up mechanically against the dorsi-flexing efforts of the anterior tibial group of muscles.

The muscles brought into play during the extension (*plantar flexion*) of the foot on the leg are: the gastrocnemius, plantaris, soleus, tibialis posterior, peroneus longus and brevis, flexor digitorum longus, and flexor hallucis longus; during flexion (*dorsi-flexion*), the tibialis anterior, peroneus tertius, extensor digitorum longus, and extensor hallucis longus; during adduction, the tibialis anterior and posterior; during abduction, the peronei.

Articulation effusion causes bulging in front of the joint (obliterating the tendinous markings), around the malleoli, and upon either side of the tendo Achillis (*tendo-calcaneus*). Extra-articular effusions are limited in area. If the swelling is severe it extends down on the dorsum of the foot for two and a half or more centimeters (an inch or more). The swelling of ankle-joint disease is horizontal, while that of disease affecting the anterior tendon sheaths is more apt to be vertical in its direction.

THE INTERTARSAL ARTICULATIONS (Plate CCCXXIV)

These articulations are divided into the following groups: the calcaneo-astragaloid joint; the articulations of the anterior portion of the tarsus; and the medio-tarsal joint.

The Calcaneo-astragaloid (Talo-calcaneal) Articulation.—The astragalus (*talus*) articulates with the os calcis (*calcaneus*) at two points, making a posterior and an anterior articulation, the two joints being separated by the interosseous astragalo-calcaneal (*talo-calcaneal*) ligament.

The **anterior calcaneo-astragaloid (talo-calcaneal) articulation** communicates with the medio-tarsal joints, and is formed by the upper anterior facet on the os calcis (*calcaneus*) and the facets on the inferior surface of the head and neck of the astragalus (*talus*). The ligaments of this point of union are the interosseous, the internal and anterior calcaneo-astragaloid (*medial and anterior talo-calcaneal*) and the external calcaneo-scaphoid (*plantar calcaneo-navicular*). This articulation together with its scaphoid connection which really should be considered as the anterior calcaneo-scapho-astragaloid (talo-calcaneo-navicular) joint is to a degree a ball and socket joint.

The *interosseous talo-calcaneal ligament* is the most powerful of the ligaments of this articulation, being the main bond of union between the bones. It consists of strong fibers which pass from the groove on the under side of the astragalus

(*talus*) to the depression between the articular facets on the upper part of the calcaneus. Strong fibers extend from the lower lateral surface of the neck of the astragalus (*talus*) to the anterior upper surface of the calcaneus, forming the posterior boundary of the anterior calcaneo-astragaloid joint. These fibers are called the anterior interosseous ligament.

The *antero-internal calcaneo-astragaloid* (*anterior and medial talo-calcaneal*) *ligament* connects the medial surface of the neck of the astragalus (*talus*) to the upper edge of the free border of the sustentaculum tali. It blends posteriorly with the interosseous ligament, and anteriorly with the inferior astragalo-scaphoid (*talo-navicular*) ligament. The internal lateral (*deltoid*) ligament strengthens it.

The *external calcaneo-scaphoid* (*plantar calcaneo-navicular*) *ligament* forms the lateral limits of this as well as of the calcaneo-scaphoid (*calcaneo-navicular*) articulation. It will be described with the latter joint.

The *synovial sac* is continuous with that of the astragalo-scaphoid (*talo-navicular*) joint.

The **posterior calcaneo-astragaloid** (**talo-calcaneal**) **articulation** is formed by the facet on the body of the astragalus (*talus*) and the posterior facet on the upper surface of the os calcis (*calcaneus*). The ligaments of this joint are the interosseous, external and internal calcaneo-astragaloid (*lateral* and *medial talo-calcaneal*), and the posterior calcaneo-astralagoid (*posterior talo-calcaneal*).

The *interosseous ligament* has been described.

The *external calcaneo-astragaloid* (*lateral talo-calcaneal*) *ligament*, short and strong, passes from the groove on the lateral surface of the astragalus (*talus*) to the lateral surface of the calcaneus below its articular margin. It lies on a deeper plane than the middle fasciculus of the external lateral (*calcaneo-fibular*) ligament of the ankle, and somewhat in front of it, the general course of the fibers of the two, however, being the same.

The *internal calcaneo-astragaloid* (*medial talo-calcaneal*) *ligament* passes from the tuberosity of the astragalus (*talus*), obliquely downward and backward, to the sustentaculum tali.

The *posterior calcaneo-astragaloid* (*posterior talo-calcaneal*) *ligament* closes in the calcaneo-astragaloid (*talo-calcaneal*) articulation behind. It passes from the lateral process of the astragalus (*talus*) to the os calcis (*calcaneus*), being attached to the latter bone a variable distance from its articular margin.

The *synovial sac* is not connected with any other.

Blood Supply.—From branches of the posterior tibial, dorsalis pedis, and peroneal arteries.

Nerve Supply.—From the posterior tibial (*tibial*) or plantar nerves.

Movements.—These joints allow adduction, abduction, and some rotation.

The Medio-tarsal Articulations.—This set includes the astragalo-scaphoid (*talo-navicular*) and the calcaneo-cuboid articulations.

The **astragalo-scaphoid (talo-navicular) articulation** is formed by the head of the astragalus (*talus*) fitting into the depression formed by the posterior surface of the scaphoid (*navicular*), the anterior articulating surface of the calcaneus, and the superior surface of the inferior calcaneo-scaphoid (*plantar calcaneo-navicular*) ligament.

The *astragalo-scaphoid* (*talo-navicular*) is the only ligament of this joint. It is a membranous band found on the dorsum of the foot. It passes obliquely forward from the head of the astragalus (*talus*) to the superior surface of the scaphoid (*navicular*) bone.

Two other ligaments, while not attached to the astragalus (*talus*), strengthen and steady the joint. These are the *external calcaneo-scaphoid* (*calcaneo-navicular part of lig. bifurcatum*) and the *inferior calcaneo-scaphoid* (*plantar calcaneo-navicular*) *ligaments*, that hold together the calcaneus and scaphoid (*navicular*), the bones, however, not articulating.

The *external calcaneo-scaphoid ligament* (*calcaneo-navicular part of lig. bifurcatum*) is attached, in conjunction with the internal calcaneo-cuboid (*calcaneo-cuboid part of lig. bifurcatum*) in the medial astragalo-calcaneal (*talo-calcaneal*) sulcus. It passes from the medial side of the calcaneus to the lateral side of the scaphoid (*navicular*).

The *inferior calcaneo-scaphoid* (*plantar calcaneo-navicular*) *ligament*, strong, broad and thick, extends from the front and medial extremity of the under surface of the os calcis (*calcaneus*) to the inferior surface of the scaphoid (*navicular*). This ligament fills the gap on the plantar side of the foot between the sustentaculum tali and the scaphoid (*navicular*). It is wide, and helps to form the articular cavity for the head of the astragalus (*talus*). Above, it is covered with synovial membrane, while below it is the tendon of the tibialis posterior.

The *synovial sac* found in this joint is continuous with the one found in the anterior calcaneo-astragaloid (*talo-calcaneal*) joint.

The **calcaneo-cuboid articulation** is surrounded by a capsule, the medial side of which is formed by the interosseous calcaneo-scaphoid (*calcaneo-navicular*) ligament. It is a modified saddle joint. The motion is largely a screw motion. The capsule is supported by four ligaments, two plantar and two dorsal.

The *long calcaneo-cuboid*, or *long plantar, ligament* is the longest of the tarsal ligaments. It is superficial to the short plantar (*plantar calcaneo-cuboid*); its fibers extend from the inferior surface of the os calcis (*calcaneus*) in front of the posterior tubercles, to the ridge of the inferior surface of the cuboid, some of

them, however, passing forward to be inserted into the bases of the third, fourth, and fifth metatarsal bones. It covers the peroneus longus muscle.

The *short plantar (plantar calcaneo-cuboid) ligament* lies close to the bones, being separated from the long plantar ligament by a small amount of adipose tissue. It is very broad but short, being only two and a half centimeters (one inch) in length. It passes from the anterior tubercle of the calcaneus to the inferior surface of the cuboid behind the ridge.

The *dorsal calcaneo-cuboid ligament* is a thin band which passes from the dorsal surface of the calcaneus to the dorsal surface of the cuboid.

The *interosseous calcaneo-cuboid ligament*, a part of the interosseous calcaneo-cubo-scaphoid (*calcaneo-navicular*) ligament, forms one of the strongest bonds of union between the first and second rows of tarsal bones. It is a short and thick band of fibers found in the hollow between the astragalus (*talus*) and the calcaneus. This ligament and the one previously mentioned constitute the Y, or bifurcate, ligament of the French anatomists. The interosseous ligament is the more important.

The Articulations of the Anterior Part of the Tarsus (Plate CCCXXV). This set includes the scapho-cuneiform (*naviculo-cuneiform*), cubo-scaphoid (*cubo-navicular*), intercuneiform, and cubo-cuneiform (*cuneo-cuboid*) joints.

The **scapho-cuneiform** (**naviculo-cuneiform**) **articulation** is formed by the three cuneiform bones anteriorly and by the scaphoid (*navicular*) posteriorly. The ligaments of the articulation are the dorsal and plantar. The *dorsal ligaments* are three small fasciculi which pass from the dorsal surface of the scaphoid (*navicular*) to the dorsal surface of each of the cuneiform bones. The *plantar ligaments* are similar bands but are strengthened by small strips given off from the tendon of the tibialis posterior muscle.

The **scapho-cuboid** (**cubo-navicular**) **articulation** has three ligaments: a dorsal and a plantar scapho-cuboid (*cubo-navicular*) and an interosseous.

The *dorsal scapho-cuboid* (*cubo-navicular*), composed of short fibers, extends obliquely between the two bones, and the *plantar scapho-cuboid* (*cubo-navicular*) passes transversely between the two bones.

The *interosseous* intervenes between adjacent surfaces of the bones.

The scapho-cubo-cuneiform (*cubo-naviculo-cuneiform*) may be considered as one joint bounded by a synovial cavity extending for varying distances between the bones. Between the first and second cuneiform it communicates with the joint of the second metatarsal, while it is bounded by the interosseous ligament between the second and third metatarsals and by the same structure between the latter and the cuboid. The interosseous ligament resists the tendency to spreading of the transverse arch of the foot.

PLATE CCCXXV.

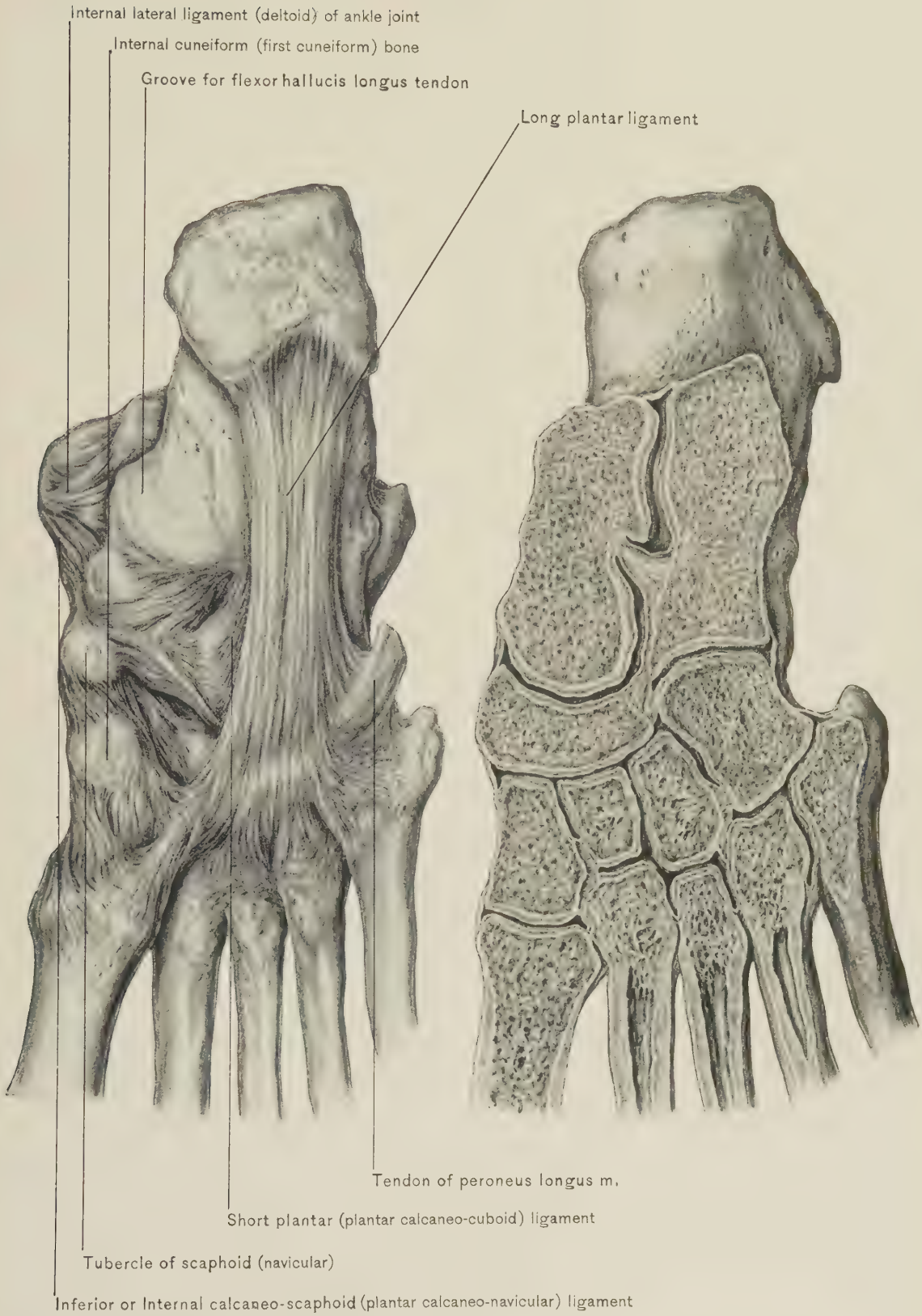
Internal lateral ligament (deltoid) of ankle joint
Internal cuneiform (first cuneiform) bone
Groove for flexor hallucis longus tendon
Long plantar ligament
Tendon of peroneus longus m.
Short plantar (plantar calcaneo-cuboid) ligament
Tubercle of scaphoid (navicular)
Inferior or Internal calcaneo-scaphoid (plantar calcaneo-navicular) ligament

(A) LIGAMENTS OF THE FOOT, PLANTAR SURFACE. (B) SECTION SHOWING THE SYNOVIAL CAVITIES OF THE FOOT.

The **intercuneiform** and the **cubo-cuneiform articulations** are held together by dorsal, plantar, and interosseous ligaments.

The *dorsal ligaments* are made up of three bundles, two connecting the cuneiform bones with each other, and the other connecting the lateral (*third*) cuneiform with the cuboid. They pass transversely.

The *plantar ligaments* are two in number. One unites the medial (*first*) with the middle (*second*) cuneiform; the other, the lateral (*third*) with the cuboid. They are strengthened by strips from the tendon of the posterior tibial muscle.

The *interosseous ligaments* are three in number and connect the cuneiform bones with each other and the lateral (*third*) cuneiform bone with the cuboid.

The *synovial membranes* of the intercuneiform, the cubo-cuneiform, and the scapho-cuboid (*cubo-navicular*) articulations are parts of the great tarsal synovial membrane.

THE TARSO-METATARSAL ARTICULATIONS

The articulations of the tarsal with the metatarsal bones may be divided into three sets: the medial, between the internal (*first*) cuneiform and first metatarsal bones; the middle (*intermediate*), between the three cuneiforms and the second and third metatarsal bones; and the lateral, or cubo-metatarsal, between the cuboid and the fourth and fifth metatarsal bones.

The **Internal (Medial) Articulation** is supported by a *capsular ligament*, which is strong on its plantar aspect, and blends with the scapho-cuneiform (*cuneo-navicular*) ligament.

The **Middle (Intermediate) Articulation,** formed by the three cuneiform and the second and third metatarsal bones, is supported by dorsal, plantar, and interosseous ligaments.

The *dorsal ligaments* are strong, flat bands which unite the three cuneiform bones to the bases of the metatarsals.

They vary in their arrangement between the articulating bones, the medial (*first*) cuneiform being attached to the second metatarsal by a narrow fibrous band; the second metatarsal receives a slip from each of the cuneiform bones, and the third metatarsal receives only one, from the external (third) cuneiform.

The *plantar ligaments* are less regular than the dorsal. Oblique bands connect the medial (*first*) cuneiform to the second and third metatarsal bones, while others pass transversely from the lateal (*third*) cuneiform to the third metatarsal.

The *interosseous ligaments* are the medial, intermediate and lateral; the *medial* passes from the medial (*first*) cuneiform to the second metatarsal; the *intermediate* passes from the lateral (*third*) cuneiform to the second metatarsal

bone; and the *lateral* passes from the lateral side of the lateral (*third*) cuneiform to the third and fourth metatarsal bones.

The **External (Lateral)** or **Cubo-metatarsal Articulation** is also supported by dorsal, plantar, and interosseous ligaments.

The *dorsal ligament* passes from the cuboid to the bases of the fourth and fifth metatarsals, and forms part of the capsule of the joint.

The *plantar ligament* extends from the cuboid to the bases of the fourth and fifth metatarsal bones. At the lateral side of the fifth metatarsal bone it becomes continuous with the dorsal ligament and medially with the interosseous ligaments, completing the capsule.

The *interosseous ligament* divides the cubo-metatarsal from the intermediate tarso-metatarsal joint. It extends from the lateral (*third*) cuneiform to the apposed surfaces of the third and fourth metatarsal bones.

There are three *synovial sacs* in relation with the tarso-metatarsal articulations, one between the medial (*first*) cuneiform and the first metatarsal; a second or middle sac is found between the middle (*second*) and lateral (*third*) cuneiform and the second and third metatarsal, and is continuous with the scapho-cuneiform (*cuneo-navicular*) and intercuneiform joints; and the third is between the cuboid and the fourth and fifth metatarsals.

Blood Supply.—The blood supply of the tarso-metatarsal joints is derived from the dorsalis pedis, the plantar, and metatarsal arteries.

Nerve Supply.—From the anterior tibial (*deep peroneal*) and plantar nerves.

Movements.—These joints permit of flexion and extension of the metatarsus on the tarsus; and a gliding motion which diminishes or increases the arch of the foot.

THE INTERMETATARSAL ARTICULATIONS

The metatarsal bones are held together at their bases by dorsal, plantar, and interosseous ligaments; and at their heads by a transverse metatarsal ligament.

The *dorsal ligaments* unite the four lateral metatarsal bones on their dorsal aspect. The ligament from the medial (*first*) cuneiform to the base of the second metatarsal bone acts as a dorsal ligament between the first and second metatarsal bones.

The *plantar ligaments* are strong and well marked and connect the bases of the bones on their plantar surfaces.

The *interosseous ligaments* connect the non-articular surface beyond the bases of the bones and limit the synovial cavities.

At their heads these bones are united by a strong *transverse metatarsal ligament* which blends with the sheath of the flexor tendons. It differs from its

counterpart in the hand in that a slip passes from the first to the second metatarsal bone, so that in the foot it connects all five digits, while in the hand it connects only four.

Blood Supply and Nerve Supply.—The same as in the tarso-metatarsal articulations.

Movements.—A gliding movement to raise or flatten the transverse arch of the foot.

THE METATARSO-PHALANGEAL ARTICULATIONS

These joints are formed by the rounded heads of the metatarsal bones and the cup-like depression in the base of the corresponding proximal phalanges. The joints are supported by a dorsal and two lateral (*collateral*) ligaments, and by a plantar sesamoid plate.

The *lateral* (*collateral*) *ligaments* are identical in their arrangement with their counterparts in the hand. Connecting the sides of the articulating bones, they are united above by the dorsal ligament.

The *dorsal ligament* extends between the lateral (*collateral*) ligaments and completes the capsule and is connected with the extensor tendons.

The *plantar sesamoid plate* (*plantar accessory ligament*) deepens the facet on the head of the phalanx and thus prevents dislocation. It is absent in the great toe, being replaced there by sesamoid bones developed in the tendon of the flexor hallucis brevis muscle. Its counterpart in the hand is the glenoid ligament.

The *synovial membrane* is quite loose.

Blood Supply.—From the digital arteries.

Nerve Supply.—From the cutaneous, digital, or interosseous, branches of the anterior tibial (*deep peroneal*) and the plantar nerves.

Movements.—These joints permit flexion, extension, abduction, adduction, and circumduction.

THE INTERPHALANGEAL ARTICULATIONS

Each toe possesses two interphalangeal joints with the exception of the great toe which has only one.

These joints are similar to those in the fingers, with the exceptions that the bones are smaller and that the joints are often ankylosed. The ligaments that support the joints are the two lateral (*collateral*), the dorsal, and the plantar.

The *collateral ligaments* connect the sides of the head and base of the corresponding phalanges.

The *dorsal ligaments* unite the lateral ligaments and are connected with the extensor tendons.

The *plantar ligaments* (fibro-cartilaginous plates) protect the joints on their plantar surface, and are grooved by the flexor tendons.

Blood Supply and Nerve Supply.—From the digital arteries and nerves.

Movements.—These are restricted to flexion and extension.

THE FOOT AS A WHOLE

The **Foot** is composed of twenty-six bones: seven of the tarsus, five of the metatarsus, and fourteen phalanges. The foot joins the leg at right angles. This peculiarity, together with the similar cranio-vertebral junction, is seldom seen in any of the lower animals.

The foot is composed of a number of arches diverging from the medial tuberosity of the os calcis (*calcaneus*) and ending anteriorly at the heads of the metatarsal bones. The main arches are the longitudinal and transverse.

The **longitudinal arch** extends from the heel to the metatarso-phalangeal joints, its summit being crowned by the astragalus (*talus*), upon which are mounted the leg bones. It is divided into a posterior pillar, composed of the posterior portion of the astragalus (*talus*) and the os calcis (*calcaneus*), and an anterior pillar, formed by the anterior portion of the astragalus (*talus*), and the rest of the tarsal and metatarsal bones. The highest part of the astragalus forms the summit of the arch. The longitudinal arch is really a series of arches mediolaterally. The highest arch is that in the line of the great toe, while that in line of the small toe is the lowest. The vault is not rigid, and is capable of considerable variation.

The *posterior pillar* is half as long as the anterior, and thus has a less gradual ascent. The foot being viewed as a lever of the second class, with the weight upon the continuity of the lever (between its ends), the fulcrum is at the ball of the foot, while the power is applied at the heel by the tendo Achillis (*tendo calcaneus*). The shortness of the posterior limb of the pedal arch conduces to celerity of movement at the expense of power, while its composition, of the thick heavy os calcis (*calcaneus*) and back part of the astragalus (*talus*), gives it the advantage of solidity for the leverage of the tendo Achillis (*tendo calcaneus*), without loss of power through multiple joints and their movements. The posterior calcaneo-astragaloid (*posterior talo-calcaneal*) joint is its only articulation.

The *anterior pillar*, because of its numerous parts and their gliding synovial interstices, presents an elastic resistance to sudden impact upon the ball of the extended foot, and thus lessens the jar upon the ankle, knee, hip, spinal column, and intracranial contents, in the order named. In broad jumping the heel strikes the ground first, but the great momentum of the body quickly carries it forward

upon the toes, thus rocking it upon the foot from the heel to the ball, the ultimate and greater strain falling upon the anterior pillar of the arch.

The arch is triangular, with its apex at the heel and its base at the ball of the foot. The widening of the anterior pillar of the arch from the astragalus (*talus*) to the ball of the foot serves to distribute force along the five metatarsal bones to the ball of the foot.

The *anterior pillar of the arch of the foot* is also divided longitudinally into two pillars: a *medial pillar*, consisting of the astragalus (*talus*), scaphoid (*navicular*), three cuneiform, and the first, second and third metatarsal bones; and a *lateral pillar*, formed by the cuboid, and the fourth and fifth metatarsal bones, the cuboid being the real arch and the metatarsals its lateral brace. In standing, most of the weight of the body is transmitted to the medial pillar, and because of the longer downward extension of the lateral malleolar articulation of the astragalus (*talus*), the weight is mainly thrown upon the medial side of this pillar, falling eventually upon the ball of the great toe, where it is most ably borne. The cuboid braces the lateral (*third*) cuneiform bone just where it tends to bulge, and also receives some weight from the os calcis (*calcaenus*), and transmits it to the fourth and fifth metatarsal bones.

The **transverse arch** is most noticeable in the tarso-metatarsus, and adds to the stability of the longitudinal arch, especially in front, where it materially aids in preventing undue spreading at the metatarsus and the ball of the foot, besides providing additional elasticity. It is most marked at the cuneiform bones.

The **lateral arch** of the foot is convex laterally from the heel to the base of the little toe, giving the best basis of support for the leg and its superimposed weight, which, because of the medial direction of the femur and lower end of the tibia, is directed downward and medialward. On this account it is also appropriate that the medial side of the foot is much stronger and more arched, as the downward pressure is radiated lateralward, forward, and backward from it, to the calcaneo-cuboid arch, the ball, and the heel, respectively.

Another advantage of the plantar arches consists in the security from compression they afford the plantar muscles, vessels, tendons, and nerves.

The arches of the foot are maintained by the bridge or keystone arrangement of the bones, especially noticeable in the cuneiform bones and the bases of the metatarsals in preserving the transverse arch, and the ligaments, tendons, and muscles. One of the most important structures in the maintenance of these curves is the tendon of the peroneus longus, which, it will be remembered, passes downward behind the lateral malleolus, then through grooves on the lateral side of the os calcis (*calcaneus*) and under side of the cuboid, to be attached to the under surface of the base of the great toe. It thus assists in the support of both the longitudinal

and transverse arches. The long calcaneo-cuboid (*long plantar*) ligament, extending longitudinally between the two ends of the long arch, forms its most important tie or brace.

The functions of the arches of the foot therefore are: (1) to distribute the weight of the body; (2) to give spring and elasticity to the step; (3) to break shocks, in running and jumping; (4) to provide a space where soft parts of the sole may lie free from undue pressure.

Flat-foot is a lowering of the medial pillar of the pedal arch by sinking of the astragalo-scaphoid (*talo-navicular*) junction. This deformity is due to habitual strain early in life, and to cramping the foot in thick heavy shoes during growth. Even adults carrying very heavy loads often become flat-footed from gradual yielding of the calcaneo-scaphoid (*calcaneo-navicular*), the long calcaneo-cuboid (*long plantar*) and short calcaneo-cuboid (*plantar*) ligaments, the plantar fascia, and the tendons of the anterior and posterior tibials and of the peroneus longus, resulting in the rolling downward and medialward of the head of the astragalus (*talus*) and the descent of the medial scaphoid (*navicular*) tuberosity, of the medial (*first*) cuneiform, and of the first metatarsal base. Relief of strain incident to heavy carrying, and the regular performance of suitable gymnastic exercises, may effect a cure. A boot which gives proper support and does not constrict the anterior portion of the foot should be prescribed.

In the **negro-heel** the posterior limb of the arch is elongated, while there is also a shallowness of the transverse arch, and more of the lateral edge of the foot touches the ground.

Talipes, or **Club-foot,** is a permanent adduction, abduction, extension, or flexion of the foot, even in walking, so that only the lateral or medial side of the foot, or the ball, or the heel, respectively, touches the ground; or combinations of these may occur. Many of the newer text-books on surgery include only talipes equino-varus under true club foot. I have however retained the more liberal interpretation.

The commonest form is **talipes, or pes, equino-varus,** in which the heel is drawn upward and the lateral side and the ball of the foot rest upon the ground. It is often congenital, and then may be a continuance of the normal intra-uterine position of the foot, probably due to pressure from the uterine wall. It may, however, be associated with some malformation of the bones of the foot. When acquired it may be due to paresis or to paralysis of those muscles which oppose adduction and extension (*dorsal flexion*) of the foot, that is the extensor digitorum longus and the peronei. The object of treatment is to restore the foot to its normal position and retain it there. The least severe measures should be utilized first, such as gentle manipulation or retention in an improved position either

by a cast or brace. Should these be unsuccessful, especially in older children and adults, extreme force may be utilized or tenotomy may be performed. This should be done as early as possible after unsuccessful use of the milder methods, to prevent permanent changes in the shape of the bones. The tendons to be severed in the operation are the tendo Achillis (*tendo calcaneus*), which sometimes is sufficient, the tibialis anterior, tibialis posterior, the flexor digitorum longus, and the front of the internal lateral (*deltoid*) ligament attached to the scaphoid (*navicular*) tuberosity, the medial part of the plantar fascia, and perhaps even the abductor of the great toe; in fact, anything requisite for the restoration of the foot. Care should be taken not to cut tendons in their synovial sheaths, as this prevents union, but if severed beyond their sheaths union will take place. The division may be performed by the open or subcutaneous methods. In adults it is sometimes necessary to remove a wedge of bone from the top and medial side of the instep, or the astragalus (*talus*) may be excised.

In **talipes, or pes, valgus** the lateral edge of the foot is drawn off the ground and the patient walks upon the depressed medial pillar of the medial arch. It is rare.

In **talipes, or pes, calcaneus** the patient walks upon the heel, the ball of the foot being held off the ground in the position of dorsal flexion. It may be due to contraction of the extensor muscles, the tendons of which should then be divided, or to rupture of the calf muscles, in which event the relaxed muscle is sutured or a portion of the tendo Achillis (*tendo calcaneus*) excised and the severed ends spliced.

In **talipes, or pes, equinus** the patient walks upon the ball of the foot, the heel being held off the ground in the position of plantar flexion. The tension in the long digital extensors draws the toes backward upon the foot, while the long digital flexors hold down the distal phalanx. Sometimes the toes are partially dislocated upon the dorsum of the metatarsus, but they can generally be replaced by forcible flexion of the foot.

Talipes, or pes, cavus consists in an exaggerated curve of the foot due to contracture of the plantar fascia, similar to that of the palm producing Dupuytren's contracture. It is very frequently associated with talipes calcaneus, and is then treated, surgically, by section of the tendo Achillis (*tendo calcaneus*) and the plantar fascia.

The **Toes** (with the exception of the great toe), within a pair of shoes, are substantially rudimentary organs. To a certain extent they exert leverage in walking by adding a final propulsive effort to that which sends the body forward, this being done by the digital flexors. They also serve to enlarge the area of the anterior base of the great longitudinal arch of the foot. In walking bare-footed

they adapt the foot to surface inequalities. They are most diminutive in the highest types of human beings, and are longer in all lower forms.

Hammer-toe usually affects the second or third toes; it consists in permanent hyperextension at the metatarso-phalangeal joint, and permanent flexion of the two phalangeal joints, so that the end of the toe bears on the ground. It is sometimes successfully treated by mechanical restraint, or by tenotomy of the tendons and contracted fascia. It is not good practice to amputate the second toe since severe hallux valgus may result.

Hallux valgus is a prominence and hypertrophy of the medial side of the base of the great toe due to forcible pressure from tight shoes, displacing the great toe toward the other toes (*abduction*), under or over which it then generally lies. In the normal foot the line of the great toe, when carried backward, should pass through the center of the heel (Meyer's line). In its early stages it is successfully treated by wearing wide-toed shoes with soles having a straight inner edge, and by placing a pad between the great and the second toes; but when advanced, the bones must be exposed, and a wedge with its base medialward removed from the head of the first metatarsal so as to allow proper reposition of the toe. If of long standing, a subcutaneous bursa forms, which becomes a *bunion*, if inflamed.

Operations for Talipes.—Talipes valgus may often be corrected by subcutaneous division of the tendons causing it. Among these are the peroneus tertius, the tendo Achillis (*tendo calcaneus*), the extensor digitorum longus, and at times, the tibialis anterior and extensor hallucis longus tendons. In dividing the tendons of the peroneus tertius and extensor digitorum longus, the tenotome should be introduced to the medial side of the latter, the tendons being divided from within lateralward. The other tendons requiring division may be divided through the same incision, with the exception of the tendo Achillis (*tendo calcaneus*).

In **talipes varus** the tendons requiring division include the tendo Achillis (*tendo calcaneus*), and those of the tibialis anterior, the tibialis posterior, the flexor digitorum longus, and the plantar fascia. The tendo Achillis (*tendo calcaneus*) may be divided by introducing the tenotome along the side of the tendon, on a level with its anterior margin, and cutting from within lateralward. In dividing the tendon of the tibialis posterior, the sharp-pointed tenotome should be introduced at a point immediately above the medial malleolus, and carried medialward in close relation with the posterior surface of the tibia, until the fascia in relation with the tendon has been opened. The tenotome should be withdrawn and the blunt-pointed one introduced in the same wound until it comes into the space between the tibia and the tendon. Its cutting edge is then turned against the tendon and the latter divided with a slight sawing motion.

In some cases of talipes varus simple tenotomy of the tendons will not suffice to allow the foot to be placed in its normal position. In such cases a resection of the tarsus is advisable. Some surgeons advocate the removal of the cuboid bone, but better results can be obtained by removing the astragalus (*talus*) or a triangular piece from the tarsus. In performing this operation, an incision should be made along the anterior border of the foot, beginning at the middle of the calcaneus, and carried forward to a point about two and a half centimeters (one inch) anterior to the tuberosity of the metatarsal bone of the little toe. A second incision should then be carried from the middle of the first incision to the lateral side of the tendon of the extensor digitorum longus, at right angles to the first cut. The skin and superficial fascia, with twigs to the internal saphenous (*saphenous*) nerve, and a few cutaneous vessels will be divided. The tarsus will be exposed by reflecting the flaps. The tendons should be lifted up, and a triangular piece of the tarsus removed with a metacarpal saw or, preferably, with an osteotome or chisel and mallet. No attention need be paid to the lines of articulation between the several bones, but care must be taken to avoid wounding the soft structures of the sole of the foot.

In the combinations of these forms of talipes the offending tendons should be divided.

In **talipes calcaneus** it will often be necessary to divide the tendons of the tibialis anterior, the extensor hallucis longus, the extensor digitorum longus, and the peroneus tertius. All these tendons can be divided through a single puncture. The tenotome should be introduced to the medial side of the tendon of the extensor digitorum longus, in the front of the ankle. The instrument should be carried medialward and the tendons of the extensor hallucis longus and tibialis anterior divided; the tenotome should then be withdrawn and reintroduced, and carried in a lateral direction, when the tendons of the peroneus tertius and extensor digitorum longus can be divided.

In passing the tenotome care must be taken to avoid wounding the anterior tibial artery which lies between the tendon of the tibialis anterior and that of the extensor longus digitorum.

In **talipes equinus** usually the division of the tendo Achillis (*tendo calcaneus*) suffices to correct the deformity.

DISLOCATIONS

The subject of luxations in general has been considered with the description of dislocations of the upper extremity.

Dislocations at the hip-joint are not so frequent as at the shoulder-joint because of the greater depth of the acetabular cavity, its reinforcement by the

cotyloid (*glenoid*) fibro-cartilage, of the surrounding muscular attachments, and more especially because of the reinforcements of the capsule by the ischio-, ilio-, and pubo-femoral (*pubo-capsular*) ligaments.

A line drawn from the anterior superior iliac spine to the tuber ischii will bisect the acetabulum and divide each side of the pelvis into two planes, the pubo-ischiatic, the medial, or anterior, plane, and the ilio-ischiatic, the lateral, or posterior, plane. When the head escapes from its socket it may rest on the dividing line and then by muscle pull or the injuring force it assumes an anterior or posterior position.

The **femur** is liable to dislocation in one of four directions: upward and backward onto the dorsum ilii, upward and backward into the greater sciatic notch, downward and forward into the obturator foramen, and upward and forward onto the pubis.

In *dislocation onto the dorsum ilii* ("above the obturator tendon"), the head rests upon the ilium just above and behind the acetabulum. The capsule is lacerated, especially in the lower and posterior part, and the round ligament is almost always completely ruptured. The small lateral rotators of the thigh are put on the stretch, and the tendon of the obturator externus is markedly stretched across the posterior part of the neck of the bone, while the obturator internus is frequently torn. The gluteus maximus, medius, and minimus are generally relaxed and pushed upward. The ilio-femoral, or Y, ligament is rarely, if ever, torn. At times the great sciatic (*sciatic*) nerve may become injured by being carried around the neck in a loop. If this occurs, the head can be replaced but there remains a residual flexion of the thigh on the abdomen unless the nerve is replaced. After the dislocation has been of some standing, the glutei muscles will contract, and thus render the reduction of the luxation much more difficult. The greater trochanter is made very prominent. The thigh is rotated medialward, flexed and adducted, more by the false position of the head than by the action of the muscle. The knee is drawn toward the opposite knee, crossing the distal third of the opposite thigh, and the ball of the great toe rests upon the opposite instep. The limb is shortened from five to eight centimeters (two to three inches).

In an *ischiatic, or sciatic, disoclation* ("below the obturator tendon"), the head of the femur is forced through the posterior part of the capsule in a backward direction until it comes in contact with the strong tendon of the obturator internus muscle, which reflects the head into the sciatic notch. There is always extensive laceration of the posterior part of the capsule, and complete separation of the ligamentum teres. The gluteus maximus is often badly torn, and sometimes the head of the bone is found embedded in that muscle. The gluteus minimus, the

gemellus superior, and the pyriformis are generally more or less torn. The head is often found resting upon the gemelli muscles, and either upon, or close to the great sciatic (*sciatic*) nerve. At times the obturator externus is torn. The axis of the femur crosses the opposite knee and the great toe rests upon the dorsum of the opposite great toe.

In *luxation into the obturator foramen* the head of the bone is forced through the lower medial side of the capsule, which is extensively lacerated. The ligamentum teres is separated from the bone. The head of the femur rests upon the obturator externus muscle, over the obturator foramen. The greater trochanter is obscured, and the ilio-tibial tract is made tense. The adductor muscles are frequently lacerated. The leg is apparently lengthened and the toes point forward and lateralward. Flexion, abduction, and lateral rotation are well marked. Frequently pain is referred along the distribution of the obturator nerve.

In the *luxation onto the os pubis* the capsular ligament is extensively lacerated and the ligamentum teres completely separated from the bone. At times the head of the bone will force its way under Poupart's (*inguinal*) ligament and rest upon the iliacus and psoas muscles, with the anterior crural (*femoral*) nerve lying over the neck of the bone. Generally the head rests upon the pubis below Poupart's (*inguinal*) ligament. The trochanter disappears and at times occupies the acetabulum. The leg is apparently shortened. The foot is everted by the action of the iliacus and psoas magnus (*psoas major*) muscles, and the lateral band of the Y ligament. Abduction is pronounced.

The **patella** may be dislocated lateralward, medialward, or upon its vertical axis. These dislocations, however, are rare.

In the *lateral dislocation* the patella is found riding over the lateral condyle, unless the luxation is complete, when the patella will be found on the lateral aspect of the knee-joint. The ligamentum patellæ will be tense, and may at times be lacerated. The quadriceps extensor (*quadriceps femoris*) muscle will be tense. The articular surface of the medial condyle can be plainly felt. The internal lateral (*tibial collateral*) ligaments and many of the fibers of the tendinous expansions will be torn. This type is the one most frequently observed.

In the *medial luxation* the anatomical conditions are the same as those in the lateral variety, but reversed.

In both varieties there is inability to flex the knee, as the quadriceps is unable to act on account of the anomalous position of the patella.

In a *luxation in which the patella is rotated on its axis*, there is tightening of the quadriceps extensor (*quadriceps femoris*) muscle and the ligamentum patellæ, with stretching or laceration of the lateral (*collateral*) ligaments.

Dislocation of the knee may be forward, backward, medialward, lateralward, or by rotation, the tibia in each case taking the direction indicated. These dislocations are also rare. The condition is frequently confused with epiphyseal separation of the distal end of the femur, the epiphysis being carried anteriorly.

In *backward luxation of the head of the tibia* there is a marked depression immediately below and to either side of the patella. The head of the tibia is felt in the popliteal space. In a complete luxation, there is marked pain, owing to the pressure upon the popliteal nerves. The femoral condyles can be felt projecting forward. The posterior cruciate ligament of the joint is lacerated and the semimembranosus, the semitendinosus, and the biceps femoris muscles are stretched. There is pressure upon the popliteal vessels and nerves which are sometimes torn; gangrene from pressure has been observed. If the dislocation is complete, the cruciate ligaments are torn. The gastrocnemius, popliteus, and plantaris muscles are stretched and may be lacerated. All the parts connected with the joint suffer from laceration, stretching, or pressure.

In *forward luxation of the head of the tibia*, the patella, the head of the tibia, and the fibula can be plainly felt in front, while the condyles of the femur project behind. The gastrocnemius, popliteus, and plantaris muscles are greatly stretched, and the vessels and nerves of the popliteal space pressed against the condyles. Pressure upon the popliteal artery may be such that the resulting interruption of the blood flow in the branches below may lead to gangrene of the parts supplied. The capsule is often lacerated, and the cruciate and lateral (*collateral*) ligaments are either torn or put on the stretch.

Lateral luxations are generally incomplete on account of the great width of the joint surfaces and the strong lateral (*collateral*) ligaments. In a *medial dislocation* the head of the tibia can be felt on the medial side of the condyle of the femur. In the partial variety the medial condyle rests on the lateral articulating surface of the tibia. The lateral (*collateral*) ligaments are either greatly stretched or torn, and the cruciate ligaments generally torn. The tendons of the hamstring muscles are pulled to one side, and the contents of the popliteal space may be pulled out of place. In the lateral variety the anatomic signs are practically the same as those of the medial variety, reversed.

Dislocation of the Fibula.—The proximal end of the fibula may be dislocated forward or backward. These are rare. Only about twenty-five cases have been reported.

In *forward dislocation* the head of the fibula is carried forward and presents in front near the ligamentum patellæ. The posterior superior tibio-fibular ligament is greatly stretched, and the anterior generally lacerated. The direction

of the tendon of the biceps femoris muscle is altered, and sometimes there is a considerable deformity in the shape and position of the leg.

In *backward dislocation* the head of the fibula is carried backward, and presents beneath the skin on the lateral side of the popliteal space. The tendon of the biceps femoris is very evident. The anterior and superior tibio-fibular ligaments are stretched or partially lacerated. The external popliteal (*common peroneal*) nerve may also be injured.

Dislocations of the foot or ankle may be backward, forward, medialward, or lateralward. These dislocations are sometimes classed as luxations of the bones of the leg. In the descriptions, where the tibia is taken as the bone luxated, the direction of the dislocation is opposite to that here described. Both complete and incomplete dislocations of the ankle joint are frequently associated with fracture of the bones around the joint; in fact, some authors believe that it is impossible to obtain an uncomplicated dislocation.

In *backward dislocation* the foot is carried backward, the tibia resting on the scaphoid (*navicular*) bone when the luxation is complete, and on the neck or head of the astragalus (*talus*) when it is incomplete. The posterior tibio-tarsal ligament is greatly stretched or torn, and the anterior and lateral (*collateral*) ligaments are lacerated. There is generally a fracture of the distal part of the fibula and a separation of the inferior tibio-fibular ligament. This deformity is frequently seen in the Dupuytren fracture of the tibia. The tendo Achillis (*tendo calcaneus*) stands out prominently, being carried backward with the foot. The foot itself goes into extreme plantar flexion. The heel is lengthened and the foot shortened; the calcaneus is made very prominent. The tendons, nerves, and vessels passing behind the malleoli may be thrown out of place and severely injured.

In *forward dislocation* the astragalus (*talus*) presents in front of the distal end of the tibia, the latter resting on the os calcis (*calcaneus*). The tendo Achillis (*tendo calcaneus*) loses its prominence. This luxation may be complicated by fracture of one or both malleoli. The anterior and lateral (*collateral*) ligaments are ruptured and the posterior ligament is greatly stretched or torn; the foot is lengthened.

In *lateral dislocation* of the foot the external lateral ligament is ruptured and the lateral malleolus is broken, or there may be a break in the fibula (Pott's fracture). At times the medial malleolus is also broken. The anterior and posterior ligaments are stretched or torn. Owing to the subcutaneous position of the malleoli, this dislocation is generally compound.

In *medial luxation* the anatomic signs are the same as those of the lateral variety, reversed. This luxation is frequently compound.

Dislocations of the astragalus (**talus**) may be forward, backward, medialward or by rotation and combinations of the above may occur.

In *forward luxation* the astragalus (*talus*) is disjoined from the calcaneus and moves forward in front of the scaphoid (*navicular*) and rests on the internal (*first*) cuneiform bone. The anterior and posterior tibio-tarsal ligaments are stretched or torn, and the lateral, medial, and posterior calcaneo-astragaloid (*talo-calcaneal*) ligaments are ruptured or stretched. The interosseous ligament between the calcaneus and the astragalus (*talus*) is also torn. When associated with lateral rotation the foot is rotated medialward and assumes a club-foot position.

In *backward dislocation* the astragalus (*talus*) escapes posteriorly from the intermalleolar space and from the os calcis (*calcaneus*) and scaphoid (*navicular*). It rests on the posterior part of the os calcis (*calcaneus*), generally between the tibia and the tendo Achillis (*tendo calcaneus*). The ligaments stretched or ruptured are the same as those affected in forward luxation.

In *lateral dislocation* the astragalus (*talus*) escapes to the side of the ankle, its escape being allowed by fracture of the malleolus of that side. The same ligaments are stretched or ruptured as in the anteroposterior varieties.

The *incomplete congenital luxation* of the astragalus (*talus*), met with in certain forms of club-foot has been considered under the description of that condition.

"**Subastragaloid dislocation**" (**talo-calcaneal dislocation**) is a term applied by Malgaine to a separation of the os calcis (*calcaneus*) and scaphoid (*navicular*) bones from the astragalus (*talus*), the latter remaining in its normal position in the mortise between the two malleoli. Another form, termed the total dislocation of the astragalus (*talus*), is one in which the astragalus (*talus*) is completely separated from its articulation with the bones of the leg as well as from the os calcis (*calcaneus*) and scaphoid (*naviculat*). The luxation may be forward, backward, or lateralward.

In *forward dislocation* the astragalus (*talus*) tests on the facets of the os calcis (*calcaneus*); in *backward luxation*, upon the scaphoid (*navicular*) or cuboid bones; in the *lateral dislocation*, upon the cuboid bone, in the *medial*, upon the tuberosity of the scaphoid (*navicular*). In all of them the tibio-tarsal ligaments remain intact, but the lateral, medial, and posterior calcaneo-astragaloid (*talo-calcaneal*) ligaments, the interosseous, and the superior astragalo-scaphoid (*talo-navicular*) ligaments are torn. In the lateral variety the tendons of the tibialis anterior and the tibialis posterior are streteched, the former over the neck of the astragalus (*talus*), and the latter against the groove of the tibia.

The **os calcis** (**calcaneus**) may be dislocated *lateralward* from the astragalus (*talus*), or *lateralward and upward* from the astragalus (*talus*) and the cuboid.

PLATE CCCXXVI.

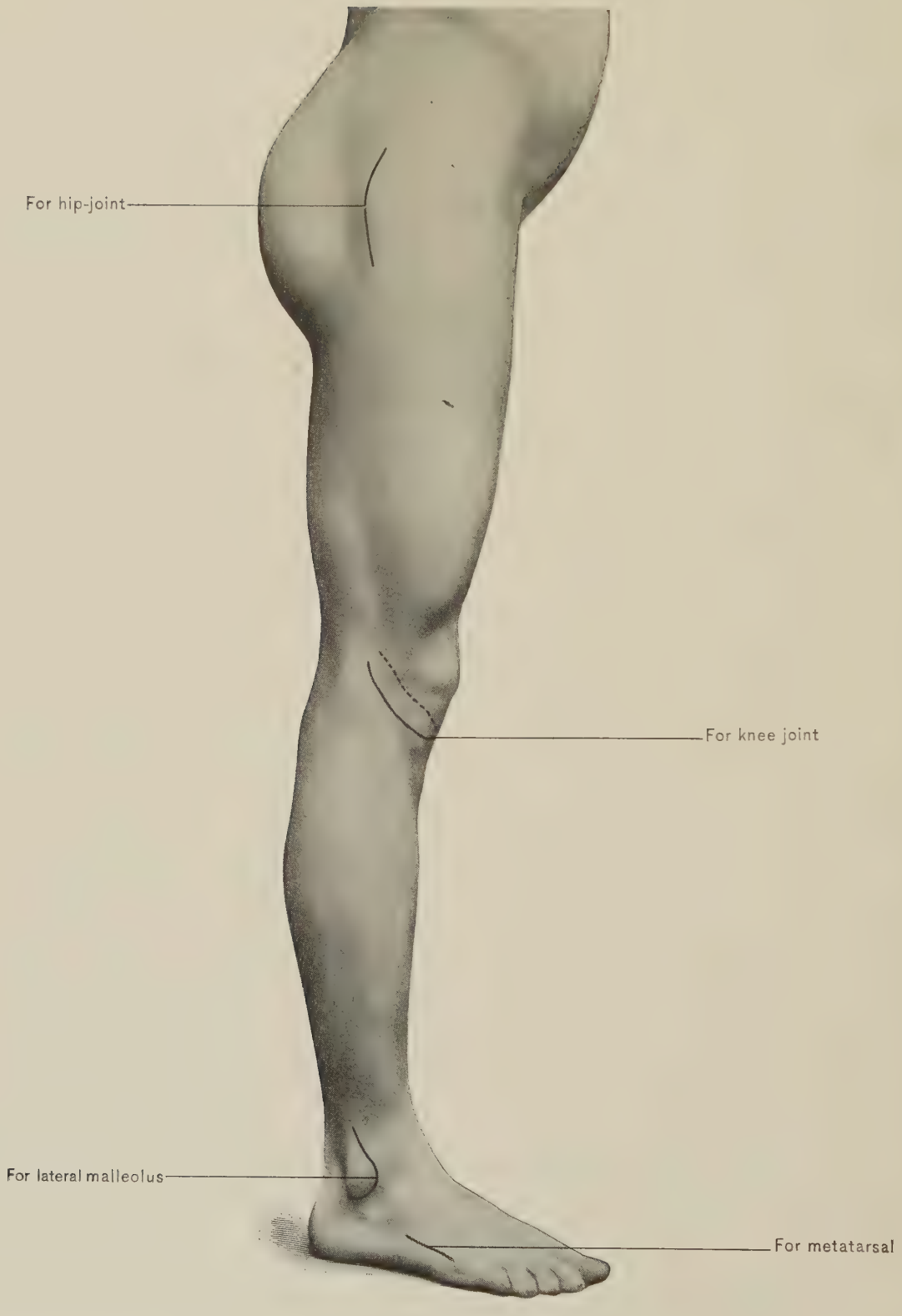

LINES OF EXCISIONS.

In the former variety the lateral and posterior calcaneo-astragaloid (*talo-calcaneal*) ligaments are stretched and the medial calcaneo-astragaloid (*talo-calcaneal*) and the interosseous are either greatly stretched or torn. The tendo Achillis (*tendo-calcaneus*) is carried lateralward with the bone to which it is attached. If the connection with the cuboid is also severed, the superior, inferior, long (*long plantar*), and short calcaneo-cuboid (*plantar calcaneo-cuboid*) ligaments will be either stretched or torn, in addition to those above enumerated.

Dislocations of the remaining bones of the tarsus are very rare, and when they do occur are generally associated with a fracture of some of the adjoining bones. There is a laceration of all the various ligaments connecting the bones, and marked deformity, depending upon the extent of the injury and the bones displaced.

Dislocation of the metatarsal bones may occur either singly or of the entire number. The dislocation occurs at Lisfranc's joint. The dorsal plantar and the interosseous ligaments are either stretched or torn, and the tendons and vessels lying over or under the joints may be seriously injured. It occurs most often in the forward (upward) direction. The foot is shortened and the toes point medialward.

Dislocations of the phalanges of the toes may occur, although they are comparatively rare. These take place in a forward and backward direction.

A *dislocation of the proximal phalanx* of the great toe is always difficult to reduce, although there is no definite reason for this trouble. In these dislocations the plantar and the two lateral (*collateral*) ligaments are either stretched or torn.

EXCISIONS OF THE LOWER EXTREMITY

The subject of excisions in general has been discussed with the description of the excisions of the upper extremity.

Excision of the Hip-joint (Plate CCCXXVI).—In excising the hip the patient should lie on the sound side, with the thigh of the affected limb flexed. A slightly curved incision is made, beginning about four centimeters (one and a half inches) above the greater trochanter, and, after skirting the posterior border of the base of this process, ending about five centimeters (two inches) below it. The incision should be made freely and should reach to the bone. The skin and superficial fascia will be divided, together with branches of the first and second lumbar, the lateral branch of the twelfth dorsal, and the iliac branch of the ilio-hypogastric nerves; small branches from the external (*lateral*) cutaneous nerve and from the lesser sciatic (*posterior cutaneous nerve of thigh*); branches of the gluteal (*superior gluteal*) and sciatic (*inferior gluteal*) arteries

and their veins; the deep fascia, the three gluteal muscles nearly in the line of their fibers, muscular and articular branches of the gluteal (*superior gluteal*) and sciatic (*inferior gluteal*) arteries, the capsule of the joint, and the periosteum. If the greater trochanter has to be removed, the muscles attached to it, the gluteus medius and minimus, the pyriformis, the gemellus superior and inferior, the obturator externus and internus, and part of the quadratus femoris, must be divided and the periosteum separated from the bone. The capsule is freely opened and the head of the bone brought into the wound by dividing the ligamentum teres and then carrying the thigh well forward. As much of the bone as is to be removed should be cleared of its periosteum, and removed with a saw.

Excision of the Knee-joint (Plate CCCXXVII).—In excising the knee-joint the incision should be made transversely across the front of the knee-joint, with the leg flexed. The incision starts at the posterior edge of the base of the condyle and is carried directly across the front of the joint to a similar point on the opposite condyle. The first cut should divide all the structures down to the joint. The structures divided will be: the skin and superficial fascia, twigs of the internal (*medial*) cutaneous and of the cutaneous branch of the popliteal nerves, and small arteries with their veins, the ligamentum patellæ, and the capsule of the joint. The skin and superficial fascia with the ligamentum patellæ and the patella should be dissected upward as far as necesssary and all the structures divided down to the bone in the line of the proposed section. The cruciate and the internal and external lateral (*tibial and fibular collateral*) ligaments should be divided and the diseased parts removed with a saw. On account of the obliquity of the femur, and because the epiphyseal line is somewhat higher on the anterior than the posterior surface of the bone, the "section of the condyles should be in a plane which, as regards the axis of the femur, is oblique from behind forward, from below upward, and from within outward." The tibia should be divided in a plane at right angles to the shaft of the bone. In making the section of the femur and tibia it is advisable to saw from behind forward, and thus avoid the possibility of injuring the popliteal vessels, especially the artery, which are separated from the posterior surface of the joint by the posterior (*oblique popliteal*) ligament. With the leg extended, the popliteal artery lies against the posterior (*oblique popliteal*) ligament of the joint; but with the leg flexed, the artery is carried away from the ligament. The patella is to be removed, as a rule, whether diseased or not. This will necessitate division of the tendo patellæ, formed by the union of the four muscles forming the quadriceps extensor (*quadriceps femoris*) namely, the vastus externus (*lateralis*), the vastus internus (*medialis*), the rectus femoris, and the crureus (*vastus intermedius*). If the parts are much diseased, there will be considerable bleeding on account of the anom-

PLATE CCCXXVII.

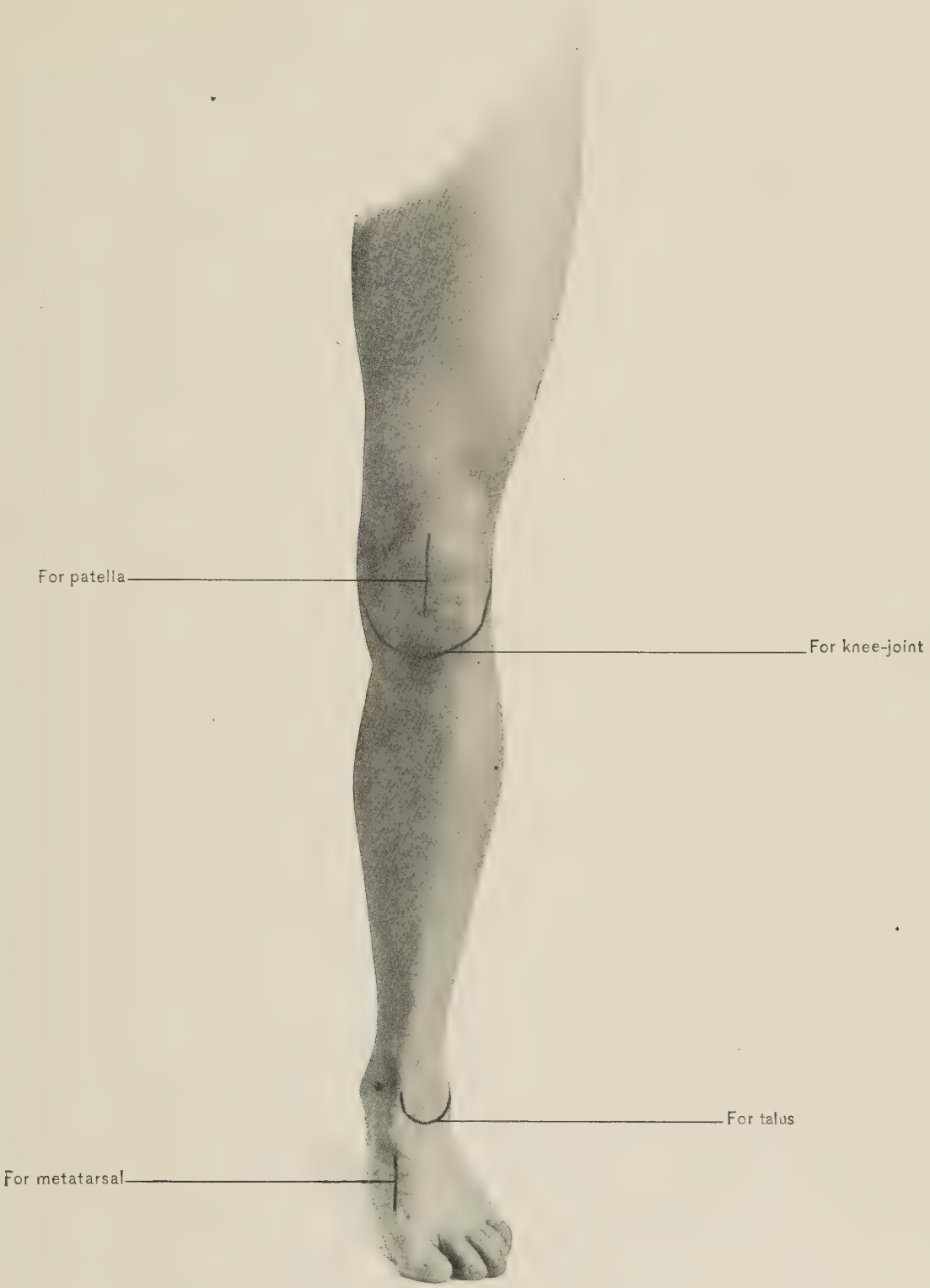

LINES OF EXCISIONS.

PLATE CCCXXVIII.

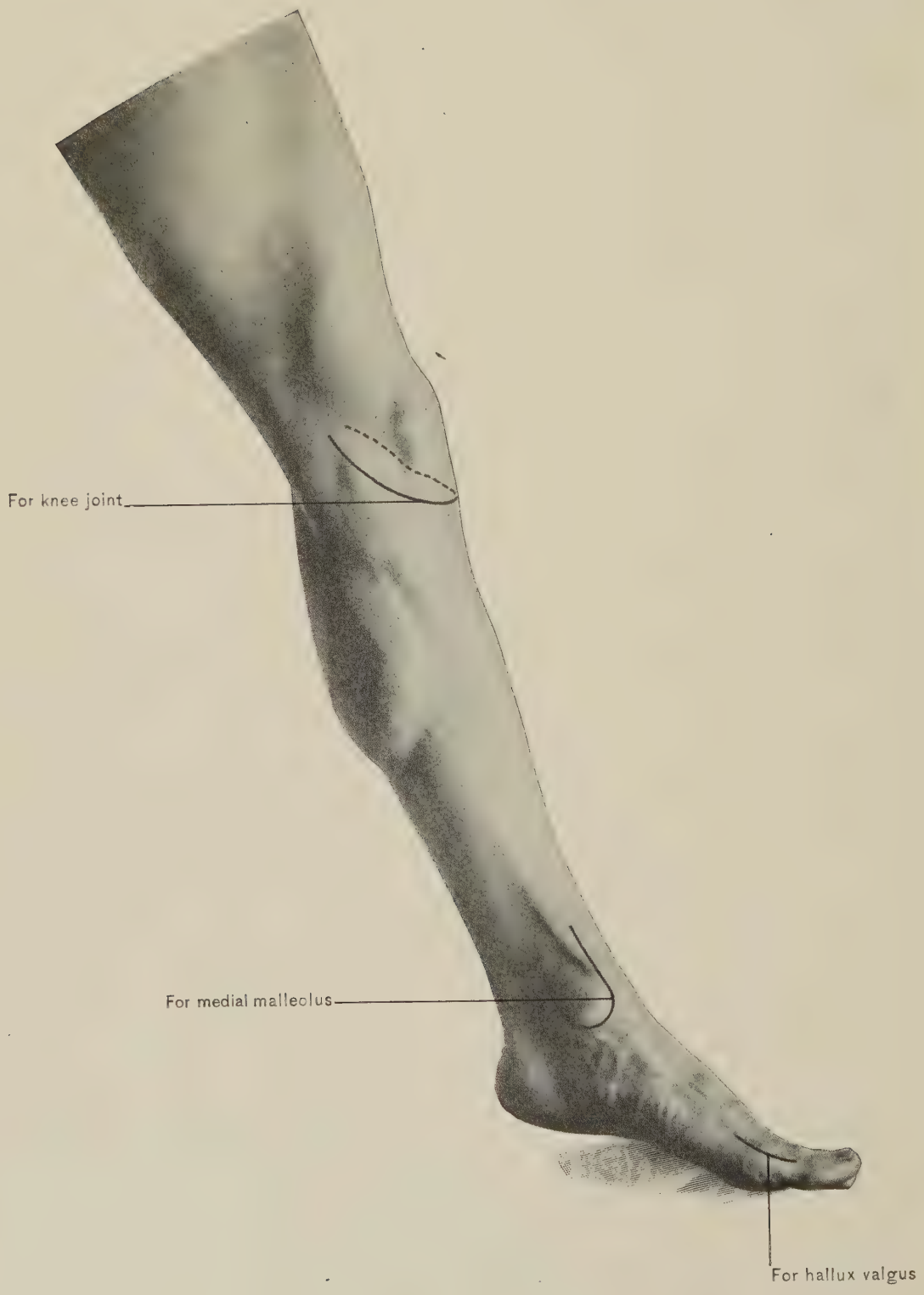

LINES OF EXCISIONS.

alous condition of the arterial supply to the joint. The vessels usually requiring ligation are branches of the four articular (*genicular*) arteries and of the tibial recurrent. When the disease extends into the bursa beneath the quadriceps extensor (*quadriceps femoris*) muscle, the dissection should be carried upward far enough to remove the entire bursa.

The **patella** may require excision on account of injury or disease. A longitudinal incision is made directly over the bone. The skin and superficial fascia are divided, with twigs of the internal (*medial*) cutaneous and of the cutaneous branch of the popliteal nerves, small arteries and their veins. The patella is exposed and its fibrous covering divided in the line of the original incision. The bone or its fragments are removed, with as little of the soft parts as possible.

Excision of the Ankle-joint.—(Plate CCXXVIII.) In excising the ankle-joint by the subperiosteal method, two incisions should be employed, one over each malleolus. The lateral incision is made along the anterior edge of the fibula to the tip of the lateral malleolus, then curving backward around the process. The medial incision is similarly made with regard to the tibia. The skin and superficial fascia will be divided, with twigs of the internal saphenous (*saphenous*) nerve on the medial aspect and of the external, or short, saphenous (*sural*) and musculo-cutaneous (*superficial peroneal*) on the lateral aspect of the leg. Small branches of the anterior and posterior tibial arteries with their veins will also be severed. The periosteum of the fibula should then be divided longitudinally and stripped from the bone in anterior and posterior flaps. Division of the external lateral ligament will be required, and this should be performed in a vertical direction, in order to preserve its usefulness as much as possible. The lateral malleolus should then be removed, either with the chisel or the saw. The periosteum over the medial malleolus, the internal lateral (*deltoid*) ligament, and the medial malleolus should then be similarly treated. The astragaloid (*taloid*) ligaments are divided with a blunt-pointed knife, and as much of the astragalus (*talus*) removed as is thought necessary. Usually the entire bone is taken out.

Excision of the Astragalus (Talus).—In excising the astragals (*talus*) a semilunar incision is made on the anterior and lateral aspect of the joint. The skin and superficial fascia are divided, with twigs of the external saphenous (*sural*) and musculo-cutaneous (*superficial peroneal*) nerves, and small branches of the posterior tibial or plantar arteries. The external lateral ligament is divided and as much of the bone removed as required.

Excision of the Os Calcis (Calcaneus).—In excising the calcaneus or a portion of it, an incision may be made by one of several methods. Holmes recommends an incision beginning at the medial edge of the tendo Achillis (*tendo*

calcaneus), and carried through the tendo Achillis (*tendo calcaneus*) and around the lateral aspect of the foot on a level with the upper border of the bone to a point midway between the heel and the base of the fifth metatarsal bone. A second incision is then carried from the anterior end of the first incision, and at right angles to it, downward and across the plantar surface of the heel to the medial grooved surface of the os calcis (*calcaneus*). The flap is dissected from the bone, carrying with it the divided tendons of the peroneal muscles. The ligaments between the os calcis (*calcaneus*), and the cuboid are then divided and the os calcis (*calaneous*) tilted medialward, when the calcaneo-astragaloid (*talo-calcaneal*) ligaments are to be divided. The bone is then to be twisted lateralward and the soft parts separated from its medial surface, thus freeing the bone.

Excision of a metatarsal bone may be either complete or partial. A longitudinal incision is made over its dorsal surface through the skin and fasciæ, and the tendons displaced to one side. The periosteum is incised and separated from the bone together with the interossei muscles. The bone is then freed and removed. Care should be taken not to injure the plantar vessels and nerves.

The **metatarso-phalangeal joint of the great toe** sometimes requires excision for caries of the articular surfaces of the bones forming the joint. This is usually the result of suppuration of the synovial sac in case of "bunion." The incision should be made along the medial side of the joint.

In **excision of the phalanges** it is to be remembered that the middle phal- of the toes should never be excised, as that would leave useless toes. The base of the proximal phalanx of the great toe and the terminal phalanges of the toes may be removed. The incision for excision of the terminal phalanax of the toe may be made on the plantar surface or from side to side around the end of the toe. It is best to leave the base of the phalanx behind, if possible, on account of the insertion of the extensor tendons.

DEVELOPMENT OF THE BONES OF THE LOWER EXTREMITY

The **femur** is developed by three primary and two secondary centers of ossification. Of the primary centers the one for the shaft appears not later than the seventh week of fetal life. The shaft and neck of the femur are developed from this center. The center for the distal epiphysis appears at about the ninth month of fetal life; it is the only epiphysis in the body in which ossification begins before birth. Because of this, it has been used as a guide to the age of the fetus or infant. However, the exact time of its appearance as well as its size is entirely too variable for dependence. The condyles and tuberosities are developed from this center. The center for the head appears toward the end of the

first year. The secondary centers are for the two trochanters, the center for the greater trochanter appearing at about the fourth year, and the one for the lesser during the fourteenth year. The union of these several centers takes place in the order opposite to that of their formation. Thus, the lesser trochanter, which is the last center to show signs of ossification, is the first to join the shaft, at about the seventeenth year. This is followed by the greater trochanter and the proximal epiphysis during the eighteenth year, and the distal epiphysis during the twentieth year.

The **patella** is developed from a single center of ossification which appears at about the third year; ossification is not completed until the age of fourteen or fifteen. The cartilaginous origin of the patella is found at about the third fetal month.

The **tibia** is ossified from three centers, one for the shaft and one for each end. The center for the shaft appears in the seventh or eighth fetal week, the center for the proximal epiphysis usually appears during the last fetal month, the union to the shaft occurring at about the twentieth year. The center for the distal epiphysis appears during the second year and joins the shaft during the eighteenth year.

The **fibula** has three centers of ossification, one for the shaft and one for each end. The center for the shaft appears during the eighth week, a little later than that for the shaft of the tibia. The center for the distal end appears about the second year, before that of the proximal epiphysis. This is contrary to the general rule, that the epiphysis toward which the nutrient artery is directed is the first to ossify. It joins the shaft about the twenty-first year. The center for the proximal extremity of the bone appears during the third or fourth year, and joins the shaft at about the twenty-fourth year.

The **tarsal bones** have one center of ossification each, with the exception of the os calcis (*calcaneus*), which always has two, and the astragalus (*talus*), which may at times have two. The first center of the os calcis (*calcaneus*) appears at about the sixth month of fetal life; the second center appears about the tenth year and coalesces with the first toward the fourteenth year. The center for the astragalus (*talus*) appears at the seventh month, that of the cuboid near the ninth month, that of the lateral (*third*) cuneiform about the first year after birth, that of the middle (*second*) and medial (*first*) cuneiform and the scaphoid (*navicular*) in the third or fourth year.

The **second, third, fourth, and fifth metatarsal bones** have two centers of ossification, one for the shaft, which appears during the eighth or ninth week, and one for the head, which appears from the third to the eighth year. The epiphysis joins the shaft at about the nineteenth year.

The **first metatarsal bone** also has two centers of ossification, but the epiphysis in this case is at the proximal extremity. At times there are two epiphyses formed, one at each end. The centers in this bone appear at about the same time as do those of the other four metatarsals.

Each of the **phalanges** has two centers of ossification, one for the shaft and distal end, the other for the proximal end. They unite at about the twentieth year.

FRACTURES

Fractures of the femur occur at the neck, throughout the shaft, and in connection with the condyles. Fractures through the neck are divided into intracapsular and extracapsular; fractures through the shaft, are divided into those of the proximal, intermediate, and distal third; fractures of the condyles, into those affecting one or both condyles, fractures between the condyles, or above the base of the condyles, supracondylar fractures.

Intracapsular fractures are those which occur entirely within the capsule. Clinically, they are hard to diagnose on account of the fact that the capsule is attached at different distances from the head of the bone, thus making it probable that part of the fracture is within, and part of it without the capsular ligament. In this type of fracture the lower extremity is shortened about two and a half centimeters (one inch) at the time of fracture; the shortening, however, is increased after partial absorption of the neck (consecutive shortening) has occurred. Sometimes the ends of the fragments are in apposition; in such cases the shortening, if any, is very slight and may not appear for several weeks. It is caused by the action of the glutei, the semimembranosus, the semitendinosus, the tensor fasciæ femoris (*tensor fasciæ latæ*), the rectus, the sartorius, the ilio-psoas, the adductor, the gracilis, and the pectineus muscles. This shortening of the limb brings the greater trochanter nearer the crest of the ilium, and thus also reduces the base of Bryant's triangle, and throws the three points in Nélaton's line out of alignment, the greater trochanter being above the other two points. (This triangle and line are described under the surface anatomy of the lower extremity.) The action of the ilio-psoas, the lateral rotators, the pectineus, and the adductor muscles tends to roll the limb lateralward. Owing to the displacement of the greater trochanter, flattening of the normal site of this process takes place. The tensor fasciæ femoris (*tensor fasciæ latæ*), the ilio-tibial band, and the gluteus medius muscles are generally relaxed. As a rule, none of the ligaments of the hip-joint will be torn, although some of them may be slightly stretched.

Extracapsular fractures of the femur present about the same anatomic signs as the intracapsular variety. The same muscles act on the two fragments, and

PLATE CCCXXIX.

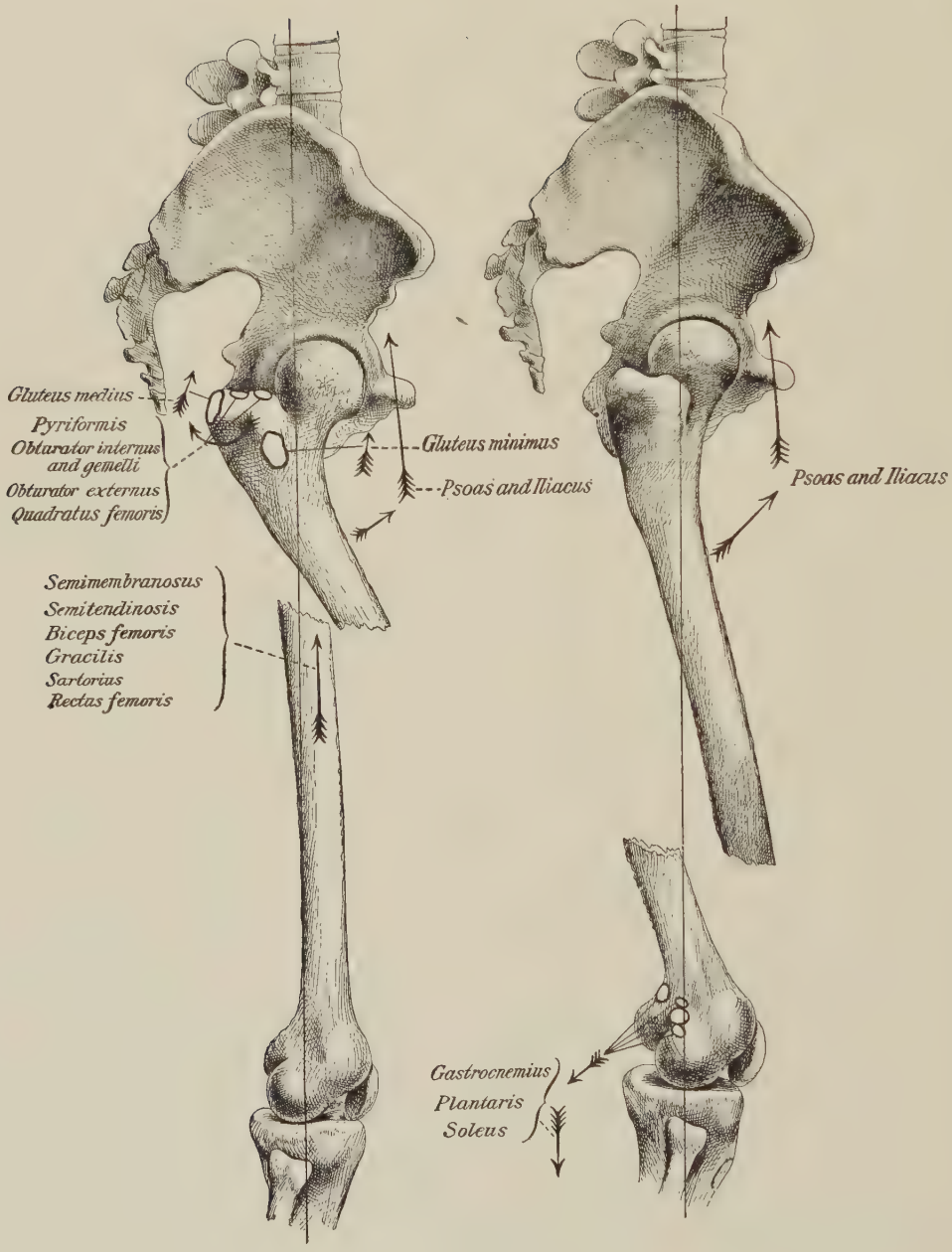

FRACTURES OF THE SHAFT OF THE FEMUR.

the same changes in the base of Bryant's triangle and in Nélaton's line are noticed. If the fracture extends through the capsule, thus making the break a combination of the two varieties, there may be some laceration of the capsular ligament (*articular capsule*) and of some of the accessory ligaments of the capsule.

The **greater trochanter** may be severed from its connection to the shaft of the femur, generally by direct action. In this fracture the process lies above Nélaton's line, and the base of Bryant's triangle is shortened. The process is drawn upward and backward by the action of the lateral rotators which are attached to it.

Fractures of the shaft (Plate CCCXXIX) may be divided into those of the proximal, intermediate, and distal thirds. The highest fracture is that of the bone just below the lesser trochanter. The proximal fragment is abducted and tilted upwards by the psoas and iliacus which are inserted into the process, and abducted by the lateral rotators. The distal fragment is acted upon by the extensor muscle, the quadriceps extensor (*quadriceps femoris*), which draws it upward and abducts it.

In fractures of the shaft of the femur the distal fragment is generally drawn upward, within or posterior to the proximal fragment, which is carried anteriorly and abducted. The distal fragment is carried upward by the action of the semimembranosus, the semitendinosus, the gracilis, the rectus femoris, the sartorius, the tensor fasciæ femoris (*tensor fasciæ latæ*), the adductor longus, the adductor magnus, and the vastus externus (*vastus lateralis*). The proximal fragment is carried forward by the action of the psoas and iliacus muscles, and adducted by the lateral rotators of the thigh. The angle of deformity is generally marked. The limb is shortened from two and a half to seven and a half centimeters (one to three inches), depending upon the obliquity of the fracture. In fractures of the distal third the superficial femoral artery or vein may be injured, on account of the close proximity of these vessels to the bone in this part of their course. In the supracondylar variety the fracture is from two and a half to five centimeters (one to two inches) above the base of the condyles. The contour of the knee is lost. The distal fragment is drawn medialward and backward by the action of the gastrocnemius, popliteus, and plantaris muscles, and upward by the abductor muscles. The patella is thrown forward, and often rests upon the distal end of the proximal fragment, the latter being in front of the distal fragment. In such cases the distal end of the proximal fragment may enter the knee-joint. Sometimes, this fracture may have a T-shape, and extend into the knee-joint. In such cases there is often marked effusion into the joint, which renders the diagnosis of the fracture more difficult.

In **fracture of either condyle** there is little, if any, displacement of the fragments. The width of the knee-joint may be markedly increased and the general contour of the joint lost.

In **fracture of the patella** the displacement will depend upon whether the fracture is due to direct or indirect violence. When due to direct violence (which is rare) the line of fracture is in any direction, in fact, it is frequently stellate. The separation is slight because the lateral expansions of the quadriceps are not torn. In fractures due to indirect violence there is marked displacement of the proximal fragment, as a rule, by the action of the quadriceps, which is inserted into it. The distal fragment usually retains its normal position on account of the unyielding quality of the ligamentum patellæ. There is generally a marked sulcus between the two fragments. There may be lateral displacement of the fragments through the unequal contraction of the ligaments or fibrous bands connected to the sides of the bone. Crepitus is absent, as a rule, owing to the fact that many of the strands of the fibrous expansion of the quadriceps muscle are drawn into the fracture, thus preventing exact apposition of the fragments. This also plays an important rôle in the union which follows this fracture. The knee-joint should always be opened, unless the fracture is in the distal part of the patella. The posterior surface of the bursa in front of the knee is generally lacerated, thus allowing free communication between the articular synovial capsule and the bursal cavity.

Fractures of the tibia generally occur near the junction of the distal with the intermediate third. The bone is smaller at this point than at any other part of the shaft, and this probably accounts for the frequency of the fracture here. As a rule, the displacement is not very marked, because the fibula acts as a retaining splint, and the fracture is generally transverse. If the fracturing force is indirect, the line of fracture will generally be oblique, and displacement of the distal fragment upward and backward by the muscles of the calf takes place. Owing to the subcutaneous situation of the crest of the tibia, fractures of this bone are very frequently compound, or may be readily made so by careless manipulation of the fragments.

Fractures of the medial malleolus usually show but little sign of displacement of the fragment, owing to the fact that the internal lateral (*deltoid*) ligament, which is attached to the borders and apex of the malleolus, prevents the fragment from becoming detached. There may be slight inversion of the foot, with a small amount of lateral displacement of the fragment.

The **fibula** may be fractured at any part of its extent, although most commonly the distal part of the bone is affected. The tibia acts as a very strong side-splint and thus protects the fibula from injury. Fractures in the middle

PLATE CCCXXX.

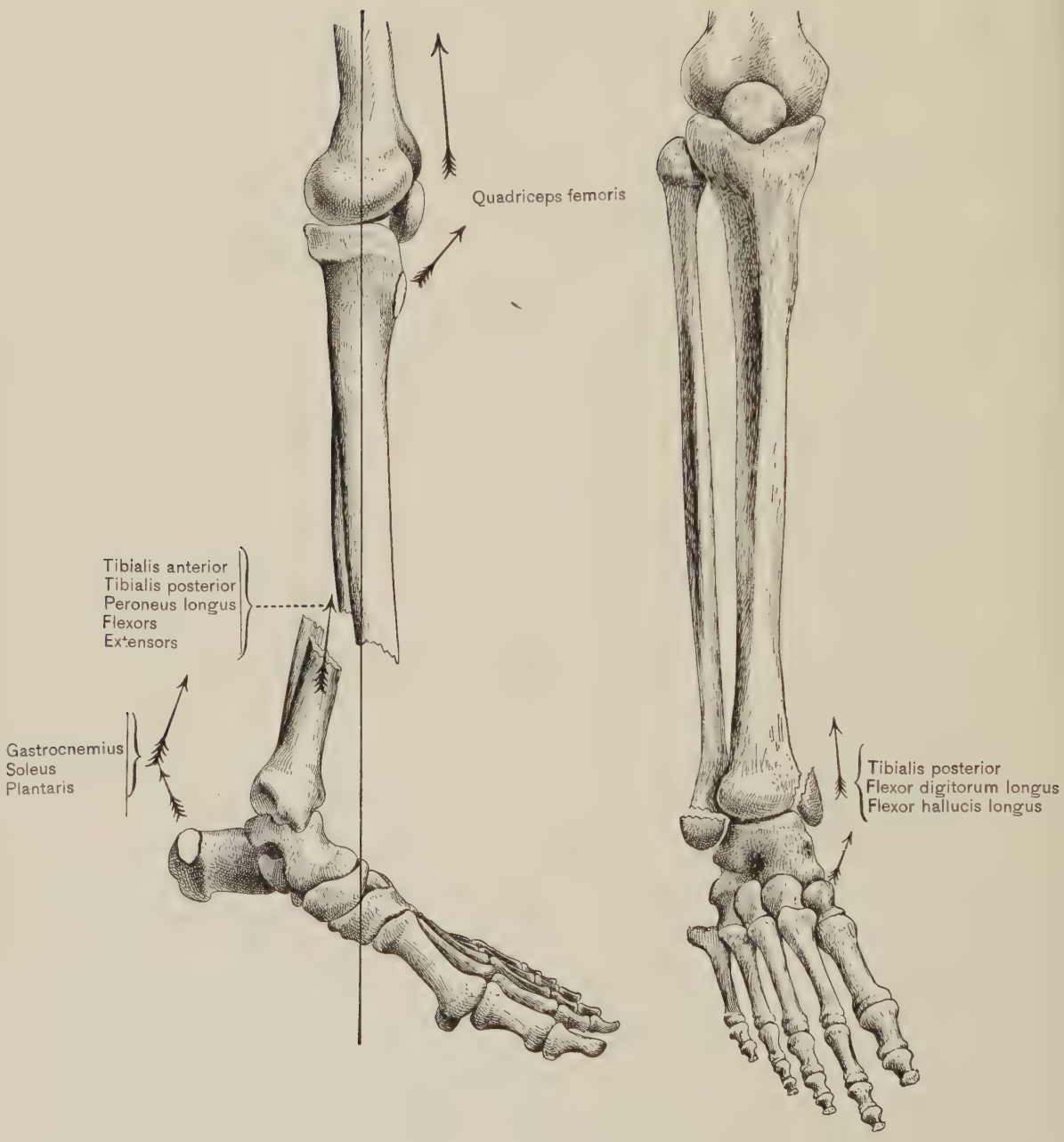

(A) FRACTURE OF BOTH BONES OF THE LEG.

(B) FRACTURE OF BOTH MALLEOLI.

and proximal thirds cause but little displacement, on account of the presence of the tibia, and on account of the firm padding of the muscles and fascia of the fibula. In the distal part of the fibula, fracture of the bone about five to seven centimeters (two to three inches) above the lateral malleolus is quite frequent. This is known as **Pott's fracture,** and is generally complicated by laceration of the internal lateral (*deltoid*) ligament. The fracture most commonly occurs after forced eversion, but may occur from forced inversion. The internal lateral (*deltoid*) ligament gives way or tears off the tip of the medial malleolus in the former, while in the latter the external lateral ligament is put on the stretch. If this ligament gives way no further damage will result. Posterior dislocation at the ankle results when the tibio-fibular ligaments are ruptured and the width of the mortise is increased. This is known as a **Dupuytren's** fracture.

The **lateral malleolus** may be fractured, but there is little, if any, displacement, unless the external lateral ligament is torn. This is the most frequent seat of *sprained fracture*, the external lateral ligament tearing off the portion of the lateral malleolus to which it is attached. In the majority of so-called "sprained ankles" this is the true condition of affairs, as demonstrated by X-ray examination.

Fractures of both bones of the leg (Plate CCCXXX) are more common than fracture of either bone separately. The displacement is generally in the line of the fracturing force.

In **fractures of the astragalus** (**talus**) the break usually occurs at the neck of the bone, as this is the weakest part of it. There is but little, if any, displacement, as there are no muscular attachments to produce it.

Fractures of the os calcis (**calcaneus**) are generally due to direct violence. If the break is anterior to the attachment of the strong calcaneo-astragaloid (*talo-calcaneal*) ligaments, there is little displacement; if behind these ligaments, the posterior fragment is drawn upward by the action of the calf muscles which are inserted into the bone through the tendo Achillis (*tendo calcaneus*), thus making a marked deformity. The dense fibrous tissue around the bone helps to prevent marked displacement.

Fractures of the tarsus do not show marked displacement, on account of their intimate relation one with the other and the firm ligaments which tend to hold them in place.

In **fracture of the metatarsal bones** the displacement is always slight, and generally in the line of the breaking force. Sprained fracture of the overlapping process of the fifth metatarsal bone at its articulation with the cuboid is not infrequent.

In **fracture of the phalanges** there is little, if any displacement.

AMPUTATIONS

The methods of amputations have been described with the amputations of the upper extremities.

Amputations of the Foot.—The principal amputations of the foot are: disarticulation at the interphalangeal joints; disarticulation at the metatarso-phalangeal joints; disarticulation at the tarso-metatarsal joint (Lisfranc's amputation), or disarticulation at the medio-tarsal joint (Chopart's amputation); disarticulation of the entire foot at the joint formed by the tibia, fibula, and astragalus (*talus*) (Symes' amputation), and Pirogoff's amputation, a modification of Symes' amputation in which part of the os calcis (*calcaneus*) is retained. The foot, however, or any part of it, can be amputated without regard to the several joints, the foot being considered as a solid whole.

In **amputation of the phalanges of the toes** the portion of the member to be removed is generally disarticulated at the joint proximal to the side of the injury or disease. In removing any of the toes, with the exception of the great toe, it is considered advisable to remove the entire member at the metatarso-phalangeal articulation, as the stump remaining after an amputation in the continuity of the phalanx, or at any of the phalangeal joints, is often very troublesome and of very little use.

In *disarticulating the distal phalanx* of any of the toes the incision is carried along the lateral aspect of the same from the level of the joint, around the end of the toe to a point directly opposite the beginning of the incision on the other side. The two ends of the incision are then joined by a dorsal incision. The incision should reach the bone in its entire extent. The lateral incision should be made nearer the dorsal than the plantar surface in order to avoid injuring the plantar digital arteries. The lateral incision severs the skin and superficial fascia and the pad of connective tissue over the end of the toe. The dorsal incision goes through the skin and superficial fascia, divides the tendon of the extensor digitorum longus in the lateral four toes and of the extensor hallucis longus in the great toe. The arteries severed are as follows: branches of the second, third, and fourth dorsal interosseous (*dorsal metatarsal*) arteries in the lateral three toes and in the lateral side of the second toe; branches of the dorsalis hallucis (*first dorsal metatarsal*) on the medial side of the second, and lateral side of the great toe; and the dorsal digital artery on the medial side of the great toe. The nerves are branches of the external saphenous (*sural*) and musculo-cutaneous (*superficial peroneal*) nerves. The dorsal incision should open the joint. The lateral and glenoid (*plantar accessory*) ligaments are then divided and the bone removed. If the plantar flaps have been carefully made, by keeping close to the

bone, the plantar digital arteries will not be severed. They will be found in the lower flap, near the junction of the lateral and dorsal incisions.

In *disarticulating at the first interphalangeal joint* the incision is begun on the dorsal surface of the toe, just proximal to the joint, and carried over the joint to a point about one and a quarter centimeters (one-half inch) distal to it. From there the incision is prolonged around the sides of the toe to the end of the dorsal incision. This incision will divide the skin and superficial fascia, with twigs from the collateral branches of the musculo-cutaneous (*superficial peroneal*) and external saphenous (*sural*) nerves on the dorsum and sides of the toes, and of the medial and lateral plantar nerves on the plantar surface; the plantar digital and the interosseous branches of the first, second, third, and fourth interosseous arteries; the tendons of the flexor digitorum brevis and flexor digitorum longus and the flexor hallucis longus in the great toe, on the plantar surface; the extensores digitorum longus and brevis, and, in the great toe, the extensor hallucis longus, on the dorsal surface. The bone is then freed by dividing the external and internal lateral (*lateral and medial collateral*) and the glenoid (*plantar accessory*) ligaments.

In *disarticulating the toes at the metatarso-phalangeal joint* the incision is made over the dorsal aspect of the joint, with lateral incisions extending to the plantar surface. In the great toe the incision should be carried well forward in order to afford sufficient tissue to cover the large extremity of the metatarsal bone. The end of the metatarsal bone should never be removed unless absolutely necessary, as the entire bone is needed for the support of the foot. In all the toes the skin and superficial fascia are divided, with twigs of collateral branches of the external saphenous (*sural*) and musculo-cutaneous (*superficial peroneal*) nerves on the dorsum of the toes, and of the medial and lateral plantar nerves on the plantar surface; and the plantar, digital, and interosseous arteries. The tendons of the flexor digitorum brevis and flexor digitorum longus and the lumbricales will be divided on the plantar surface of the lateral four toes, and the extensor digitorum brevis and extensor digitorum longus on the dorsal aspect of the same. The lumbricales will be severed near their attachment to the medial surface of the base of the lateral four toes; the plantar interossei, near their attachment to the medial surface of the bases of the lateral three toes, and the dorsal interossei, near their attachment to the lateral side of the bases of the second, third, and fourth toes, and medial surface of the base of the second toe. The flexor hallucis brevis, the flexor hallucis longus, and the extensor hallucis longus are divided in removing the great toe. The lateral (*collateral*) and the glenoid (*plantar accessory*) ligaments are then severed. In removing all the toes at one time, a dorsal incision is made from the lateral to the medial border of the

bases of the phalanges, on a level with the free margin of the web. The joints are opened separately from the dorsal side, and the phalanges disarticulated separately. A plantar flap is then made by cutting along the plantar surface of the phalanges. The same structures are divided as described above.

Before taking up the amputation of the foot and ankle, it may be well to enumerate the articulations of the separate bones. The metatarsal bones articulate with the medial (*first*), middle (*second*), and lateral (*third*) cuneiform and the cuboid bones. The line of the articulations is very irregular. Thus, the medial (*first*) cuneiform bone and, to a less extent, the lateral (*third*) project beyond the middle (*second*), a mortise being formed for the articulation of the second metatarsal. The cuboid also recedes, its medial proximal tip being fitted in a notch of the lateral (*third*) cuneiform. The medial (*first*) cuneiform bone receives the base of the first metatarsal, and articulates with the medial side of the end of the second metatarsal. The middle (*second*) cuneiform receives the second metatarsal, and the lateral (*third*) cuneiform and third metatarsal. The cuboid receives both the fourth and fifth metatarsal bones. The second metatarsal bone is fitted into the mortise formed by the medial (*first*) and lateral (*third*) cuneiform bones. The fifth metatarsal bone does not articulate with the cuboid by its entire surface, the lateral end projecting laterally in the form of a tuberosity. The three cuneiform bones articulate with the scaphoid (*navicular*) by their proximal ends, and the scaphoid (*navicular*) with the astragalus (*talus*) by its proximal end. The cuboid articulates with the os calcis (*calcaneus*) by its proximal end, and with the lateral (*third*) cuneiform by its medial surface. Usually a small facet for articulation with the scaphoid (*navicular*), is found just posterior to the articulation with the lateral (*third*) cuneiform, but at times the scaphoid (*navicular*) and cuboid are completely separated. The line of articulation between the astragalus (*talus*) and scaphoid (*navicular*), and the os calcis (*calcaneus*) and cuboid is practically a straight one. The astragalus (*talus*) rests upon the os calcis (*calcaneus*), articulating with that bone and the scaphoid of the tarsus, and with the tibia and fibula of the leg. The os calcis (*calcaneus*) articulates with the astragalus (*talus*) and the cuboid.

Lisfranc's amputation is a disarticulation of the foot at the tarso-metatarsal joint. This joint is marked approximately by a line from the base of the fifth, to the base of the first metatarsal bone. The dorsal incision begins on the lateral side of the foot just above the tuberosity of the fifth metatarsal, is carried along this edge for about two and a half centimeters (one inch), then across the dorsum of the foot with a gentle downward curve to the base of the first metatarsal, and then along the medial edge of the foot for about two and a half centimeters (one inch). The flap, consisting only of skin and subcutaneous tissue, is dis-

sected back for about two and a half centimeters (one inch); the tendons are then cut across transversely, and all the soft tissues down to the bones are dissected up to beyond the tarso-metatarsal articulation. The plantar flap is then made. This begins at the end of the dorsal incision just above the tuberosity of the fifth metatarsal and is carried along the lateral edge of the foot to the level of the metatarso-phalangeal joint; then across the sole of the foot, on a line with the heads of the other metatarsal bones, to the metatarso-phalangeal articulation of the first toe; then along the medial side of the foot to the medial end of the dorsal incision. A flap of skin and subcutaneous tissue is dissected up for about two and a half centimeters (one inch); then all the soft parts are divided down to the bone, and the flap, consisting of all the soft parts, is dissected up to above the tarso-metatarsal articulation. The structures divided on the dorsal aspect of the foot are: the skin and superficial fascia, the four dorsal interossei arteries with their veins, and branches of the musculo-cutaneous (*superficial peroneal*) and external saphenous (*sural*) nerves, the deep fascia, the tendons of the flexor digitorum brevis, the flexor digitorum longus, extensor hallucis longus, and the dorsal interossei muscles. The structures divided by the plantar incision are: the skin and superficial fascia, twigs from the plantar arteries and nerves, the plantar fascia, the digital branches of the medial and lateral plantar arteries, the medial and lateral plantar nerves, the tendons of the flexor digitorum brevis, the lumbricales, and the abductor digiti quinti muscles. The peroneus tertius and tibialis anterior tendons are not severed in making the incisions. The bones are then disarticulated from the dorsal surface, beginning at the fifth metatarsal. The dorsal and interosseous ligaments are divided between the lateral three metatarsal and the cuboid and lateral (*third*) cuneiform bones. In dividing these ligaments and separating the bones, the tendons of the peroneus longus and peroneus brevis muscles are severed. The first metatarsal bone is then disarticulated from the medial (*first*) cuneiform, and the expansion of the tibialis anterior tendon severed. There now remains the second metatarsal articulation to be divided. As the seond metatarsal bone fits in the mortise between the medial (*first*) and lateral (*third*) cuneiform bones, there is often great difficulty experienced in separating the bones. It is first disarticulated from the middle (*second*) cuneiform, and then from the medial (*first*) and lateral (*third*) cuneiform. The peroneus longus tendon is then divided, and the foot is free.

The arteries to be tied in the dorsal flap are the four interossei, which will be found over the interosseous spaces. In the plantar flap the arteries to be tied are branches of the medial and lateral plantar, and at times these vessels themselves.

In this amputation the plantar flap may be made by transfixion, but it is not so advisable as the method described, as the tarso-metatarsal articulation must be separated before the plantar flap is made, and because there is great danger of wounding the soft parts of the sole of the foot, and especially the plantar arteries. When performing this operation, the dorsal incision is first made, and the metatarsal bones disarticulated from the tarsal. The point of the knife is forced between the bones and worked backward and forward until the ligaments are severed. During this procedure great care must be exercised not to injure the soft parts of the sole, and especially the plantar arteries, a thing that is very liable to happen if the point of the knife is forced too far, or if it should accidentally slip. After the bones have been disarticulated, the foot is sharply flexed, and the plantar flap made by carrying the knife downward in close relation to the plantar surface of the bones.

Hey's operation is practically the same as that of Lisfranc, differing only in the fact that Hey first removed the lateral four toes by disarticulating their metatarsal bones from the tarsal attachments, and then removed the projecting end of the medial (*first*) cuneiform bone with the saw, the end of the bone carrying the metatarsal bone of the great toe with it. The structures divided are the same as those in a Lisfranc amputation, with this exception.

Chopart's amputation is a disarticulation of the foot at the mid-tarsal joint. About two and a half centimeters (one inch) in front of the medial malleolus and a little below it, the tuberosity of the scaphoid can be felt. Just posterior to this is the medial end of the mid-tarsal joint. The lateral end of the joint is marked by a point midway between the tip of the lateral malleolus and the base of the fifth metatarsal bone. This joint is practically double, being formed by the articulation of the os calcis (*calcaneus*) with the cuboid, and the astragalus (*talus*) with the scaphoid (*navicular*). These two articulations have separate synovial membranes and separate ligaments. They are practically on the same line, although the astragalo-scaphoid (*talo-navicular*) articulation is slightly in advance of the calcaneo-cuboid. In performing Chopart's amputation the incisions used are of the same shape as those in the amputation by Lisfranc's method. The dorsal flap begins on the lateral side at a point midway between the tip of the lateral malleolus and the tuberosity of the fifth metatarsal bone. It is carried along the lateral edge of the foot for a short distance and then over the dorsum of the foot in a slight curve on a level with the bases of the metatarsal bones. Having reached the medial side of the foot, it is carried along the edge of the same to a point just behind the tuberosity of the scaphoid (*navicular*). The plantar flap is made by carrying an incision across the sole of the foot at the middle of the metatarsal bones. The flaps consist of all the soft parts down to

the bone. They are dissected up as far as the mid-tarsal articulation, which is fully exposed. The os calcis (*calcaneus*) is then disarticulated from the cuboid by severing the internal calcaneo-cuboid, the dorsal calcaneo-cuboid, and the long and short plantar ligaments; the astragalus (*talus*) is then to be separated from the scaphoid (*navicular*) by dividing the astragalo-scaphoid (*talo-navicular*) and the inferior and external calcaneo-scaphoid ligaments. The structures severed, with the exception of the ligaments and the tendon of the tibialis posterior, are the same as those in the Lisfranc amputation.

The vessels that require ligation in the dorsal flap are the dorsalis pedis and its tarsal and metatarsal branches. In the plantar flap the medial plantar artery is divided in the medial portion, the lateral plantar on a level with the second metatarsal bone, and the digital branches of the lateral plantar in the lateral portion of the flap.

Symes' amputation consists in the disarticulation of the astragalus (*talus*) from the tibia and fibula, and the removal of the articulating surface of the tibia together with the medial and lateral malleoli. The first incision starts at the tip of the lateral malleolus and is carried, at right angles to the long axis of the foot, across the heel and vertically up the medial side of the foot to a point just below the tip of the medial malleolus. It is often advisable to carry the first part of the incision across the heel and then start again at the medial malleolus and carry an incision downward to meet the end of the first. In this way the possibility of carrying the incision too high on the medial side of the foot is prevented. The main objection to this operation is that the blood supply of the heel-flap is liable to be deficient, thus causing subsequent sloughing. This may be avoided to a great extent by carrying the incision across the sole of the foot a little anterior to the long axis of the tibia (Wyeth). The incision severs all structures down to the bone. The flap is then carefully carried backward, the knife hugging the bone in order to avoid injuring the branches of the posterior tibial near its bifurcation. The os calcis (*calcaneus*) is stripped of all its soft parts. The dorsal incision is then made by joining the ends of the plantar incision directly across the front of the ankle. This incision severs all the soft parts down to the bone, and also the anterior ligament of the ankle-joint. The external lateral ligament is then divided, then the internal (*deltoid*) and posterior, and finally the tendo Achillis (*tendo calcaneus*), and the foot is removed. The soft parts are then cleaned from the two malleoli and the distal end of the tibia. In doing this, care should be exercised not to injure the flaps. The ends of the tibia and fibula are then removed with a saw, in a horizontal cut, a small portion of the cartilage covering the tarsal end of the tibia being removed with the malleoli.

The parts divided by the plantar incision include: the skin and superficial fascia, twigs from the musculo-cutaneous (*superficial peroneal*), short saphenous (*sural*), and internal (*medial*) calcanean nerves, branches of the external (*lateral*) calcanean and the medial and lateral plantar arteries, the deep fascia, the external (*small*) saphenous vein, the medial malleolar and lateral malleolar branches of the anterior tibial artery, the tendons of the peroneus longus and peroneus brevis, and the flexor hallucis longus muscles, the plantar fascia, and the origins of the abductor hallucis, flexor digitorum brevis, and abductor digiti quinti muscles. The posterior tibial artery divides into the medial and lateral plantar arteries on a level with a line drawn from the point of the medial malleolus to the center of the convexity of the heel. This point is very near the line of incision, and the branches of the posterior tibial, or even that vessel itself, may at times be divided. The dorsal incision divides: skin, superficial fascia, twigs of the musculo-cutaneous (*superficial peroneal*) and saphenous nerves, the internal (*great*) saphenous vein, the musculo-cutaneous (*superficial peroneal*) nerve, the deep fascia, the tendons of the peroneus tertius, extensor digitorium longus, tibialis posterior, and flexor digitorum longus muscles, the anterior peroneal and anterior tibial vessels, and the anterior tibial (*deep peroneal*) nerve.

The vessels that will require a ligature are the anterior tibial, which will be found in the center of the dorsal incision; the medial and lateral plantar, in the medial part of the heel-flap; the medial malleolar branch of the posterior tibial, behind the medial malleolus; the anterior peroneal in front of the tibiofibular joint; and the medial and lateral malleolar branches of the anterior tibial.

In **Pirogoff's amputation** the same incisions are used as those in Symes', with the exception that the plantar flap is carried more anteriorly. The plantar flap is dissected from the os calcis (*calcaneus*) for only about six millimeters (one fourth of an inch), and the dorsal flap is then made. The joint is opened and the astragalus (*talus*) is carried forward from its position between the two malleoli. A fine saw is applied to the os calcis (*calcaneus*) just behind the posterior lip of the astragalus (*talus*) and the bone sawed through in a forward and downward direction. After the malleoli have been removed as in Symes' amputation, and the vessels secured, the remaining portion of the os calcis (*calcaneus*) is brought into apposition with the ends of the tibia and fibula and held in place with silver wire. The other structures divided are the same as in the Symes' operation.

Amputation of the Leg.—*Anteroposterior flap method:* the incision is started on the medial side of the leg about two and a half centimeters (one inch) below the point at which the bones are to be divided. It is carried downward along the medial side of the leg for a sufficient distance to furnish enough flap, and then across the back of the leg to the middle of the lateral side. The lateral longitu-

PLATE CCCXXXI.

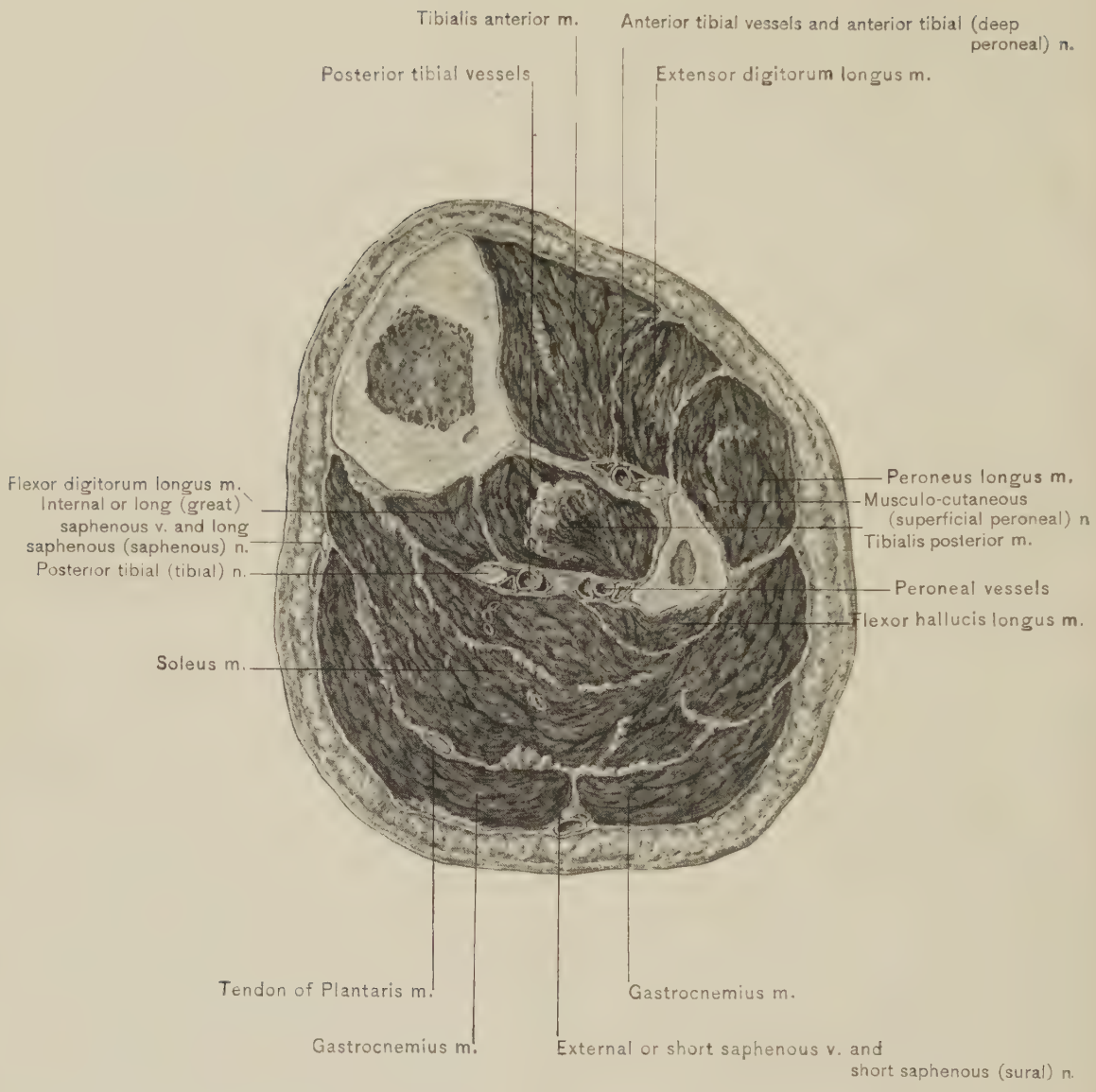
Tibialis anterior m.
Anterior tibial vessels and anterior tibial (deep peroneal) n.
Posterior tibial vessels
Extensor digitorum longus m.
Flexor digitorum longus m.
Internal or long (great) saphenous v. and long saphenous (saphenous) n.
Posterior tibial (tibial) n.
Soleus m.
Peroneus longus m.
Musculo-cutaneous (superficial peroneal) n.
Tibialis posterior m.
Peroneal vessels
Flexor hallucis longus m.
Tendon of Plantaris m.
Gastrocnemius m.
Gastrocnemius m.
External or short saphenous v. and short saphenous (sural) n.

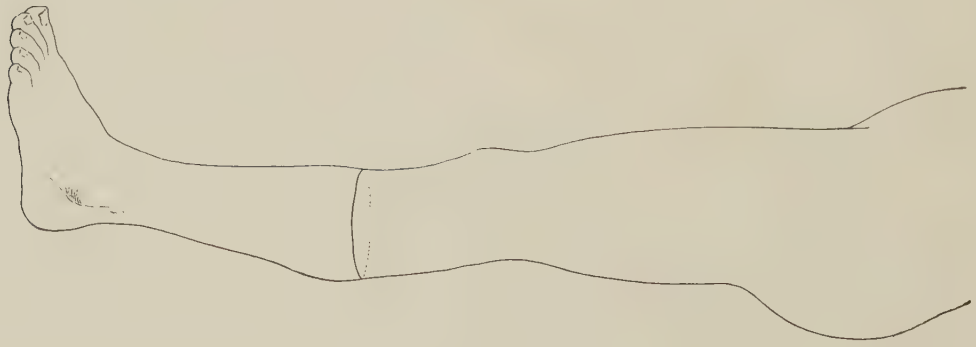

AMPUTATION OF LEG, PROXIMAL THIRD.

dinal incision is then made. It should commence at a point on a level with the beginning of the first incision and complete the posterior flap. The anterior flap is made by carrying an incision across the front of the leg, with a slight downward curve. These incisions sever only the skin and superficial fascia. The flaps consisting of skin and fasciæ are dissected up and the muscles and vessels cut transversely by a circular incision. The bones are then sawed through, the fibula first, after the soft parts have been well cleaned from them (Plate CCCXXXI).

The anterior incision will divide: in the middle of the leg, the skin and superficial fascia, with the internal saphenous (*saphenous*) nerve and vein, twigs from the internal saphenous (*saphenous*) and the communicans tibialis (*medial sural*) nerves, and small branches of the anterior tibial artery. The posterior incision divides: the skin and superficial fascia with the external saphenous (*sural*) nerve and external (*small*) saphenous vein, the cutaneous branch of the external popliteal (*common peroneal*) nerve, and branches of the popliteal artery. The circular incision divides: the deep fascia, the tibialis anterior, the extensor digitorum longus, and the extensor hallucis longus muscles, the anterior tibial vessels, and the anterior tibial (*deep peroneal*) nerve on the anterior aspect of the leg; the flexor digitorum longus, tibialis posterior, soleus, and gastrocnemius muscles, the posterior tibial vessels, the posterior tibial (*tibial*) nerve, and the peroneal vessels on the posterior aspect, and the peronei muscles on the lateral aspect. The main vessels to be tied are: the anterior tibial artery, which is found between the tibialis anterior and extensor hallucis longus muscles, lying on the anterior surface of the interosseous membrane; the posterior tibial, which is found beneath the flexor digitorum longus muscle in the posterior part of the leg; and the peroneal artery, which is found beneath the tibial is posterior, just to the tibial side of the fibula.

Modifications in making the flaps and dividing the muscles are numerous. Among them may be mentioned Teale's, which consists of a long anterior rectangular, and a short posterior rectangular flap, both flaps containing all the tissues down to the bone. Lee's amputation is very similar to that devised by Teale, with the exception that the long flap is made on the posterior, and the short one on the anterior surface of the leg. Lateral flaps are also often advised. In Teale's and Lee's flaps the soft parts are divided on a level with the skin incision. Hey advises severing the gastrocnemius muscle first, and then making two lateral incisions to the bone, in the line of the skin incision. The muscles must then be separated from the bone and severed by cutting them from within outward, thus making the flaps musculo-tegumentary.

Amputation at the Knee-joint.—*Anteroposterior flap method:* The incision begins on a level with the posterior border of the condyle of the femur, a little

below its tuberosity (*epicondyle*). If started above this point, there will be danger of cutting the fascial and fibrous tissues which hold the attachments of the strong muscles of the thigh. The incision is carried down the leg to a point about on a level with the tubercle (*tuberosity*) of the tibia, and then across the front of the leg with a slight downward curve to the opposite side, and then up this side of the leg to a point opposite the beginning of the incision on the other side. The flap contains the skin and superficial fascia. It is dissected up as far as the tubercle (*tuberosity*) of the tibia, and the leg is then flexed in order to tighten the ligamentum patellæ, which is divided. The capsule of the joint is opened and the anterior flap turned upward. The lateral (*collateral*) and crucial ligaments are divided, but the ligamentum mucosum (*patellar synovial fold*) is allowed to remain to afford additional strength to the anterior flap. In dividing the ligaments care must be taken to prevent the knife injuring the vessels in the popliteal space. The knife is then passed between the tibia and femur, close to the tibia, and a posterior flap made by cutting downward and outward.

The anterior incision divides the skin and superficial fascia, the patellar plexus of nerves and superficial branches of the arterial plexus, the deep fascia, the ligamentum patellæ and the capsule of the knee-joint; the long (*great*) saphenous vein and long saphenous (*saphenous*) nerve, near the medial angle of the flap; and near each condyle the anastomotic and the two superior articular (*genicular*) arteries. The posterior incision divides the skin and superficial fascia, with twigs of the saphenous nerve and vein, the communicans peronei and communicans poplitei nerves, small branches of the popliteal, anastomotic, and articular arteries, the deep fascia, the small sciatic (*posterior cutaneous nerve of thigh*) nerve, the sartorius, the gracilis, the semimembranosus, the semitendinosus, the popliteus, the plantaris, the biceps femoris, and both heads of the gastrocnemius, the popliteal artery, the popliteal vein, and the internal (*medial*) and external (*lateral*) popliteal nerves. The arteries to be ligated are the popliteal, which will be found near the center of the posterior flap, the anastomotica magna (*genu suprema*), and the superior articular (*superior genicular*).

The **Stokes-Gritti Amputation** consists of a large anterior and a short posterior flap. The anterior flap is dissected up so as to include the patella. The soft parts are divided by a circular cut of the knife, and the femur is divided just above the femoral condyles. The cartilaginous portion of the patella is removed with a saw and the remainder of the patella is fixed to the distal end of the femur.

Amputation of the thigh (Plates CCCXXXII; CCCXXXIII) may be performed by one of several methods. In the circular method the incision is to be made a sufficient distance below the point at which the bone is to be divided to allow enough flap material to cover the end of the stump. As the muscles of the

PLATE CCCXXXII.

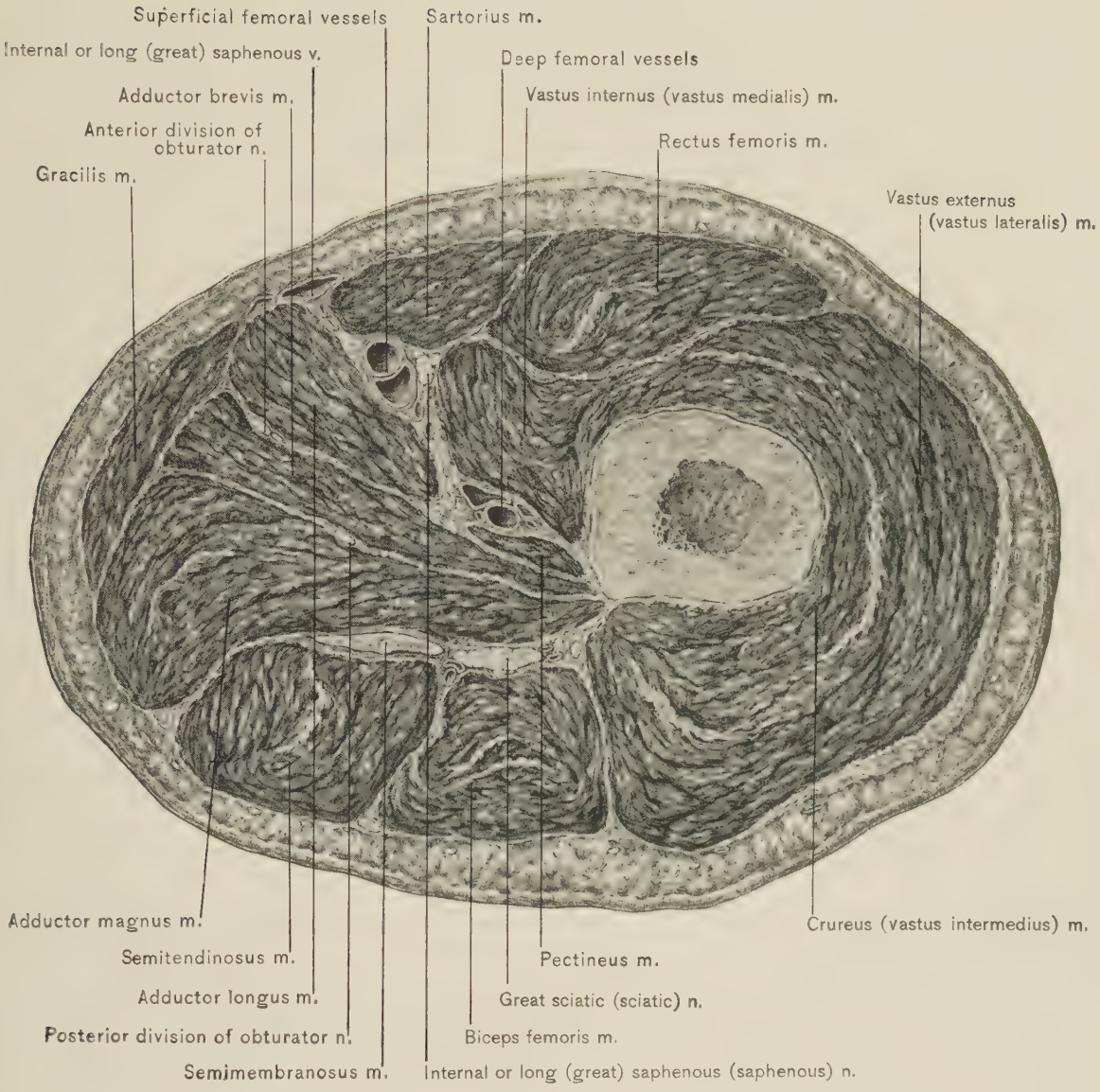

AMPUTATION AT THE PROXIMAL THIRD OF THE THIGH.

PLATE CCCXXXIII.

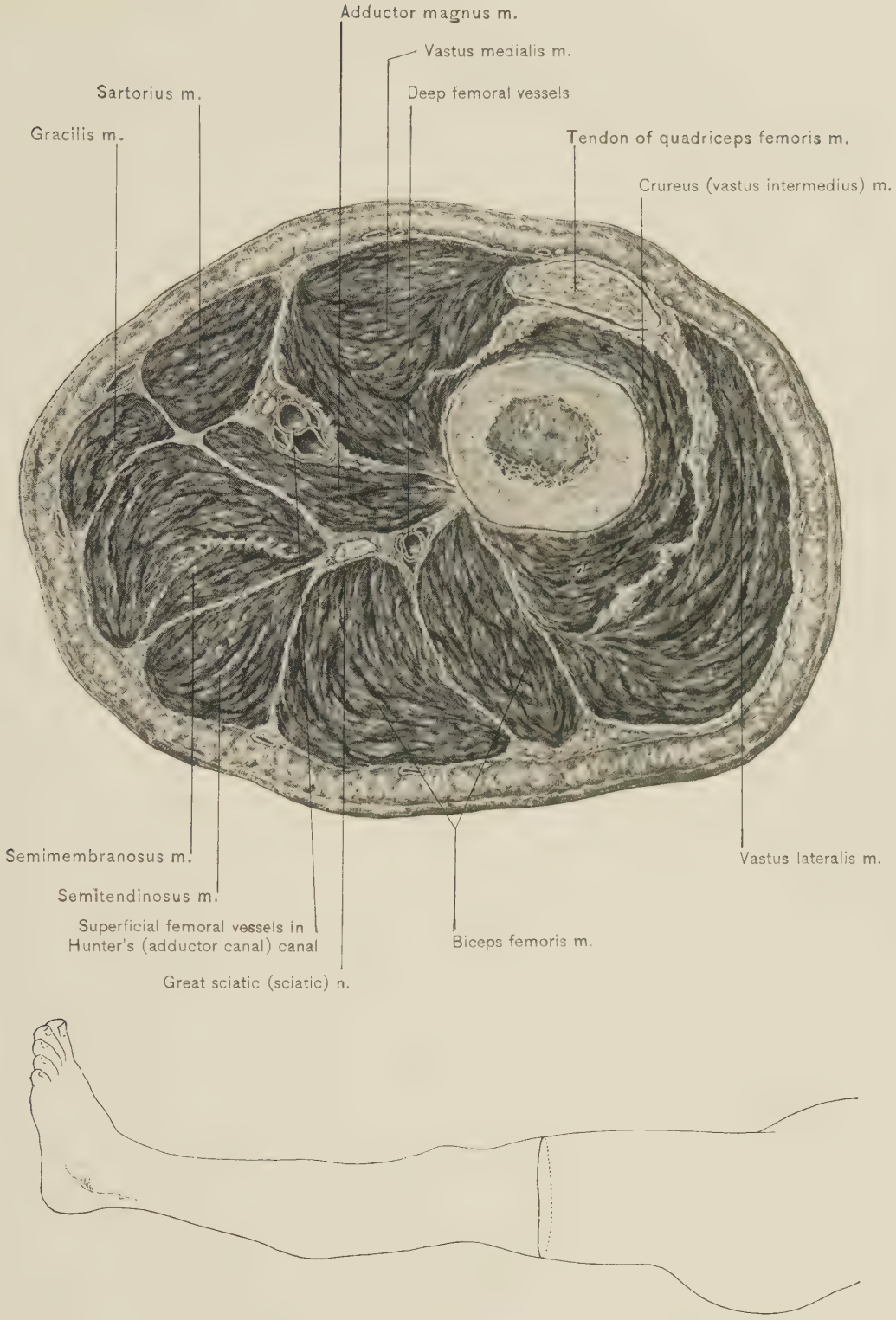

AMPUTATION AT THE DISTAL THIRD OF THE THIGH.

thigh contract unequally, the incision should be made at right angles to the long axis of the limb, but with a gentle slope from above downward and before backward. The flap is carried upward to the level at which the limb is to be amputated and the soft tissues are then divided at right angles to the bone at this point. The muscles and vessels are protected by a cloth retractor, and the bone sawed through. If desirable, after making the circular incision through the skin, the latter may be allowed to retract and the muscles then severed at right angles to the bone at the margin of the retracted skin. Two lateral incisions are then made down to the bone and the soft parts separated from it, and then lifted from the bone in the form of anterior and posterior solid flaps, and the bone divided.

The parts divided by the circular incision through the skin and superficial fascia are: the middle (*intermediate*) cutaneous, the internal (*medial*) cutaneous, and the external (*lateral*) cutaneous nerves, the cural (*genito-crural*) branch of the genito-crural (*lumbo-inguinal*) nerve, and the internal (*great*) saphenous vein. The circular incision through the soft parts divides the fascia lata, the extensor quadriceps (*quadriceps femoris*), sartorius, gracilis, adductor longus, adductor magnus, semimembranosus, semitendinosus, and biceps femoris muscles; the superficial femoral, the deep femoral, the lower perforating, and the descending branch of the external (*lateral*) circumflex arteries; the obturator, the great sciatic (*sciatic*), and the small sciatic (*posterior cutaneous nerve of thigh*) nerves. The main vessels to be ligated will be the superficial femoral artery and vein, the deep femoral (*profunda femoris*) artery and vein, and the descending branch of the external (*lateral* circumflex artery. The superficial femoral (*femoral*) artery will be found on the medial aspect of the thigh in the triangular space between the sartorius, medially, the vastus internus (*vastus medialis*) anteriorly, and the adductor longus, posteriorly. The vein will be found to its medial side. The deep femoral (*profunda femoris*) will be found immediately behind the femur, between the crureus (*vastus intermedius*) and adductor magnus muscles. The descending branch of the external (*lateral*) circumflex will be found on the lateral aspect of the stump, lying on the sheath of the crureus (*vastus intermedius*) muscle.

Amputation at the Hip-joint.—The main difficulty experienced in performing this operation is the prevention of hemorrhage from the femoral artery and its large branches. Many ways have been suggested by which this difficulty may be overcome, among them being the ligation of the femoral or external iliac artery before the flap has been made; ligation of the femoral at the edge of the flap before dividing the artery; compression of the artery as it passes over the brim of the pelvis; compression of the external iliac artery; compression of all the blood supply by a rubber band, etc. Wyeth has advised the use of two long mattress needles, by which the rubber band is retained in place and all possibility

of the band slipping and freeing the vessels is prevented. "Two steel mattress needles, four and a half millimeters (three-sixteenths of an inch) in diameter and a foot long are used. The point of one is inserted three and three-quarters centimeters (an inch and a half) below, and just to the medial side of the anterior superior spine, and is made to traverse the muscles, passing about half-way between the greater trochanter and the iliac spine, lateral to the neck of the femur, and coming out just behind the trochanter. The point of the second needle is entered two and a half centimeters (one inch) below the level of the groin medial to the saphenous opening, and, passing through the adductors, comes out about three and three-quarters centimeters (an inch and a half) in front of the tuber ischii. No vessels are endangered by these needles. The points are protected by corks, to prevent injury to the operator's hands."

The strong rubber tube is then wrapped firmly around the limb above the needles and firmly tied, and the limb removed by the circular method.

External Racket Incision.—With the limb adducted and rotated medialward, the point of the knife is introduced above the upper edge of the greater trochanter and is carried vertically down the thigh for about fifteen or seventeen centimeters (six or seven inches). The incision is then carried around the thigh, anteriorly and posteriorly, in two parts which meet on the medial side of the thigh. This incision divides the skin and superficial fascia, the external (*lateral*), middle (*intermediate*), and internal (*medial*) cutaneous nerves, anteriorly; and the small sciatic (*posterior cutaneous nerve of thigh*) posteriorly; the internal (*great*) saphenous vein, and numerous branches of the posterior femoral cutaneous vein; branches of the obturator and gluteal arteries, and the internal (*medial*) and external (*lateral*) circumflex. The skin and subcutaneous tissues are then dissected up in the form of a flap for about five centimeters (two inches), and the vertical incision carried down to the bone. The muscles attached to the femur are divided, the capsule opened, the round ligament divided, and the head of the bone disarticulated. The muscles to be separated from the femur include: the gluteus muscles, maximus, medius, and minimus, the gemellus superior and inferior, the obturator internus and externus, the pyriformis, the psoas, the iliacus, the pectineus, the adductor magnus, and the adductor brevis. Having thoroughly cleared the proximal part of the femur of the muscle attachments, the capsule is freely opened by a vertical incision. The thigh is rotated lateralward and the round ligament divided. The remaining muscles are then divided by a circular cut at the level of the retracted skin. This incision divides the fascia lata and the ilio-tibial band, the tensor vaginæ femoris (*tensor fasciæ latæ*), the rectus, the sartorius, the gracilis, the adductor longus, the semimembranosus, the semitendinosus, and the biceps femoris muscles, the superficial femoral (*femoral*)

PLATE CCCXXXIV.

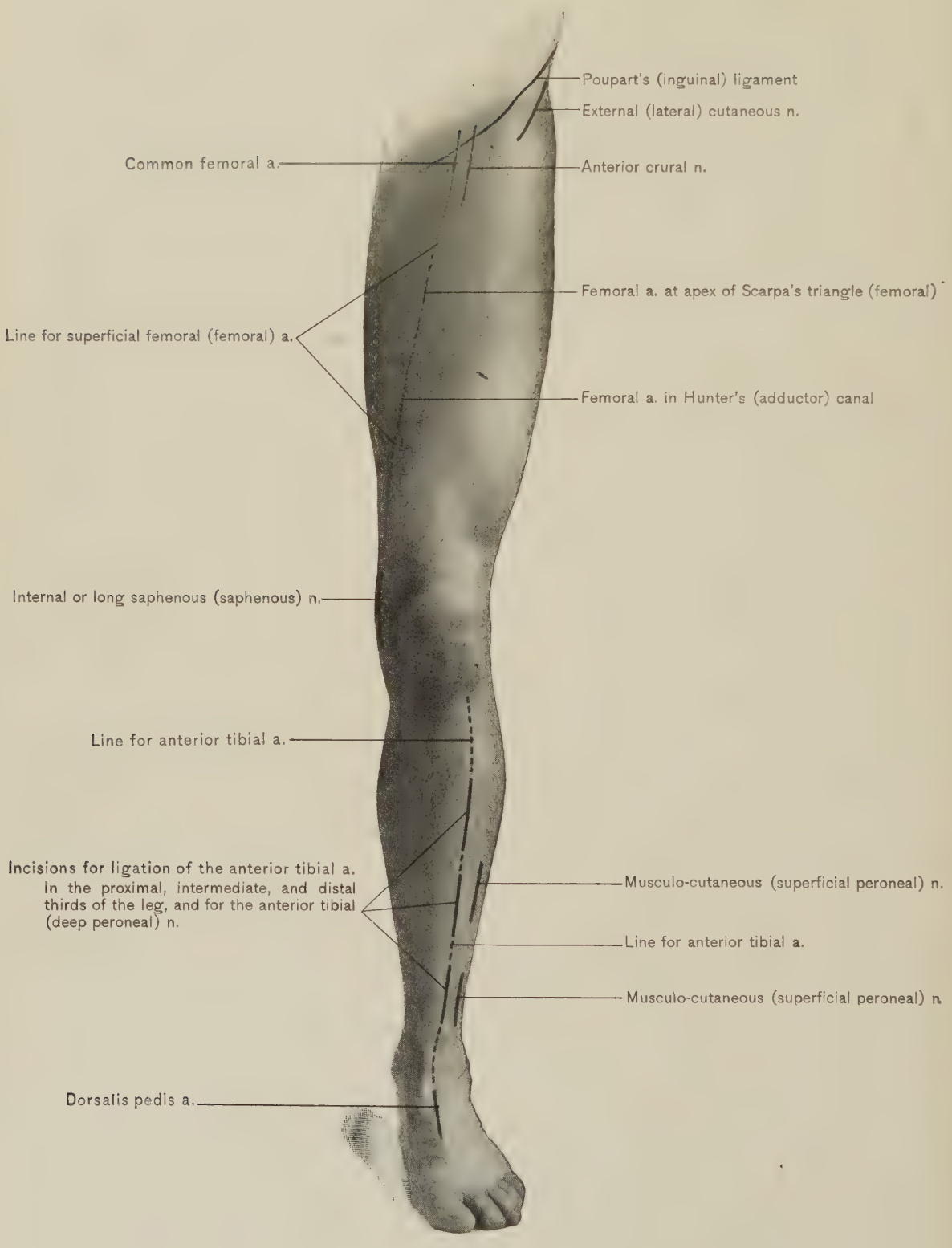
Poupart's (inguinal) ligament
External (lateral) cutaneous n.
Common femoral a.
Anterior crural n.
Femoral a. at apex of Scarpa's triangle (femoral)
Line for superficial femoral (femoral) a.
Femoral a. in Hunter's (adductor) canal
Internal or long saphenous (saphenous) n.
Line for anterior tibial a.
Incisions for ligation of the anterior tibial a. in the proximal, intermediate, and distal thirds of the leg, and for the anterior tibial (deep peroneal) n.
Musculo-cutaneous (superficial peroneal) n.
Line for anterior tibial a.
Musculo-cutaneous (superficial peroneal) n.
Dorsalis pedis a.

LINES OF INCISIONS FOR EXPOSURE ARTERIES AND NERVES.

artery and vein, the deep femoral (*profunda femoris*) artery and vein, the internal (*medial*) and external (*lateral*) circumflex arteries, and branches of the gluteal (*superior gluteal*), obturator, and sciatic (*inferior gluteal*) arteries. The great sciatic (*sciatic*) nerve, the anterior crural (*femoral*) nerve, and numerous muscular twigs from these nerves will also be divided.

The femoral vessels will be found near the center of the anterior part of the flap, in the following order from without medialward: superficial femoral artery, superficial femoral vein, deep femoral vein, deep femoral artery. The internal (*medial*) circumflex artery will be found near the medial and posterior side of the acetabulum. The external (*lateral*) circumflex may not be divided, but its descending branch will be divided near the medial edge of the vastus externus (*vastus lateralis*).

In removing the lower extremity at the hip-joint by the transfixion method, no tourniquet or rubber band is applied. The point of the knife is introduced at a point midway between the anterior superior iliac spine and the top of the greater trochanter, and is then thrust through the limb parallel with Poupart's (*inguinal*) ligament and brought out on the medial side of the thigh at a point about two and a half centimeters (one inch) in front of, and two and a half centimeters (one inch) below, the tuber ischii. Being passed as deeply as possible, the knife grazes the head of the femur and opens the capsule of the joint. The anterior flap is then cut by carrying the knife downward for about seventeen and a half to twenty centimeters (seven to eight inches), and then forward through the intervening structures. As soon as the assistant is able to pass his fingers through the wound he should do so, and compress the main vessels of the anterior flap, as in amputation at the shoulder-joint, with the exception that the thumbs are on the skin in the thigh, and against the vessels in the arm. The capsule is then thoroughly opened, the limb rotated lateralward, and the round ligament divided. The assistant still retains the pressure on the anterior vessels and holds the anterior flap out of the way of the operator. The posterior flap is then formed by carrying the knife behind the head of the femur and the greater trochanter, downward and lateralward. The internal (*medial*) circumflex artery should then be tied at once, and after that the femoral.

LIGATIONS OF THE ARTERIES (Plate CCCXXXIV)

The methods of ligation and the general rules to be observed have been given under ligations of arteries of the upper extremity.

Ligation of the Femoral Arteries.—The line of the common and superficial femoral arteries with the thigh slightly flexed and rotated laterally, is from a

point midway between the anterior superior iliac spine and the symphysis pubis to the tuberosity of the medial condyle (*medial epicondyle*). The common femoral, and its continuation, the superficial femoral (*femoral*) artery lie on the following structures, from above downward: the psoas, pectineus, adductor brevis, and adductor longus muscles, and the tendon of the adductor magnus muscle. These arteries lie in Scarpa's (*femoral*) triangle and are superficial; their pulsations can readily be detected. From the apex of the triangle the superficial femoral artery enters Hunter's (*adductor*) canal, which is about in the middle of the thigh. Associated with the artery in Hunter's (*adductor*) canal are the internal saphenous (*saphenous*) nerve, the femoral vein, and the superficial part of the anastomotica magna (*genu suprema*) artery. The relation of the superficial femoral artery to the vein throughout its course is important. In Scarpa's (*femoral*) triangle the artery lies to the lateral side of the vein, and on the same plane; in the apex of the triangle the artery is in front of the vein; in Hunter's (*adductor*) canal it lies in front of, and to the medial side of the vein. The artery may be ligated at the base of Scarpa's (*femoral*) triangle, at the apex of the triangle, or in Hunter's (*adductor*) canal.

In *ligating the femoral artery at the base of Scarpa's (femoral) triangle* (Plate XXXV) an incision is made directly over the artery, beginning a little above Poupart's (*inguinal*) ligament and extending downward for about seven and a half centimeters (three inches). The skin and superficial fascia are divided, with twigs from the external (*lateral*), middle (*intermediate*) and internal (*medial*) cutaneous nerves, and small branches of the superficial epigastric and superficial circumflex iliac arteries with their veins. The cribriform fascia is then divided in the original line of incision and the sheath of the vessels exposed. Care must be exercised in cutting the cribriform fascia to avoid wounding the superficial external pudendal and superficial epigastric arteries, which lie near the line of incision. The crural (*lumbo-inguinal*) branch of the genito-crural (*genito-femoral*) nerve will be seen lying on the sheath of the vessels, but to its lateral side. The sheath is then opened, and the ligature passed from within lateralward; that is, away from the vein.

The *collateral circulation* is established by the anastomoses formed between the internal pudendal and the pudendal branch of the femoral; between the gluteal (*superior gluteal*) and the external (*lateral*) and internal (*medial*) circumflex and the first perforating; between the superficial circumflex iliac and the external (*lateral*) circumflex; between the obutrator and the internal (*medial*) circumflex; between the sciatic (*inferior gluteal*) and the superior perforating and the internal (*medial*) circumflex; and between the comes nervi ischiadici and the first perforating.

PLATE CCCXXXV.

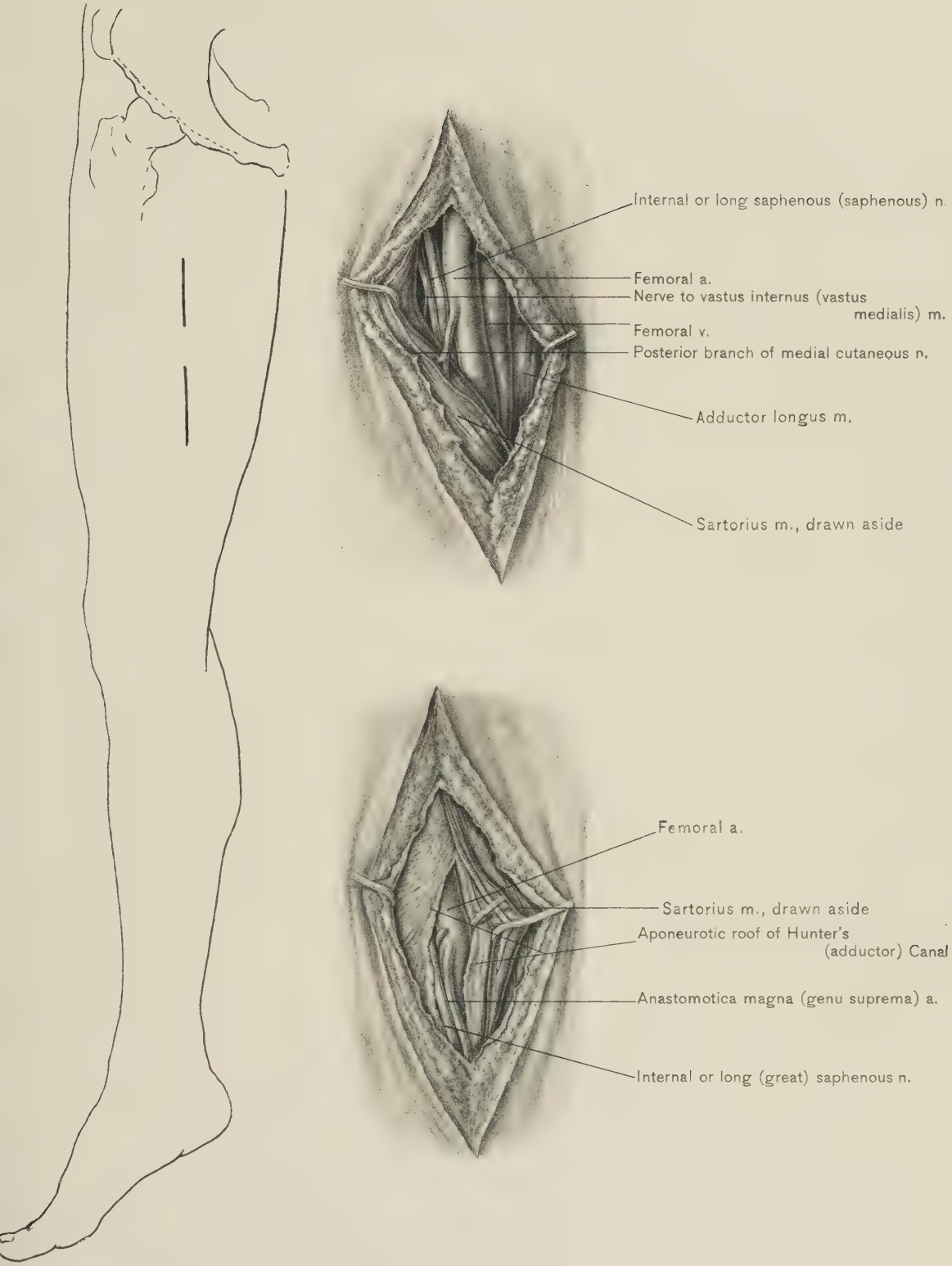
Internal or long saphenous (saphenous) n.
Femoral a.
Nerve to vastus internus (vastus medialis) m.
Femoral v.
Posterior branch of medial cutaneous n.
Adductor longus m.
Sartorius m., drawn aside
Femoral a.
Sartorius m., drawn aside
Aponeurotic roof of Hunter's (adductor) Canal
Anastomotica magna (genu suprema) a.
Internal or long (great) saphenous n.

LIGATION OF FEMORAL ARTERY IN SCARPA'S (FEMORAL) TRIANGLE AND IN HUNTER'S (ADDUCTOR) CANAL.

In *ligating the superficial femoral artery at the apex of Scarpa's (femoral) triangle* an incision is made in the line of the artery, beginning about three and a half centimeters (one and a half inches) below the middle of Poupart's (*inguinal*) ligament and extending downward for about seven and a half centimeters (three inches). This brings the middle of the incision over the apex of the triangle. The incision divides the skin and superficial fascia, with twigs of the middle (*intermediate*) and internal (*medial*) cutaneous nerves, tributaries of the long (*great*) saphenous vein, and small arterial twigs from the external pudendal and superficial epigastric. The fascia lata is then incised in the same line as the original incision. This will expose the sartorius muscle at the lateral and inferior part of the wound, and the internal saphenous (*saphenous*) nerve and the nerve to the vastus internus (*vastus medialis*) muscle lying to the lateral side of the vessels. The muscle should be drawn lateralward, the sheath of the vessel opened, and the ligature passed from the medial to the lateral side. Great care should be exercised in passing the needle holding the ligature, in order to avoid wounding the femoral vein. The needle should hug the walls of the artery.

In *ligating the superficial femoral (femoral) artery in Hunter's (adductor) canal* the incision is made along the line of the artery, in about the middle of the thigh. The skin and superficial fascia are divided, with twigs of the middle (*intermediate*) and internal (*medial*) cutaneous nerves, and, at times, the internal (*medial*) cutaneous nerve itself. The long (*great*) saphenous vein will be seen in the medial part of the wound, and must be drawn medially. The fascia lata is then incised and the sartorius muscle, which forms the roof of the canal, fully exposed. The fibers of this muscle can be easily recognized by their downward and medialward direction. The muscle is drawn medially, when the artery can be observed entering the canal formed by the adductor magnus and the vastus internus (*vastus medialis*) muscles. The transverse fibers of the fascia covering the canal are divided and the sheath of the vessels exposed. The internal (*great*) saphenous nerve will be seen to the lateral side of the vessel. The ligature may be passed from either side.

The *collateral circulation* after the ligation of the superficial femoral (*femoral*) is carried on by the anastomoses formed by the perforating branches of the profunda and the anastomotica magna (*genu suprema*) of the femoral, with the articular (*genicular*) arteries of the popliteal and the recurrent branch of the anterior tibial.

Ligation of the Popliteal Artery.—The popliteal artery extends from the opening in the adductor magnus to the lower border of the popliteus muscle. It is on a level with the tubercle (*tuberosity*) of the tibia at its termination, where it divides into the anterior and posterior tibial arteries. It lies deep in the

popliteal space, being under the semimembranosus above and the gastrocnemius below. In the middle of the popliteal space it is ligated with difficulty, owing to its deep location, but in the superior or inferior part of its course it may be readily tied. The relations of the popliteal artery should be borne in mind. In front of it are the femur, from which it is usually separated by a small quantity of loose fat, the posterior part of the capsule of the knee-joint, and the fascia covering the popliteus muscle. It is crossed posteriorly by the popliteal vein and the internal popliteal (*tibial*) nerve, and it is covered, above, by the semimembranosus muscle; by fat in the middle of the space, and below by the gastrocnemius, plantaris, and soleus muscles. On the lateral side are the biceps femoris, the lateral head of the gastrocnemius, and the plantaris muscles, and on the medial side, the semimembranosus and the medial head of the gastrocnemius muscles. The relations of the artery to the vein and the internal popliteal (*tibial*) nerve are important. Above, the vein lies lateral and posterior to the artery; posterior to the joint it lies almost posterior to the artery, crossing it, to lie on its medial side in the distal part of the space. The internal popliteal (*tibial*) nerve lies on a plane posterior to the vessels and at first to their lateral side, crossing the artery below to lie on its medial side.

In *ligating the popliteal artery in its proximal part* the leg is flexed to a right angle, and an incision is made about seven and a half centimeters (three inches) long, beginning at the junction of the middle and distal thirds, and running parallel with the tendon of the adductor magnus. The incision divides the skin and superficial fascia with twigs from the internal (*medial*) and middle (*intermediate*) cutaneous nerves, and small branches of the sural and articular (*genicular*) arteries with their veins. Sometimes the anterior division of the internal (*medial*) cutaneous nerve may be exposed, and should be drawn to one side. The deep fascia is then divided and the sartorius muscle, the tendon of the adductor magnus, and the semimembranosus muscle exposed and drawn aside, and the artery located. The ligature is passed from either side, care being taken not to wound the deep branch of the anastomotica magna (*genu suprema*) artery, which lies on the anterior surface of the adductor tendon.

In *ligating the popliteal artery in its distal third* the leg is extended and an incision about seven and a half centimeters (three inches) long made over the artery, beginning at the center of the popliteal space. The skin and superficial fascia are divided, along with twigs of the small sciatic (*posterior cutaneous nerve of thigh*) and internal saphenous (*saphenous*) nerves, and small branches of the articular (*genicular*) and sural arteries with their veins. The external (*small*) saphenous vein and short saphenous (*sural*) nerve will be seen in the lateral part of the wound, and care should be taken not to wound them. They should

PLATE CCCXXXVI.

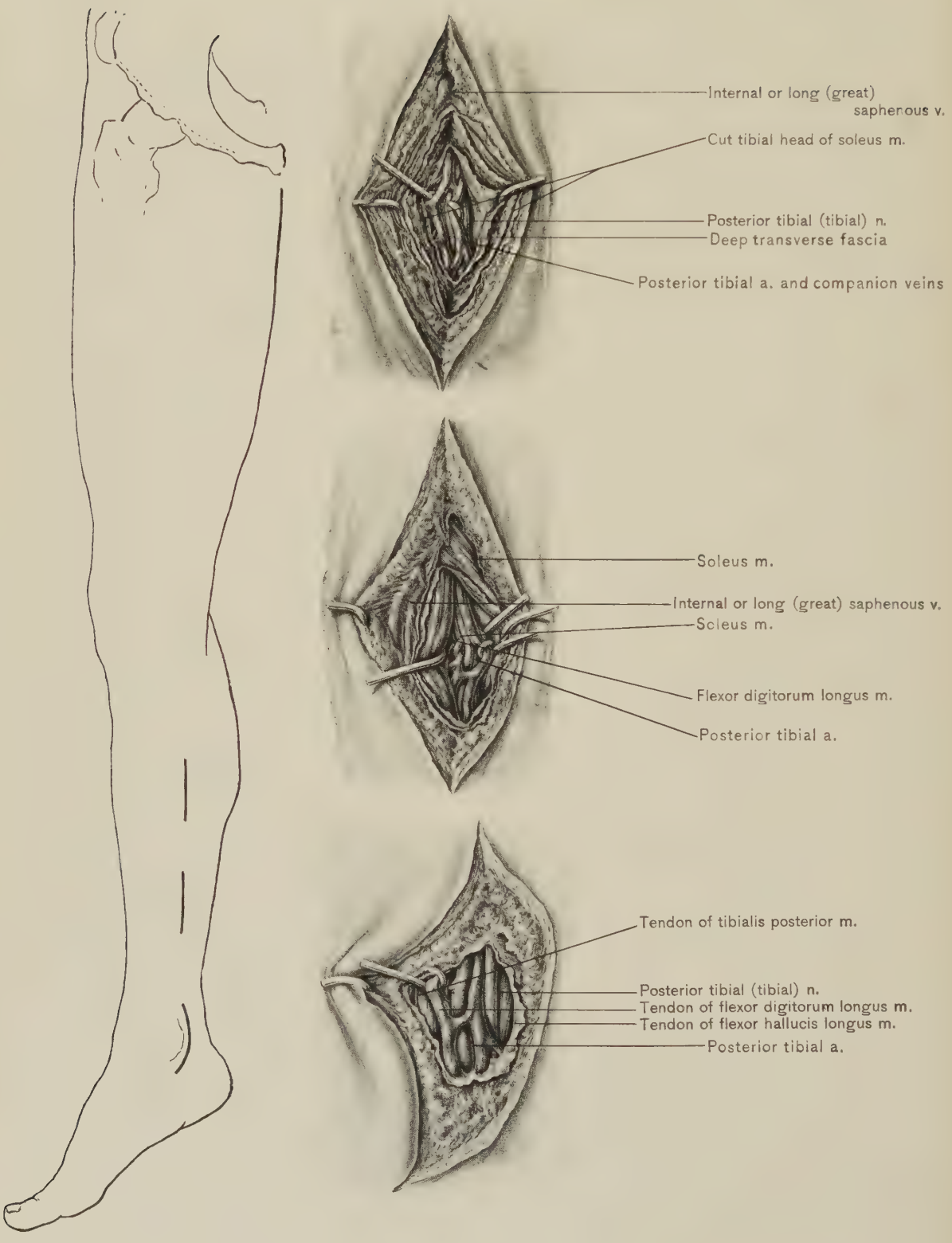
Internal or long (great) saphenous v.
Cut tibial head of soleus m.
Posterior tibial (tibial) n.
Deep transverse fascia
Posterior tibial a. and companion veins
Soleus m.
Internal or long (great) saphenous v.
Soleus m.
Flexor digitorum longus m.
Posterior tibial a.
Tendon of tibialis posterior m.
Posterior tibial (tibial) n.
Tendon of flexor digitorum longus m.
Tendon of flexor hallucis longus m.
Posterior tibial a.

LIGATION OF THE POSTERIOR TIBIAL ARTERY IN THE PROXIMAL, MIDDLE, AND DISTAL THIRDS OF THE LEG.

be drawn lateralward and the deep fascia divided. This will expose the heads of the gastrocnemius, between which will be found the popliteal artery. The two sural arteries will be seen on each side entering the heads of the gastrocnemius muscle. The external popliteal (*common peroneal*) nerve and the popliteal vein, overlying the artery, should be drawn to the medial side and the ligature passed from that side.

The *collateral circulation* after ligation of the popliteal artery will be carried on by the anastomoses formed between the inferior articular (*inferior genicular*) and the anterior tibial recurrent below, and the superior articular (*superior genicular*), the anastomotica magna (*genu suprema*), and the external (*lateral*) circumflex above.

Ligation of the Posterior Tibial Artery (Plate CCCXXXVI).—The posterior tibial artery extends from the lower border of the popliteus muscle to the deep concavity between the medial malleolus and the os calcis (*calcaneus*), where it divides into the two plantar arteries. In the proximal part of its course the artery lies on the tibialis posterior and flexor digitorum longus muscles, and in the distal part on the posterior surfaces of the tibia and the internal lateral (*deltoid*) ligament of the ankle-joint. The posterior tibial (*tibial*) nerve at first lies to the medial side of the artery, but soon crosses over the latter, and at the intermediate and distal part of the leg is found to the lateral side of the artery.

In *ligating the posterior tibial artery in its proximal third* the leg is flexed and laid on its lateral side. An incision about seven and a half centimeters (three inches) long is then made along the medial edge of the tibia. The skin is divided with the superficial fascia, great care being taken to avoid the internal (*great*) saphenous vein and nerve, both of which lie in the line of incision. They should be drawn to one side. The deep fascia is then incised and the origin of the soleus muscle brought into view. This muscle should be detached from the tibia; if the soleus has not been fully recognized, there is danger of missing the vessel by going through the interspace between the heads of the gastrocnemius and thus going behind the vessel, or by detaching the tibialis posterior with the soleus, going in front of the artery. The under surface of the soleus presents a shining appearance, and a layer of fascia, the intermuscular septum, separates it from the tibialis posterior. On passing the finger toward the lateral aspect of the leg, the artery will be felt pulsating. The intermuscular septum should be incised in the line of the original incision and the vessel separated from the overlying connective tissue, the veins, and the nerve, and the ligature passed from the lateral to the medial side.

In *ligating the posterior tibial artery in its intermediate third* the incision is made in the middle of the leg over the medial edge of the tibia. The skin having

been divided, the internal (*great*) saphenous vein and nerve should be located and drawn aside, and the deep fascia then opened. The medial border of the soleus should be pushed aside, and the artery will then be found with the veins and the posterior tibial (*tibial*) nerve to its lateral side. The artery should be separated from the vein and nerve, and the ligature passed from the lateral to the medial side.

In *ligating the posterior tibial artery at the ankle* the incision should be semicircular in shape, and should be made midway between the medial malleolus and the os calcis (*calcaneus*). The skin and superficial fascia are divided, with twigs of the calcaneal nerve, and small branches of the internal (*medial*) plantar artery. The deep fascia should be carefully incised and the vessel exposed. To its lateral side will be found the tendons of the tibialis posterior and flexor digitorum longus muscles, and to its medial side the posterior tibial (*tibial*) nerve and the tendon of the flexor hallucis longus. The accompanying veins lie on either side. They should be separated from the artery and the ligature passed from without medialward.

Ligation of the Peroneal Artery.—The peroneal artery arises from the posterior tibial about two and a half centimeters (one inch) below the lower border of the popliteus muscle, and, after passing to the lateral side of the leg, runs downward along the posterior medial surface of the fibula and at the distal third of the leg it pierces the interosseous membrane as the anterior peroneal artery. Throughout most of its course the vessel lies within the substance of the flexor hallucis longus muscle, and is covered by the fibular origin of the soleus.

In *ligating the peroneal artery* the incision should be made over the lateral border of the fibula, on a level with the fibular origin of the soleus muscle. The incision divides the skin and superficial fascia, with twigs from the cutaneous branch of the internal popliteal (*tibial*) nerve, and some tributaries of the internal (*great*) saphenous vein. The deep fascia is then incised and the origin of the soleus exposed. The muscle is separated from the bone and the fibers of the flexor hallucis longus are brought into view. These fibers and the intermuscular septum should be divided, and the artery will then be found lying in the angle formed by the junction of the intermuscular septum with the fibula. The ligature may be passed from either side.

Ligation of the Anterior Tibial Artery (Plate CCCXXXVII).—The line for the anterior tibial artery, which closely corresponds to the general course of that vessel, is drawn from a point midway between the tubercle (*tuberosity*) of the tibia and the head of the fibula, to the middle of the intermalleolar space in front. The artery passes above the intermuscular septum at the lower border of the popliteus muscle to reach the anterior aspect of the leg. In the proximal

PLATE CCCXXXVII.

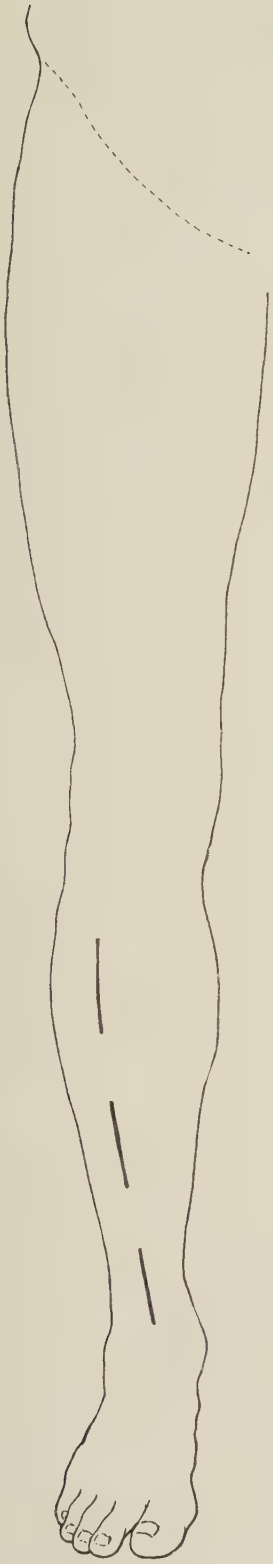



LIGATION OF ANTERIOR TIBIAL ARTERY IN THE PROXIMAL, MIDDLE, AND DISTAL THIRDS OF THE LEG

third of its course the anterior tibial artery lies between the tibialis anterior and the extensor digitorum longus muscles and rests upon the interosseous membrane. In the middle of the leg the artery is in relation with the tibialis anterior on its medial side and the extensor hallucis longus on its lateral side. In the distal third of its course, just above the ankle, it lies between the tendon of the extensor hallucis longus on the medial side, and the tendon of the extensor digitorum longus on the lateral side. The anterior tibial (*deep peroneal*) nerve lies to the lateral side of the artery above, in front of it in the middle of the leg, and again to its lateral side below.

In *ligating the anterior tibial artery at its proximal third* an incision is made over the course of the artery, beginning on a level with the head of the fibula. The incision divides the skin and superficial fascia together with twigs from the internal saphenous (*saphenous*) nerve and tributaries of the internal (*great*) saphenous vein. The intermuscular space between the tibialis anterior and the extensor digitorum longus muscles is to be located and the deep fascia then divided. The muscles should be separated, and the artery will be found lying on the interosseous membrane, the veins being on each side and the nerve (*deep peroneal*) to the lateral side. The artery should be separated from the veins and nerve (*deep peroneal*), and the ligature passed from the lateral to the medial side.

In *ligating the anterior tibial artery in its intermediate third* an incision about seven and a half centimeters (three inches) long should be made over the course of the vessel. The skin and superficial fascia, with twigs of the internal saphenous (*saphenous*) nerve and tributaries of the internal (*great*) saphenous vein, will be divided. After dividing the deep fascia the tibialis anterior and the extensor digitorum longus muscles should be separated, and the extensor hallucis longus will be seen lying between them. This muscle should be separated from the tibialis anterior, and the artery will be found between the two, with the veins and nerve (*deep peroneal*) in the same relative position as in the proximal third, except that the nerve may be more anterior. The ligature should be passed from without medialward.

In *ligating the anterior tibial artery in its distal third* an incision about five centimeters (two inches) long should be made over the line of the vessel, beginning about seven and a half centimeters (three inches) above the tibio-tarsal articulation. The skin and superficial fascia will be divided, with twigs from the internal saphenous (*saphenous*) and musculo-cutaneous (*superficial peroneal*) nerves, and tributaries of the internal (*great*) and external (*small*) saphenous vein. The second tendon from the crest of the tibia, the tendon of the extensor hallucis longus, should then be located and the deep fascia opened to its lateral side.

The space between the tendons of the extensor hallucis longus and the extensor digitorum longus should be enlarged, when the artery will be found in this space, with the nerve to the lateral side. The ligature should be passed from without medialward.

Ligation of the Dorsalis Pedis Artery.—The line of the dorsalis pedis artery is from a point midway between the two malleoli to a point midway between the anterior extremities of the first and second metatarsal bones. Its course is over the first interosseous space.

In *ligating the dorsalis pedis artery* the incision should be made over the artery. The skin and superficial fascia will be divided, with twigs of the anterior tibial (*deep peroneal*) and musculo-cutaneous (*superficial peroneal*) nerves, and tributaries of the internal (*great*) and external (*small*) saphenous veins. The deep fascia is then divided, and the artery found to the medial side of the medial tendon of the extensor digitorum brevis. The ligature should be passed from without medialward.

THE THORAX

The **Thorax,** or chest, is that portion of the trunk which lies between the neck and the abdomen. It resembles in shape a truncated cone being small above and large below, flattened in front and behind, but rounded laterally. In transverse section it may therefore be said to be shaped like the kidney. The right side is often the larger, owing to the more frequent use of the right hand. The thorax is bounded in front by the sternum and the costal cartilages; on either side by the shafts of the ribs; behind by the bodies of the thoracic, or dorsal, vertebræ, the intervertebral discs, and the heads and necks of the ribs. The intercostal spaces or intervals between the ribs are closed by the external and internal intercostal muscles. The anterior thoracic wall is shorter than the posterior, the upper margin of the manubrium sterni, after expiration, being on a level with the second thoracic intervertebral disc, while the lower end of the gladiolus, or body, of the sternum is on a plane with the middle of the ninth dorsal vertebra.

The thorax has a **superior** and an **inferior opening**; a **vertical,** a **transverse,** and an **anteroposterior diameter.** In a plane passing through its transverse and anteroposterior diameter it is kidney-shaped. The forward projection of the bodies of the dorsal vertebræ greatly diminishes the anteroposterior diameter of the thorax in the median plane, but to either side of the spinal column a deep hollow is formed by the backward, lateralward, and forward curve of the ribs. This hollow accommodates the thick portion of the lungs. The anteroposterior diameter is much increased in Pott's disease, involving the dorsal spine, in which

the kyphosis and shortening of the spinal column causes the sternum to protrude and bend.

The **superior aperture of the thorax,** or **thoracic inlet,** is much smaller than the inferior, or outlet, its anteroposterior diameter being about five and seven-tenths centimeters (two and a quarter inches.) It is bounded anteriorly by the manubrium sterni and the first costal cartilage; behind, by the body of the first dorsal vertebra and the head and neck of the first rib; on either side, by the first rib. The plane of this opening slopes obliquely from behind forward. Owing to this obliquity structures which enter or leave the thorax at its anterior part do so at the level of the second thoracic intervertebral disc. Thus the lower part of their cervical course is opposite the first and second thoracic vertebræ. It is closed by the structures which pass through it—namely, the sterno-hyoid, sterno-thyroid, and longus colli muscles; the innominate and inferior thyroid veins; the left recurrent laryngeal nerve, the phrenic and vagus nerves, the gangliated trunks of the cervical sympathetic nerves, the cervical cardiac branches of the vagus and sympathetic nerves and the anterior branch of the first thoracic nerve; the innominate, left common carotid, left subclavian, internal mammary, and superior intercostal arteries, and the thyroidea ima artery, when present; the thymus gland, or its shrunken remains; the esophagus, trachea, pleura, apices of the lungs, and the thoracic duct and the lamella of deep cervical fascia which lies upon the trachea, and is continuous with the fibrous layer of the pericardium.

The **inferior aperture,** or **thoracic outlet,** is much wider than the superior and is bounded in front by the ensiform cartilage (*xiphoid process*) of the sternum; behind, by the body of the twelfth dorsal vertebra and the head and neck of the last rib; on either side, by the chondral arch, the twelfth rib and part of the eleventh. The margin of the inferior opening extends at first lateralward and downward and backward along the lower costal margin to the tip of the eleventh rib. From there it passes upward, backward, and medialward along the last rib to the vertebral column. Its plane is therefore obliquely downward and backward. Its anteroposterior diameter is about fourteen and a quarter centimeters (five and three-eighths inches). It is occluded by the diaphragm, the arched floor of the chest, which divides the thoracic from the abdominal cavities, and by the structures which pass through the diaphragm. The structures piercing the diaphragm are as follows: through the esophageal opening, the esophagus, vagus nerves, and the esophageal branches of the coronary (*left gastric*) artery and of the thoracic aorta; through the caval opening (*foramen for vena cava*), the inferior vena cava, branches of the right phrenic nerve and some of the hepatic lymphatics; through the aortic opening, the aorta, thoracic duct, vena azygos major (*vena azygos*), and two descending lymph trunks from the

intercostal glands. The less important structures which piece the diaphragm are as follows: the superior epigastric vessels which pass between slips from the ensiform (*xiphoid*) and the seventh costal cartilage; the musculo-phrenic vessels pass between slips from the seventh and eighth costal cartilages; the last five intercostal nerves with their accompanying vessels which pass between slips from the seventh to the twelfth costal cartilages; the last thoracic (*subcostal*) nerve and vessels pass behind the external arcuate ligament (*lateral lumbo-costal arch*); the sympathetic trunk behind the internal arcuate ligament (*medial lumbo-costal arch*); the splanchnic nerves, greater and lesser, pierce the crus, while the vena azygos minor inferior (*hemiazygos*) pierces the right crus.

The diameters of the chest at different levels in the average male skeleton are as follows: The **anteroposterior diameter,** at the inlet, is five and a half centimeters (two and one-fourth inches); at the junction of the manubrium and body, eleven and two-tenths centimeters (four and one-half inches), and at the outlet fourteen and twenty-five-hundredths centimeters (five and three-eighths inches). The **transverse diameter** at the inlet measures eleven centimeters ((four and three-eighths inches); between the second ribs, seventeen and a half centimeters (seven inches); between the third ribs, twenty and three-tenths centimeters (eight and one-eighth inches); gradually increasing between the succeeding ribs, it attains its maximum between the ninth ribs, where it measures twenty-six and six-tenths centimeters (ten and five-eighths inches), and gradually diminishes below that level. The **vertical diameter of the chest** is increased by the contraction and descent of the diaphragm which depresses the abdominal contents and pushes the abdominal wall outward. Expansion of the chest in its anteroposterior and transverse diameters is caused by elevation and lateral rotation of the ribs. If, on measuring the circumference of the chest at the level of the nipple, a maximum expansion on inspiration of seven and a half centimeters (three inches) is found, it is considered normal. By bringing into action the accessory muscles of respiration, the expansion of ordinary respiration, which varies from three and one-fifth centimeters (one and one-fourth inches) to five centimeters (two inches), can be almost doubled.

In the **fetus** the anteroposterior diameter of the thorax is greater than the transverse diameter. In infancy these diameters are about equal, but as growth occurs the transverse diameter increases more rapidly than the anteroposterior diameter.

The **female thorax** differs from that of the male in having a smaller capacity, a shorter sternum, a superior aperture which is larger in proportion to the inferior, and more movable upper ribs. This freedom of movement in the upper chest is of advantage in advanced pregnancy, when the enlarged uterus restricts the

descent of the diaphragm. The female thorax also differs from that of the male in having larger mammary glands attached to it. In the virgin the mammæ are firm, and project from the chest-wall. Those of the woman who has borne and nursed children are flaccid and pendent.

Among the various forms of the chest may be mentioned the normal, the flat, the "barrel-shaped," and the "pigeon-breasted."

In the **normal chest** the anteroposterior diameter is considerably shorter than the transverse, the latter being one-fourth greater, the ribs slope downward and forward, and the subcostal angle is about equivalent to a right angle.

The **flat chest** has a short anteroposterior and a comparatively long transverse diameter. The ribs slope downward and forward much more sharply than in the normal chest, and the subcostal angle is less than a right angle. It is hereditary, and is especially seen in persons predisposed to, or suffering from pulmonary tuberculosis. A person with a flat chest need not necessarily become tuberculous, although this type of chest is frequently called the "phthisical chest."

The **"barrel-shaped" chest** is short and round, due to elevation of the ribs. Its anteroposterior diameter is nearly as long as its transverse diameter. The ribs are almost horizontal, and the subcostal angle is greater than a right angle. It is the result of emphysema.

"Pigeon-breast" is a term applied to a chest of which the sternum and costal cartilages project forward beyond the ends of the ribs. The anteroposterior diameter is long, and the transverse is short. It is one of the results of rachitis, or rickets. In these cases there is usually a thickening at the junction of the ribs with their cartilages; a beaded appearance is thus produced, and the term "rachitic rosary" has been applied to the condition. From the level of the ensiform (*xiphoid*) cartilage a groove may be seen to pass lateralward in these cases. This is known as **"Harrison's Groove."**

Occasionally there is found a considerable depression at the lower end of the sternum; at the bottom of this depression lies the ensiform cartilage. Such a condition is the result of a developmental defect, and is known as the **"funnel-breast."** An analogous condition may be produced by prolonged pressure in certain occupations ("shoemaker's breast").

The "barrel-shaped" or emphysematous chest is irremediable, as it is due to permanent distention of the air vesicles of the lungs. In young individuals both the flat and "pigeon-breasted" chests may be much improved by suitable gymnastic exercises.

Unilateral changes may also be found. A pleural effusion or tumors, either of the lungs, or bony framework, will cause more or less bulging of the affected side. Retraction of one side may be brought about by phthisis, or by collapse

of the lung. Extreme retraction will produce lateral curvature (scoliosis) of the spine, the convexity of the curve being directed toward the sound side. In scoliosis, or lateral curvature, of the spine there is a compression of the thorax from above downwards. A twisting around the vertical axis also occurs, and the deformity may cause the lower ribs to rest on the crest of the ilium.

Surface Anatomy of the Thorax and Relation of Contents to the Surface.—The upper margin of the sternum corresponds to the cartilaginous disc between the second and third dorsal vertebræ. The junction of the manubrium with the body of the sternum, or gladiolus, is marked by a transverse ridge which is called the **sternal angle,** or **angulus Ludovici.** The second costal cartilages articulate with the sternum at that point. This is opposite the fifth thoracic vertebra. In fractures at the *sternal angle,* the lower fragment is usually displaced anteriorly. The trachea bifurcates at this level and the right and left pleural sacs are here adjacent. The depression over the lower end of the sternum or xiphoid cartilage is called the *scrobiculus cordis,* or "pit of the stomach." This is opposite the seventh costal cartilages, and corresponds to the ninth dorsal vertebra behind.

The **sterno-clavicular junction** is prominent. Behind it on the right side lie the innominate artery, the right innominate vein, and the right pleural sac; behind it on the left are the left innominate vein, the left carotid artery, and the left pleural sac. The sterno-clavicular joint, a universal joint, is quite mobile and forms the chief means of uniting the upper extremity to the trunk. Dislocation of the clavicle at this point sometimes occurs. It may take place forward, backward, or upward, in this order of frequency. The rhomboid (*costo-clavicular*) ligament limits excessive displacement in cases of luxation.

The **acromio-clavicular joint** is a firm articulation, owing to the conoid and trapezoid ligaments. Dislocation of the clavicle may take place at this joint; it is usually upward in direction owing to the beveling of the apposed surfaces of bone.

It is frequently necessary to count the ribs. This is readily done in lean persons, but in fat people it is difficult. Still, certain ribs may be located in any individual. The **first rib** lies immediately beneath the clavicle. The **second rib** is identified by the prominent ridge which marks the line of junction of the manubrium with the gladiolus (*body of the sternum*), at which point the costal cartilage of this rib joins the sternum. The **fourth interspace** is marked by the nipple in the male, so the fourth rib forms the upper boundary of this interspace. The course of the **fifth rib** is marked by the inferior margin of the great pectoral muscle. A line drawn horizontally around the chest over the nipple on the male chest intersects the **sixth interspace** midway between the anterior and posterior median lines. When the arm is raised, the **sixth rib** is marked by the highest visible

PLATE CCCXXXVIII.

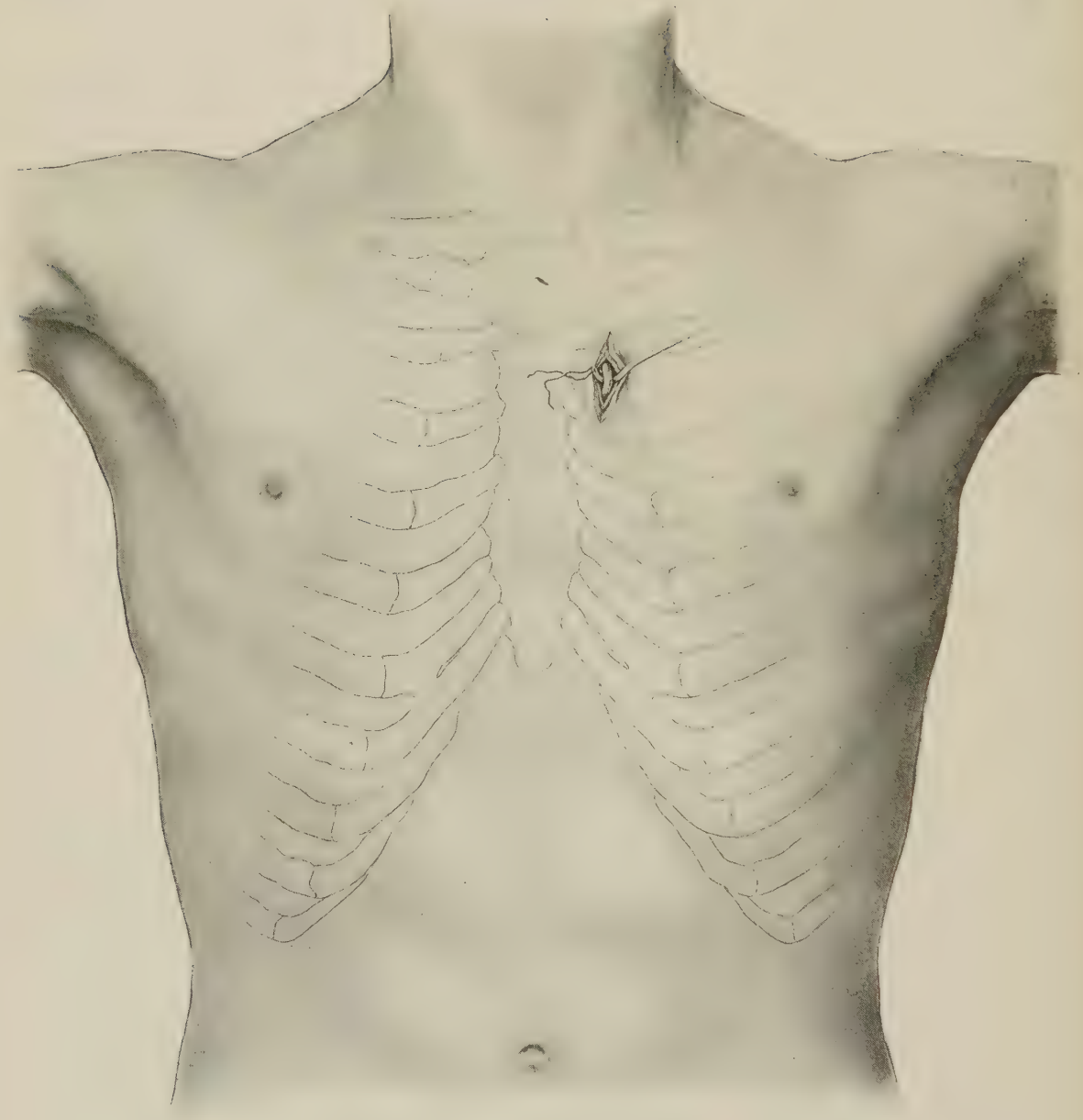

LIGATION OF INTERNAL MAMMARY ARTERY.

digitation of the serratus magnus (*serratus anterior*) muscle; each succeeding digitation indicates the next lower rib. The position of the scapula between the **second** and **seventh ribs** in the ordinary position of the shoulder is a useful, though variable, index. The **last two ribs** are readily felt, except in very corpulent individuals. The kidneys lie in front of them, the right kidney being located lower than the left owing to the presence of the liver on the right side.

From the vertebræ the ribs slope downward and forward. The anterior end of each rib is on a level with the third vertebra below the one with which it articulates. This is a general rule, subject to variations depending upon changes in the size and shape of the sternum.

The **delto-pectoral groove** lies below the clavicle and between the deltoid and the clavicular portion of the pectoralis major muscle. Into it passes the cephalic vein to join the axillary vein beneath the clavicle; from it emerges the descending (*deltoid*) branch of the acromio-thoracic (*thoraco-acromial*) artery; both traverse the delto-pectoral groove. Except in very muscular individuals, the medial side of the coracoid process of the scapula can be felt projecting from under the deltoid into the lateral part of this depression when the arm is abducted. It is, therefore, possible to determine whether or not the process is fractured. Through this interval the axillary artery may be compressed against the second rib.

Behind the **manubrium sterni** there is usually no lung tissue. This part of the chest is occupied as follows: the remains of the thymus gland lie immediately behind the manubrium; the left innominate vein crosses behind the latter just below its upper border; the innominate, the left common carotid, and the left subclavian arteries, branches of the transverse portion of the aortic arch, come next; the trachea and its division into the primary bronchi lie behind these, and the esophagus is back of all. The left recurrent laryngeal (*recurrent*) nerve is in the groove between the esophagus and the trachea. The highest part of the aortic arch is about two and a half centimeters (one inch) below the upper margin of the sternum. The remains of the thymus gland lie nearest the sternum, in front of the other structures named.

The **innominate artery** extends from above the middle of the junction of the manubrium and gladiolus (*body of the sternum*) to the right sterno-clavicular joint. The artery is posterior to the sterno-hyoid and sterno-thyroid muscles and the thymus. The artery passes from the anterior to the right lateral surface of the trachea.

The **internal mammary artery** (Plate CCCXXXVIII) lies behind the costal cartilages parallel to, and twelve millimeters (a half inch) from the margin of the sternum. It gives off a perforating branch to each interspace, that to the second being the longest. The internal mammary artery can be ligated in almost any

interspace, but the second is preferably selected for that purpose. The pericardiophrenic branch of the internal mammary artery accompanies the phrenic nerve into the thorax. The internal mammary vein ends in the innominate vein.

In **viewing the thorax from behind,** the surface markings of the back, as described with the "Surface Anatomy of the Back," are seen. In the floor of the median furrow the spines of the vertebræ can be felt. On each side of the furrow the muscles of the erector spinæ group are located. The spinous process of the seventh cervical vertebra is particularly prominent and is known as the "vertebra prominens." As these spines slope downward and backward, their tips are on a lower plane than the bodies of the corresponding vertebræ. The external curve formed by the spinous processes in the thoracic region is not so marked as the curve formed by anterior portion of the bodies of the thoracic vertebræ. The spines in the upper and lower dorsal regions project out nearly at a right angle while those in the middle portion project downward. Thus the spines of the seventh cervical and the first and twelfth thoracic are opposite the bodies of the respective vertebræ, while the others are opposite the bodies of the vertebrm below. Slight frictional strokes will cause red spots to appear over the tips of the spines. The latter can also be made more prominent by bending the body forward. The third dorsal spinous process is opposite the vertebral end of the scapular spine, and corresponds to the highest point attained by the aorta in front of the vertebral column, to the bifurcation of the trachea, and to the apex of the lower lobe of the lungs. Opposite the fourth dorsal spine the aortic arch ends, and there the upper margin of the heart is located; the seventh dorsal spinous process corresponds to the lower angle of the scapula; opposite the eighth are the lower level of the heart and the central tendon of the diaphragm; opposite the ninth, the vena cava and esophagus pass through the diaphragm, on a level with the top of the spleen; opposite the tenth is the lower edge of the lung, the liver becomes superficial behind, and we have the cardiac opening of the stomach; the twelfth indicates the lowest part of the pleura, the aortic opening of the diaphragm, and the pylorus of the stomach. In operations in the lumbar region care must be exercised not to carry the incision too high since the pleura may be opened along the lower margin of the twelfth rib.

The **primary bronchi** are indicated by lines extending from the third thoracic spine, or a point a little below it, to the dimple in the skin over the root of the scapular spine. As the right bronchus is nearer to the back of the chest, sounds in it are heard more clearly.

For the purpose of locating and describing pathologic conditions of the thoracic contents, the clinician makes use of certain lines, and also applies certain names to the various regions of the chest-wall:

PLATE CCCXXXIX.

POSITION OF THE HEART AND LUNGS.

The **sternal line** is drawn along the lateral border of the sternum. The **mid-sternal line** is the median line of the sternum. The **parasternal line** extends midway between the sternal line and the line of the nipple, the **mammillary, or mid-clavicular, line.** The **axillary,** or **midaxillary, line** is a line dropped vertically from the highest portion of the axilla. The **anterior** and **posterior axillary lines** are dropped vertically from the point of junction of the anterior and posterior axillary folds with the chest-wall. The **scapula line** is one drawn vertically, passing through the inferior angle of the scapula. The names applied to the various regions of the chest are self-explanatory; thus, we speak of the **infraclavicular fossa,** the **sternal, mammary,** and **inframammary regions,** the **lateral thoracic region,** the **supraspinous,** or **suprascapular, region,** the **infrascapular region,** etc.

The **position of the heart** (Plates CCCXXXIX and CCCXL) can be indicated by lines drawn on the surface. From a point (*A*) on the right third costal cartilage, twelve millimeters (half an inch) from the border of the sternum, draw a line to a point (*B*) in the second interspace on the left side, two and a half centimeters (one inch) from the sternal margin, to locate the base. From a point (*C*) in the fifth interspace, two and a half centimeters (one inch) to the medial side of, and five centimeters (two inches) below the left nipple, draw another line along the lower end of the gladiolus (*body of the sternum*) to a point (*D*), twelve millimeters (half an inch) beyond the right border of the sternum, in the fifth interspace, to define the margin of the right ventricle as it rests upon the central tendon of the diaphragm. Connect the point (*A*) with (*D*) to indicate the right border of the heart. Join (*B*) and (*C*) to find the left margin of the heart. The corners of this space should be rounded; that near the nipple should be the sharpest, and the right lower angle the least so. The left upper angle marks, approximately, the position of the left appendix auriculæ. A needle passed through the second right interspace would strike the sinus of the aorta; through the first right interspace the needle would enter the superior vena cava; in both instances the instrument would first traverse the anterior fringe of the lung. The points for aspiration of the pericardium are found in the fourth interspace at the left border of the sternum; in the fourth interspace two and a half centimeters (one inch) from the left sternal margin; or in the fifth interspace, four centimeters (one and a half inches) from the left sternal border. A very large effusion can be advantageously reached in the left xipho-costal angle.

The **region of precordial dulness** corresponds to that portion of the heart uncovered by lung tissue and in contact with the anterior chest wall. The area of absolute cardiac dulness begins opposite the left fourth costal cartilage and from here extends along the sternum, between the median line and the left edge to a point opposite the sixth left costal cartilage where the liver dulness begins.

To the left the line passes with lateral convexity from the fourth left costo-sternal junction to the apex of the heart. This area may be increased in cardiac hypertrophy or in pericardial effusion.

The **apex-beat of the heart** is usually in the left fifth interspace, three and eight-tenths centimeters (one and a half inches) below, and two centimeters (three-fourths of an inch) to the medial side of the nipple. But this varies with changes in the position of the body and during deep respiration; it descends in inspiration. Its changes, due to altered positions, can readily be studied upon himself by any individual. The apex-beat is very distinct while lying upon the left side; it is slightly noticeable when the body reclines upon the right side, and is more perceptible when the person rests upon the back.

Location of the cardiac valves.—(Plate CCCXL) The *aortic semilunar valve* is found behind the sternal end of the third left intercostal space. It is below and to the right of the pulmonary valve and above and to the left of the mitral valve. The *pulmonary semilunar valve* is a little above, behind the third left chondro-sternal junction. It lies highest on the sternum and is also the most superficial. The *tricuspid valve* is placed behind the middle of the sternum at the level of the fourth intercostal space. It lies obliquely, beginning at the third left intercostal space and ending at the fifth right intercostal space. The *mitral*, or *bicuspid, valve* is situated behind the fourth left costal cartilage at the left border of the sternum. It lies nearly transversely. Since the cardiac valves are covered by the anterior margin of the lung, their sounds can be more distinctly heard if breathing is suspended.

The **lungs** extend from three and eight-tenths centimeters (one inch and a half) to five centimeters (two inches) above the first rib, and are covered by the pleura and by a portion of the cervical fascia (Sibson's fascia). The subclavian arteries arch over the apex of the lung on either side. They are higher in women than in men. Behind the middle piece of the sternum, between the levels of the second and fourth cartilages, they approach the median line by a thin border. The lungs gradually diverge below the fourth cartilage to follow the chondral margin. The anterior margin of the left lung is notched to accommodate the heart. The margin of the right lung descends in almost a straight line to the sixth chondro-sternal junction. The lungs extend downward as far as the sixth rib, in the mid-clavicular line; as low as the eighth rib in the axillary line, and down to the tenth rib posteriorly in the line of the inferior angle of the scapula (the arms being held close to the sides.) The lower pulmonary margins descend about four centimeters (an inch and a half) in deep inspiration.

The left lung has one fissure and two lobes, while the right lung has two fissures and three lobes. The relation of these fissures to the chest-wall are

PLATE CCCXL.

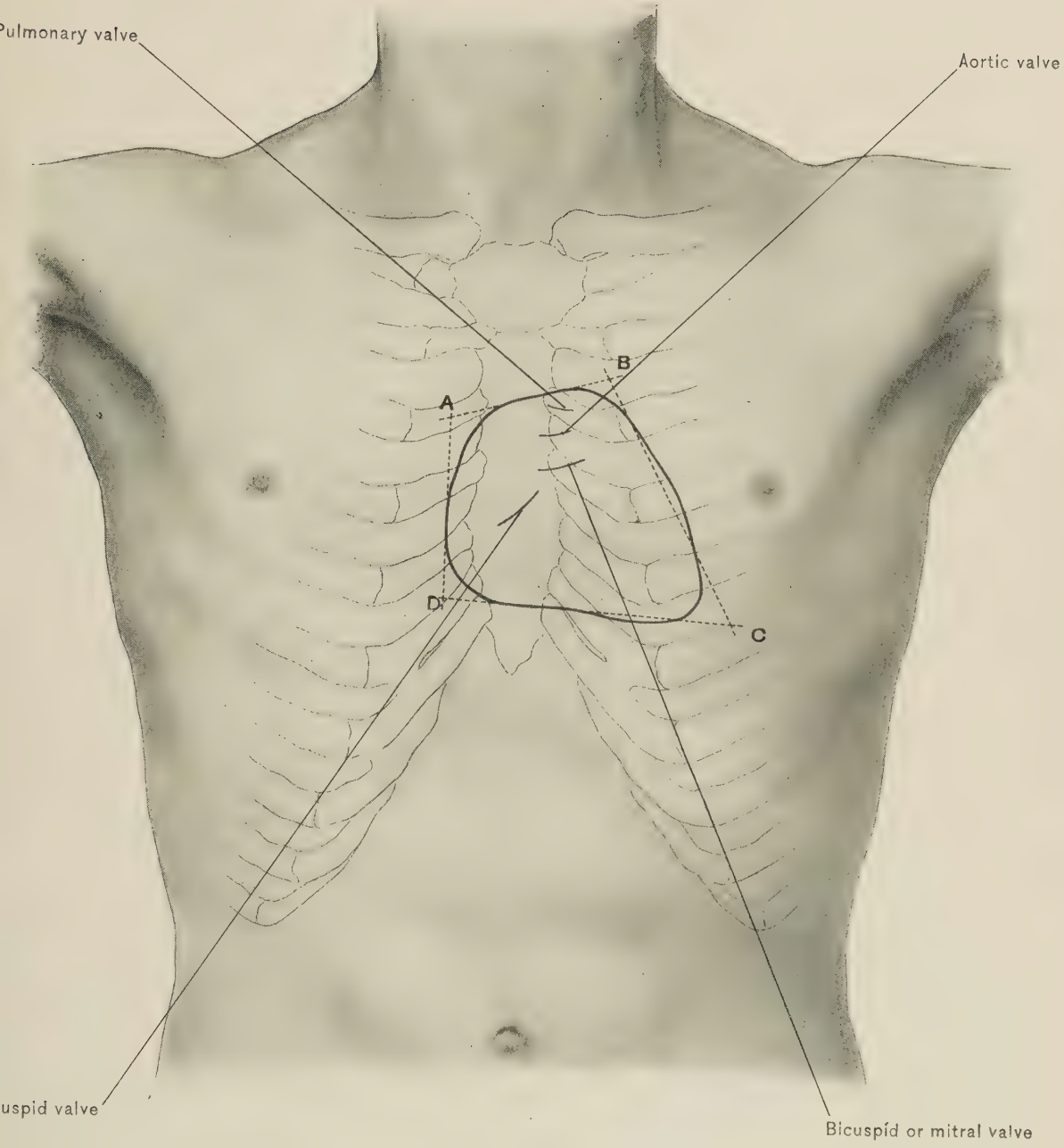

DIAGRAM OF POSITION OF HEART AND LOCATION OF CARDIAC VALVES.

PLATE CCCXLI.

POINTS FOR ASPIRATION OF PLEURA AND PERICARDIUM.

somewhat variable, the right main fissure being somewhat lower than the left posteriorly. The *fissures* dividing the lungs into lobes can be marked as follows: the great fissures can be outlined generally by drawing lines from the second dorsal spinous process, which corresponds to seven and a half centimeters (three inches) below the apex of the lung, downward and forward to the junction of the sixth rib with its cartilage. It crosses the fifth rib in the axillary line and may end anywhere in the region of the parasternal line on the left, while on the right it ends near the mid-clavicular line. On the right side a second fissure extends from the middle of the preceding line to the fourth chondro-sternal junction. Thus it is seen that the left lung is divided into two, the right into three lobes. The lower lobes form almost the entire posterior surface of the lungs and the upper lobes almost the entire anterior surface.

The **pleural sac** (Plate CCCXLI) can be aspirated in the seventh interspace in the midaxillary line, for the purpose of withdrawing fluid, or in the eighth interspace to the lateral side of the inferior angle of the scapula.

Behind the manubrium sterni the pleural sacs are separated by an angular interval, but behind the upper portion of the gladiolus (*body of the sternum*) they are contiguous. The right may even overlap the left pleural sac at this point. At the level of the fourth chondro-sternal junction the pleuræ diverge, the right being continued downward to the seventh costal cartilage in almost a straight line; the left deviates laterally at the level of the second costal cartilage and a little to the left of the midline.

The line of the left pleura is traced from the fourth chondro-sternal junction, at first lateralward and downward across the fourth interspace at a variable distance from the mid-sternal line, leaving a small triangular portion of the pericardium thus exposed. It is then continued downward across the fifth cartilage, fifth interspace, and sixth cartilage, usually close to the margin of the sternum, from where it inclines obliquely downward and lateralward to reach the seventh costal cartilage. From there it passes across and along the seventh, eighth, ninth, and tenth ribs, reaching the latter midway between the spinal column and the sternum. The lower border of the left pleura is slightly below the plane of the right, extending to the lower border of the tenth rib in the midaxillary line. From this point the lower limit of the left pleura corresponds to that of the right. The pleura extends much lower down than the lung. Its lower margin on the right side reaches the seventh costal cartilage near the sternum and extends from there lateralward and downward and backward along the seventh costal cartilage; it reaches the ninth interspace in the midaxillary line. It crosses the tenth rib and is continued along the eleventh rib to the neck of the twelfth rib. Holden calls attention to the liability of a foreign body, like a musket-ball, after it has

entered the pleural sac, to fall or roll to its most dependent part, which corresponds to the vertebral extremity of the last rib, where it may be found and extracted. He also mentions the last interspace, at the lateral edge of the erector spinæ (*sacro-spinalis*) muscle, as favorable for drainage of the pleura, but cautions against the use of a trochar, as it might enter the abdomen through the diaphragm, and advises that a knife should be used, care being taken to cut below the middle of the space so as to avoid the intercostal artery. This method is hardly to be recommended. In many of the cases of empyema the costophrenic space is obliterated and drainage from this supposedly dependent position is not satisfactory.

THE THORACIC WALL

Dissection.—In the dissection of the upper extremity the skin and fasciæ, as well as the pectoral muscles, will have been removed. Along the sternum and costal cartilages will be noticed the remains of the pectoralis major muscle; laterally, the attachments of the pectoralis minor, serratus magnus (*serratus anterior*), external oblique, and latissimus dorsi muscles, and below, the rectus abdominis muscle. Above will be seen the subclavius and the scaleni muscles. Posteriorly are the muscles of the back. Remove these muscles with the exception of the scaleni muscles, and expose the intercostal spaces and the ribs. The lateral cutaneous branches of the intercostal nerves should be noted emerging between the serrations of the serratus magnus (*serratus anterior*) muscle, also the anterior cutaneous branches of the intercostal nerves and the perforating branches of the internal mammary artery as they pierce the origin of the pectoralis major muscle close to the sternal margin.

The **thoracic wall** is composed of bone, cartilage, muscle, membrane or fascia, nerves, vessels, and lymphatics. The thickness of the thoracic wall varies in different individuals, and this should be considered in physical examination of the chest. During respiration a decided movement of the chest-wall takes place, permitted by the rotation of the ribs, producing considerable alteration in the capacity of the thorax. The walls of the thorax, owing to the elasticity of the ribs and costal cartilages, are markedly yielding, especially in young subjects. This in a great measure prevents fractures and dislocations of the sternum and ribs.

The **sternum** is composed of three parts: manubrium, gladiolus (*body of the sternum*), and ensiform cartilage, or xiphoid process. These three portions are sometimes known as the presternum, mesosternum and metasternum, respectively. The sternum is developed in two halves and if these fail to unite a cleft sternum results, through which the motions of the heart may be observed. A transverse ridge (angle of Ludwig, or sternal angle) opposite the second costal

cartilage marks the junction of the manubrium and gladiolus (*body of the sternum*), and this is the most frequent seat of dislocation and fracture. The xiphoid process is usually perforated, but may be bifid. The xiphoid branches of the internal mammary arteries pass through the opening. The upper border of the manubrium presents the suprasternal, or interclavicular, notch, and becomes continuous on each side with the notch for the articulation of the sternal end of the clavicle. Laterally the sternum shows depressions or notches for articulation with the upper seven, or rarely eight, costal cartilages. The costal cartilage of the first rib is continuous with the manubrium, and therefore an exception to this. The sternum gives attachment to the following muscles: the pectoralis major, sterno-mastoid, sterno-hyoid, sterno-thyroid, rectus abdominis, internal intercostals, triangularis sterni (*transversus thoracis*), diaphragm, and transversalis (*transversus*) abdominis. These muscles by pulling against each other, as in bending the spine backward, may cause a fracture of the sternum. Fracture, however, rarely occurs, owing to the cancellous structure of the bone and the elasticity of the ribs and the costal cartilages which support it. In old age, when the cartilages have become ossified, the chest-wall no longer yields and the sternum is more liable to fracture. The sternum may be fractured by direct violence, but is most apt to be broken in injuries of the spinal column. Extreme forward and backward bending of the body will likewise cause fracture. The line of fracture is almost always transverse, and usually at the junction of the manubrium and gladiolus (*body of sternum*). Usually the manubrium stays in position and the gladiolus (*body of sternum*) is displaced anteriorly. This is fortunate, as marked posterior displacement of the upper fragment would result in tracheal obstruction, since the trachea bifurcates at this level. Dislocations sometimes occur at this junction in young subjects in whom these parts have not as yet united. The manubrium in such cases, as a rule, is kept in place by the clavicles and first ribs, and the gladiolus (*body of sternum*) glides in front of it.

Aneurysms of the ascending portion of the arch of the aorta by constant pressure will cause bulging of the thoracic wall and finally necrosis and absorption of the sternum or adjacent costal cartilages, and may then rupture externally through the skin overlying the part. Necrosis from other causes, such as gummatous change, is also observed; in fact, this is one of the most common situations for the presence of gummata. The bone, owing to its sponginess, may be penetrated by knife wounds. It may be trephined for draining mediastinal abscesses and pericardial effusions, although more satisfactory exposures for the latter are now at our disposal. (See page 181.) The sternum, however, has been split to permit of satisfactory exposures of the mediastinum or heart. The method of Duval-Barasty is the best of those recommended.

Congenital defects, such as clefts or openings, are sometimes observed in the sternum. These are usually so small as to be barely recognizable, but occasionally are of good size, allowing a view of the pulsating heart. The sternum may occasionally be entirely cleft; or the two sides, united only at the manubrium, may be separated below that point. Mediastinal abscesses may discharge or surface abscesses burrow through these clefts or openings. The sternum may undergo change in shape and position in persons whose occupation requires instruments to be pressed against the chest.

The **ribs** are flat, narrow, very much curved, elastic bones, united posteriorly to the thoracic vertebræ by ligaments and articulating anteriorly with the costal cartilages. They slope obliquely downward from behind forward, so that the tips are much below the heads of the corresponding ribs, a general rule being that the tip of a rib is on a level with the head of the fourth rib below it. The most oblique rib is the ninth. The upper seven or eight ribs, by means of their respective costal cartilages, are united to the sternum and are called "true ribs." The eighth, ninth, and tenth join the cartilage of the seventh rib, and the last two, called "floating ribs," are free at the tip, and may be readily palpated even in fat subjects. Occasionally one finds either a cervical rib or a lumbar rib. In counting the ribs it is best to begin with the second which is opposite the angle of Ludwig (*sternal angle*).

The lower border of each rib is grooved for the intercostal vessels and nerve, the vein being above the artery and the nerve below it. In hemorrhage from an intercostal artery it may be necessary to pass the ligature around the rib to compress the vessel. The groove on the lower border of the rib contains the vessels and nerve as far back as the angle of the rib, from which point they occupy the middle of the space.

Owing to the elasticity of the ribs and costal cartilages, these structures yield to pressure and are not readily broken. In old age, when the cartilages have become ossified, fractures of the ribs are more frequent, the ribs most frequently involved being the sixth, seventh, and eighth. The first rib is least liable to be broken, owing to its protected position.

Fractures of the ribs may be produced by direct violence, the fracture occurring at the point struck; this would tend to drive the fragments inward and injure the pleura and lung. Or they may be produced by indirect violence, force being applied at a point remote from the seat of fracture, as in a crush of the chest by heavy weights, causing such an increase in the curve of the ribs as to cause them to break. In such cases the direction of the fracture is usually outward and away from the pleura, but this is not always so. Displacements of the fragments and shortening of the ribs are rendered quite impossible by the intercostal

muscles that are attached to the ribs, unless several adjacent ribs are broken. Diseased or weak ribs may occasionally be fractured during violent fits of coughing or during parturition.

The ribs frequently deflect a bullet from its course, the latter then following the curve of the rib around the thorax under the skin.

In some affections of the pleural cavity, as empyema, the resection of one or more ribs may be necessary or the ribs may be spread after an intercostal incision.

The bodies of the thoracic vertebræ and the intervertebral discs, bound together by ligaments, form the thoracic wall behind. Caries of the vertebræ, as in Pott's disease, causes deformity of the spine, as well as of the sternum and ribs, and produces shortening of the body, often to such an extent that the lower ribs extend below the iliac crests.

Cervical Rib.—Occasionally the costal element of the seventh cervical vertebra may develop into a partially or fully formed rib. If the rib is long enough it may cause compression of the brachial plexus or subclavian artery as these structures pass over it. At times an adventitious ligament may pass from the tip of the cervical rib to the sternum or first rib. When the presence of the rib causes symptoms it may be excised. The incision for its removal begins at the posterior border of the sterno-mastoid muscle at its attachment to the clavicle and is carried upward and laterally to the anterior border of the trapezius, so as to make an angle of about 45° with the clavicle. The transverse cervical vessels must be ligated. The pad of fat anterior to the brachial plexus is freed at its lateral edge and retracted medially, thus exposing the plexus. The cervical fascia is then divided along the lateral edge of the plexus, which is separated from its floor so as to permit exposure of the rib. It is then retracted anteriorly. Care must be taken not to injure the plexus of veins about the vertebral artery or the artery itself.

Other Anomalies of the Ribs.—The number of ribs may not only be increased, but the twelfth rib may be excessively short and the first may even be incomplete. The eighth costal cartilage may have a direct attachment to the sternum. The second and third may be bifid at their extremities; the cartilages which spring from these two portions of the bone unite, as a rule, before reaching the sternum. A bicipital rib due to fusion of the first, second, and third ribs is sometimes present.

The **intercostal spaces,** the intervals between the ribs, differ in width; they are wider anteriorly than posteriorly and the upper spaces are wider than the lower. The third, second, and first are the widest, in this order; while the lowest four are the narrowest. These spaces are closed by the external and internal intercostal muscles, between which run the intercostal vessels and nerves. The action of these muscles during inspiration narrows the spaces by elevating and rotating the ribs.

The eleven interspaces between the ribs are filled with the external and internal intercostal muscles and the intercostal fasciæ or membranes (Plate CCCXLII). Between the two strata of muscles lie the intercostal vessels, nerves, and lymphatics.

The **external intercostal muscles** extend obliquely between adjacent ribs, their tendino-muscular fibers passing downward and forward, like those of the abdominal external oblique muscle, of which they are virtually continuations, intersected by osseous interruptions (the ribs). They *arise*, in each interspace, from the lower or lateral border of the upper rib (except the last), to be *inserted* into the upper border of the rib below (with the exception of the first), and extend anteriorly from the tubercle of the ribs to the ends of the ribs, beyond which point they are continued to the sternum as fibro-tendinous membranes, the **anterior intercostal membranes,** sometimes called the **external intercostal fasciæ,** or **interchondral membranes,** except in the last two interspaces, the muscles there extending to the tips of the last two ribs. The attachments of these muscles at the back of the chest are more readily seen from the inside of the cavity after its contents have been removed.

Relations.—The external intercostal muscles are covered by the pectorales major and minor, the serratus magnus (*serratus anterior*), the external oblique, the latissimus dorsi, the levatores costarum, the upward continuation of the erector spinæ (*sacro-spinalis*), the serratus posterior superior and inferior, the rhomboidei major and minor, and the trapezius muscles. By their deep surface they are in relation with the middle intercostal fascia which separates them from the internal intercostal and the infracostal muscles, and the intercostal vessels and nerves.

Dissection.—The external intercostal muscles and the external intercostal membranes should be severed along their attachment to the lower rib in the interspace in which they lie. They should then be reflected upward, care being taken not to injure the intercostal vessels and nerves that lie between the external and the internal intercostal muscles, covered by the middle intercostal fascia, which intervenes between the two strata of muscles. This should now be removed and the vessels and nerves exposed.

The **internal intercostal muscles** differ from the external in that their fibers run downward and backward. They extend from the edge of the sternum as far back as the costal angles, beyond which, to the costal tubercles, they are continued as the **posterior intercostal membranes,** or **internal intercostal fasciæ.** They *arise* from the medial surface of the upper rib, above the medial margin of the subcostal groove, to be *inserted* into the medial surface of the lower rib near its upper margin. In the last two interspaces these muscles are continuous with those of the abdominal internal oblique muscle.

PLATE CCCXLII.

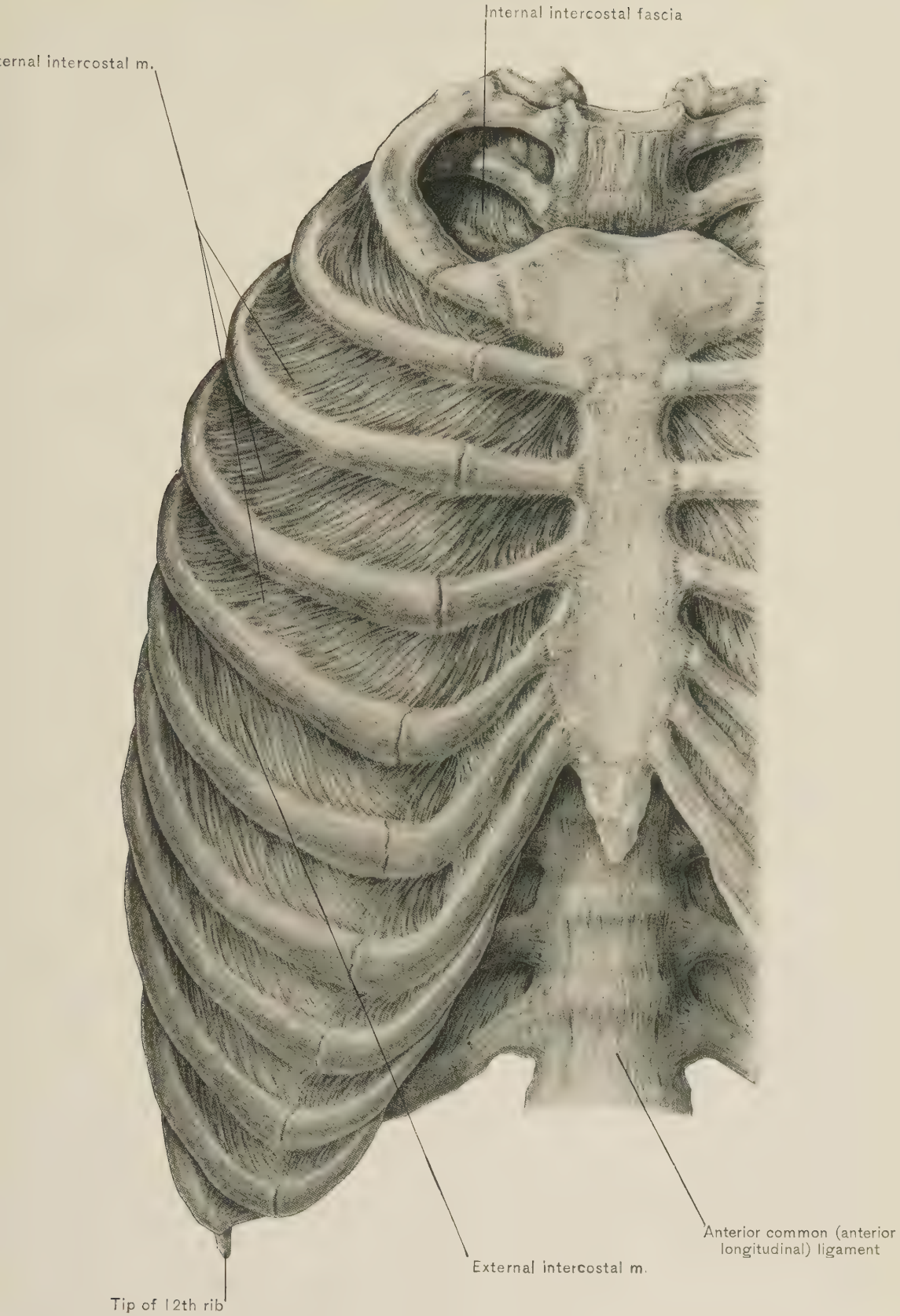

THE INTERCOSTAL MUSCLES.

Relations.—The internal intercostal muscles are covered by the middle intercostal fascia (the intercostal vessels and nerves intervening) which separates them from the external intercostal muscles; the anterior intercostal membranes, also called external intercostal fasciæ, cover them between the cartilages. Deeply they are in relation with the pleura, the triangularis sterni (*transversus thoracis*), and the infracostal muscles.

From the foregoing description it will be seen that the directions of the fibers of the external and internal intercostal muscles are such as to cross at an acute angle, like the bars in the letter X. Displacement of the fragments in fractures of the ribs is rendered almost impossible by this arrangement.

Nerve Supply.—The intercostal muscles are supplied by filaments of the intercostal nerves.

The **levatores costarum muscles** have been described with the muscles of the back (Volume II). They consist of twelve pairs of small fan-shaped muscles in series with the external intercostals. They *arise* from the tips of the transverse processes of the last cervical and the upper eleven thoracic vertebrae, to be *inserted* into the upper border of the next rib below each transverse process, from the tubercle to the angle. The levatores costarum are also inserted into the second rib below their origin.

Relations.—They are covered by the upward continuation of the erector spinæ (*sacro-spinalis*) muscle, and anteriorly are in relation with the external intercostal muscles, with which they are continuous by their lateral borders.

Nerve Supply.—From branches of the intercostal nerves.

The **infracostal muscles,** or **subcostals,** cover the medial surface of the ribs from the tubercle to the angle. They vary in length and development, being usually stronger below. They *arise* from the medial surface of one rib to be *attached* to the medial surface of the first, second, or third rib above, the direction of their fibers being oblique like the internal intercostal muscles. They can best be seen from within the thorax, after the removal of its contents. They are more usually seen on the medial surface of the lower ribs.

Relations.—These muscles lie in front of the vertebral extremities of the ribs and the external and internal intercostal muscles in that region. Their thoracic, or medial, surface is covered by the parietal pleura, from which they are separated by a thin fascia called the **endothoracic fascia.**

Dissection.—The sternum should be sawed through opposite the first and sixth interspaces, the costal cartilages cut through near the sternum, and pieces of several cartilages excised to show the internal mammary artery. The ease with which it may be injured can then be seen. The severed sternum and cartilages should then be removed by cutting away the attachment of the triangu-

laris sterni (*transversus thoracis*) muscle. Great care must be taken not to injure the pleura or the internal mammary arteries. This piece of the sternum should be preserved so that it may be replaced when studying the relations of the thoracic viscera to the surface.

The **triangularis sterni,** or **transversus thoracis, muscle** is virtually an upward extension of the transversalis (*transversus*) abdominis in the same plane in which it lies. It *arises* from the back of the lower part of the sternum and the ensiform cartilage (*xiphoid process*) and the adjacent ends of the fifth, sixth, and seventh costal cartilages, and is *inserted* by five digitations into the back part of the costal ends of the second, third, fourth, fifth, and sixth cartilages, sometimes encroaching upon the ribs. It varies considerably in size. The lower fibers are horizontal and are continuous with the transversalis (*transversus*) abdominis muscle.

Nerve Supply.—All the muscles of this group are supplied by the intercostal nerves.

Action.—The intercostal muscles are the chief factors in moving the ribs. After the first rib has been fixed by the scaleni muscles, they elevate and rotate the ribs and thus increase the capacity of the thorax and aid the diaphragm in inspiration. They are aided by the levatores costarum muscles. The triangularis sterni (*transversus thoracis*) and the infracostals (*subcostals*) depress the ribs and costal cartilages, and are muscles of expiration. Forced inspiration, after fixation of the shoulder and scapula, is assisted by the trapezius, the pectoralis minor, the serratus posterior inferior and superior, the rhomboidei, and possibly the lower fibers of the serratus magnus (*serratus anterior*). By fixing the head, the sterno-mastoid aids forced inspiration, drawing up the sternum and fixing the clavicle, thus giving the intercostal muscles a fixed point from which to act.

Ordinary expiration probably is not dependent on muscular effort, but is the result of the elastic lungs and chest-wall returning to a condition of rest. In forced expiration the muscles of the abdomen, the triangularis sterni (*transversus thoracis*), and the infracostals (*subcostals*) are brought into play. The quadratus lumborum and ilio-costalis muscles, by fixing the last rib, likewise increase the expiratory effort and allow the lower intercostal muscles to aid in expiration.

The **internal mammary artery** (Plate CCCXLIII) arises from the first part of the subclavian artery at the medial border of the scalenus anterior, opposite the origin of the thyroid axis (*thyro-cervical trunk*), passes downward behind the clavicle, and enters the thorax, lying between the cartilage of the first rib and the parietal layer of the pleura. The artery descends in almost a straight line vertically downward, crossing the interspaces on the medial surface of the thoracic wall, about twelve millimeters (one-half inch) from the sternal margin, and should

PLATE CCCXLIII.

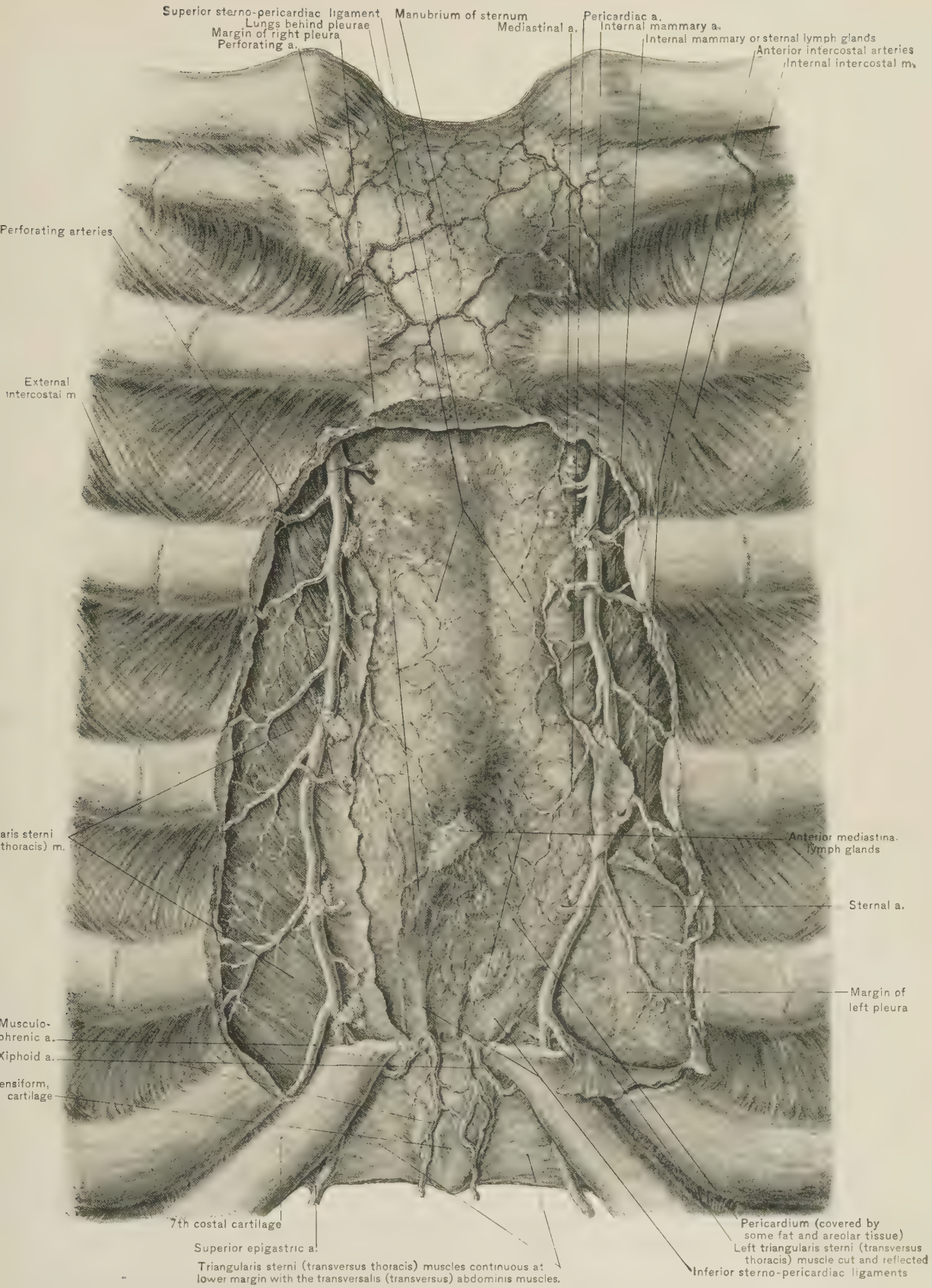

THE INTERNAL MAMMARY ARTERY.

be avoided in the tapping of pericardial effusions. At the sixth intercostal space the artery divides into its terminal branches: the **superior epigastric** and the **musculo-phrenic arteries.**

The internal mammary artery may be described as consisting of a cervical and a thoracic portion.

The *cervical portion* is short and extends from the origin of the artery to the upper border of the first costal cartilage. No branches are given off from it. It is covered anteriorly by the subclavian or internal jugular and by the origin of the innominate vein; behind it lies on the pleura. The phrenic nerve crosses it obliquely lateromedially.

The *thoracic portion* begins at the upper border of the first costal cartilage and ends at the division of the artery into its terminal branches at the sixth costal cartilage. In front of it are the upper six costal cartilages, the internal intercostal muscles, the external intercostal membrane, and the sternal fibers of the pectoralis major muscle. Behind it are, above, the pleura; lower down, the triangularis sterni (*transversus thoracis*) muscle. On the left side, between the fourth and sixth costal cartilages, it can be regarded as being contained in the anterior mediastinum, as the pleura here deviates to the left to form an incisura. The artery can be quite easily tied in the upper three interspaces, the second interspace being the one preferred. Lower down, the interspaces become too narrow and resection of the costal cartilages is necessary to expose the artery. Each artery is accompanied by venæ comitantes.

The branches of the internal mammary artery are: the superior phrenic (*pericardiaco-phrenic*); the mediastinal, or thymic; the pericardiac; the sternal; the anterior intercostals; the perforating; the lateral infracostal; the superior epigastric, and the musculo-phrenic.

The *superior phrenic artery*, or *comes nervi phrenici* (*pericardiaco-phrenic*) is given off behind the first costal cartilage, and accompanies the phrenic nerve to the diaphragm; it comes in relation with the pleura to the lateral side, and with the innominate vein, the superior vena cava, and the pericardium to the medial side, in its course to the diaphragm. It gives off branches to both pleura and pericardium, and anastomoses with the other phrenic arteries in the diaphragm. It also sends two branches into each of the seventh, eighth and ninth intercostal spaces.

The *mediastinal*, or *thymic, branches* are small, and supply the fat and areolar tissues and lymphatics in the superior and anterior mediastinal spaces, and the remains of the thymus gland. The *pericardiac branches* supply a portion of the pericardium.

The *sternal branches* enter the nutrient foramina of the sternum and supply the triangularis sterni (*transversus thoracis*) muscle.

The *anterior intercostal arteries* arise quite irregularly from the internal mammary artery in the upper five or six interspaces, and from the musculo-phrenic, one of the terminal branches of the internal mammary artery, below that point. In each of the interspaces, one artery passes along the upper border of the rib below and another along the lower border of the rib above; these arise separately from the internal mammary or the musculo-phrenic artery, or sometimes by a common trunk, which then divides into the branches described. These branches follow the course of the ribs and anastomose, after piercing the internal intercostal muscle, in the first interspace with the branches of the superior intercostal artery (*costo-cervical trunk*), and in the other interspaces with the aortic intercostal arteries. At first these arteries lie between the internal intercostal muscles and the pleura; later, between the external and internal intercostal muscles, which they supply, together with the ribs.

The *perforating branches* arise from the front of the internal mammary artery and pierce the internal intercostal and pectoralis major muscles to supply the latter and the skin and fascia over that region. They are usually five or six in number, one for each of the upper interspaces. The second, third, and fourth perforating arteries—the second being perhaps the largest—supply the mammary gland and become much enlarged during lactation. They require ligation in the operation of excision of the breast.

The *lateral infracostal artery* arises near the first rib and descends behind the ribs just outside their junction with the costal cartilages. It is small in size and not constant. It anastomoses with the upper intercostal arteries.

The *superior epigastric artery*, one of the terminal branches of the internal mammary artery, is the direct continuation of that vessel. It leaves the thorax by passing downward posterior to the seventh costal cartilage or to the ensiform (*xiphoid*) cartilage and through the space between the costal and sternal attachments of the diaphragm. It then enters the sheath of the rectus abdominis muscle, lying posterior to that muscle at first, later entering it to supply it, and to anastomose with branches of the deep (*inferior*) epigastric artery, a branch of the external iliac artery, thereby forming the longest anastomosis in the body. It gives off some small branches to the diaphragm; a xiphoid branch, which anastomoses with its fellow of the opposite side; a few cutaneous branches; muscular branches to the rectus abdominis muscle; several small hepatic branches (on the right side only) that reach the liver by running along the falciform ligament and anastomose with the hepatic artery, and some peritoneal branches, which pierce the posterior wall of the sheath of the rectus abdominis muscle and supply the peritoneum.

The *musculo-phrenic artery* is the other terminal branch of the internal mammary artery and runs lateralward and downward from the seventh costal

PLATE CCCXLIV.

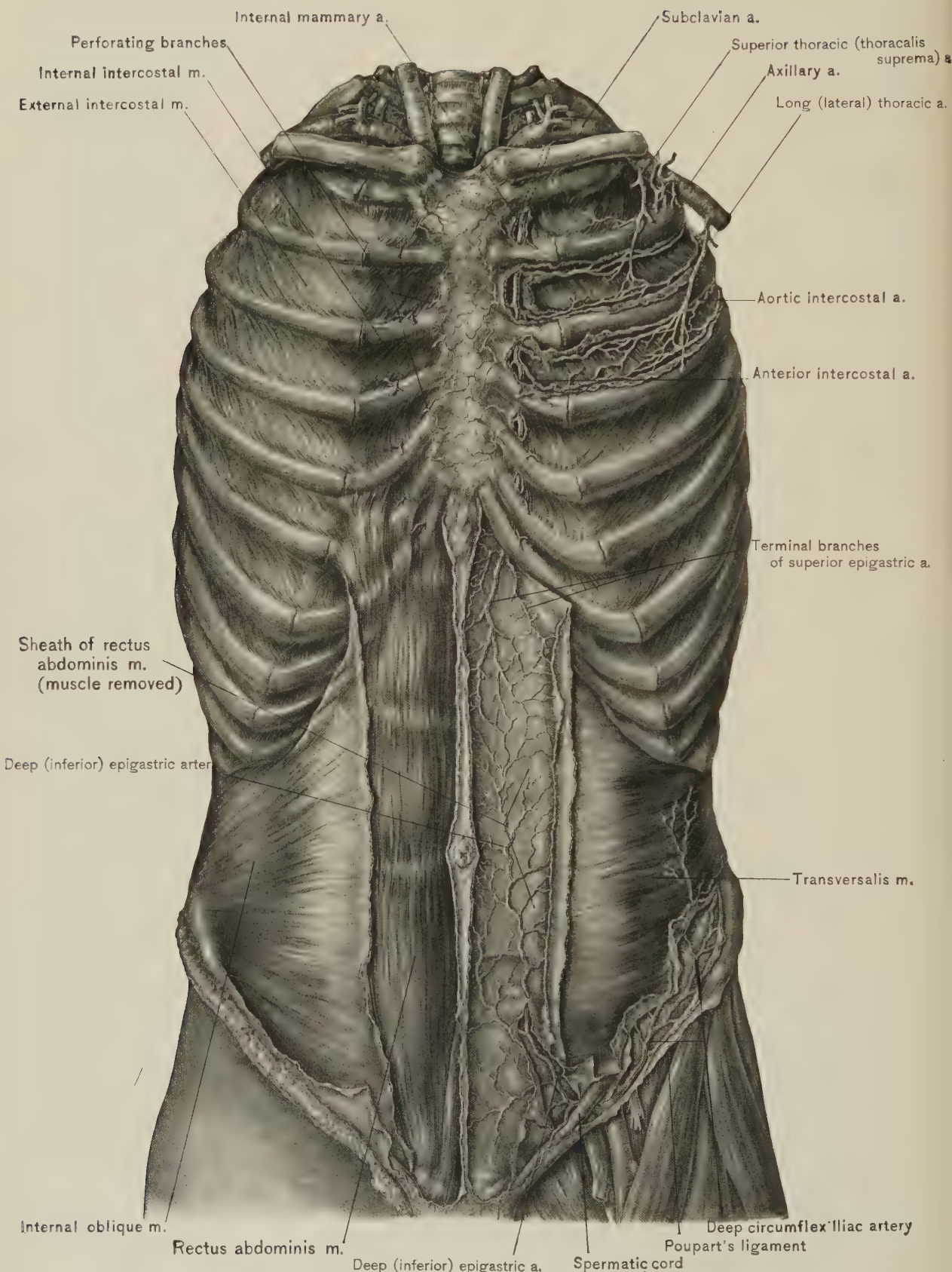

INTERCOSTAL, EPIGASTRIC, AND DEEP CIRCUMFLEX ILIAC ARTERIES.

cartilage, behind the cartilages of the false ribs, pierces the diaphragm at about the eighth or ninth rib, and continues to the last interspace, where it ends. In its course, as it crosses each interspace, it gives off anterior intercostal branches which anastomose, as in the upper interspaces, with the aortic intercostal arteries. Branches are also given off to supply the pericardium, the diaphragm, and the abdominal muscles.

The **internal mammary veins,** two in number, accompany the internal mammary artery to the first interspace, where they unite to form a single trunk, which empties into the corresponding innominate vein at the medial side of the artery; on the right side the vein occasionally empties into the superior vena cava.

The **intercostal arteries** (Plate CCCXLIV) are derived from the internal mammary and the musculo-phrenic arteries anteriorly and from the superior intercostal arteries (*costo-cervical trunks*) and the aorta posteriorly. The anterior intercostal arteries usually arise in pairs, two arteries to each interspace, but only a single posterior intercostal artery is given off to each interspace; this single artery, however, gives off a branch (the collateral intercostal branch) opposite the angle of the rib which crosses the interspace to run along the upper border of the lower rib. The main trunk of the artery continues along the lower border of the upper rib in the subcostal groove. The posterior intercostals, like the anterior, run between the external and internal intercostal muscles and anastomose with those vessels, covered by the middle intercostal fascia.

In all of the intercostal spaces the intercostal nerves lie below, while the veins run above the arteries, except in the third and fourth spaces, where the nerves at first lie higher than the arteries because the latter run upward to gain the interspaces.

The **anterior intercostal arteries** have been described with the internal mammary artery (Volume II).

The **superior intercostal artery** (**costo-cervical trunk**) is given off from the second portion of the subclavian artery behind the scalenus anterior muscle on the right side, but from the first portion of the subclavian artery at the medial border of the scalenus anterior on the left side. It then passes upward and backwards over the apex of the pleura behind the scalenus anterior to the neck of the first rib where it divides. Its branches are the deep cervical and the intercostal arteries and the arteria aberrans. The deep cervical artery has been described with the neck (Volume II).

The *intercostal* (*highest intercostal*) *branch* is really the terminal branch of this artery. It is given off at the neck of the first rib and runs along its lower border to the angle where it divides into two branches and is distributed like an aortic intercostal artery. Frequently, especially on the right side, after giving off a

branch to the first interspace it descends over the neck of the second rib to the second interspace to be distributed in like manner.

The *arteria aberrans*, often absent, is usually very small. It descends into the thorax from the right superior intercostal artery (*costo-cervical trunk*), or rarely from the subclavian artery, to anastomose posterior to the esophagus and anterior to the third thoracic vertebra with a branch of the thoracic aorta that arises below the ductus arteriosus. This anastomosis, when present, is the remains of the right aortic stem, and sometimes is very large, so that the right subclavian artery is then derived from the arch of the aorta and passes posterior to the esophagus.

The **aortic intercostal arteries** arise in pairs from the posterior aspect of the descending thoracic aorta in the posterior mediastinum, and are generally ten in number. They supply the lower nine intercostal spaces, the upper two being usually supplied by the superior intercostal artery (*costo-cervical trunk*). The tenth, or last, artery, also called the subcostal artery, owing to its position, runs along the lower border of the last rib and in front of the quadratus lumborum muscle to the tip of the rib, and is then distributed to the abdominal muscles, like the lumbar arteries, and anastomoses with the latter and with the external circumflex iliac artery. Each intercostal artery can be described as consisting of a vertebral, or mediastinal, and an intercostal portion.

The *vertebral*, or *mediastinal, portions* lie on the vertebræ. Owing to the position of the aorta to the left of the median line, the vessels are longer on the right than on the left side. The upper aortic intercostal arteries in the adult run upward to reach the interspaces, because of the disproportional rate of growth of the aorta and spinal column. This portion of the arteries comes in relation with the structures of the posterior mediastinum. The arteries of the right side are crossed by the thoracic duct, the vena azygos major (*azygos*), and the esophagus, and are covered by the pleura. The arteries of the left side are crossed by the vena azygos minor (*hemiazygos*) and the intercostal veins, and are likewise covered by the pleura.

The *intercostal portions* of these vessels are found in the interspaces. At first each artery runs across the interspace on the external intercostal muscle and is covered by the endothoracic fascia, infracostal muscle, and pleura, to reach the angle of the rib above, at which point it passes in front of the internal intercostal muscle. At this point also is given off the collateral intercostal branch, which runs along the upper border of the rib below to anastomose with one of the anterior intercostal arteries. The continuation of the artery runs along in the subcostal groove between the external and internal intercostal muscles, to anastomose with the other of the two anterior intercostal arteries given off to each interspace. The sympathetic nerve crosses these arteries opposite the heads of

the ribs. The first aortic intercostal anastomoses with the superior intercostal artery (*costo-cervical trunk*) and sometimes supplies the entire second interspace. This is usually the case on the left side.

In thoracentesis the puncture should not be made further back than the angle of the ribs, as beyond that point the artery runs in the middle of the interspace. Here also unless the direction of the needle is carefully guarded important intrathoracic structures may be damaged. A vein and a nerve accompany each artery, the vein being above, the nerve below it, except in the upper interspaces, where the nerve at first lies above the vessels.

The aortic intercostal arteries give off the following branches: a *dorsal branch* supplies the muscles of the back and the contents of the spinal canal; a *collateral intercostal branch,* described above; *pleural branches; muscular branches; lateral cutaneous branches,* which accompany the lateral cutaneous nerves, and *branches to the mammary gland* from the arteries in the third, fourth, and fifth interspaces.

The **intercostal veins** correspond in number to the intercostal arteries, the last vein being called the **subcostal vein.** There is one intercostal vein to each artery; this lies above the artery in each interspace. Near the spinal column the intercostal veins are joined by the veins that accompany the dorsal branches of the intercostal arteries; they return the blood from the muscles of the back, and, by their communication with the spinal plexus of veins, also from the contents of the spinal canal. The intercostal veins are very irregular in their terminations and differ much on the two sides of the body. Between the intercostal muscles they communicate with the tributaries of the internal mammary veins accompanying the anterior intercostal arteries.

The *right superior intercostal vein* accompanies the right superior intercostal artery (*costo-cervical trunk*) and empties into the vertebral at its junction with the subclavian vein, or into the innominate vein. Sometimes the veins from the upper two interspaces do not join, but empty separately. The upper vein is then called the *upper right superior intercostal vein.* The vein from the second interspace is in that instance usually joined by the veins from the third and fourth interspaces, and is known as the *lower right superior intercostal vein.* It empties into the vena azygos major (*azygos*) as the latter winds around the root of the right lung. The remaining intercostal veins and the subcostal vein empty into the vena azygos major (*azygos*).

The *left superior intercostal vein* is usually larger than the right, especially when the left upper azygos (*hemiazygos accessoria*) vein is absent, and drains the upper four interspaces. Its tributary from the first interspace may empty separately, as on the right side, and then is called the *upper left superior intercostal*

vein; the veins from the next three interspaces then unite to form a single trunk which receives the name of the *lower left superior intercostal vein*, and passes over the arch of the aorta to empty into the left innominate vein. At its lower end it may communicate with the left upper azygos (*hemiazygos accessoria*) vein, or, in the absence of this vein, pass over the spinal column to empty into the vena azygos major (*azygos*). A thin fibrous cord can usually be seen to connect it to the oblique vein of Marshall (*oblique vein of left atrium*), passing through the vestigial fold of pericardium. This is the remains of the fetal **left duct of Cuvier** which is the fetal left superior vena cava. The bronchial and superior phrenic veins empty into the lower left superior intercostal veins. The fifth, sixth, and occasionally the seventh intercostal veins either form the left upper vena azygos (*hemiazygos accessoria*) or empty directly into the vena azygos major (*azygos*). The seventh (sometimes), eighth, ninth, tenth, and eleventh intercostal veins, and the subcostal vein, empty into the vena azygos minor (*hemiazygos*).

The **intercostal nerves** extend along the lower margin of the ribs in the subcostal grooves below the intercostal arteries, hidden from view on the medial side of the wide lateral lip, from beneath which they can, however, be drawn by gentle traction upon their lateral cutaneous branches.

They are eleven in number, and are derived from the anterior divisions of the upper eleven thoracic spinal nerves, the twelfth or last thoracic nerve running below the last rib, after giving off a communicating branch, the dorsi-lumbar nerve, to the first lumbar nerve. The distribution of the last thoracic nerve is similar to that of an intercostal nerve, and is described with the abdomen at p. 284. The thoracic nerves are connected by rami communicantes, two to each nerve, with the gangliated trunk of the sympathetic, opposite the heads of the ribs. The first thoracic nerve divides, the greater part joining the brachial plexus of nerves, while the smaller, called the first intercostal nerve, is continued along the lower border of the first rib to the angle, where it passes between the external and internal intercostal muscles. It differs from the other intercostal nerves in that, as a rule, it gives off no lateral or anterior cutaneous branches. The posterior divisions of the thoracic nerves pass backward between the transverse processes of the vertebræ, divide into an internal (*medial*) and an external (*lateral*) branch, and supply the muscles and integument of the back. They have been described with the back (Volume II). The ten remaining intercostal nerves are divided into an upper and a lower set. The upper set includes the anterior divisions of the second, third, fourth, fifth, and sixth, and the lower set the anterior divisions of the seventh, eighth, ninth, tenth, and eleventh thoracic nerves.

PLATE CCCXLV.

1. 1st Thoracic n.
2. 2d Thoracic n.
3. Branch of 1st Thoracic n. (1st Intercostal n.).
4. Anterior division 1st Thoracic n. (Joins brachial plexus).
5. Posterior division 2d Thoracic n.
6. Anterior division 2d Thoracic n. (Intercostal n.).
7. Interior (medial) branch.
8. Exterior (lateral) branch.

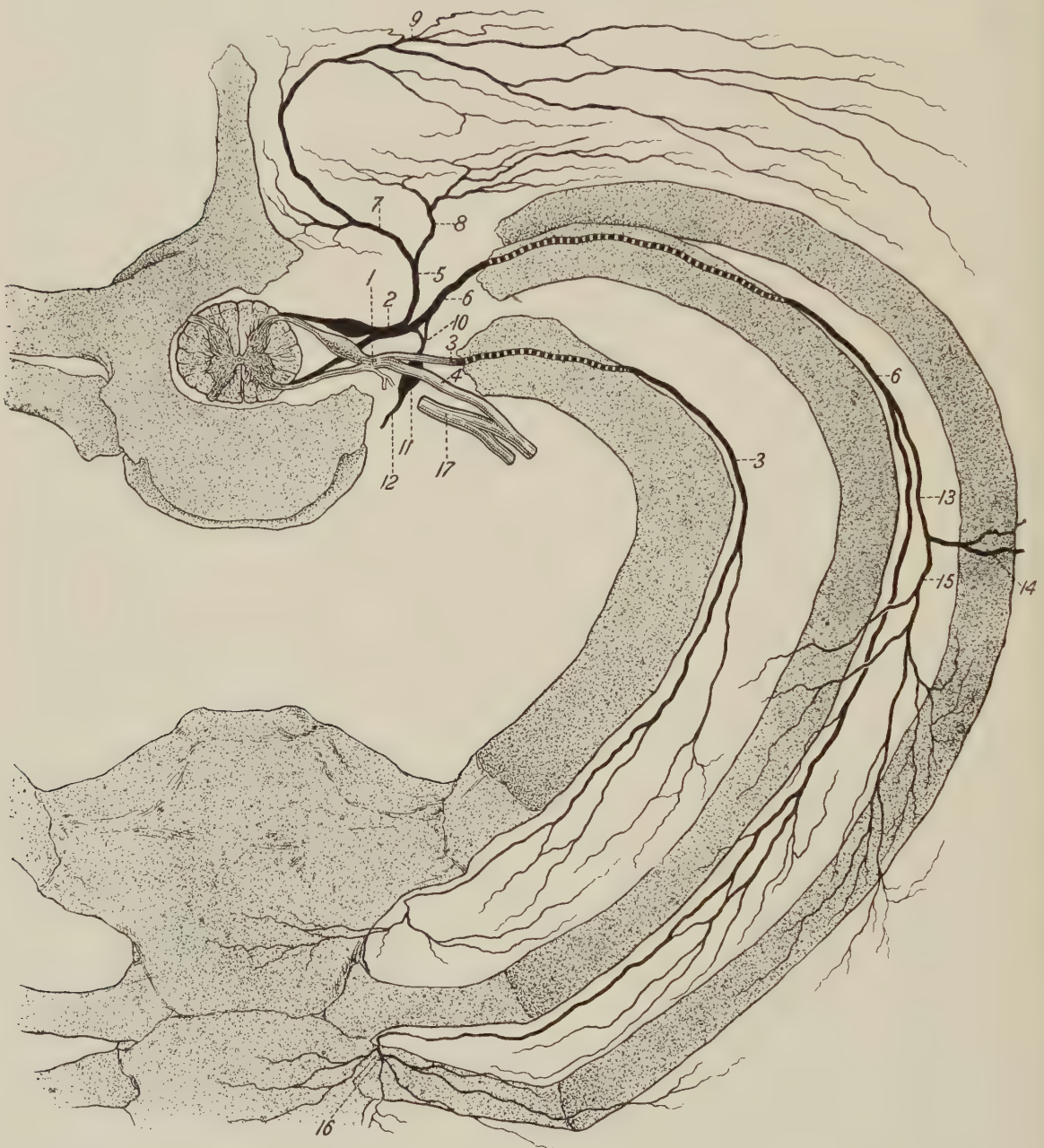

9. Posterior cutaneous branch.
10. Ramus communicans.
11. Sympathetic ganglion.
12. Ramus efferens.
13. Lateral cutaneous branch.
14. Posterior division, lateral cutaneous branch of 2d Intercostal n., the intercosto-humeral (intercosto-brachial) n.
15. Anterior division of lateral cutaneous branch.
16. Anterior cutaneous branch.
17. 8th Cervical n.

DIAGRAM OF UPPER INTERCOSTAL NERVE.

PLATE CCCXLVI.

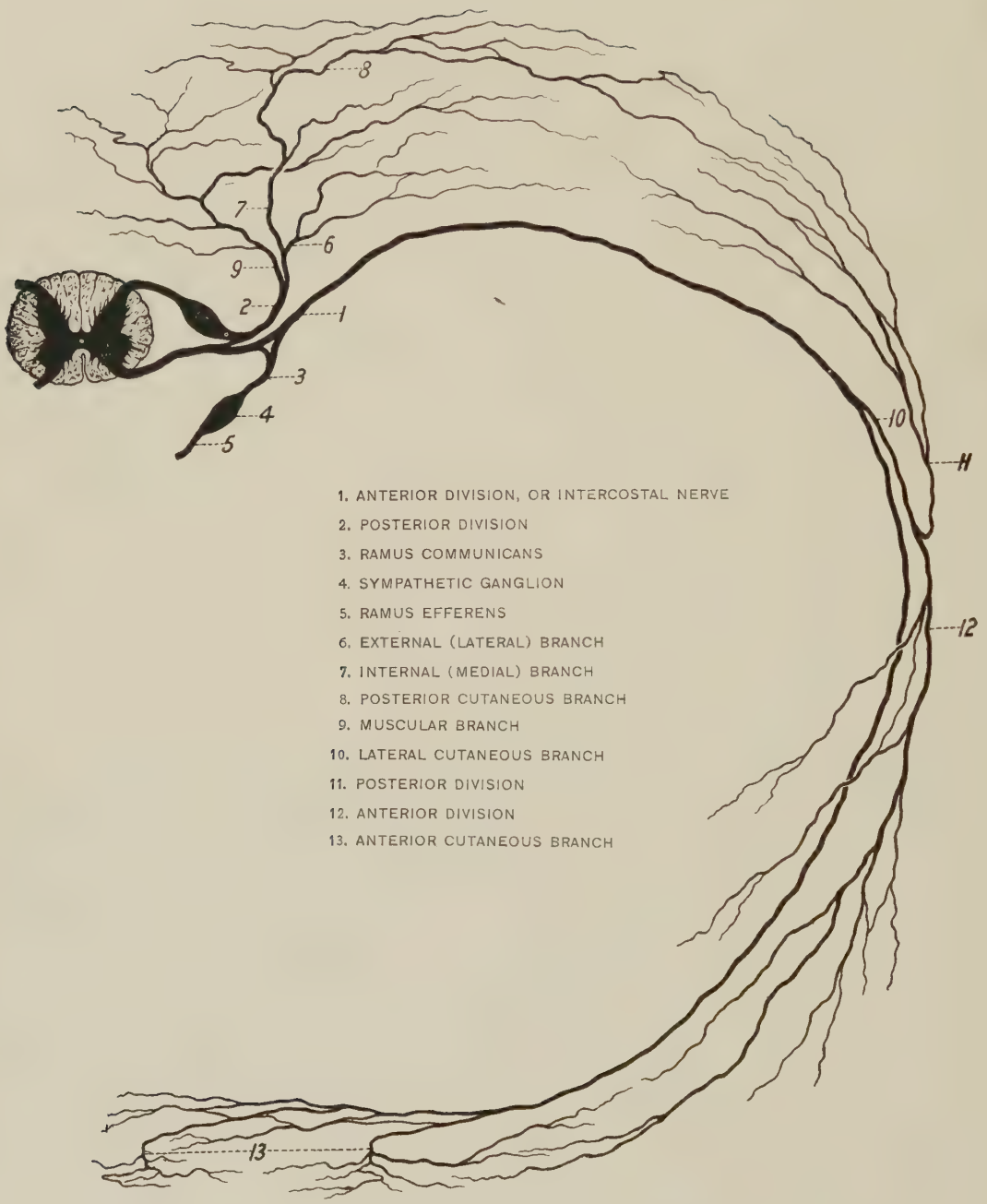

1. ANTERIOR DIVISION, OR INTERCOSTAL NERVE
2. POSTERIOR DIVISION
3. RAMUS COMMUNICANS
4. SYMPATHETIC GANGLION
5. RAMUS EFFERENS
6. EXTERNAL (LATERAL) BRANCH
7. INTERNAL (MEDIAL) BRANCH
8. POSTERIOR CUTANEOUS BRANCH
9. MUSCULAR BRANCH
10. LATERAL CUTANEOUS BRANCH
11. POSTERIOR DIVISION
12. ANTERIOR DIVISION
13. ANTERIOR CUTANEOUS BRANCH

DIAGRAM OF A LOWER INTERCOSTAL NERVE.

Dissection.—The internal intercostal muscles should now be carefully incised along the course of the intercostal nerves and the latter exposed.

The **upper intercostal nerves** (Plate CCCXLV) run outward in the interspaces, at first between the internal intercostal fascia (*posterior intercostal membrane*) and the pleura, and then between the external and internal intercostal muscles, till the midaxillary line is reached. Each nerve here gives off a lateral cutaneous branch, which pierces the external intercostal muscle and emerges between the serrations of the serratus magnus (*serratus anterior*) muscle. The main trunk of the nerve at this point enters the substance of the internal intercostal muscle and runs in it till the costal cartilage is reached, at which point it passes behind the internal intercostal muscle, lying on the pleura and serrations of the triangularis sterni (*transversus thoracis*) muscle. After crossing in front of the internal mammary artery it pierces the interspace close to the sternum as the anterior cutaneous nerve. The upper intercostal nerves supply the levatores costarum, serratus posterior superior, external and internal intercostal, infracostal, and triangularis sterni (*transversus thoracis*) muscles. Each also gives off a lateral cutaneous branch, as before mentioned, and an anterior cutaneous branch. The lateral cutaneous branches vary in size, the second and third being the largest and most important. After piercing the external intercostal muscles, these nerves divide into anterior and posterior branches; the anterior partly supplies the skin over the anterior axillary fold, and gives twigs to the mammary gland; the posterior branches supply the skin over the posterior axillary fold. The lateral cutaneous branch of the second intercostal nerve, or *intercosto-humeral* (*intercosto-brachial*) *nerve*, communicates with the lesser internal cutaneous nerve (*medial cutaneous nerve of arm*), or nerve of Wrisberg, of the brachial plexus, and the lateral cutaneous branch of the third intercostal nerve, and is distributed to the upper portion of the medial and posterior surface of the arm. It has been described with the upper extremity. The anterior cutaneous nerves, or terminal branches of the intercostal nerves, pierce the internal intercostal muscles, the external intercostal fascia, and the pectoralis major muscle in company with the perforating cutaneous branches of the internal mammary artery. They supply the skin over the sternum and over almost the entire pectoral region, and give branches to the mammary gland.

The **lower intercostal nerves** (Plate CCCXLVI) differ from the upper only in the part of their course after they pierce the interspaces. After emerging from between the costal cartilages they pass into the abdominal wall between the transversalis and internal oblique muscles, and, after piercing the sheath of the rectus muscle, and supplying that muscle, they terminate as the ancutane-terior-

ous nerves of the abdomen. They supply the integument over the rectus abdominis muscle. The lateral cutaneous branches, like the upper intercostal nerves, divide, and supply the integument of the abdomen as far forward as the semilunar line, and that of the back over the loin. They are described with the abdominal parietes at p. 284.

Paravertebral Dorsal Block.—This consists of injecting a local anesthetic (novocaine) close to the emergence of the nerve roots from the intervertebral foramina. Since the anatomy of the intercostal nerves has been discussed on page 130) it will not be discussed again here. Labat, whose method seems to be the one most frequently used in this country, suggests blocking the nerves at a point three to five centimeters (one to two inches) from the line of the transverse processes. The patient lies on the side opposite to that to be injected. The spine is arched and the face and knees are approximated, thus widening the intercostal spaces. A cushion is placed under the loin to straighten the vertebral column and to relax the erector spinæ (*sacro-spinalis*) muscle. The twelfth rib is defined and traced to the midline posteriorly. A perpendicular of five centimeters (two inches) is then measured off; this marks the tip of the spinous process of the twelfth thoracic vertebra. A wheal is raised as a landmark and the other spinous processes are identified. The area to be anesthetized is selected and at a point four centimeters (one and a half inches) from the midline opposite each spinous process a wheal is raised. A needle eight centimeters (three inches) long is inserted through the wheal and carried forward, perpendicular to the skin, until it comes in contact with the posterior surface of the rib above the space to be injected. The needle is then slightly withdrawn and the hub is inclined at an angle of 45° laterally and upward, while the needle is carried downward and medialward to meet the lower border of the rib. When this is met it is carried into the intercostal space for two centimeters (four-fifths of an inch) in the same direction. This carries the needle half way between the two ribs and one centimeter (two-fifths of an inch) in front of the transverse process. Five or more cubic centimeters of one per cent novocaine are then injected.

The **membranes** or **fasciæ** found in the thoracic wall are the *external intercostal fascia*, or *anterior intercostal membrane*, which stretches over the external intercostal muscles, and is thickest where these muscles end—namely, between the costal cartilages over the internal intercostal muscles; the *internal intercostal fascia*, or *posterior intercostal membrane*, which lines the internal intercostal muscles internally and is strongest where they are absent, between the angles of the ribs and the spinal column; the *middle intercostal fascia*, between the intercostal muscles; the *endothoracic fascia*, and the *parietal pleura*.

The name *endothoracic fascia* is given to the fascia that intervenes between the deep surfaces of the ribs and internal intercostal muscles, and the parietal pleura. It splits to cover the infracostal muscles, and is lined internally by the *parietal layer of the pleura*, which is described with the pleural sac.

The **lymphatics of the thoracic wall** are divided into a superficial and a deep set.

The **superficial lymphatics** ramify over the muscles covering the chest-wall and empty into the axillary glands. Those from the lateral part of the mammary gland end in the lymph glands along the pectoral muscles, while those from its medial portion empty into the internal mammary lymph glands by passing through the second, third, and fourth intercostal spaces. Carcinoma of the breast may thus give rise to secondary mediastinal carcinoma of the lymph glands.

The **deep lymphatics** of the chest-wall are the *intercostal* and the *diaphragmatic*. The former accompany the intercostal arteries and empty into the internal mammary lymph glands in front, and the intercostal glands behind. The latter accompany the different vessels of the diaphragm and end in the internal mammary and anterior mediastinal lymph glands, the posterior mediastinal glands, and the lumbar glands described under the lymphatics of the abdomen and pelvis.

The **superficial lymph glands of the chest-wall** are the pectoral lymph glands (three or four glands along the lower border of the pectoralis major muscle, described with the upper extremity, Volume II) and the epigastric gland, below the ensiform cartilage (*xiphoid process*). The former receive some of the lymphatics from the mammary gland; the latter receives some of those from the anterior portion of the chest-wall.

The **deep lymph glands of the chest-wall** are the *internal mammary*, also called *external* or *anterior intercostal glands*, and the *posterior intercostal glands*. The former lie along the internal mammary artery, usually one gland in each interspace, and receive the lymphatics from the medial part of the mammary gland, those from the anterior part of the intercostal spaces, and those accompanying the musculo-phrenic and superior epigastric arteries. The efferent vessels from the upper glands empty into the thoracic duct, or the right lymphatic duct, while those from the lower empty into the mediastinal glands. The *posterior intercostal glands* lie at the vertebral ends of the ribs in the posterior part of the interspaces. They receive the lymphatics from the posterior part of the intercostal spaces, the spinal canal, the muscles of the back, and the diaphragm. The efferent vessels from these glands join the thoracic duct. Some of those on the right side, joining the broncho-mediastinal lymphatics, empty into the right lymphatic duct.

THE THORACIC CAVITY

Dissection.—By removing the sternum the cavity of the thorax has been opened. Parts of the left fourth, fifth, sixth, and seventh costal cartilages should now be removed, care being taken not to injure the parietal layer of the pleura and the internal mammary artery. The cut margin of the triangularis sterni (*transversus thoracis*) muscle should be displaced to each side, especially on the left, to show the deviation of the pleural sacs.

The **viscera** contained in the **thoracic cavity** are the **lungs,** enveloped in the pleural sacs, and the **heart** within the pericardium. The lungs are placed on each side and the heart between them, but extending further to the left than to the right.

The interval, or space, between the two pleural sacs is called the **mediastinum.** It extends from the neck to the diaphragm, and is bounded anteriorly by the sternum, posteriorly by the vertebral column, and laterally by the mediastinal portions of the pleural sacs. The space is subdivided into a superior and an inferior compartment in an arbitrary manner, by an imaginary plane passing through the junction of the manubrium and the gladiolus (*body of the sternum*), that is, the angle of Ludwig (*sternal angle*), and the lower margin of the body of the fourth thoracic vertebra. This plane slants obliquely upward from before backward, and nearly corresponds to the level of the upper limits of the pericardium. For this reason many anatomists use the pericardium to divide the mediastinum into four parts. The upper space is called the **superior mediastinum,** the lower space is still further subdivided into the **middle mediastinum,** corresponding to the limits of the pericardium, and the **anterior mediastinum,** which lies in front of, and the **posterior mediastinum** which lies behind the pericardium.

The **anterior mediastinum** (Plate CCCXLVII) is exposed to view by removing the sternum and the fourth, fifth, sixth, and seventh left costal cartilages, which bound it anteriorly. Posteriorly it is bounded by the anterior surface of the pericardium. This space is narrow, in reality merely a slit, behind the sternum opposite the second, third, and fourth costal cartilages, but below it grows larger as the left pleural sac diverges to form the notch for the accommodation of the heart, and corresponds to the area of normal cardiac dulness. It therefore extends further to the left than to the right, and contains the portion of the triangularis sterni (*transversus thoracis*) muscle which lies behind the fourth, fifth, sixth, and seventh costal cartilages on the left side; the left internal mammary artery corresponding to the same area; a few lymph glands; areolar tissue; the sterno-pericardiac ligaments, and sometimes the lower portion of the thymus gland, or its remains.

PLATE CCCXLVII.

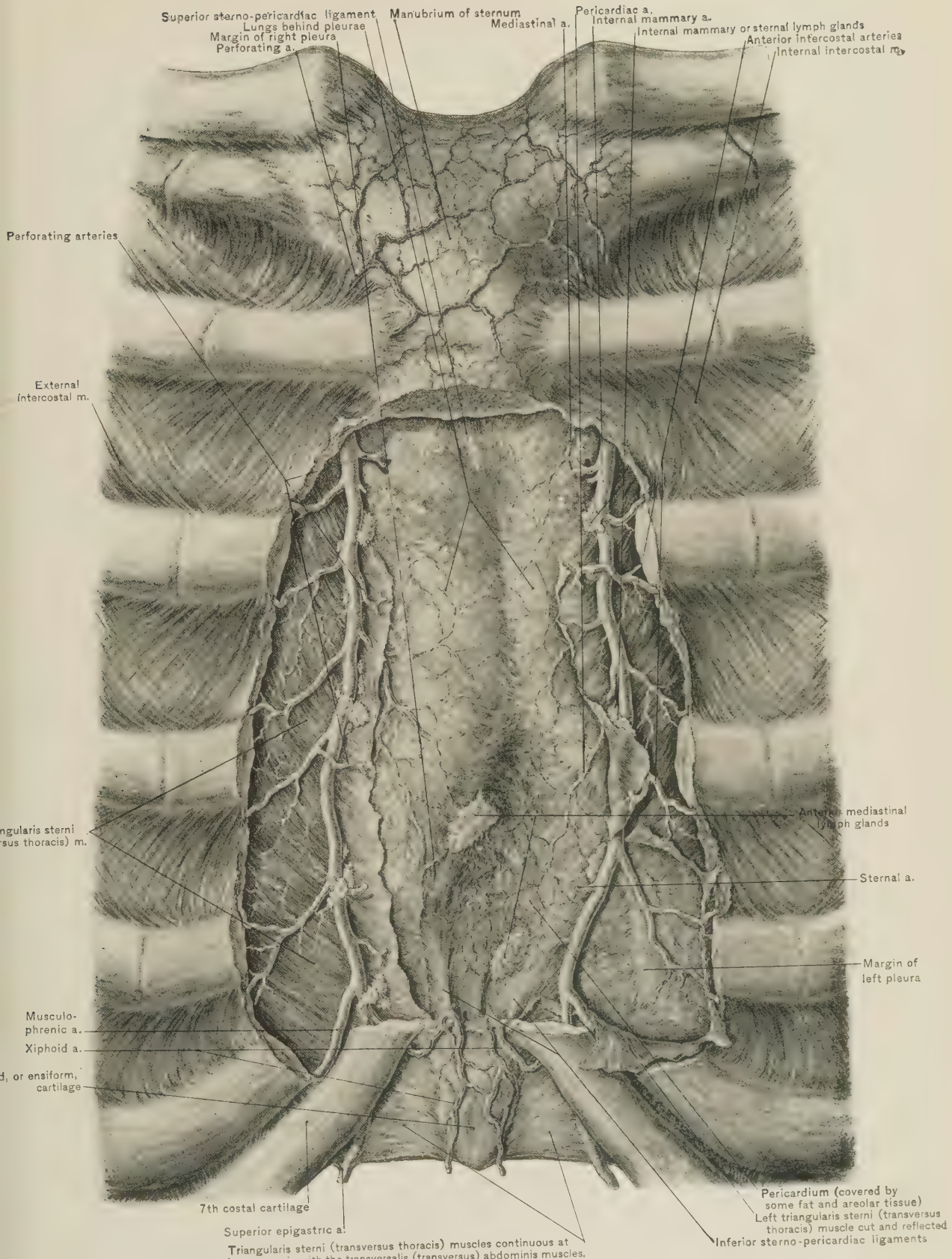

ANTERIOR MEDIASTINUM.

The *lymphatics* in the anterior mediastinum are a few small glands that lie in front of the pericardium in the loose areolar tissue of that region, behind the sternum. They receive vessels from the lower internal mammary lymph glands, from the anterior surface of the pericardium and the heart, from the middle and anterior portion of the diaphragm, and from the upper surface of the right lobe of the liver. Their efferent vessels empty into the lymph glands of the superior mediastinum. A few internal mammary lymph glands corresponding to the portion of the left internal mammary artery behind the fourth, fifth, sixth, and seventh costal cartilages can be said to be contained in the anterior mediastinum.

The thymus gland may extend into the upper portion of the anterior mediastinum in young children, but very rarely in adults. This gland, or its shrunken remains, as a rule occupies the superior mediastinal space.

Neoplasms occur more frequently in the anterior mediastinum. The tumors may be malignant, such as carcinoma (often secondary to carcinoma of the mammary gland) or sarcoma, or benign. Malignant growths are more common than benign tumors and metastatic lesions more frequent than primary lesions. In Hodgkin's disease, tuberculosis or syphilis, the mediastinal nodes may become so large as to obstruct the large blood vessels of the thoracic cavity, the trachea and the esophagus. These growths may give rise to the symptoms and physical signs of aortic aneurysm. Dermoid cysts and teratomata also originate in the mediastinum. They usually produce symptoms which suggest disease of the lung or of the pleural cavity. Abscesses likewise may be found. These may result from broken down lymph nodes, from injury or from punctured wounds. Such abscesses may rupture into either pleural sac, into the pericardium posteriorly or work their way inferiorly into the abdomen, or point in the intercostal spaces. They may also discharge through congenital openings in the sternum, or point in the costo-xiphoid angle. The abscess should be evacuated by trephining the sternum or by resection of a costal cartilage. Great care must be taken that the pleural cavity is not opened at this time or an empyema will result.

Paracentesis (Plate CCCXLI) of the pericardium may be performed in the sixth intercostal space close to the sternum or the pericardium may be drained by resecting the fifth or sixth costal cartilage. It is best to ligate the internal mammary artery in such cases or secondary hemorrhage may result. Although many text books state that the pericardium may be drained in the fifth and sixth intercostal spaces lateral to the internal mammary artery, it should be remembered that this is not always safe, since the pleura passes closer to the median line than does the lung and it may thus be wounded.

The **superior mediastinum** (Plate CCCXLVIII) is bounded anteriorly by the manubrium, and sterno-hyoid and sterno-thyroid muscles, posteriorly by the fourth dorsal vertebra and the longus colli muscle, laterally by the pleura, and inferiorly by the oblique plane which divides the superior mediastinum from the anterior, middle and posterior mediastinum. It contains the aortic arch and its three large branches; the innominate veins and the terminal part of their tributaries; the extra-pericardial portion of the superior vena cava, the trachea, the esophagus, and the thoracic and right lymphatic ducts; the vagus, phrenic, and cardiac nerves; the left recurrent laryngeal (*recurrent*) nerve; the thymus gland, or its remains, and lymph glands, especially at the bifurcation of the esophagus.

With all these important structures crowded into so small a space it is easy to see why thymic enlargements in childhood or growths in adult life can so readily produce pressure symptoms. Aneurysm of the arch of the aorta is common and may not only cause pressure symptoms, but may cause erosion of the manubrium or costal cartilages. The presence of the trachea in the median line and the edges of the lungs which meet opposite the angle of Ludwig (*sternal angle*) results in a resonant percussion note in this area. When growths encroach on the space dulness or flatness replaces the resonance.

The **middle mediastinum** contains the pericardium, within which are found the heart, the ascending portion of the aorta, the pulmonary artery, and the lower half of the superior vena cava; the phrenic nerves, and the phrenic arteries and their companion veins; the roots of the lungs and the anterior pulmonary plexuses; the termination of the vena azygos major (*azygos*), and the bronchial lymph glands. The bronchial lymph nodes are numerous at the bifurcation of the trachea and the roots of the lungs. In children they are frequently the site of early tuberculosis and in adults are often invaded by secondary malignant disease.

The **posterior mediastinum** is bounded anteriorly by the posterior surface of the pericardium and the roots of the lungs, and in its lowest portion by the posterior surface of the diaphragm; posteriorly it is bounded by the thoracic spine below the fourth thoracic vertebra and laterally by the mediastinal pleura. It contains the last part of the aortic arch, and the descending thoracic aorta; the esophagus; the thoracic duct; the azygos veins; the vagus nerves; lymph glands; the vertebral portion of the aortic intercostal arteries; the arteria aberrans (when present); the origin of the esophageal, bronchial, pericardiac, and mediastinal arteries; the right lymphatic duct; the greater splanchnic nerves, and the posterior pulmonary plexus.

This space is really a continuation downward of the superior mediastinum, many structures from the superior passing into the posterior mediastinum.

PLATE CCCXLVIII.

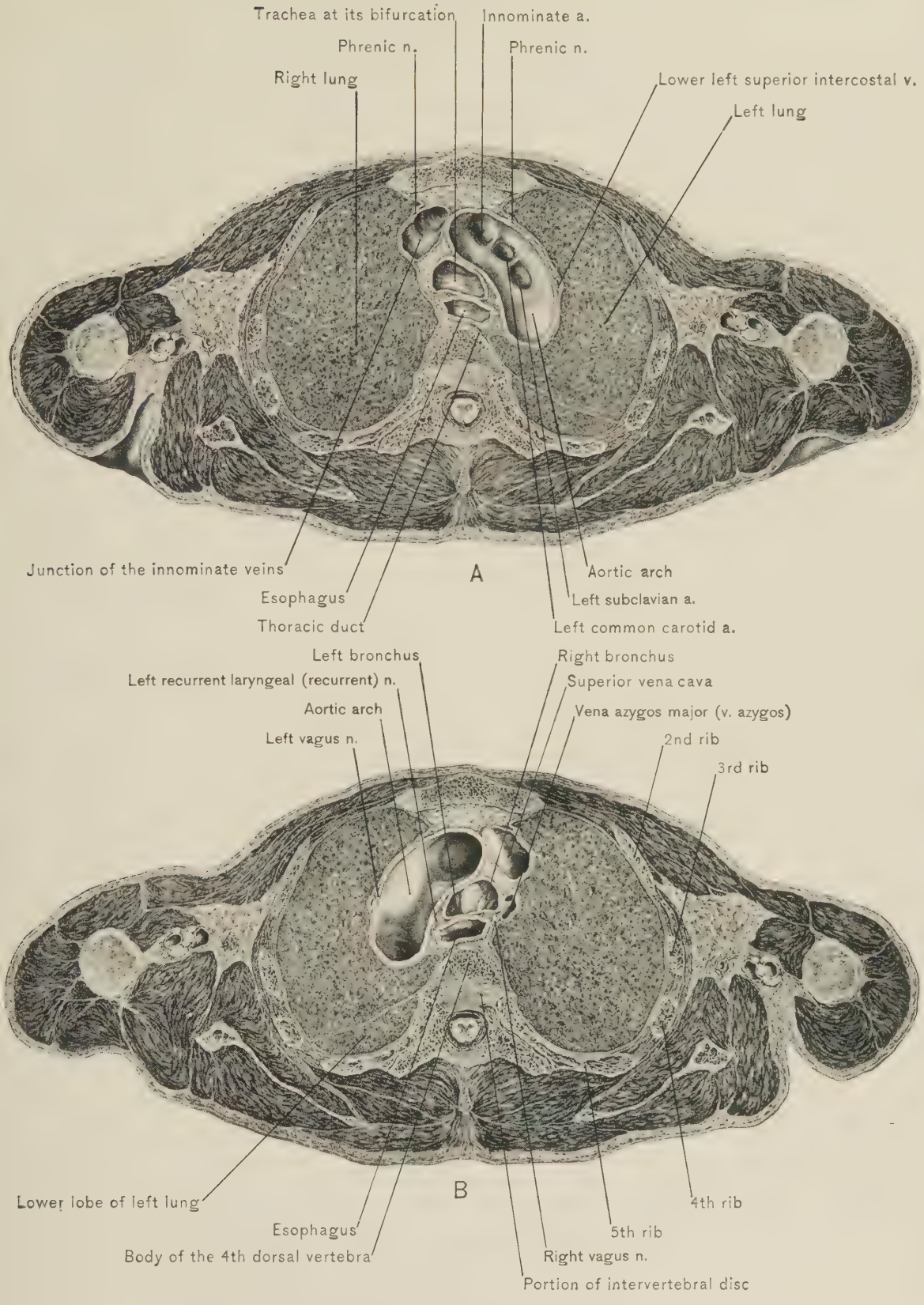

CROSS-SECTION OF THE THORAX THROUGH THE SUPERIOR MEDIASTINUM.

(A) FROM BELOW. (B) FROM ABOVE.

DISSECTION.—The connective tissue, fat, lymph glands of the anterior mediastinum, and the internal mammary artery should now be removed, thereby exposing the pericardium and the anterior margins of the pleural sacs.

THE PLEURA

The anterior portions of the **pleuræ,** or **pleural sacs,** are exposed by the removal of the sternum and costal cartilages; they form the lateral limits of the anterior mediastinum. The pleuræ are completely closed serous sacs, one for each lung, the cavities of which do not communicate with each other. Each pleura lines the internal surface of the thoracic wall and at the root of the lung is reflected over the lung and becomes closely and inseparably attached to it. Thus two layers are formed with a space between. The outer, called the **parietal layer,** is attached to the internal surface of the thoracic wall, of which it forms a part, to the pericardium, to the diaphragm, and, in the neck, to the cervical fascia. It receives different names, according to the part it lines; as, the *costal pleura;* the *diaphragmatic pleura;* the *mediastinal pleura,* and the *cervical pleura.* The inner layer is called the **visceral layer,** and closely invests the lungs. The two layers, it must be remembered, are continuous with each other and are merely names given to different parts of the same membrane. The space between the layers is called the **cavity of the pleural sac,** but normally it does not exist, as the two layers are in contact.

The pleuræ are separated above, behind the manubrium sterni; their anterior margins meet at the junction of the first with the second piece of the sternum, a little to the left of the median line, and descend to the fourth costal cartilage, the left usually slightly overlapping the right sac. The anterior margins of the two sacs diverge at this point, the right continuing downward in almost a straight line to the ensiform cartilage (*xiphoid process*); from there it is reflected behind the seventh costal cartilage to the diaphragm. An incision should now be made along the anterior margin of the right pleura large enough to admit the hand, and the extent of the right pleural sac studied from within its cavity. It extends from the seventh costal cartilage downward, lateralward, and posteriorly, behind the eighth and ninth ribs, reaching the ninth interspace in the midaxillary line; it then passes behind the tenth rib to the eleventh, along which it passes to reach the spinal column at the head of the twelfth, or last, rib.

The left pleural sac differs from the right in that it is narrower and longer. Its anterior margin deviates lateralward from the point of contact of the two pleural sacs behind the sternum at the level of the fourth costal cartilage, to form a notch for the heart, leaving a space of irregular outline between the anterior margins of the two pleuræ, called the anterior mediastinum. This has already

been described. From the point mentioned, the left pleura deviates lateralward, crossing the fourth interspace obliquely, to a point on the medial surface of the fifth costal cartilage, about twelve millimeters (one-half inch) away from the left margin of the sternum. From there it continues somewhat obliquely downward and lateralward to the deep surface of the seventh costal cartilage. Introducing the hand into the cavity of the left pleura, after opening it along its anterior margin, the left pleura is found extending downward and lateralward behind the seventh costal cartilage, and then crossing the eighth, ninth, and tenth ribs, reaching the lower border of the tenth rib in the midaxillary line. From there the lower margin of the pleura extends posteriorly behind the eleventh rib to the head of the twelfth rib. The limits of the pleural sacs have been described with the Surface Anatomy of the Thorax, at p. 111. In operating on the kidney it should be remembered that the pleura extends down to the last rib at the spine, and therefore care should be taken not to wound the diaphragm or open the pleural sac.

Beyond this the pleuræ are quite similar, and therefore do not require separate description. The diaphragmatic attachment of the left pleura is on a lower plane than that of the right, but on neither side does the lung extend as far down as the pleura. Therefore, in the lower portion of the thorax the costal pleura is not in contact with the visceral pleura, but with the diaphragmatic pleura. This part of the pleural cavity is known as the **complemental,** or **supplemental, pleural space,** or the **costo-phrenic sinus.** From this extreme lower margin the pleuræ are reflected onto the arched diaphragm and extend, medially, as far as the pericardium (diaphragmatic pleura). Sweeping the hand along the inner surface of the thoracic wall, the parietal layer of the pleura will be found lining it in its entire extent (costal pleura), and even passing upward through the upper opening of the thorax into the neck (cervical pleura) to the extent of two and a half to five centimeters (one to two inches), where a process of cervical fascia (Sibson's fascia) becomes attached to it. The subclavian artery arches over the cervical pleura, and the scalenus anterior muscle lies anterior to it.

The *costal pleura* is found to be quite thick and tough as compared with the visceral layer, and forms part of the wall of the thorax. It is separated from the internal intercostal and infracostal (*subcostal*) muscles by the endothoracic fascia. The *diaphragmatic pleura* is closely attached to the diaphragm and bound down to it by a strong fascia, called the **phrenico-pleural fascia** (Cunningham). It does not, however, reach the costal attachment of the diaphragm, so that a narrow space is left between that muscle and the thoracic wall, known as the **costo-phrenic sinus.** More recently this name has been given by surgeons to the complemental sinus.

Owing to the position of the heart, the extent of the diaphragmatic attachment of the left pleura is smaller than that of the right, and its medial line of reflection further from the sternum than that of the right pleura. This, together with the more favorable position of the esophagus, has led surgeons to attempt resection of the thoracic esophagus more often through the left thoracic cavity than through the right. By sweeping the hand from the diaphragm toward the median line, the pleura is found to be continued as a partition from the sternum anteriorly to the sides of the bodies of the vertebræ posteriorly, where it becomes continuous with the costal pleura, and to the neck above, where it is continuous with the cervical pleura. It is reflected onto the roots of the lungs, this being its only interruption in its upward extent to become the visceral layer of the pleura, the two layers thus being continuous at the roots of the lungs. This is the mediastinal portion of the parietal layer of the pleura, and forms, on each side, the lateral boundary of the mediastinal space. Its medial surface comes in close contact with the pericardium and becomes quite adherent to it in the posterior part of its extent. Below the roots of the lungs, in passing the hand along the mediastinal pleura from before backward, a barrier is encountered; this is the **ligamentum latum pulmonis** (**pulmonary ligament**), which extends from the roots of the lungs to the diaphragm, and is formed by the portions of the mediastinal pleura passing anteriorly from the spine, and posteriorly from the sternum to the sides of the pericardium, and along them to be reflected lateralward to the lungs, separating there to inclose the lower part of the lungs as the visceral layer. It can be brought to view by drawing the base of the lung lateralward, when it will appear as a triangular fold of membrane extending from the lower border of the root of the lung to the diaphragm, supporting the upper part of that structure.

The *visceral layer of the pleura* envelops the lung and passes into the fissures to cover the lobes, allowing them to glide over each other without friction. When the pleura is normal, its surfaces will feel smooth, moist, and slippery to the hand introduced between the layers. Normally there is no space between the layers, and, except for a small amount of fluid, the two surfaces of pleura are in apposition and glide over each other. Quite frequently, however, bands of adhesions, resulting from some inflammatory process, connect the two layers in different localities; this is particularly liable to occur at the apex. One of the lobes of the lung is not infrequently adherent to another from the same cause.

Blood Supply.—The pleuræ are supplied by the aortic intercostal, internal mammary, phrenic, inferior thyroid, thymic, pericardiac, and bronchial arteries; the veins correspond to the arteries.

Nerve Supply.—The parietal layer of the pleura is supplied by the intercostal nerves; the visceral layer, by the phrenic nerve and filaments of the sympa-

thetic nerves. It may be noted that the costal pleura is supplied with nerves and vessels from the same sources largely as the chest-wall, the lymphatics also having a similar course, whereas the vascular and nervous supply of the visceral pleura is closely related to that of the lung.

The *lymphatics* of the pleuræ are numerous; those of the parietal pleura pass to the sternal and intercostal glands, while those of the visceral pleura empty into the bronchial glands.

Surgical Considerations.—The lungs are in contact with the parietal pleura everywhere, only a thin film of fluid separating the two. In the potential pleural space there exists a negative pressure which is sufficient to overcome the inherent elasticity of the lung. This negative pressure is the main factor in the maintenance of lung expansion. It is equal to about six millimeters of mercury and varies only slightly with normal inspiration and expiration. The capillary attraction of the parietal and visceral pleuræ assists in maintaining apposition of the membranes. The negative pressure is reduced in emphysema, and is increased in fibrosis of the lung and in pneumonia.

The presence of a partial pneumothorax permits of an increase in the variations of the intrapleural pressure. A rapid decrease or increase of the intrapleural pressure causes distress, and in certain cases of suppurative disease of the pleura an opening through the chest wall which dissipates the intrapleural negative pressure may result in death. This is especially true in the streptococcic empyemata where the mediastinal pleura is not rigid and "mediastinal flutter" results. A patient can stand a much higher negative pressure than a positive pressure. Any operation which demands wide exposure of the chest, thus affecting the intrapleural pressure, should be done only when means are at hand of overcoming pulmonary collapse by regulating the intrapulmonary pressure. The condition of open pneumothorax is dangerous not only through its effect on the exposed lung but because of the effect on the pressure in the opposite side of the chest and of the effect on the mediastinum.

Inflammation of the pleura, known as **pleuritis,** or **pleurisy,** causes a roughening of the normally smooth, moist membrane; the movement of respiration then produces the friction sounds that are heard in auscultation of the chest under such conditions. When an effusion of fluid into the pleural sac takes place, the condition is known as **hydrothorax;** pus in the pleural sac is called **pyothorax,** or **empyema thoracis; pneumothorax** signifies air in the pleural sac; when air and pus occupy the pleural sac resulting from a pyothorax communicating with a bronchus, the condition is known as **pyopneumothorax; hemothorax** means that blood occupies the pleural sac. Fluid in the pleural sac may be removed by **thoracentesis,** by puncturing the chest-wall and withdrawing the fluid by means

PLATE CCCXLIX.

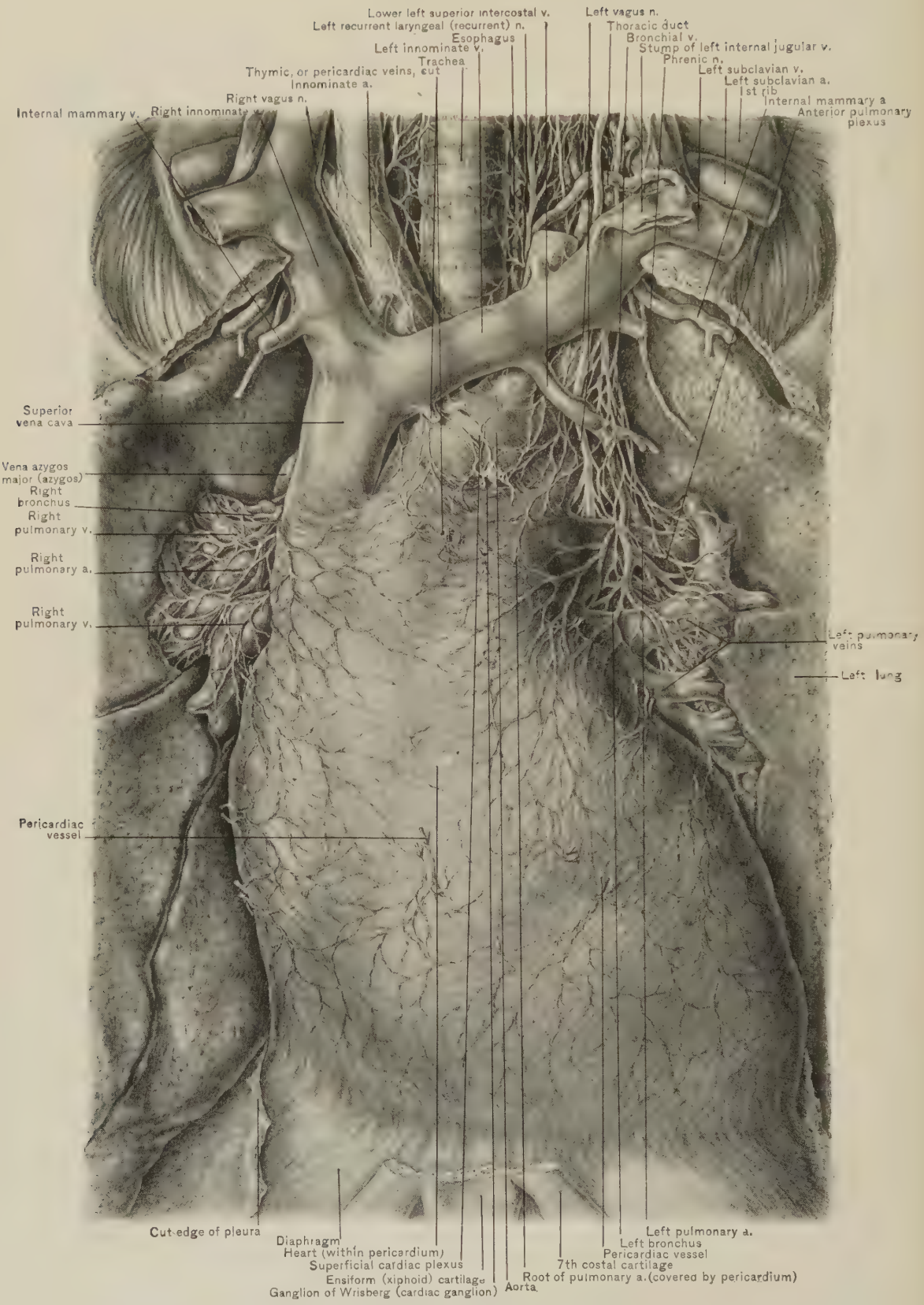

STRUCTURES IN THE SUPERIOR MEDIASTINUM, AND THE PERICARDIUM AND ROOTS OF THE LUNGS.

of an aspirator. The points for aspirating the chest have been described with the surface anatomy of the thorax, at p. 111.

Pus in the pleural sac in neglected cases may evacuate itself by spontaneous rupture, either externally, **empyema necessitans**, or through the lung, or through the diaphragm into the abdomen, or into the pericardium. External rupture may take place through the chest-wall, usually in the fifth intercostal space, or the pus may burrow downward along the spine and appear as a psoas or lumbar abscess. Perforation through the diaphragm of a liver or subdiaphragmatic abscess may cause a localized pyothorax. When pus is present, early evacuation and free drainage are imperative, as collapse of the lung and chest-wall on the affected side is less likely to follow such a course. It is usually necessary to remove a portion of one or more ribs in the infra-axillary region, to obtain free drainage. This operation is known as **thoracotomy.** Cases of pyothorax are separated surgically into four groups: those due to the tubercle bacillus; those due to the pneumococcus; those due to the streptococcus or staphylococcus, and those occurring in very young children. With the first group the surgeon will rarely concern himself if he wishes to avoid trouble. In the pneumococcal infections I believe that primary rib resection offers the best chance of ultimate recovery, while in the streptococcal cases repeated aspiration or interrib puncture is the better primary operation. In very young children the operation which least disturbs the intrapleural pressure is the safest.

In rib resection the opening in the chest should be as low as possible; it is best made by excising a portion of the ninth rib in the scapular line or the eighth rib in the midaxillary line. I prefer the vertical incision since, if the original opening does not drain the base of the cavity, the incision can be lengthened and a part of another rib can be resected.

An **abscess** sometimes forms between the parietal pleura and the chest-wall and is called **peripleuritic abscess.**

The pleura may be the seat of tumors, such as carcinoma, sarcoma, or fibroma. Occasionally they cause bulging of the chest-wall, especially in the interspaces, and may even ulcerate through the tissues. The malignant forms of growths are the more common, and are usually secondary to primary growths in the lungs. Tumors of the pleura, especially when diffuse, may give physical signs similar to a pleural effusion. They can readily be differentiated from the latter by the *x*-ray.

THE SUPERIOR MEDIASTINUM (Plate CCCXLIX)

Dissection.—Remove the remaining portion of the sternum and first ribs as far laterally as the insertion of the scalenus anterior muscle. The other ribs, as

far down as the seventh or eighth, should be divided at about the mid-clavicular line, the anterior margin of the lungs displaced lateralward, and the roots of the lungs and the pericardium exposed on both sides by separating the mediastinal pleura from the pericardium. Its reflection over the roots of the lungs to become the visceral layer of the pleura should be studied, also the **ligamentum latum pulmonis** (**pulmonary ligament**), which will be seen to extend from the lower aspect of the roots to the diaphragm, and between the lower portion of the lungs and the sides of the pericardium. It consists of two closely applied layers of pleura, and is continuous above with the pleura covering the anterior and posterior portions of the root of the lung, medially with the pericardial pleura, laterally with the pulmonic pleura below the hilum, and inferiorly one with the other, so as to form a free lower border. A puncture should then be made in a portion of the pericardium just large enough to admit the small end of a blow-pipe with which the pericardium may be inflated to demonstrate its extent when filled with serous effusion. An opening should also be made in the trachea, into which a large-mouthed blow-pipe with a stop-cock attached should be inserted, so that the lungs may be inflated and the relations of their anterior borders demonstrated. The attachments of the cervical fascia to the pericardium should be studied, and the thymus gland or its remains noted. These structures should then be removed and the great vessels and the nerves exposed and cleaned. This exposes to view the structures in the superior mediastinum, which have already been enumerated.

The **thymus gland** is probably a vestigial organ which reaches its full size at the end of the second year, after which it ceases to grow and gradually atrophies. Its function is unknown. When of full size, it is about five centimeters (two inches) in length, of a grayish color, and consists of two lateral lobes which touch each other along the midline and are ensheathed by fascia. In the infant it is situated in the superior mediastinal space and in the neck, extending from the fourth costal cartilage upward as high as the lower border of the thyroid gland, with which it is sometimes connected. I have met with this condition in performing the operation of low tracheotomy. In the superior mediastinum it rests upon the transverse aorta and its branches, and the left innominate vein, being separated from the vessels by the pericardium and the extension of the deep cervical fascia which attaches to the pericardium. In the neck it lies on the front and sides of the trachea. In the adult it may either have disappeared or its remains are indicated by a small amount of tissue of a brownish color, consisting largely of fat, lying just above the arch of the aorta, and in front of the innominate, the left subclavian, and the left common carotid arteries. Occasionally the gland may be of considerable size in the adult and may give rise to pressure symptoms. It is found enlarged in individuals of the lymphatic type, and I have observed

it enlarged in several instances of death from status lymphaticus. Its blood supply is from the internal mammary and the inferior thyroid. Its nerve supply is from the vagus and sympathetic. The lymphatics which drain it end in the glands in front of the pericardium, those along the internal mammary vessels and the tracheo-bronchial and lower cervical nodes.

The **innominate,** or **brachio-cephalic, veins,** right and left, are formed by the union of the subclavian and internal jugular veins of the corresponding side behind the sternal end of the clavicle. They have no valves.

The **left innominate vein,** sometimes called the transverse vein, is longer and larger than the right, being about seven and a half centimeters (three inches) in length, and passes from left to right behind the sternal end of the left clavicle, the first portion (manubrium) of the sternum, the sterno-hyoid and sterno-thyroid muscles, the remains of the thymus gland, and the process of the deep cervical fascia continuous with the pericardium, which separates it from that gland. It crosses the left subclavian and left common carotid arteries, the trachea, and the innominate artery, as well as the left vagus, left phrenic, and cardiac nerves to unite with its fellow of the opposite side to form the superior vena cava. It is therefore posterior to the thymus, sterno-thyroid and sterno-hyoid muscles and the manubrium; anterior to the left common carotid and innominate arteries, trachea and pretracheal fascia which is behind and between the arteries; inferiorly is the aortic arch. The relation the vein bears to the three primary branches of the aorta should be borne in mind when studying cases of aneurysm of these vessels, in which circumstances the vein may be compressed between the aneurysm and the sternum, thus causing swelling and venous congestion in the parts from which it returns blood. In some cases the vein passes across the root of the neck in front of the trachea, a fact to be borne in mind in performing a low tracheotomy. Into it empty the vertebral, deep cervical, and inferior thyroid veins from above; the left superior intercostal, the internal mammary, and some of the thymic, mediastinal, and pericardiac veins from below. The thoracic duct empties into it at the junction of the internal jugular and subclavian veins.

The **right innominate,** or **brachio-cephalic, vein** is the shorter and smaller, being about three and three-quarters centimeters (one and a half inches) in length; it commences behind the medial end of the clavicle and descends vertically to unite with its fellow of the opposite side behind the junction of the first right costal cartilage with the sternum, to form the superior vena cava. To the lateral side are the pleura and lungs, and the right phrenic nerve; to its medial side, and on a plane posterior to it, are the right subclavian and the innominate arteries, the right vagus nerve, and the trachea. In front of it are the remains of the thymus

gland, the origin of the sterno-thyroid and the sterno-hyoid muscles, the sternal end of the clavicle, and the first costal cartilages. Behind it are the pleura and lungs in a groove of which it lies, so that these structures are slightly posterior as well as lateral and anterior, and overlap its termination. Its tributaries are the vertebral, deep cervical, internal mammary, and inferior thyroid veins, the right lymphatic duct at the confluence of the internal jugular and subclavian veins, and sometimes the superior intercostal vein.

The **superior, or descending, vena cava** is formed by the union of the right and left innominate veins, which unite at nearly right angles, opposite the interval between the cartilages of the first and second ribs on the right side of the sternum. It descends vertically, and empties into the upper part of the right auricle. It is invested by pericardium to about three and three-quarters centimeters (an inch and a half) above the heart, and it is this portion that is counted as belonging to the middle mediastinum, the upper portion being contained in the superior mediastinum. It is from six and a quarter to seven and a half centimeters (two and a half to three inches) in length. It has no valves. The superior vena cava is in relation, anteriorly, with the pericardium and with the process of the deep cervical fascia which is continuous with it; the first and second intercostal spaces, the second costal cartilage, and the remains of the thymus gland; the pleura and lungs overlap it, and that portion in the superior mediastinum grooves the medial surface of the lung. Posteriorly, it is in relation with the right bronchus and the right pulmonary vessels, the vena azygos major (*azygos*), the right pulmonary artery, the superior right pulmonary vein, and the pericardium; on its right side, with the pleura, the lungs, and the phrenic nerve; on its left side, with the ascending aorta and the right innominate artery. Into it empty small pericardiac and mediastinal veins, and the vena azygos major (*azygos*) which enters its posterior surface just above the pericardium.

The **vena azygos major** (**vena azygos**) for the greater part of its extent occupies the posterior mediastinum, and only as it arches forward and upward over the right bronchus does it occupy the superior mediastinum. It is formed in the abdomen by branches of the lumbar veins, often communicating with the left renal vein, and at times with the inferior vena cava. It enters the thoracic cavity through the aortic orifice of the diaphragm, and from this point to about the level of the fourth dorsal vertebra it occupies the posterior mediastinum. There the vein passes forward and winds from behind forward over the root of the right lung. At this point it receives the right bronchial vein. It empties into the superior vena cava at the point where the latter becomes invested with the pericardium. It receives blood from the right superior intercostal vein; the right inferior intercostal veins; the vena azygos minor (*hemiazygos*); the vena azygos

tertia (*hemiazygos accessoria*), when present; the right bronchial vein; some of the esophageal veins, and a few small pericardiac veins.

Owing to the persistence of the **left duct of Cuvier,** sometimes a left superior vena cava is found, which empties into the coronary sinus. The **oblique vein of Marshall** (**oblique vein of left atrium**) is the remains, in the adult, of this fetal duct; it communicates with the left lower intercostal vein, and passes, as a thin fibrous band, through the vestigial fold of pericardium to end in the coronary sinus. The right duct of Cuvier becomes the superior vena cava.

The Phrenic Nerves.—Before opening the pericardium, the relations of the phrenic nerves should be studied. Both nerves at first occupy the superior mediastinum, but between the pericardium and pleura they lie in the middle mediastinum. Each nerve usually arises by three roots from the anterior divisions of the third, fourth, and fifth cervical nerves; occasionally it has only two roots, and sometimes only one, that from the fourth cervical nerve. The filament from the fifth cervical nerve is commonly derived from the nerve to the subclavius muscle or from the communicating branch from the cervical plexus to the brachial plexus. After receiving a twig from the cervical sympathetic each phrenic nerve runs obliquely downward and medialward over the scalenus anterior, but posterior to the sterno-mastoid muscle, and enters the chest through its upper opening behind the subclavian vein, crossing the internal mammary artery at its beginning, from without medialward. There it is usually joined by the root from the fifth cervical nerve which is frequently called the **accessory phrenic nerve.** The **right phrenic nerve** then runs downward along the right side of the right innominate vein, the superior vena cava, and the pericardium, and between these structures and the pleura, to reach the diaphragm. The **left phrenic nerve** passes anterior to the arch of the aorta and the cervical cardiac branch of the vagus, and between the pericardium and pleura, to the diaphragm. Both nerves cross anterior to the roots of the lungs and enter the middle mediastinum. The phrenic nerves contain both sensory and motor fibers. They give sensory branches to the pleura and pericardium while in the thorax. Upon reaching the diaphragm they pierce it and ramify on its under surface, and supply it. The left phrenic is longer than the right owing to the greater inclination of the pericardium and heart toward the left side and to the fact that the diaphragm is lower on the left side. Each nerve distributes branches to the pericardium and pleura and communicates with the sympathetic and other nerves. On the right side one or two filaments join with the diaphragmatic branches of the solar (*celiac*) plexus to form a small ganglion, the ganglion diaphragmaticum (*phrenic ganglion*), from which branches are distributed to the hepatic plexus, the suprarenal gland, and the inferior vena cava. From the left phrenic, filaments pass to join the left

diaphragmatic (*phrenic*) plexus. According to Luschka, various respiratory disturbances, paralysis of the diaphragm, and certain forms of hiccup may be due to interference with the function of the phrenic nerve by adhesions of the pericardium and pleura.

Several cases of post-encephalitic diaphragmatic tic have been reported which have been cured by phrenicotomy. The nerve may also be severed in intractable hiccup. Sauerbruch has divided the phrenic nerve in order to raise the diaphragm after pulmonary lobectomy for bronchiectasis. The effect of such paralysis without lobectomy is to produce a diminution in size of the lower part of the pleural cavity and marked diminution or complete absence of expansion of the lower lobe. The nerve should be divided just above the clavicle through an incision carried along the lateral border of the sterno-mastoid muscle. The latter is retracted medially and the scalenus anterior is exposed. The phrenic nerve is then seen on its anterior surface near its medial margin.

Inasmuch as filaments from the right phrenic nerve pass to the substance of the liver through the coronary and falciform ligaments, it is likely that the right shoulder pain in hepatic disease is due to this distribution, the pain being referred to the termination of the dorsalis scapulæ, which arises from the fifth cervical, and the suprascapular, which arises from the fifth and sixth. Each phrenic nerve is accompanied by the **comes nervi phrenici** (**pericardiaco-phrenic**) **artery,** a branch of the internal mammary artery, which has been described with that vessel.

The Vagus Nerves (Plate CCCL).—The **right vagus nerve** passes between the subclavian vein and the first portion of the subclavian artery, enters the chest through its superior opening, and descends in the superior mediastinum behind the right innominate vein on the right side of the trachea to the posterior surface of the root of the right lung, where it occupies the posterior mediastinum. Behind the right bronchus it becomes broad and flat and supplies several branches to the right posterior pulmonary plexus or may in itself form this plexus. Thence the nerve descends as two cords across the vena azygos major (*azygos*) to the right side of the esophagus, where it gives off numerous branches which inosculate with similar branches from the left nerve. These branches of both vagi ramify on the anterior and posterior surfaces of the esophagus and form the *esophageal plexus*, or *plexus gulæ*. The fibers from the right vagus form the posterior esophageal plexus while those from the left form the anterior esophageal plexus. Beyond this plexus, the right vagus nerve continues as a single trunk on the posterior surface of the esophagus to enter the abdomen through the esophageal opening of the diaphragm. It is then distributed to the posterior surface of the stomach and supplies branches to the celiac, splenic, and left renal plexuses. The **left**

PLATE CCCL.

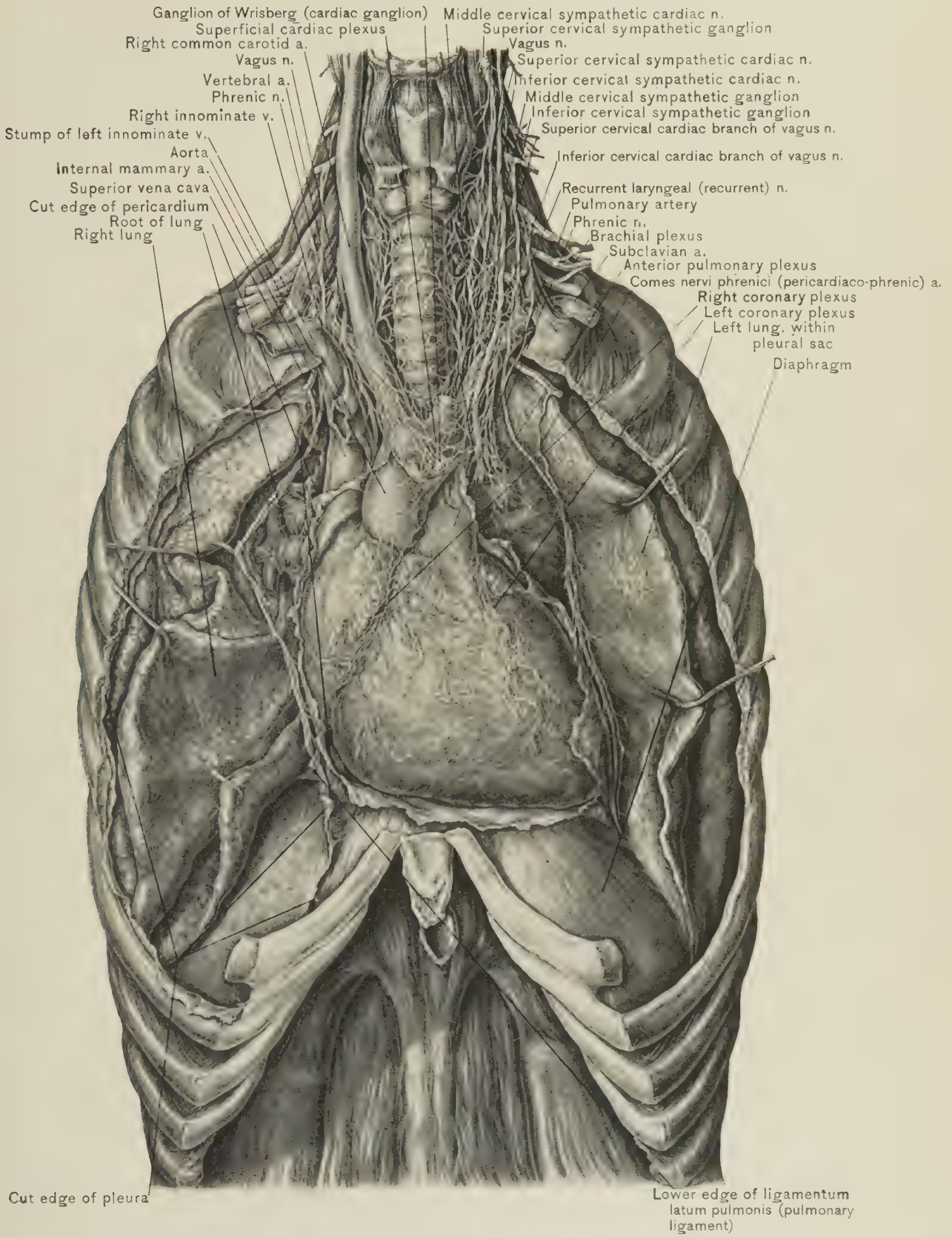

STRUCTURES IN THE SUPERIOR MEDIASTINUM, AND THE HEART AND LUNGS.

vagus nerve enters the chest at its superior opening, between the left common carotid and the left subclavian arteries and behind the left innominate vein. It descends in the superior mediastinum between the left common carotid and the left subclavian arteries, and, bending posteriorly, crosses anterior to the left side of the transverse portion of the arch of the aorta, and passes to the posterior surface of the root of the left lung, where it enters the posterior mediastinum. From this point, its course is similar to that of the right vagus. It supplies branches to the left posterior pulmonary plexus; descends as two cords on the left side of the esophagus; assists in the formation of the esophageal plexus; then, as a single trunk, descends on the anterior surface of the esophagus and passes through the esophageal opening of the diaphragm. It is distributed to the anterior surface of the stomach and supplies branches to the hepatic plexus.

In the chest, in addition to the branches mentioned above, each nerve gives off branches to the anterior pulmonary plexus and the deep cardiac plexus, and the recurrent laryngeal (*recurrent*) nerve.

The **right recurrent,** or **inferior, laryngeal** (**recurrent**) **nerve** is given off as the vagus nerve crosses the first portion of the subclavian artery, winds around that vessel, and passes upward, posterior to the common carotid and inferior thyroid arteries, to gain the side of the trachea. It then runs upward in the groove between the trachea and the esophagus and enters the larynx posterior to the lower border of the inferior constrictor of the pharynx. It gives off a branch to the cardiac plexus at its commencement.

The **left recurrent,** or **inferior, laryngeal** (**recurrent**) **nerve** arises from the left vagus anterior to the transverse aorta, and winds, from before backward, around the aorta below the attachment of the ductus arteriosus. It then ascends by the side of the trachea, where it lies in the groove between the trachea and the esophagus, along which it passes to be distributed like its fellow of the opposite side. In aneurysm of the arch of the aorta this nerve is subjected to pressure, giving rise to laryngeal disturbances. Both nerves have been described with the neck (Volume II.)

The vagus nerves give off superior and inferior cervical cardiac and thoracic cardiac branches. The **superior cervical cardiac branches,** usually two in number, join the superior cardiac nerves of the sympathetic. They will be described with the cardiac plexuses (see p. 161). The **right inferior cervical cardiac nerve** runs downward on the side of the trachea and enters the deep cardiac plexus. The **left inferior cervical cardiac nerve** joins the anterior or superficial cardiac plexus. It passes anterior to the arch of the aorta, and between it and the pleura, lying posterior to the phrenic nerve and in front of the left superior cervical cardiac nerve of the sympathetic. The **thoracic cardiac nerves** are

usually given off from the inferior, or recurrent, laryngeal (*recurrent*) nerves near their origin, and end in the deep cardiac plexus.

The **pulmonary branches** are the **anterior,** a few small twigs given off above the root of the lung, and which unite with branches of the sympathetic anterior to the bronchi to form the anterior pulmonary plexuses, and the **posterior,** which result from the breaking up of the vagus nerves into a network posterior to the bronchi, forming the posterior pulmonary plexus.

Besides these, the vagus nerves give off the meningeal, auricular, pharyngeal, and superior laryngeal branches which are described with the head and neck (Volume II).

The **cervical cardiac branches** of the sympathetic help to form the cardiac plexus (see p. 161). They are three in number upon each side: superior, middle, and inferior.

The **superior cardiac nerve** arises from the superior cervical ganglion of the sympathetic and sometimes from the sympathetic trunk between the superior and middle cervical ganglia. Both nerves are similar in the neck, but in the thorax they differ on the two sides. They pass downward upon the prevertebral fascia anterior to the longus colli muscle, posterior to the common carotid artery, and anterior to the inferior thyroid artery and the recurrent laryngeal (*recurrent*) nerve, communicating with the upper cervical cardiac branch of the vagus nerve, the middle cervical cardiac branch, and both the external and recurrent laryngeal (*recurrent*) nerves, and send filaments to the thyroid gland along the inferior thyroid artery. Beyond this point the course of the nerves on the two sides is different. Upon the right side the nerve passes either anterior or posterior to the subclavian artery, and thence along the innominate artery to the deep cardiac plexus behind the aortic arch. Upon the left side it lies to the left of the common carotid artery, and passes anterior to the transverse portion of the aortic arch between the vagus nerve and its inferior cervical cardiac branch to join the superior cardiac plexus.

The **middle cardiac nerve,** the largest, arises from the middle cervical ganglion, or the sympathetic trunk between the middle and inferior ganglia. On the right side it descends posterior to the common carotid, either anterior or posterior to the subclavian artery, to the trachea, on which it receives some filaments from the recurrent laryngeal (*recurrent*) nerve, and passes downward to join the deep cardiac plexus. The left middle cardiac nerve enters the chest between the common carotid and subclavian arteries to join the deep cardiac plexus. On both sides these nerves, while in the neck, communicate with the superior cardiac nerve, and in the thorax with the recurrent laryngeal (*recurrent*) nerves.

The **inferior cardiac nerve,** beginning at the inferior cervical or first thoracic ganglion, which ganglia are commonly fused, passes posterior to the subclavian artery and thence upon the side of the trachea to the deep cardiac plexus, communicating with the recurrent laryngeal (*recurrent*) and middle cardiac nerves.

The **cardiac plexus** (Plate CCCL) is formed by the cervical and thoracic cardiac branches of the vagus nerves, the cardiac branches of the recurrent laryngeal (*recurrent*) nerves, and the cardiac branches of the sympathetic. It is divided for convenience of description into a superficial and a deep plexus, although it consists of a continuous network of nerves.

The **superficial cardiac plexus** (anterior) is a small network of nerves anterior to the bifurcation of the pulmonary artery and in front of the right pulmonary artery below the concavity of the aortic arch and medial to the ductus arteriosus. It is formed by the left superior cervical cardiac branch of the left sympathetic, the inferior cervical cardiac branch of the left vagus (and sometimes also of the right), and branches from the deep cardiac plexus. At times a small ganglion, **the ganglion of Wrisberg** (**cardiac ganglion**), is found at the junction of these nerves. The dissection of the plexus must be made in a very good light, with the assistance of a good hand magnifying glass to aid in tracing the nerve filaments. Small branches can be traced to the right (*anterior*) coronary plexus, to the left anterior pulmonary plexus which lies in front of the left bronchus, and to the deep plexus.

The **right** (**anterior**) **coronary plexus** begins between the pulmonary artery and aorta, whence it extends forward on the right coronary artery; it is composed of filaments from the deep cardiac plexus but, mainly, from the superficial cardiac plexus. It supplies the right atrium and ventricle.

The **great,** or **deep, cardiac plexus** is found upon the front of the bifurcation of the trachea posterior to the arch of the aorta and just along the division of the pulmonary artery. The right half is formed by the two cervical cardiac branches of the right vagus and the three cardiac branches of the right cervical sympathetic, the cardiac branches of the right recurrent laryngeal (*recurrent*) nerve, and the thoracic cardiac branches of the right vagus. The left half is formed by the middle and inferior cardiac branches of the left cervical sympathetic, the thoracic cardiac branches of the left vagus nerve, the cardiac branches of the recurrent laryngeal (*recurrent*) nerves, and the superior cervical cardiac branch of the left vagus. The cardiac nerves not aiding in its formation are the left superior cervical cardiac branch of the sympathetic, and the inferior cervical cardiac branch of the left vagus, which form the anterior cardiac plexus. This great plexus forms the left (*posterior*) coronary plexus and a lesser portion of the right (*anterior*) coronary plexus, some of its branches going to the anterior

pulmonary plexuses and the cardiac auricles. Some of its branches on the right side pass in front of those behind the right pulmonary artery, the former going to the anterior pulmonary and the right (*anterior*) coronary plexuses, and the latter, to the right auricle and left (*posterior*) coronary plexus. On the left side its branches go to the left auricle and anterior pulmonary plexus, after which they send a few filaments to the superficial cardiac plexus, and continue backward to form the left (*posterior*) coronary plexus.

The **left (posterior) coronary plexus** passes between the left auricular appendix and the pulmonary artery to the left coronary artery, the branches of which its filaments follow to supply the heart muscle. It is formed by branches from the right, but mainly, from the left side of the great cardiac plexus, and is continuous with the deep cardiac plexus. It supplies the left atrium and ventricle.

Careful examination of the subpericardial heart surface and of its substance will reveal many sympathetic ganglia and fibers.

The **pulmonary plexuses** are found upon the root of each lung. The plexuses in front are called the **anterior,** and are formed by branches of the vagi given off at the upper border of the hilum, and sympathetic filaments. The plexuses behind are called **posterior,** and are formed by the vagi. These branches are much larger than the anterior branches, and unite with branches from the second, third, and fourth thoracic sympathetic ganglia. In fact, the posterior plexuses are formed by the vagi breaking up on the posterior surface of the hilum. These plexuses send filaments along the bronchi for distribution to the entire lung substance.

Dissection.—The right innominate vein and its relations having been studied, this vessel is now severed and reflected, thus exposing the arch of the aorta, appearing in the upper part of the cavity of the thorax, the superior mediastinum, like the crook of a shepherd's stick. It should be cleaned of its loose connective-tissue covering, care being taken not to sever the left phrenic and the left vagus nerves and the cardiac nerves to the superficial cardiac plexus, which pass downward in front of the arch of the aorta. Puncture of the pericardium should be avoided at this stage, as it is advisable occasionally to inflate this sac so as to define its upper outlines.

The **thoracic aorta** is divided for examination and description into three parts: *ascending aorta*, *transverse aorta*, or *aortic arch*, and *descending aorta*. It begins at the conus arteriosus of the left ventricle, where it is overlapped, on its left side, by the origin of the pulmonary artery, and, on its right side, by the appendix of the right auricle. Its origin is opposite the middle of the sternum on a level with the lower border of the third sterno-chondral junction. The

ascending aorta passes upward, forward, and to the right, in the line of the heart's axis for about five centimeters (two inches), as high as the upper margin of the second right costal cartilage. It extends slightly beyond the right border of the sternum at this point, where it is overlapped by the right pleura and the anterior margin of the right lung, and here the transverse aorta, or aortic arch, begins. From this point the transverse aorta passes transversely across the chest cavity and obliquely posteriorly from right to left to the left side of the fourth thoracic vertebra. These parts, with the exception of the portion of the ascending aorta that is covered by pericardium, and which belongs to the middle mediastinum, are contained in the superior mediastinum. Thence, as the descending thoracic aorta, it passes downward on the left side of the bodies of the vertebræ, gradually approaching the median line, and then passing through the diaphragm to become the abdominal aorta. This part is contained in the posterior mediastinum.

The **ascending aorta** with the pulmonary artery is largely covered by the fibrous layer of the pericardium. The part covered by pericardium is contained in the middle mediastinum; the remainder is located in the superior mediastinum. It is considerably bulged anteriorly and toward the right, just where its walls receive the direct impact of the column of blood forced out of the powerful left ventricle. This dilated or "bulged" portion is known as the **sinus of the aorta (bulb of aorta).** It is the part of the aorta which receives the greatest strain and which is generally the first to show atheromatous changes. It is, therefore, a favorable site for aneurysmal dilatation. The origin of the aorta at its ventricular attachments shows three little bellies externally: two in front, one on the right and the other on the left side, the latter being posterior to the pulmonary artery, and a third on the posterior surface. They are called **sinuses of Valsalva (aortic sinuses),** and mark the location of the aortic semilunar valves. From the two anterior, right and left, arise the right and left coronary arteries. This portion of the aorta, together with the pulmonary artery, is invested by an extension of the pericardial covering of the heart. Anterior to the beginning of the ascending aorta are the pulmonary artery and right auricular appendix. Higher up, the pericardium, connective tissue, the remains of the thymus gland, the right pleura, and the thin margin of the right lung separate it from the sternum. Posterior to it are the right pulmonary artery, the left auricle, and the right deep cardiac nerves. On its right side it abuts against the right auricle and the superior vena cava while on its left side it is in relation with the pulmonary artery, the left auricle, and the left pleura and lung.

The **transverse aorta,** or **aortic arch,** begins as a continuation of the ascending aorta behind the right margin of the sternum opposite the second costal cartilage and extends to within an inch of the suprasternal notch and may, at times, in

thin persons, be felt or even seen pulsating at the bottom of the suprasternal fossa. It extends to the left and backwards across the superior mediastinum to end at the left side of the lower border of the fourth dorsal vertebra. From its upper border arise, from right to left, the innominate, the left common carotid, and the left subclavian arteries. It is partly covered by the left pleura and lung, and to a less extent by the right pleura and lung. It is crossed by the left phrenic nerve, the left vagus nerve and its cardiac branches, the left superior cardiac branch of the cervical sympathetic, and the terminal part of the left superior intercostal vein; behind it lie the trachea, the deep cardiac plexus, the esophagus, the thoracic duct, and the left recurrent laryngeal (*recurrent*) nerve; above it are its three great branches and the left innominate vein; below it, in the concavity of the arch, are the divisions of the pulmonary artery, the remains of the ductus arteriosus, the left recurrent laryngeal (*recurrent*) nerve, as it winds around the arch from before backward, the superficial cardiac plexus, the left bronchus, and some lymph glands.

The **descending thoracic aorta,** beginning at the left lower border of the fourth dorsal vertebra, lies in the posterior mediastinum and is covered anteriorly by the pleura and root of the left lung and pericardium. Posteriorly, it lies against the spine, at first on the left side of the bodies of the vertebræ, and then approaches the median line. On its right side are the esophagus, thoracic duct, and vena azygos major (*azygos*); at the lower portion of the chest the esophagus is anterior and to the left of the aorta. Its left side is in relation with the pleura.

In consequence of the oblique position of the aortic arch, the left vagus nerve, left phrenic nerve, left bronchus, and the left pulmonary vessels pass anterior to the arch; on the right side these structures pass posterior to it. In the above description of the aorta, the terms "ascending, transverse, and descending portions of the aortic arch" have been discarded for the more accurate and appropriate terms, "ascending aorta," "transverse aorta, or aortic arch," and "descending thoracic aorta."

At this point it may be well to consider some of the symptoms produced by aneurysmal dilatation of the various portions of the thoracic aorta, inasmuch as a number of these symptoms are due to pressure upon adjacent structures.

If the aneurysm involves the artery in the neighborhood of the sinuses of Valsalva (*aortic sinuses*), rupture into the pericardial cavity may occur.

An aneurysm involving the ascending aorta along the right anterior wall, as it often does, enlarges toward the right pleura, and also forward; the superior vena cava may be compressed, leading to engorgement of the veins of the head and arms; perforation into the cava may occur, or it may burst into the pericardium, right pleural cavity, trachea, bronchus, or esophagus.

Very often aneurysm of the ascending aorta causes erosion of the sternum and costal cartilages and forms a bulging, pulsating mass in this situation, which may rupture externally.

Aneurysm of the transverse aorta may also erode the sternum, although more commonly it causes pressure on the trachea and esophagus, leading to dyspnea, dysphagia, cough, hemoptysis, etc.; or the thoracic duct may be compressed, leading to failure of nutrition. Irritation of the left recurrent laryngeal (*recurrent*) nerve may lead to laryngeal symptoms; pulsation in the suprasternal notch is frequently met with in dilated aorta, though it must be borne in mind that such pulsation may be due to the innominate artery. Inequality of the pulse in the carotids or radials may result from involvement of the great vessels which come from the arch, or from their obstruction by clots. There may be symptoms referable to pressure upon the sympathetic, vagus, and phrenic nerves.

Aneurysm of the descending aorta often causes severe pain from pressure on the intercostal nerves or from erosion of the vertebræ; pressure on the azygos and intercostal veins may lead to dilatation of the tributaries of these veins. The aneurysm may bulge externally in the midscapular region or rupture into the esophagus, left pleural cavity, or air-passages may occur.

The Coronary Arteries.—The first branches given off from the aorta are the right and left coronary arteries; they arise from the commencement of the ascending aorta and supply the muscle tissue of the heart. The **left, or anterior, coronary artery** arises from the left anterior sinus of Valsalva (*aortic sinus*) above the edge of the left anterior semilunar valve. It passes forward between the pulmonary artery and the appendix of the left auricle to the junction of the auriculo-ventricular (*coronary*) with the anterior interventricular groove. The **right coronary artery** arises from the right anterior sinus of Valsalva (*aortic sinus*) immediately above the free border of the right anterior semilunar valve. It passes forward between the pulmonary artery and the appendix of the right auricle; it then turns to the right, running in the auriculo-ventricular groove (*coronary sulcus*) to its junction with the posterior (*inferior*) interventricular groove. The further course of these vessels will be described with the heart.

The **innominate artery** is the first and largest of the three great branches of the transverse aorta. It is also the shortest of these vessels, being from three and three-quarters to five centimeters (one and a half to two inches) in length. From its origin at the beginning of the transverse aorta, or aortic arch, it passes upward and lateralward to the upper margin of the right sterno-clavicular joint, posterior to which it divides into the right common carotid and right subclavian arteries. It lies posterior to the right side of the manubrium sterni, the lowest

part of the sterno-hyoid and sterno-thyroid muscles, the remains of the thymus gland, the left innominate vein, and the right inferior thyroid vein, and the right inferior cervical cardiac branch of the vagus nerve. The right inferior thyroid vein and the left innominate vein cross the artery near its origin. It crosses obliquely anterior to the trachea. Upon its left side are the root of the left common carotid, the remains of the thymus gland, the trachea, and the right inferior thyroid vein near the bifurcation of the artery. Upon its right side are the right innominate vein, the right vagus nerve, and the pleura. The innominate artery gives off no branches, except occasionally the anomalous **thyroidea ima,** which usually ascends upon the front of the trachea to the thyroid gland. The thyroidea ima may arise from the transverse aorta. More rarely it may give origin to the vertebral, the internal mammary, or a bronchial, thymic, pericardiac, or tracheal branch. It may bifurcate lower than normal, thereby increasing the length of the first portion of the right subclavian artery; or it may divide higher than normal; in such a case it would be unusually long, and may then run upward and lateralward in front of the trachea, when it may be cut in the operation of low tracheotomy; it may run posterior to the trachea or esophagus.

The innominate artery may be tied for subclavian aneurysm, but the operation is almost uniformly followed by death, most often from secondary hemorrhage; consequently the surgeon prefers to tie the right common carotid and vertebral arteries, simultaneously with the innominate, in order to lessen the danger of hemorrhage. To reach the artery, the head is drawn backward, the shoulder depressed, and an incision seven and a half centimeters (three inches) long made along the anterior border of the sterno-mastoid muscle to the sterno-clavicular articulation, and from there lateralward along the medial one-third of the clavicle. After division of the integument, superficial fascia, and platysma muscle, the triangular flap is turned lateralward and a director is passed beneath the origin of the sterno-mastoid and the sternal portion of that muscle is divided; then the sterno-hyoid and sterno-thyroid muscles are divided on a director, near their sternal attachments, any veins that are encountered—as, for instance, the inferior thyroid or anterior jugular—are divided between ligatures. The carotid sheath should then be opened, exposing the common carotid artery, which is traced downward to its origin from the innominate; the right innominate and internal jugular veins and the vagus nerve are drawn to the right and the left innominate vein is pushed downward. With a curved aneurysm needle the ligature is passed round the artery, lateromedially and from below upward, care being taken not to injure the right pleural sac, nor to include any of the cardiac branches of the sympathetic.

The **left common carotid artery** arises from the aortic arch, just to the left of the innominate. It passes upward and to the left, reaching the root of the neck posterior to the left sterno-clavicular articulation, after which its course and relations nearly correspond to those of the right common carotid. The left common carotid artery can be conveniently described as consisting of a first, or thoracic, and a second, or cervical, portion. The course of the thoracic portion having been given, it remains to describe its relations. Anterior to it are the origins of the left sterno-hyoid and sterno-thyroid muscles, crossing its root is the left innominate vein, and the remains of the thymus gland and the fat and areolar tissue of the superior mediastinum intervene between it and the sternum. Posterior to it are the trachea, the esophagus, the thoracic duct, and the left recurrent laryngeal (*recurrent*) nerve; on its right side are the innominate artery, left inferior thyroid veins and part of the remains of the thymus gland, and the trachea. On the lateral side are the left vagus nerve, left pleural sac, and the lung; the left subclavian artery is also on the lateral side, but slightly posterior to the left common carotid artery.

The left common carotid artery may vary in the manner of its origin. It may be given off from a stem common to it and the right common carotid and subclavian arteries, and in that case it may cross the trachea obliquely and may be wounded in low tracheotomy. This is the most common of the variations of this artery, and was formerly described as the normal arrangement in man.

The **left subclavian artery,** the third great branch springing from the aortic arch, arises a little to the left of and somewhat posterior to the left common carotid from the aortic arch, and passes vertically upward. After arching over the apex of the left pleura and lung, it passes posterior to the scalenus anterior muscle at its insertion into the first rib. This constitutes the first part of the artery. From there on, both subclavian arteries are alike. Like the left common carotid artery, it may be divided into a thoracic and a cervical portion; the thoracic portion gives off no branches.

Anteriorly, it is covered by the left pleura and lung, the origins of the sterno-hyoid, sterno-thyroid, and sterno-mastoid muscles; the left vagus, phrenic, and cardiac nerves, and the left internal jugular and innominate veins are also anterior to it, the latter crossing its root. At the medial border of the scalenus anterior muscle the thoracic duct arches over the artery to empty at the junction of the internal jugular and subclavian veins. The phrenic nerve crosses the artery at the medial border of the scalenus anterior muscle and then runs downward parallel with the artery, but on a plane a little anterior to it. The left vagus nerve lies to the medial side of the artery, but between it and the left common carotid, crossing the root of the left subclavian artery just before crossing the arch of the aorta.

This artery likewise may vary somewhat in its origin, sometimes being given off from a left innominate artery or from a common trunk for the right and left common carotids and the left subclavian artery, Posterior to it are the esophagus, the thoracic duct, the inferior cervical ganglion of the cervical sympathetic, the longus colli muscle, and the bodies of the vertebræ. On the lateral side are the left pleura and lung. On the medial side are the trachea, esophagus, thoracic duct, and left recurrent laryngeal (*recurrent*) nerve.

The **pulmonary artery,** although belonging to the middle mediastinum, will be described now for convenience. It is wide and short, and arises from the conus arteriosus of the right ventricle anterior to the origin of the aorta, whence it ascends for about three and three-quarters centimeters (one and a half inches) to divide into two lateral arms, the right and the left pulmonary arteries, to be distributed to the lungs. It is invested with a visceral and a parietal layer of pericardium, like the aorta, and is separated from the sternum by mediastinal connective tissue, and sometimes by lung and pleura. Upon its right side, at its origin, are the right coronary artery, the right auricular appendix, and the ascending aorta; upon its left side, at its origin, are the left coronary artery, the left auricular appendix, and the left pleura and lung. The ascending aorta is posterior to it below, and the left auricle higher up; above, it divides under the transverse aorta, with which it is connected by the remains of the ductus arteriosus, at a point a little to the left of its division. Its direction is upward, posterior and to the left.

The **right pulmonary artery,** the longer branch, passes directly lateralward under the aortic arch and posterior to the ascending aorta and the superior vena cava to the root of the right lung, there to divide into a large upper branch to the upper lobe, which gives off a branch to the middle lobe, and a smaller lower branch to the lower lobe. The right pulmonary artery is at first in relation anteriorly with the ascending aorta, the superior vena cava, the phrenic nerve, the anterior pulmonary plexus, and the pleura; posteriorly, with the right bronchus; above, with the aortic arch, and below, with the left auricle and the pulmonary veins. At the root of the lung the right bronchus is above and posterior, and the pulmonary veins below and anterior to the right pulmonary artery. These branches run the same course as the bronchi and are distributed to the lung tissue. Their terminal branches do not anastomose.

The **left pulmonary artery** passes directly lateralward anterior to the descending thoracic aorta and the left bronchus to the root of the left lung, where it divides into an upper and a lower branch for distribution to the upper and lower lobes of the left lung. The left pulmonary artery is in relation, below and posteriorly, with the left bronchus, on account of the more vertical course of the

PLATE CCCLI.

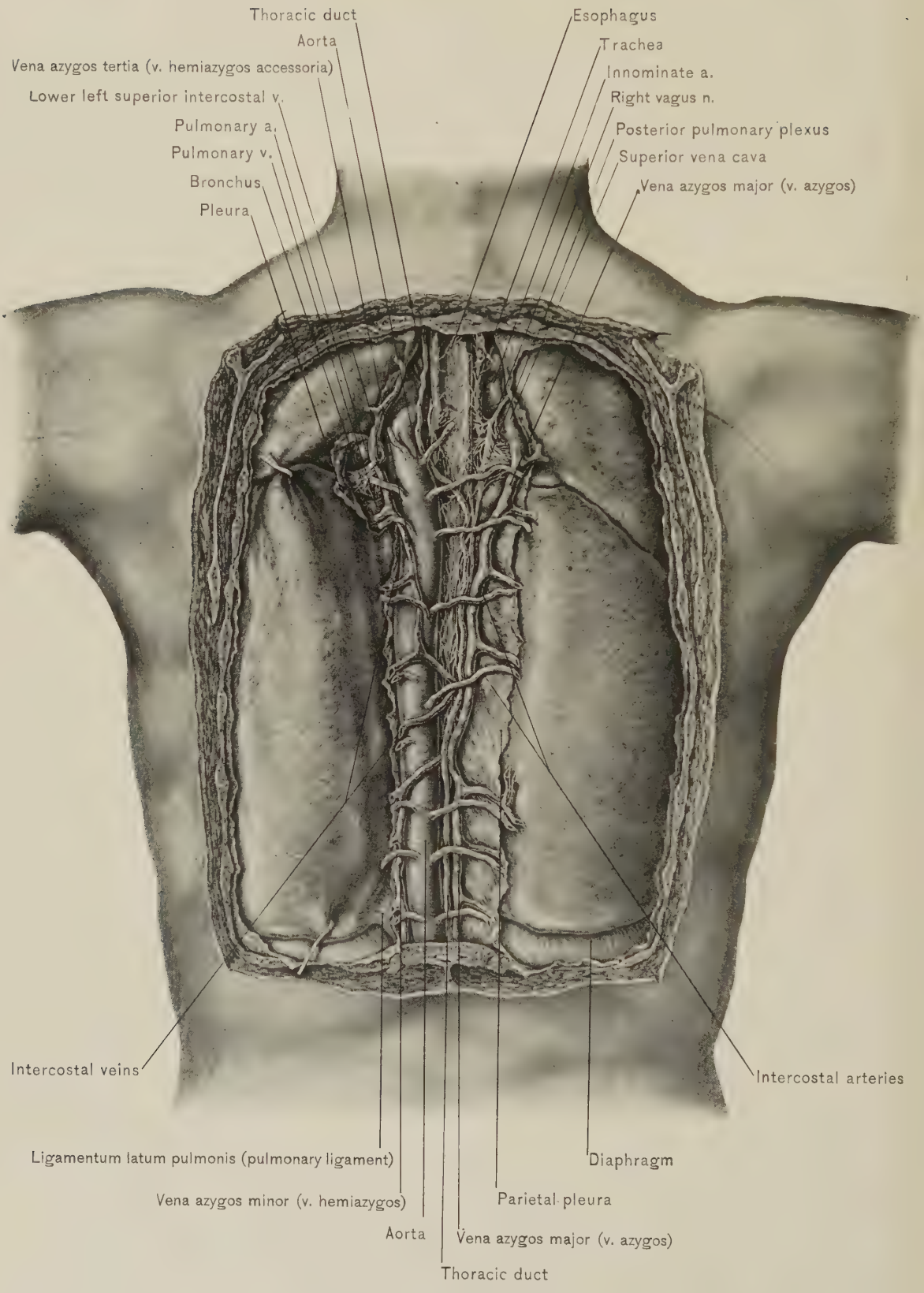

POSTERIOR MEDIASTINUM, VIEW OF TRACHEA, BRONCHI, LUNGS, AND HEART FROM BEHIND.

latter. The pulmonary veins lie below and anterior to it, and it is crossed anteriorly by the phrenic nerve and the left anterior pulmonary plexus, and posteriorly by the thoracic aorta, the left vagus nerve, and the posterior pulmonary plexus.

The dissector will observe, at this stage of the work, the cartilaginous rings of the trachea above the aortic arch, between the innominate and left common carotid arteries; and under and posterior to the left pulmonary artery he will observe the left bronchus, the right being hidden by the ascending aorta and the adjoining vena cava.

The **trachea** (Plate CCCLI), descends from the neck, in front of the esophagus, to the level of the fourth or fifth thoracic vertebra, where it divides into the two bronchi. This point about corresponds to the lower margin of the manubrium at the angle of Ludwig (*sternal angle*); therefore the lower portion of the trachea will be seen to occupy the superior mediastinum. It lies in the median plane except at its lower end, which is slightly to the right. Anterior to it lie, in the thorax, the manubrium and the origins of the sterno-hyoid and sterno-thyroid muscles, the remains of the thymus gland, the deep cervical fascia, the transverse aorta which crosses the trachea just above its bifurcation, the innominate and left common carotid arteries, which are crossed by the left innominate vein, and the deep cardiac plexus. Upon its right side are the innominate artery, the right vagus nerve, and the pleura, while upon its left are the left common carotid artery and the pleura, the left vagus, the left recurrent laryngeal (*recurrent*) nerve, and the cardiac nerves. Its cervical portion and the tracheotomy operations are described with the neck (Volume II).

Structure.—The trachea is a cartilagino-membranous tube, plano-cylindrical on cross-section, and composed of incomplete cartilaginous rings, deficient posteriorly; a fibro-elastic membrane enveloping and uniting these rings; muscle fibers; a layer of yellow elastic fibers, and, as an internal lining, mucous membrane.

The rings vary in number from sixteen to twenty. Two cartilages are occasionally partly united. Of these, seven or eight are found in the trachea above the superior aperture of the thorax, and the remainder in the thoracic portion. The first ring may fuse with the cricoid cartilage, and is usually broad. The last ring at the bifurcation of the trachea has a somewhat Y-shaped appearance anteriorly, a process extending downward and posteriorly from the middle of the cartilage. The trachealis muscle consists of two layers of unstriped muscle, and is found posteriorly where the cartilages are deficient. The fibro-elastic membrane envelops the rings and binds them together; it also helps to close the trachea where the rings are deficient. Yellow elastic fibers are found as a layer

in the posterior part of the trachea, but are also observed throughout the mucous membrane. The mucous membrane is lined with ciliated columnar epithelium and contains numerous glands in the part lining the posterior portion of the trachea. The trachea is about ten to eleven centimeters (four to four and a half inches) long in the male and nine to ten centimeters (three and a half to four inches) long in the female.

Blood Supply.—The tracheal arteries are usually derived from the inferior thyroid artery. The veins end in the thyroid plexus and the inferior thyroid vein.

Nerve Supply.—The trachea is supplied by the vagus and inferior laryngeal branches of the recurrent laryngeal (*recurrent*) nerves, and by filaments of the sympathetic nerve.

The **bronchi** (Plate CCCLII) are the two branches of the trachea at its bifurcation. They occupy the middle mediastinum, being component parts of the roots of the lungs, but are described here for convenience. The differences between the two bronchi may be summed up as follows: the right bronchus is about two and a half centimeters (one inch) long, is shorter and more horizontal than the left, and has a larger caliber; the left bronchus is about five centimeters (two inches) long, and is longer, narrower, and more vertical than the right. The two bronchi diverge at an angle of about 130 degrees. The right bronchus has arching over it from behind the vena azygos major (*azygos*) on its way to the vena cava, while the horizontal right pulmonary artery lies at first below, and then anterior to the bronchus; below the first division of the right bronchus the pulmonary artery lies posterior to the bronchus. The left bronchus crosses anterior to the esophagus, the thoracic duct, and the descending aorta, under the transverse aorta, and lies behind the left pulmonary artery. The orifice of the right bronchus being larger than that of the left and placed nearly under the center of the trachea, foreign bodies usually enter the right bronchus.

In certain cases of aneurysm of the transverse and the beginning of the descending aorta the pulsation of the aneurysmal sac leads to depression of the left bronchus, with consequent downward movement of the trachea. If in such cases the larynx is lightly grasped between the thumb and finger, this traction upon the trachea, synchronous with the systole of the heart, is felt. This sign is known as the "tracheal tug."

Foreign bodies entering the air-passages may lodge in the larynx, in the trachea, or may enter one of the bronchi, usually the right one. Due largely to the advances of Jackson and his associates in this country, the procedure for the removal of foreign bodies from the trachea or bronchi has been revolutionized. The procedure is known as bronchoscopy. These operators can remove a foreign body from the primary or secondary bronchi with surprising skill.

PLATE CCCLII.

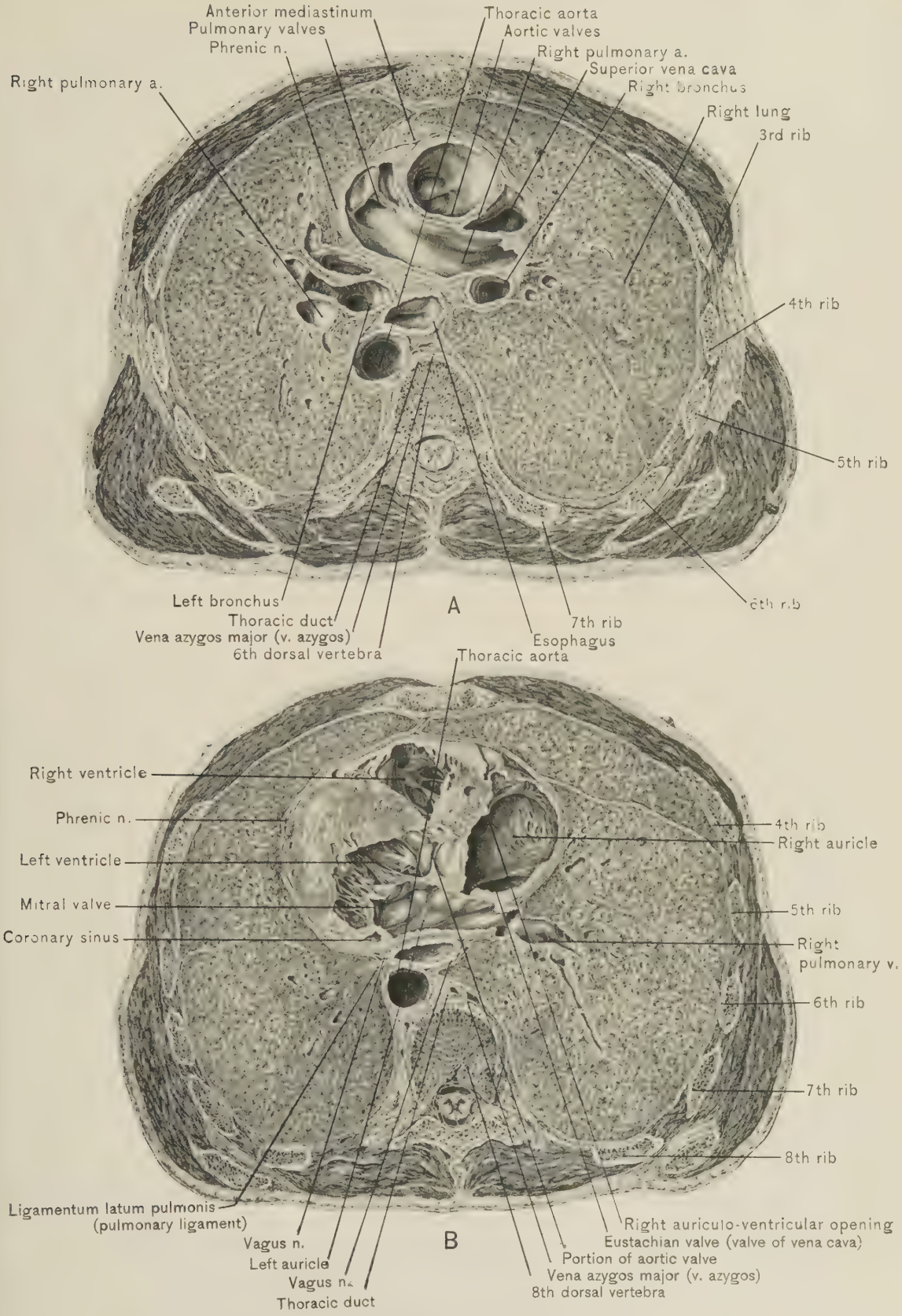

CROSS-SECTIONS OF THE THORAX.

(A) THROUGH THE ROOTS OF THE LUNGS. (B) BELOW THE ROOTS OF THE LUNGS.

The **esophagus,** or **gullet,** is a muscular tube, beginning at the level of the sixth cervical vertebra opposite the lower border of the cricoid cartilage, and is the portion of the alimentary canal connecting the pharynx with the stomach. It consists of a cervical and a thoracic portion. *The cervical portion* has been described with the neck (Volume II). *The thoracic portion* is the continuation downward of the esophagus posterior to the trachea and anterior to the spinal column, through the superior and posterior mediastinal spaces. The esophagus follows the curves of the cervical and dorsal spine, till it passes anterior to and to the left of the aorta just before penetrating the diaphragm to empty into the stomach. Besides the deviation to the left at the diaphragm it shows a lateral curvature, also to the left, at the root of the neck. Its caliber is narrowed in three localities; one is at the beginning, opposite the cricoid cartilage; another seven centimeters (two and three-quarters inches) below that point and one at the point where it passes through the diaphragm. Moulton found the caliber at those points to be a little over twelve millimeters (one-half inch) in diameter. Elsewhere it is about two centimeters (three-quarters of an inch). The constrictions at these points are apt to intercept bodies that are too large; they also show the effects of swallowed corrosive substances more definitely. Stricture of the esophagus may result from contracting scars following ulceration.

Foreign bodies impacted in the esophagus are very apt to lead to ulceration that may open into the adjacent parts, such as the aorta, the trachea, and the vena azygos major (*azygos*). These foreign bodies usually lodge at one of the three points of constriction. They are best removed by esophagoscopy. Carcinoma of the esophagus is also apt to invade the adjacent parts, especially the trachea or bronchi. When it spreads to the pleura, the right is the one usually invaded, since it is in more intimate relation with the esophagus. Cancer of the esophagus may also infiltrate the thyroid body, the pericardium, and the lung. Attempts at removal of carcinomatous growths of the thoracic esophagus have been made successfully by both the transpleural approach and posterior mediastinotomy. Of the two operations the transpleural approach gives a wider field under the eye and seems to me to be the more logical method.

If cancer or ulcerative disease affects either the left bronchus or the esophagus at the intersection, a communicating opening may form between the two, resulting in a septic pneumonia, caused by the passage of food into the lung.

Relations.—In the neck, the esophagus is in relation anteriorly with the trachea, the posterior part of the left lateral lobe of the thyroid gland, and the left recurrent laryngeal (*recurrent*) nerve. Posteriorly, it rests upon the vertebral column and the left longus colli muscle. On its left side are the common carotid and subclavian arteries, the inferior thyroid artery, and the thoracic

duct. On its right side are the right common carotid artery and the right recurrent laryngeal (*recurrent*) nerve.

In the thorax the esophagus has anterior to it, in the superior mediastinum, the trachea, the beginning of the left bronchus, the transverse aorta, and the left common carotid and subclavian arteries. In the posterior mediastinum it has anterior to it the posterior surface of the pericardium. Posteriorly it comes in relation with the vertebral column, the left longus colli muscle, and the thoracic duct in the superior mediastinum, and, in the posterior mediastinum, with the vertebral column, the thoracic duct, the vertebral portion of the right aortic intercostal arteries, the vena azygos minor (*hemiazygos*), and the lower part of the thoracic aorta. Laterally it comes in relation in the superior and posterior mediastinal spaces with the pleura and the vagus nerves, which latter form the *plexus gulæ* (*esophageal plexus*). The aorta is to the left, and the vena azygos major (*azygos*) to the right of the esophagus, and the left vagus nerve passes down anterior, and the right vagus nerve posterior to the esophagus to the stomach.

Structure.—The wall of the esophagus is composed of three coats: muscular, submucous, and mucous. The muscular coat consists of voluntary muscle fibers in the upper one-third or one-half of its extent, arranged in a longitudinal and a circular manner, and is rather thick. The submucous coat contains many racemose glands and serves to connect the muscular and mucous coats. The mucous coat presents deep longitudinal folds, and is lined with stratified squamous epithelium.

Blood Supply.—From the inferior thyroid, the aorta, and branches of the gastric (*left gastric*) and phrenic arteries.

Nerve Supply.—Mainly, from the vagus nerves, through the plexus gulæ (*esophageal plexus*).

The *lymph glands* of the superior mediastinum, called cardiac glands, are found anterior to the arch of the aorta, lying on the upper part of the pericardium. They receive the lymphatics from the upper and anterior part of the pericardium and from the right side of the heart, from the thymus gland, and from the anterior mediastinal glands. Their efferent vessels run upward on either side of the trachea and empty into the right lymphatic duct and the thoracic duct respectively.

The **thoracic duct** can be described as consisting of three parts—abdominal, thoracic, and cervical. It occupies the superior mediastinum in part of its course. It begins at the receptaculum chyli (*cisterna chyli*) at the level of the second lumbar vertebra, enters the thorax through the aortic opening in the diaphragm, and runs upward posterior to the esophagus and to the right side of the aorta in the posterior mediastinum. It then passes through the superior mediastinum

PLATE CCCLIII.

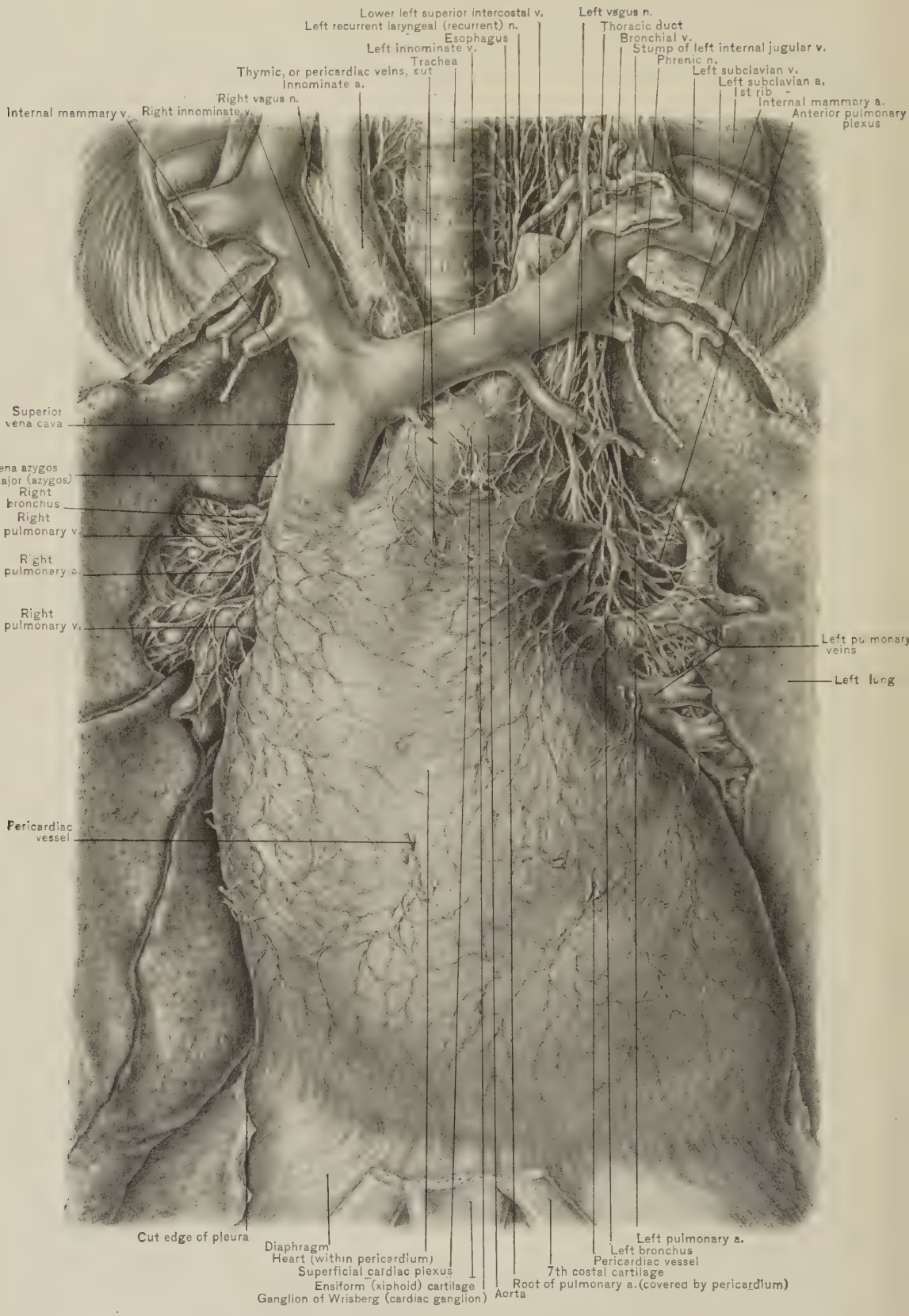

PERICARDIUM AND ROOTS OF THE LUNGS.

and leaves the thorax by passing through its upper opening to enter the neck. It empties at the junction of the left subclavian and internal jugular veins. It will be more fully described with the posterior mediastinal space.

THE MIDDLE MEDIASTINUM

The **pericardium** (Plate CCCLIII) is the fibro-serous investure of the heart and the roots of the great vessels, enabling this most active organ to glide freely and quickly within its limited area without needless friction. Its form can best be demonstrated by inflating it with a blow-pipe. The sac thus distended will appear narrow above at its attachment to the great vessels, and broad below where it adheres to the central tendon and left leaflet of the diaphragm, being therefore conical in outline, with its apex above and its base below, the latter extending more to the left side. Vertically the pericardium reaches from the xiphoid process to the middle of the manubrium. Opposite the fourth intercostal spaces it reaches six centimeters (two and a quarter inches) to the right of the median line. It consists of a fibrous and a serous layer.

The **fibrous layer** comprises all the parietal portion of the sac, and is loosely attached everywhere, except at the inferior vena cava. It extends from the base of the heart along the great vessels, including the ascending aorta, the ductus arteriosus, the entire pulmonary artery, the superior vena cava, and the pulmonary veins. Above, over the great vessels, it is continuous with the deep cervical fascia. The *sterno-pericardiac ligaments*, two slender bands of fibrous tissue, connect the back of the sternum and the front of the pericardium above and below.

The **serous layer,** like all serous layers, is smooth and glistening, being lubricated by a small amount of serous fluid that permits free movement of the heart. It is reflected from the deep surface of the fibrous layer, which it lines as the parietal portion, to the roots of the great vessels and the surface of the heart, constituting there the visceral portion. The portion of the serous layer on the heart proper is frequently called the epicardium. As the serous layer passes from the fibrous layer to the heart it completely envelops the aorta and the pulmonary artery in a single sheath, while the veins each receive a partial covering, a portion of one surface lying in contact with the fibrous pericardium. Between the layers is the cavity of the pericardium, which like all serous cavities, except the peritoneal cavity of the female, which is open by way of the Fallopian (*uterine*) tubes, is closed.

The serous layer by its reflection forms a number of pouches. One of these, the *oblique sinus*, extends upward behind the left auricle, between the inferior

vena cava and the lower left pulmonary vein, to end behind between the pulmonary veins of both sides. It is limited above by the reflection of the serous pericardium from the fibrous pericardium on to the upper part of the auricle. It partially lines the pulmonary veins, whose investment is completed by the smaller pouches derived from the great sac dipping in between the vessels to meet the reflections of the oblique sinus. Pouches are also found between the inferior vena cava and the upper right pulmonary vein, and the left pulmonary artery and the upper left pulmonary vein. One of these, the transverse sinus, is a space behind the aorta and pulmonary artery, through which the dissector can pass a finger from side to side. It is bounded anteriorly by the aorta and the pulmonary artery, posteriorly by the auricles, and superiorly by the right pulmonary artery and the reflection of the serous pericardium from the auricles on to the arteries. A knowledge of these sinuses is important when it becomes necessary to drain the pericardium in suppurative pericarditis.

The *vestigial fold of Marshall* (*ligament of left vena cava*) is a reduplication of the serous layer of the pericardium between the left pulmonary artery and vein and incloses some areolar tissue and fat, together with a fibrous band, the obliterated *left duct of Cuvier*, or left superior vena cava, which is continuous above with the left superior intercostal vein and at the heart with the oblique vein of Marshall (*oblique vein of left atrium*) and the left auricle.

The inferior vena cava is but partially invested by the serous layer, while the aorta and the pulmonary arteries receive complete tubular investments.

Relations.—Anterior to the pericardium are the thymus gland, or its remains, areolar tissue, lymph glands, the sterno-pericardiac ligaments, the triangularis sterni (*transversus thoracis*) muscle, the internal mammary vessels, and the sternum. On the sides are the mediastinal pleura, the lungs, and the phrenic nerves and vessels between the mediastinal pleura and the side of the pericardium. Posteriorly, it lies on the bronchi, esophagus, vagus nerves, deep cardiac and pulmonary plexuses, and the descending aorta.

Blood Supply.—From the aorta, and the bronchial, esophageal, phrenic, internal mammary, and musculo-phrenic arteries.

Nerve Supply.—From the phrenic, sympathetic, and right vagus nerves.

The *lymphatics* of the pericardium empty into the anterior, superior, and posterior mediastinal glands and the tracheo-bronchial glands.

Pericarditis, an inflammation of the pericardium, pursues the usual course of serous inflammations; that is, the inflammation may result in an exudate of serum, fibrin, or pus. At first the membrane becomes swollen from vascular turgescence and the surface becomes dry. In consequence of this the rubbing together of the surfaces of the parietal and visceral layers is distinctly heard

through the chest-wall and is synchronous with the beat of the heart. Adhesions may form, but the intense activity of the heart repeatedly tears them apart, thus giving a ragged, shaggy appearance to the internal surface of the serous layer of the pericardium. On the other hand, the layers may unite in places around the great vessels and base of the heart, where there is less motion, and the union may then gradually extend downward and fix the entire heart to its enveloping sac, each successive encroachment from above upon the heart's freedom of movement making it more possible for the union to extend toward the apex. In the serous form of exudate the effusion may be so abundant as to distend the pericardial sac. In acute cases the pericardium may contain as much as from three hundred and sixty to five hundred and forty cubic centimeters (twelve to eighteen ounces) of serum, and in chronic cases it may reach one and a half liters (three pints). The symptoms due to pressure from these large accumulations vary with the position of the patient, which determines the direction of pressure. In the dorsal position the pressure is upon the esophagus, and may cause dysphagia. Upward pressure upon the right auricle and vena cava, as well as the compression of the heart itself, may cause venous turgescence and possibly also edema of the face and neck. It also causes forward projection of the sternum, or bulging of the interspaces, and, of course, displacement of the lungs, especially the left one, this being particularly marked in children. In the last instance the area of cardiac dulness is increased, the heart sounds are muffled, and the apex-beat is no longer perceptible. In the purulent form of exudate the sac may be opened and irrigated with antiseptic solutions through one of the interchondral spaces, or the left xipho-costal angle; portions of the costal cartilages or sternum may be removed when required and a drainage-tube inserted.

Paracentesis of the pericardium (Plate CCCXLI) may become necessary when the fluid is not absorbed. This may be done either through the fourth left intercostal space close to the sternum, avoiding the internal mammary artery; or through the fourth interspace two and a half centimeters (one inch) from the left sternal border; or through the fifth interspace three and four-fifths centimeters (one and a half inches) from the left border of the sternum; or through the left xipho-costal angle. This has been mentioned under surface anatomy of the thorax.

Pericarditis may cause a *reflex cough* through irritation of the phrenic nerves, and through venous engorgement of the lungs due to interference with the pulmonary circulation caused by cardiac compression.

Drainage of the Pericardium.—In suppurative disease of the pericardium the drainage can be adequately established by the method of Poole. The incision

begins at the middle of the sternum at the level of the lower margin of the fourth costal cartilage; curving, it passes inferiorly and to the left to the upper margin of the chondro-sternal junction of the fifth, then downwards close to the left edge of the sternum crossing the fifth and sixth cartilages to the middle of the seventh; curving laterally, it follows the seventh costal cartilage. This gives an incision of the shape of an ellipse. The cartilages are fractured about five centimeters (two inches) from their sternal ends and at the sternal ends and removed. The internal mammary vessels are ligated. The edge of the pleura is displaced lateralward with the triangularis sterni (*transversus thoracis*).

Dissection.—Open the pericardium by a vertical incision extending from its apex to its base, and reflect the two parts, thus exposing the following structures: parts of the right and left ventricles, and between them the interventricular sulcus, the right auricle with its appendix overlapping the root of the aorta; the appendix of the right auricle overlapping the root of the pulmonary artery, the auriculo-ventricular (*coronary*) sulcus; the pulmonary artery, covering the root of the aorta; the ascending aorta, the superior vena cava, and the right and left coronary arteries. By raising the heart it will be found that the greater part of the left ventricle lies posteriorly, together with a small portion of the right ventricle. Above the ventricles posteriorly will be seen the coronary sinus, running in the auriculo-ventricular groove (*coronary sulcus*). Into it can be seen emptying the cardiac veins and the oblique vein of Marshall (*oblique vein of left atrium*). The roots of the pulmonary veins and the inferior vena cava above the diaphragm can also be observed behind.

The **heart** (Plates CCCLIV and CCCLV) is a hollow, muscular organ of pyramidal shape with its apex directed downward, anteriorly and to the left, beating against the fifth intercostal space about two and a half centimeters (one inch) to the medial side of the mid-clavicular line. It rests upon the central tendon and part of the left leaflet of the diaphragm and is posterior to the lower two-thirds of the sternum. It is suspended from the neck by the aorta and the three great branches of its transverse portion, and by the downward prolongation upon the aorta and pulmonary artery of the deep cervical fascia, which blends with the pericardium, and it is also supported from the roots of the lungs by the pulmonary arteries and veins. The direction of its base is the opposite of that of the apex—*i. e.*, upward, posterior, and to the right; the base occupies the same level as the middle four thoracic vertebræ, largely filling the space between them and the sternum. Its position is considerably changed by disease of neighboring organs. Thus it will be crowded to one side by pleural effusions as well as by collapse or retraction of a lung, or lateral curvatures of the spine that narrow one of the pleural spaces. It is pressed downward by tumors of the superior

PLATE CCCLIV.

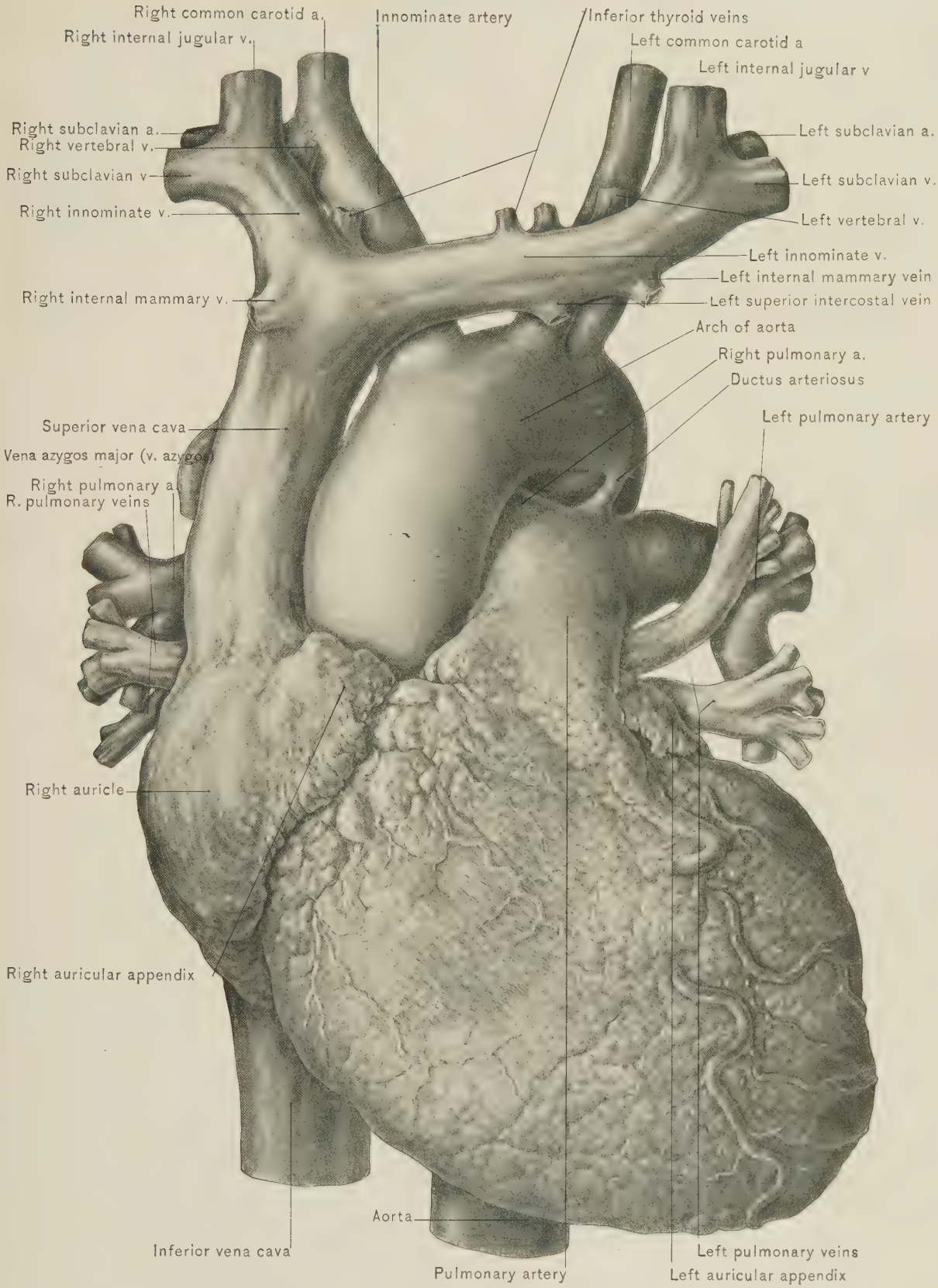

ANTERIOR VIEW OF THE HEART AND ITS VESSELS.

PLATE CCCLV.

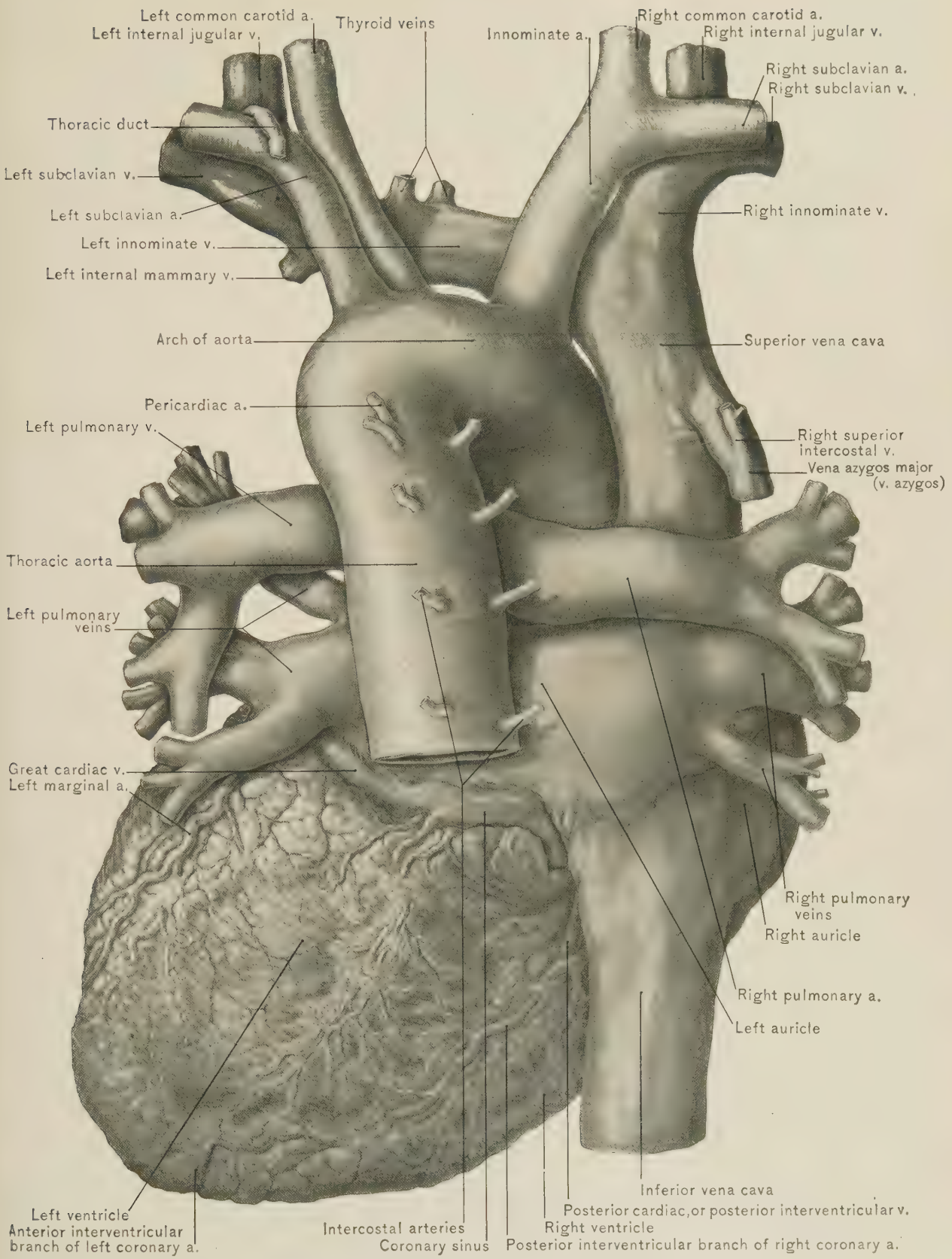

POSTERIOR VIEW OF THE HEART AND ITS VESSELS.

mediastinum and drawn downward by marked diminution in size of the adjacent abdominal viscera. Abdominal dropsy or tumors will push it upward.

The front of the heart, as seen when the pericardium is opened, is composed mainly of the right ventricle below, and the right auricle above, only a narrow strip of the anterior edge of the left ventricle being visible upon the left side. The right and lower margin, formed by the right ventricle, is sharp and thin, and is therefore called *margo acutus;* that to the left and above, formed by the much thicker left ventricle, is full and round, and consequently designated *margo obtusus.*

The heart should be raised from its bed so that the fingers may pass behind it and note the height to which the pericardium extends up the back of the great vessels. The shape of the back of the sac should be noted. Backward pressure of the finger will reveal the bodies of the thoracic vertebræ. Lateral pressure will reveal the resistance of the lungs, especially if inflated. If the segment of the sternum and its attached cartilages is replaced, the topography of the heart may be profitably considered; but as this organ is collapsed, it should be inflated. This may be done by rapid puffs through the superior vena cava, which will distend the right side and the pulmonary artery. If the arterial injection has not ruptured the aortic valves and filled the left side, this portion may be inflated through one of the pulmonary veins. While the heart is thus kept in distention by one or two persons making a succession of sharp sudden puffs through suitably long and curved blow-pipes, another can indicate its superficial relations. This practice is too valuable to neglect.

The detailed anatomy of the heart is not well shown in a dissecting-room specimen, but this must suffice if none other is at hand. Should another heart be available, it is well to open the attached specimen so as to show the valves *in situ,* that they may be compared with the anterior surface of the chest. A fresh bullock's heart serves admirably for demonstration.

The heart has four chambers: two right and two left, or two upper and two lower. The upper, smaller, and weaker ones are the **auricles,** so called because of their ear-like shape, and the lower and stronger are called the **ventricles.** The auricles receive blood for transmission to the ventricles, which then force it onward. The right side of the heart forces the blood through the lungs for oxidation and the left side sends it through the body at large for nutrient purposes. The septa between these cavities are indicated by furrows. The right auricle and the right ventricle constitute the venous side, while the left auricle and the left ventricle constitute the arterial side of the heart.

The furrows are called **interventricular** and **auriculo-ventricular** (**coronary**), the former either anterior or posterior and the latter either right or left, the

designation being amply expressive of their locations. They lodge branches of the coronary arteries.

The **right coronary artery** passes at first forward between the pulmonary artery and the right auricular appendix and then downward and lateralward along the right auriculo-ventricular groove (*coronary sulcus*) to the posterior surface of the heart, where it gives off a descending branch, the interventricular, that passes along the posterior interventricular groove to anastomose at the apex with a similar branch from the left coronary in front. The right coronary continues into the posterior part of the left auriculo-ventricular groove (*coronary sulcus*) to anastomose with a similar branch of the left coronary artery. On its way it sends a branch along the margin of the right ventricle, called the marginal branch. It also gives off auricular branches to the right auricle and a preventricular branch to the front of the right ventricle, as well as branches to the roots of the aorta and to the pulmonary artery. It supplies both ventricles and the right auricle, as well as the posterior interventricular septum.

The **left coronary artery,** the smaller, emerges from between the left auricular appendix and the pulmonary artery to enter the front of the left auriculo-ventricular groove (*coronary sulcus*) where it divides into two branches, one, the interventricular branch, passing down the anterior interventricular groove to anastomose at the apex with the corresponding posterior branch, the other, the transverse branch, passing around the left auriculo-ventricular groove (*coronary sulcus*) to the back of the heart, there to anastomose with the like branch of the right coronary artery. It gives off auricular branches to supply the left auricle; a marginal branch along the left margin of the heart, and a smaller branch to the left auricle, both ventricles, and the roots of the aorta and pulmonary artery.

The **three large veins of the heart** are the great, the anterior, and the posterior cardiac; they accompany the coronary arteries and return the blood from the walls of the heart.

The **great cardiac vein** begins at the apex and passes up the anterior interventricular furrow to the base, when it curves to the left, along the left auriculo-ventricular groove to the back of the right auricle, where it empties into the coronary sinus. Numerous veins from the ventricles and auricles empty into it.

The **posterior cardiac,** or **posterior interventricular** (**middle cardiac**), **vein** ascends in the posterior interventricular groove from the apex to the base, receiving the veins from the back of both ventricles, to empty into the coronary sinus, where it is supplied with a valve. Several small **anterior cardiac veins** collect the blood from the front of the right ventricle and empty into the front of the right auricle. The largest of these runs along the right margin of the heart, and is called the **vein of Galen.**

PLATE CCCLVI.

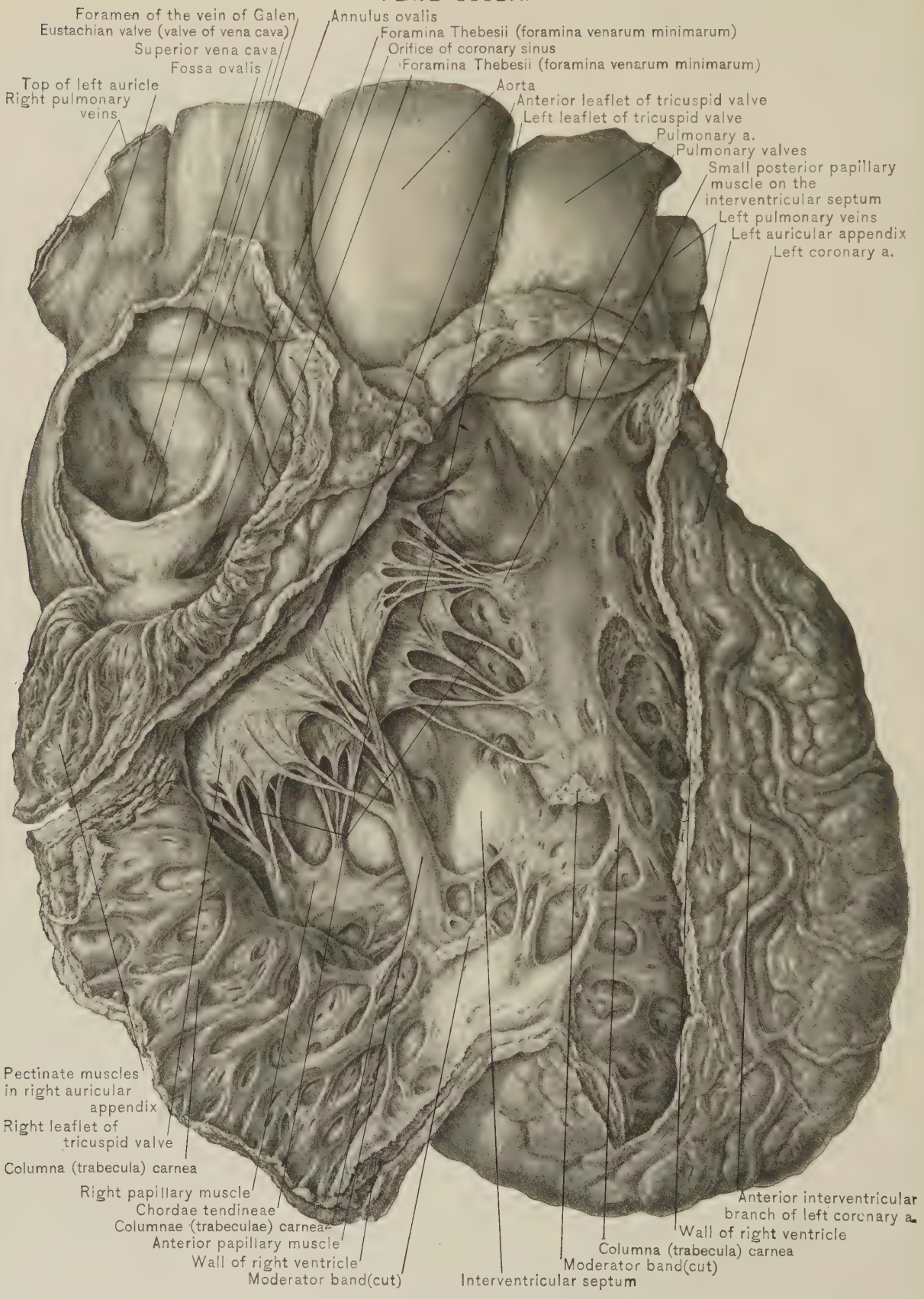

RIGHT AURICLE (ATRIUM) AND VENTRICLE.

The **coronary sinus** is the continuation of the great cardiac vein, greatly increased in caliber. It is about two and a half centimeters (one inch) long and runs along the posterior surface of the heart in the auriculo-ventricular groove (*coronary sulcus*) and empties into the right auricle, where its orifice is guarded by the Thebesian valve (*valve of coronary sinus*). From the vestigial fold of the pericardium the oblique vein of Marshall (*oblique vein of left atrium*) may be traced along the posterior wall of the left auricle to its termination in the coronary sinus. It is rarely pervious and represents the obliterated portion of the fetal left duct of Cuvier (left superior vena cava).

The **coronary plexuses,** derived from the cardiac plexuses, have been described; they accompany the coronary artery. Many ganglia can be observed near the auriculo-ventricular groove (*coronary sulcus*) under the pericardium.

Considerable fat often invests the heart, especially at the base, even in lean individuals, though this is wanting in those who die of wasting diseases. The coronary arteries are generally embedded in fat at their origin and for some distance beyond. If the entire heart is covered with a distinct layer of fat, the condition is abnormal.

Size, Weight, and Capacity.—The size of the heart is said to equal that of the closed fist of the individual. In the adult it averages from twelve to fifteen centimeters (four and three-quarters to six inches) in length; from nine to eleven centimeters (three and a half to four and a quarter inches) in its greatest breadth, and from five to eight centimeters (two to three and a half inches) in thickness.

The average weight of the heart is about three hundred to three hundred and sixty grams (ten to twelve ounces) in the male and about sixty grams (two ounces) less in the female. The average capacity of its chambers is sixty cubic centimeters (two ounces) each, although they are not filled simultaneously in the living state, as will appear in studying the circulation.

Dissection.—Remove the heart by cutting the vessels as far away from it as possible, care being taken to leave the bronchi intact. The interior of the heart is best studied by opening its cavities in the order in which the blood flows through them. The accompanying instructions as to the time and manner of opening these should be strictly adhered to. A rubber tube containing water under several pounds of pressure should be at hand to demonstrate the action of the valves, as the blow-pipe seldom suffices for this purpose.

The **right auricle** (**right atrium**) (Plate CCCLVI) is thin, its walls being only about a line in thickness, and is composed of an appendix auriculæ, overlapping the origin of the aorta, and the main portion, called the sinus of the auricle.

It should be opened by an incision extending between the openings of the two venæ cavæ, and another from the middle of this to the tip of the appendix. Its interior should then be gently cleansed of its dark blood, when the following points are to be observed:

The **openings of the right auricle** (**atrium**) are:

(A) The *superior vena cava*, in the upper anterior part, bringing blood from the head, neck, upper extremities, and upper part of the thorax, the direction of the current being toward the ventricular opening.

(B) The *inferior vena cava*, the larger cava, directed upward and medialward at the lower part of the auricle, where it hugs the diaphragm, the direction of the current being toward the auricular septum.

(C) The *orifice of the coronary sinus* is situated between the preceding two and a little toward the ventricular opening. From it flows most of the venous blood collected from the heart substance by the cardiac veins. At its orifice is a fold of the lining membrane of the heart, the endocardium, which is called the valve of the coronary sinus, or valve of Thebesius. The sinus is dilated back of its opening, but is constricted at its junction with the great coronary vein, where two unequal valvular segments prevent regurgitation.

(D) The *foramina of Thebesius* (*foramina venarum minimarum*) are numerous minute openings, some of which are the openings of small veins, called venæ cordis minimæ, or Thebesii, in different portions of the inner surface of the auricle; sometimes they are merely the openings of small cecal ducts. The right marginal vein is quite constant, and opens below the superior vena cava on the septal wall. It is also called the vein of Galen.

(E) The *right auriculo-ventricular orifice* will be described further on.

The **Eustachian valve** (**valve of vena cava**) is a crescentic fold of endocardium, containing a few muscle fibers, situated between the openings of the inferior vena cava and the right ventricle. It is attached to the former by the convex margin, its free concave edge is attached by one end to the anterior edge of the annulus ovalis, and the right blends with the auricular wall. It is a remnant of fetal life, when its duty was to direct the blood from the lower vena cava to the left auricle. It is not always present in the adult heart.

The **interauricular septum,** or **septum atriorum,** forms the posterior wall of the auricle. Upon this, a little above the opening of the inferior vena cava, is an oval depression, called the **fossa ovalis,** with a very thin floor, that marks the site of the foramen ovale of the fetal heart. Its surrounding ridge, the **annulus ovalis** (**limbus fossæ ovalis**), is incomplete below. The original foramen ovale is an oblique slit in the septum atriorum, the walls of which are approximated by the blood pressure from both sides, upon the birth of the child, and thus they become

agglutinated. When this closure is incomplete, there is a mingling of arterial and venous blood, and the face and lips become blue, giving rise to the term "blue baby." It is at times open, or "patulous," in the adult, but closed by the bilateral pressure upon its wall, thus preventing the mingling of the contents of the two auricles.

The **tubercle of Lower** (**tuberculum intervenosum**) is a structure not distinctly marked in man, but quite prominent in some of the lower animals. It occupies a position to the right of the cavity between the two caval orifices.

The **appendix auriculæ** is a small, pointed prolongation of the auricle forward and to the left, anterior to the origin of the aorta; its margins are scalloped. In its interior are found muscular columns, which, because of their supposed resemblance to some form of a comb, are called **musculi pectinati.**

Dissection.—The anterior wall of the right ventricle should now be incised for about two and a half centimeters (one inch), about twelve millimeters (one half inch) from the middle of the interventricular furrow. Into this should be inserted a rubber tube of considerable caliber and water under several pounds pressure should be allowed to flow into the ventricle. The ventricular incision should be held closed around it, and the heart tilted so that the right auriculo-ventricular orifice can be distinctly seen from the auricle, when the water should be permitted to flow suddenly. The valve will be seen to close against the stream, which will be compelled to flow into the pulmonary artery instead of into the auricle. After the completion of the demonstration, extend the ventricular incision to within half an inch of the auriculo-ventricular groove (*coronary sulcus*), thence parallel with the groove to the right border of the heart, and then continue the original incision downward to the apex. In cutting across, above, insert the finger into the ventricle from the auricle so as to guard against incising the valve at this opening. The angle of the V-shaped flap thus formed lies near the base of the pulmonary artery; it should be turned downward and lateralward, revealing the interior of the ventricle, which should be cleaned of any blood that may remain.

The **right ventricle** is triangular in form, its anterior surface is convex, and its diaphragmatic surface is flat. It is conical above toward the origin of the pulmonary artery; this portion is called the **infundibulum,** or **conus arteriosus.** The medial wall of the right ventricle is formed by the septum ventriculorum, which bulges into it. Its wall is thickest at the base and thinnest near the apex, which it does not reach by twelve millimeters (one half inch) or more.

The cavity of the right ventricle is crescentic on cross-section, it being carried around the left ventricle. Its most noticeable features are its **columnæ carneæ** (**trabeculæ carneæ**), or fleshy columns, which are of three kinds: one set forms

ridges along the ventricular septum, to which they are attached throughout their entire length; another set is similarly arranged along the walls, but free in the middle and attached only at the ends, and three or four columns, thicker than the others, are attached to the ventricular walls by one end and have the other extremity rounded and attached to the chordæ tendineæ of the auriculo-ventricular valve; these are called the **musculi papillares.** The **moderator band** is occasionally well marked in man. It is a strong muscular band connecting the anterior wall and the septum ventriculorum.

The **right auriculo-ventricular opening** is situated between the right auricle and ventricle in the median line of the body on a level with the fourth intercostal space. It is more than two and a half centimeters (one inch) in diameter and readily admits three average-sized fingers almost up to their middle. Its margin is fibrous and formed by dense connective tissue, from which project the three cusps of the tricuspid valve that guards this opening.

The **tricuspid valve** is composed of three fibro-serous segments attached to the margin of the right auriculo-ventricular opening and partly to one another near their marginal connection with the opening, the remainder of their edges being free except for the attachments of the chordæ tendineæ, some of which are also united to the ventricular surface of these flaps. The cusps, or segments, of this valve are the marginal cusp, attached to the front, the septal cusp, to the back of the orifice, and the infundibular cusp, the largest and most movable, to the left edge between it and the opening of the pulmonary artery. Each cusp is thickened in its center and quite thin at its margin. The **chordæ tendineæ** are attached to the cusps of this valve at their central thickenings, and to their free margin, in consequence of which the ventricular portions of the valves are rough, and the auricular smooth. Although very thin, they are also very strong, the thinnest of them quite readily bearing the weight of the entire heart, especially if tested not too long after death. Three smaller cusps are frequently found between the larger leaflets of this valve.

The **pulmonary opening** is found at the summit of the infundibulum (*conus arteriosus*) close to the septum. It lies to the left of the right auriculo-ventricular orifice and anterior to the aortic opening, and is opposite the left third costal cartilage near the sternum. It is guarded by the pulmonary semilunar valves, three in number, the middle one being placed anteriorly and a little to the left, the other two posteriorly.

The **pulmonary semilunar valves** should first be subjected to the water test. After completion of the demonstration, the artery should be opened from the ventricle between two of its three valve segments. These are semicircular fibro-serous folds attached to the pulmonary opening like so many wall-pockets,

PLATE CCCLVII.

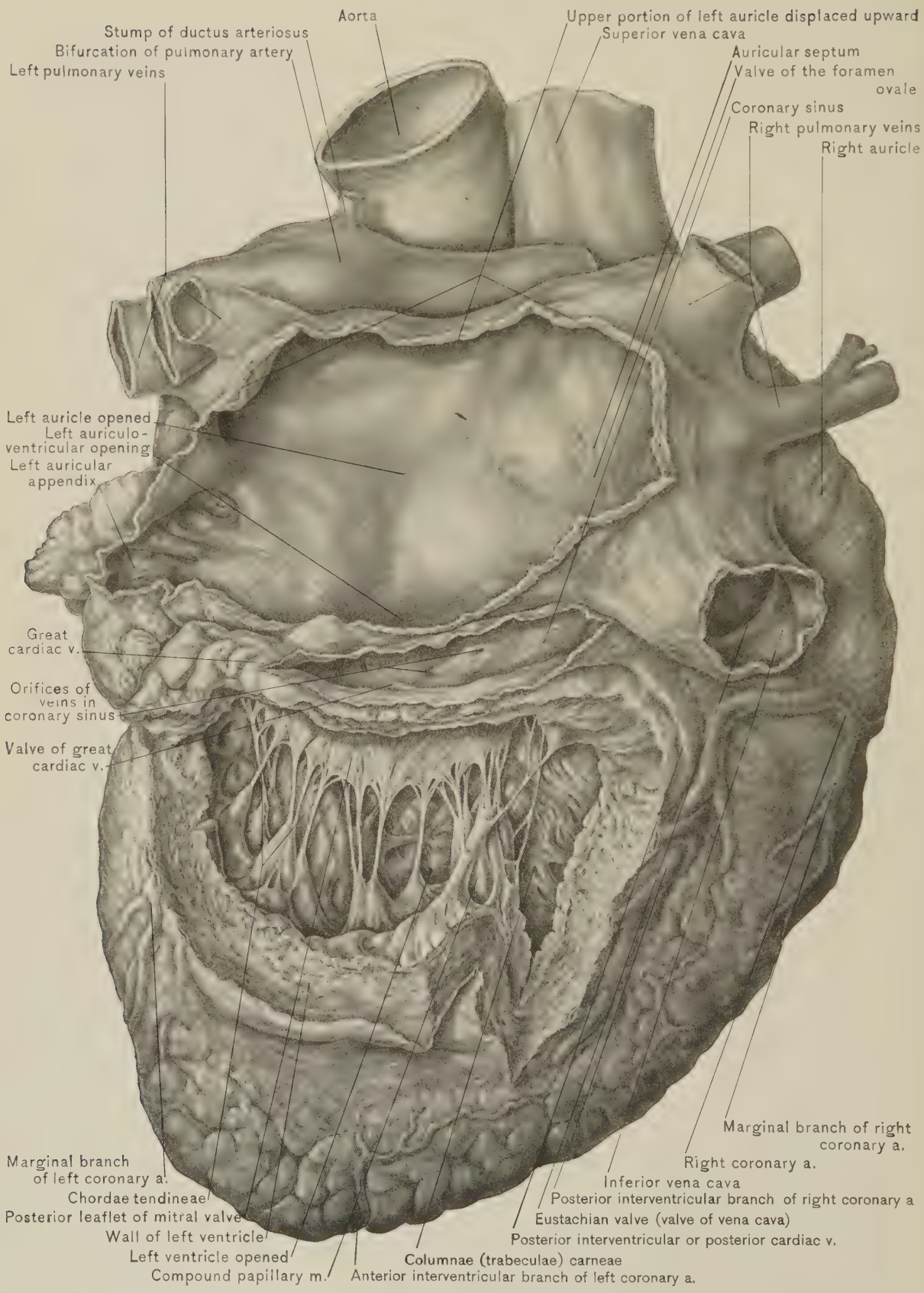
Aorta
Upper portion of left auricle displaced upward
Stump of ductus arteriosus
Superior vena cava
Bifurcation of pulmonary artery
Auricular septum
Left pulmonary veins
Valve of the foramen ovale
Coronary sinus
Right pulmonary veins
Right auricle
Left auricle opened
Left auriculo-ventricular opening
Left auricular appendix
Great cardiac v.
Orifices of veins in coronary sinus
Valve of great cardiac v.
Marginal branch of right coronary a.
Right coronary a.
Marginal branch of left coronary a.
Inferior vena cava
Chordae tendineae
Posterior interventricular branch of right coronary a
Posterior leaflet of mitral valve
Eustachian valve (valve of vena cava)
Wall of left ventricle
Posterior interventricular or posterior cardiac v.
Left ventricle opened
Columnae (trabeculae) carneae
Compound papillary m.
Anterior interventricular branch of left coronary a.

LEFT AURICLE (ATRIUM) AND VENTRICLE.

their free edges coming together to prevent the backward flow of blood. Each flap is thickest at its margin which contains a small fibrous nodule in its middle, the **corpus Arantii** (**nodule of semilunar valve**), from which fibers radiate to the attached base of the flap. When the opening is closed by these flaps, the corpora Arantii (*nodules of semilunar valves*) come together and fill up what would otherwise be a triangular opening. Behind each valve-flap the artery bulges slightly, forming a sinus of Valsalva (*aortic sinus*). Near the edge a thin crescentic area is seen on each side of the corpus Arantii (*nodule of semilunar valve*). This has received the name **lunula**, and corresponds to the area of contact of the valves.

The **left auricle** (**left atrium**) (Plate CCCLVII), thicker than the right, helps to form the left side and back of the base of the heart, only its auricular appendix being visible anteriorly, upon the left of the pulmonary artery. The appendix is more nodulated and irregular in outline than the right, and is constricted at its junction with the auricle. To open the auricle, incise it from the end of its appendix backward to the posterior auricular wall; then cleanse the auricle. Its inner surface, with the exception of the musculi pectinati in its appendix, is smooth, and presents the four valveless openings of the pulmonary veins; some small openings of veins, the foramina Thebesii (*foramina venarum minimarum*), and the left auriculo-ventricular orifice below. Two of the pulmonary veins open on its left side and two on the right; either or both pairs may unite before their entrance, the left pair doing so more frequently than the right. A slight depression exists in the auricular septum opposite the side of the fossa ovalis in the other auricle.

By opening the left ventricle the action of the bicuspid valve of the left auriculo-ventricular opening can be shown. When this is completed, the ventricle should be opened along the anterior and posterior septal margins and the wall then raised.

The **left ventricle** is longer than the right, its cavity is narrower and more nearly circular in section. It forms the apex, constitutes most of the posterior surface of the heart, and its walls are three times as thick as those of the right ventricle, being thickest near the base and thinnest at the apex, near which rupture of the heart most often occurs. Its columnæ carneæ are arranged like those of the right side, but are smaller and more numerous, those at the apex being interlaced. There are only two musculi papillares, one for each of the two cusps of the bicuspid valve.

The **left auriculo-ventricular opening** lies to the left of the aortic orifice, and posterior and to the left of the right auriculo-ventricular opening. Its margin is a fibro-serous ring from which hang the two cusps of its valve. The left auriculo-ventricular opening is smaller than the right, admitting, usually, but two fingers.

The **bicuspid valve,** or **mitral valve,** so called because of its fancied resemblance to a bishop's miter, is composed of two unequal flaps formed like the tricuspid valve, but larger, stronger, and thicker. The larger, anterior cusp is on the aortic side of the opening, corresponding to the location of the tricuspid's largest cusp in relation to the pulmonary artery. The posterior cusp is behind and to the left. Two small segments are generally found at the junction of these cusps. The attachments of the chordæ tendineæ are similar to those of the tricuspid, but the chordæ are fewer, thicker, and stronger. That portion of the ventricular cavity just below the aortic orifices has been called the aortic vestibule (Sibson); its walls are fibrous and do not collapse, thus giving the aortic valves a better opportunity for action.

The **aortic semilunar valves** (Plate CCCLVIII), three in number, are usually very well shown in injected dissecting-room subjects, and thus do not require hydrostatic demonstration, but this should not be omitted if a heart is being studied that has not had its aorta injected. The valves are identical in arrangement with the pulmonary semilunar, except that they are thicker and stronger, the corpora Arantii (*nodules*) are larger, the sinuses of Valsalva (*aortic sinuses*) are more prominent, and two of them are placed anteriorly and one posteriorly, the anterior two giving origin to the coronary arteries.

The **ventricular septum** is a muscular partition that is thickest at the apex, growing thinner toward the base, until near the aortic opening, close to its anterior and upper part, where it is devoid of muscular substance and consists of a thin fibro-serous wall, the membranous ventricular septum. It is situated just below the adjoining ends of the anterior and right posterior flaps of the aortic valve, and forms part of the wall of the aortic vestibule. The membranous part is, embryologically, the last portion of the septum to be formed; a defect in this portion of the septum, associated with stenosis of the orifice of the pulmonary artery, is one of the most common congenital abnormalities of the heart.

Injuries of the heart are not uncommonly followed by recovery. Usually it is the right ventricle that is injured, next in frequency the left ventricle, and last the left auricle. Wounds of the auricle are more rapidly fatal, owing to the thin walls of those cavities. The ventricular walls, being thicker and more robust, by contracting prevent hemorrhage. The heart can contain foreign bodies for variable lengths of time. Thus, Treves cites cases reported by different observers in which the heart had been transfixed by foils, skewers, and even an iron rod. The last-named lived for one year after the injury. Wounds of the heart, even penetrating ones, can be successfully sutured. The same exposure as suggested by Poole for pericardotomy can be used here. See p. 181.

PLATE CCCLVIII.

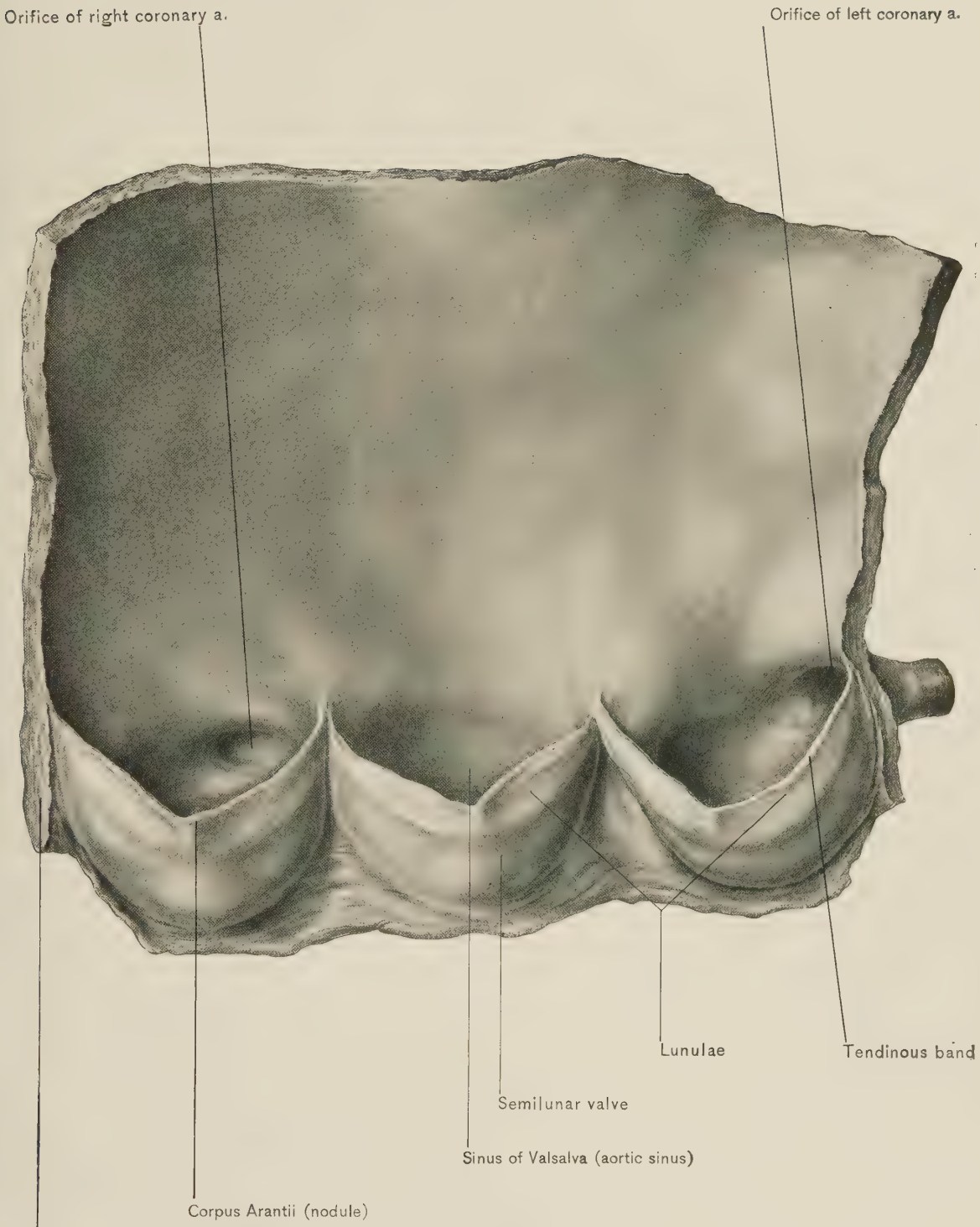

AORTIC SEMILUNAR VALVES.

The **phrenic nerves,** also occupants of the middle mediastinum, have been described with the superior mediastinum. They cross in front of the roots of the lungs and lie between the mediastinal pleura and the pericardial sac, to both of which membranes they distribute branches. They are accompanied by the comes nervi phrenici arteries, and pierce and supply the diaphragm.

The **roots of the lungs,** although occupying the middle mediastinum, will be described, for convenience, with the lungs.

THE FETAL CIRCULATION

The chief peculiarities of the fetal circulation are the **foramen ovale,** the **ductus arteriosus,** and the **ductus venosus.** They modify the course of the blood current to such an extent that the better quality of blood goes to the head and upper extremities, thus, perhaps, in part at least, accounting for the greater size and development of the upper portion of the body. These peculiarities are best understood by following the blood in its course from the umbilicus through the fetus back to the umbilical cord.

The blood enters the body of the fetus at the umbilicus through the umbilical vein, by which it is conducted in the free edge of the falciform, or umbilical, ligament to the liver. It gives off branches to the Spigelian (*caudate*) and quadrate lobes, and then continues to the transverse fissure, to divide into a large and a small branch. The smaller branch joins the left hepatic vein, and then goes to the vena cava as the ductus venosus; the larger division is joined by the portal vein and enters the right lobe of the liver. Thus almost all the blood entering the body of the fetus passes through the liver before entering the heart. A small portion passes directly into the vena cava, some directly into the liver, but most of it mingles with the portal blood before its entrance into the heart. Therefore blood carried by the inferior vena cava to the right auricle is not wholly pure, but it is the purest that is distributed to the fetus.

From the liver all the blood passes into the inferior vena cava, mixing with the blood from the lower extremities, and then to the right auricle, whence it is guided by the Eustachian valve (*valve of vena cava*) through the foramen ovale into the left auricle. Here it mingles with the little blood returned from the lungs through the pulmonary veins, and then passes into the left ventricle and the aorta. Almost all of the blood then goes to the head and upper limbs, only a very small part descending in the aorta. The posterior margin of the foramen ovale, which is overlapped by the second septum, serves as a flap valve and prevents regurgitation back into the right auricle.

The blood returns from the head and upper limbs by way of the superior vena cava to the right auricle, where it is mingled with a slight quantity of the

blood from the inferior vena cava. It passes down over the Eustachian valve (*valve of vena cava*) into the right ventricle, thus crossing the ascending current from the lower cava. From the right ventricle it enters the pulmonary artery, only very little passing into the lungs since they are functionless and receive only sufficient blood for their nourishment. The main portion goes through the ductus arteriosus into the upper end of the descending aorta, by which it is conveyed in part to the lower limbs and pelvis, but mainly through the umbilical branches of the hypogastric (*umbilical*) arteries to the placenta. The blood from the pelvis and lower limbs collects in the inferior vena cava and meets the incoming fresh stream, as stated at the beginning.

The circulation may be schematically arranged as follows:

Umbilical vein to the
Liver, and from there by the hepatic veins and the ductus venosus, to the
Inferior vena cava, to the
Right auricle, to the
Left auricle, to the
Left ventricle, to the
Aorta, to the
Head and arms, to the
Superior vena cava, to the
Right auricle, to the
Right ventricle, to the
Pulmonary artery, to the
Ductus arteriosus (very little through the lungs and back to the left auricle by the pulmonary veins), to the
Descending aorta, to the
Hypogastric (*umbilical*) arteries, to the umbilical cord (major portion), and to the pelvis and lower limbs (minor portion), from where it is returned to the inferior vena cava.

At birth the lungs fill with air and the blood current is diverted from the ductus arteriosus along the branches of the pulmonary artery to the lungs. The duct then contracts, atrophies, and becomes impervious, existing later in life only as a cord connecting the bifurcation of the pulmonary artery with the concavity of the aortic arch.

The umbilical vein and ductus venosus become similarly atrophied, the former becoming the round ligament of the liver.

The hypogastric (*umbilical*) arteries become the obliterated cords that converge toward the umbilicus from the pelvis upon either side of the urachus, and their intrapelvic, patulous remains become the superior vesical arteries.

The Eustachian valve (*valve of vena cava*) stops growing, and is either deficient in adult life or exists merely as a rudiment. The foramen ovale closes in about ten days, though it remains patulous in a large proportion of individuals, rarely causing trouble, however, because of its oblique direction.

PLATE CCCLIX.

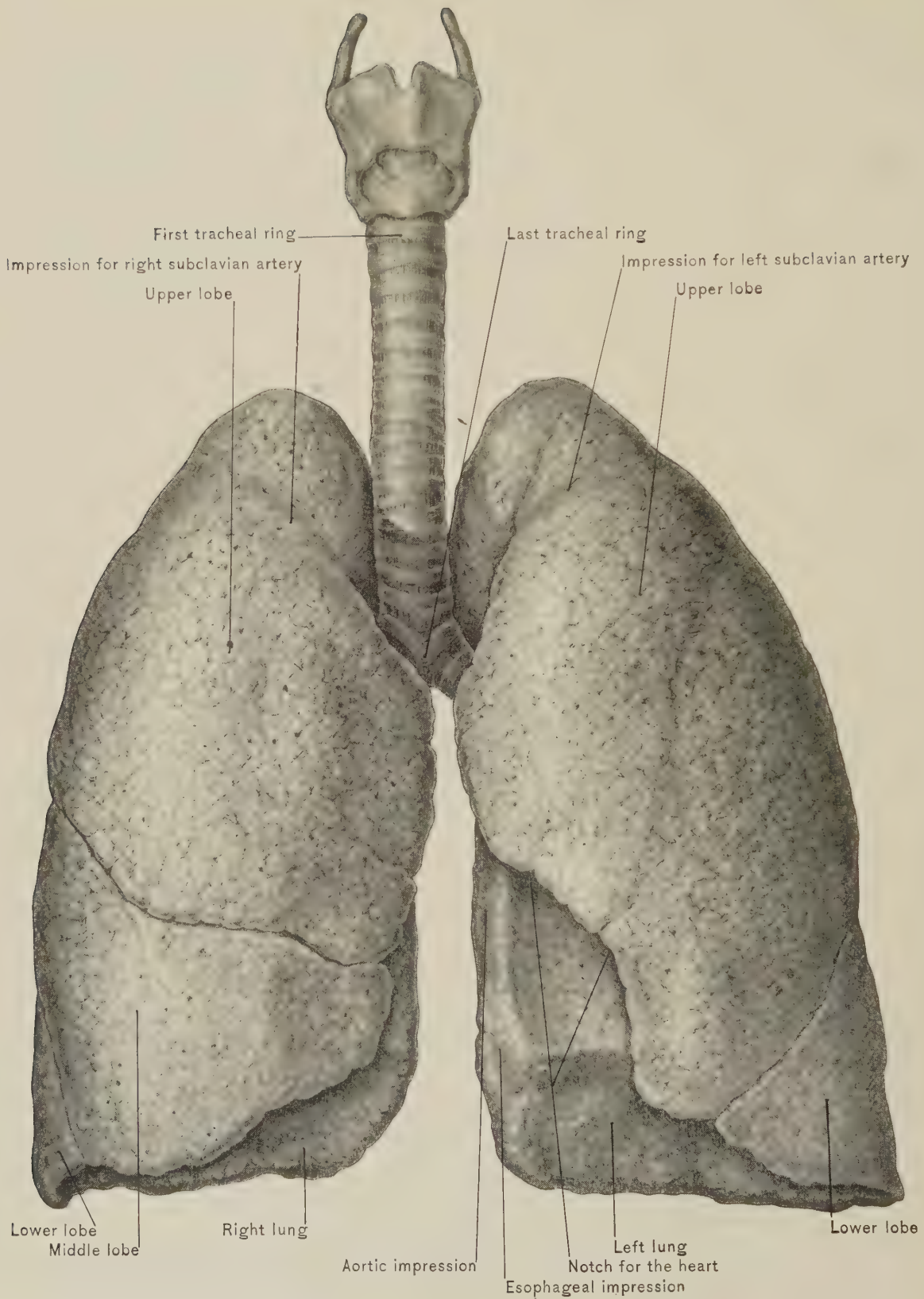

ANTERIOR VIEW OF TRACHEA AND LUNGS.

PLATE CCCLX.

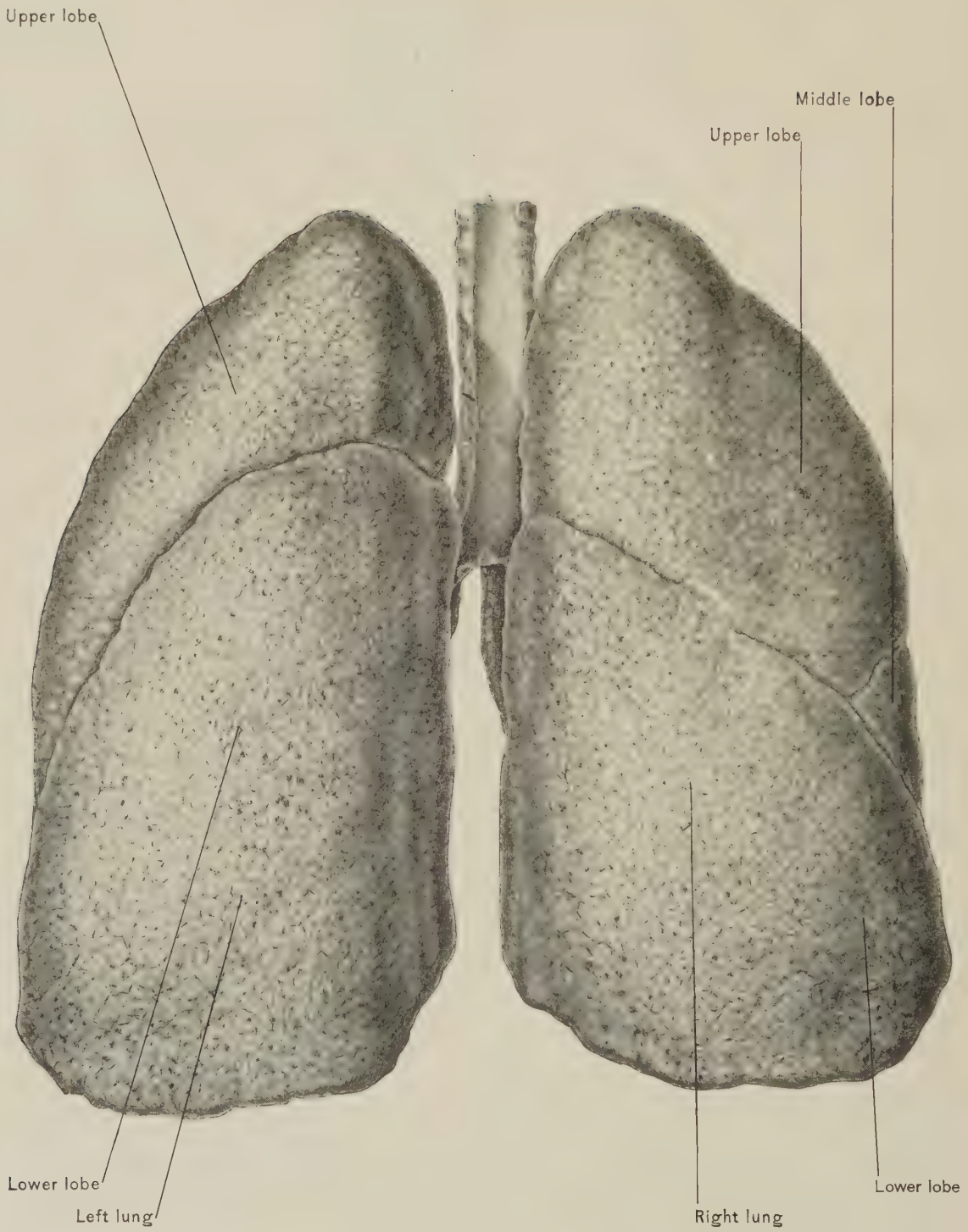

POSTERIOR VIEW OF TRACHEA AND LUNGS.

PLATE CCCLXI.

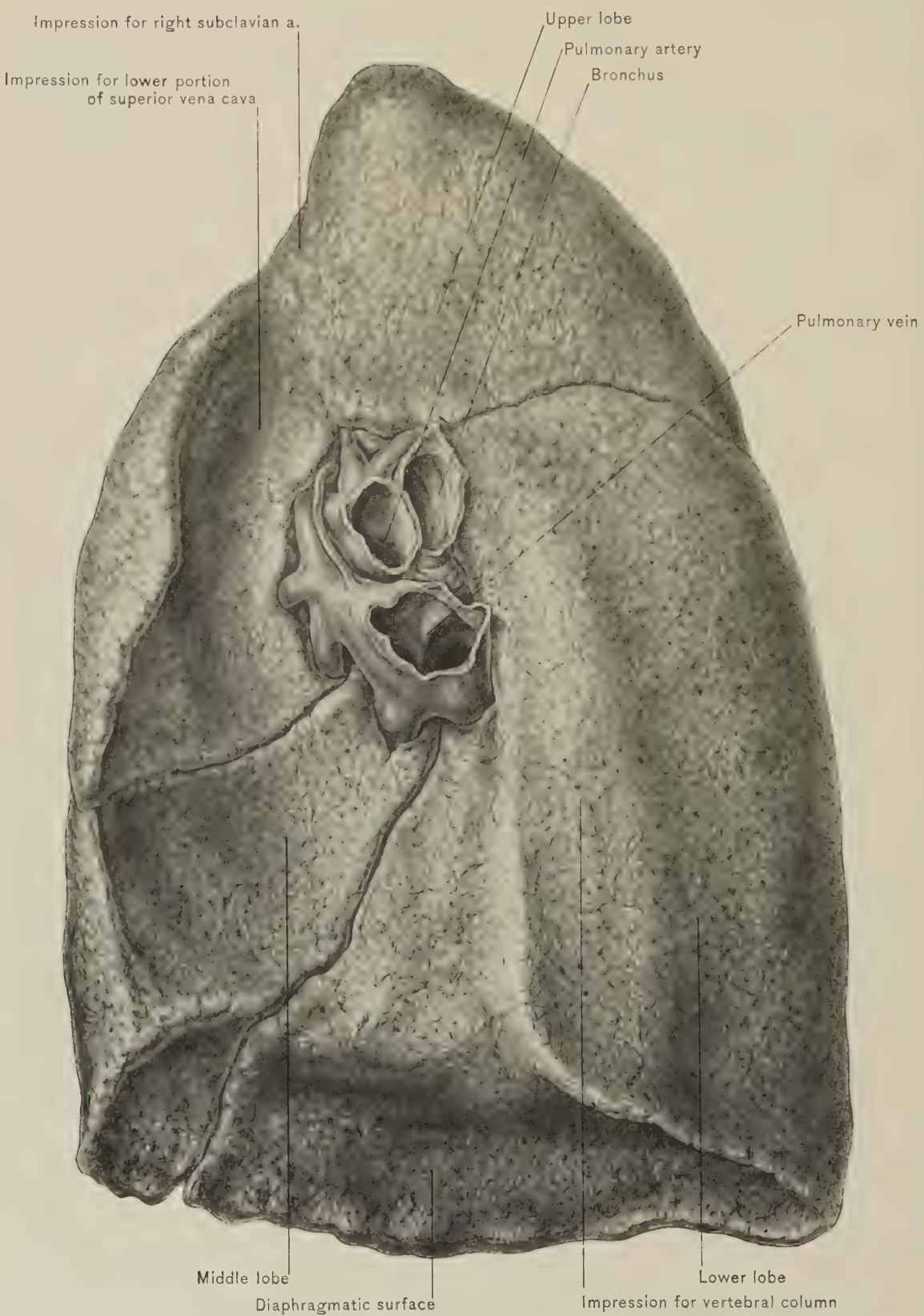

MEDIASTINAL SURFACE OF RIGHT LUNG.

PLATE CCCLXII.

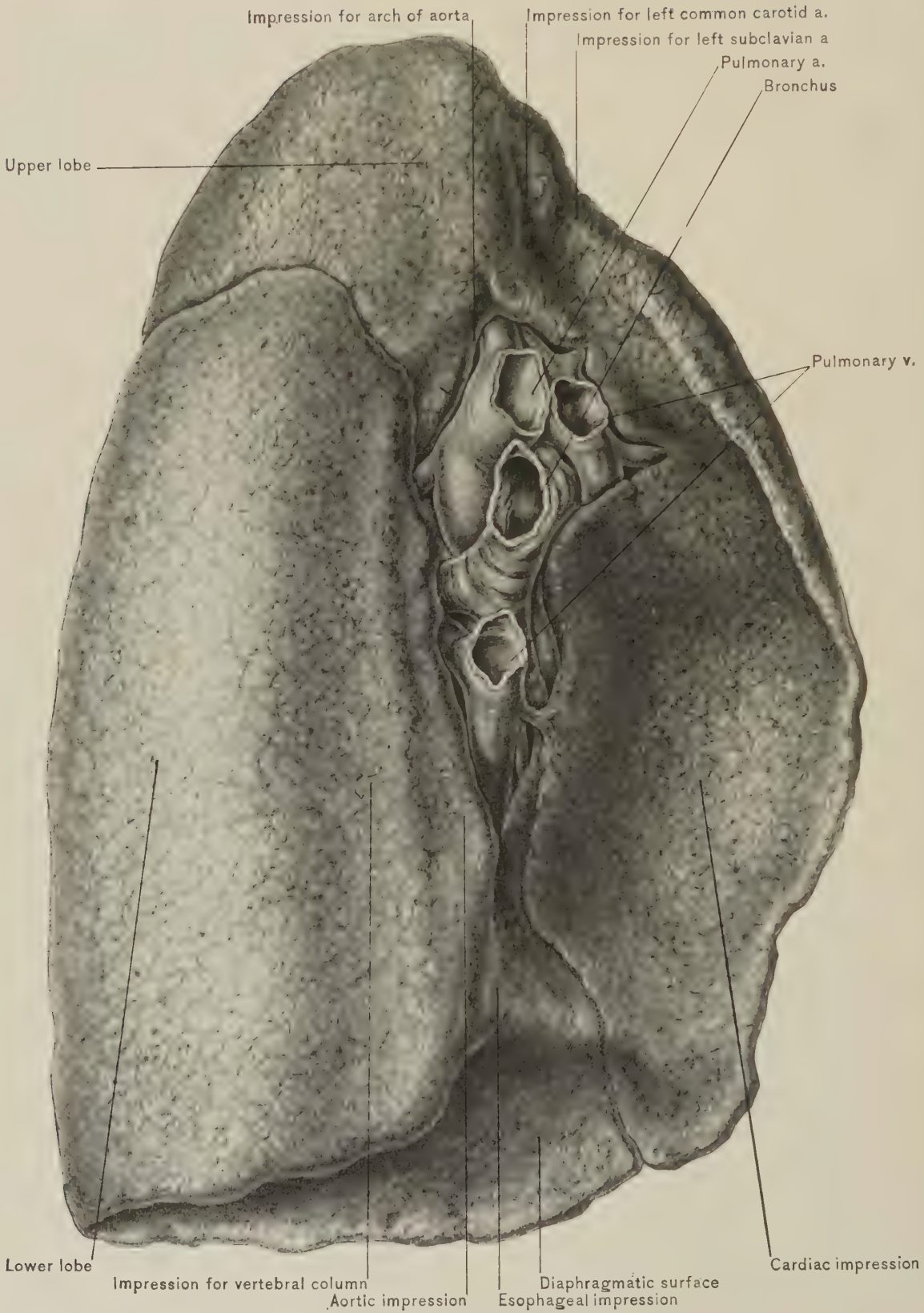

MEDIASTINAL SURFACE OF LEFT LUNG.

THE LUNGS

The **lungs** (Plates CCCLIX and CCCLX) are essentially the respiratory organs, each of the two fitting accurately within its lateral half of the thorax. Between them are the mediastinal spaces, together with thier contents, and the bodies of the thoracic vertebræ. Each lung is long and conical, or pyramidal, with a tip or apex projecting into the root of the neck, a concave base sloping downward and backward and resting upon the diaphragm, an anterior and a posterior border, and an inner, or medial, and an outer, or lateral, surface. The right lung is divided into three lobes, and the left into two. The lungs are exceedingly elastic, so that they will be found collapsed if the thorax is opened during life.

The **apex** is rounded and projects into the neck for about three and three-quarters centimeters (an inch and a half) above the sternal end of the clavicle; it lies behind the scalenus anterior muscle and the subclavian artery, the artery grooving its medial and anterior aspects.

The concave **base** fits accurately upon the convex top of the diaphragm, its thin circumference, much more marked behind, passing into the narrow space between the diaphragm and chest-wall, though not to its bottom, stopping at the tenth rib in the postscapular line. The lower limits of the lung can be represented by a line drawn around the chest from the junction of the sixth costal cartilage with the sternum to the spinous process of the tenth dorsal vertebra. The base of the right lung, owing to the presence of the liver, holds a higher position in the chest than the left, being on a level with the upper border of the fifth rib near the sternum, while the base of the left lung is on a level with the upper border of the sixth rib.

The **outer, lateral,** or **costal surface** constitutes most of the surface of the lung. It lies against the ribs and intercostal spaces throughout its entire extent except in that portion which extends into the neck; its form, therefore, corresponds closely to that of the bony chest, the impressions of the ribs being often distinctly discernible upon it. Its convex surface passes almost imperceptibly into the thick, broad, rounded posterior border, which occupies the hollow at the side of the vertebral column.

The **inner,** or **medial, surface** (Plates CCCLXI and CCCLXII) is deeply concave to accommodate the heart and the pericardium, that of the left lung being the more markedly concave because the greater portion of the heart is on that side. It is divided into a vertebral area adapted to the sides of the thoracic vertebræ, and a mediastinal area, which is in relation to the mediastinal septum. Upon this surface, above and posterior to the base of the heart, a little nearer the

apex than the base of the lung, is a recess for the entrance of the bronchus, the pulmonary and bronchial arteries and the nerves, and the exit of the pulmonary veins and lymphatics; this recess is called the **hilum.**

The **anterior border** is thin and partly overlaps the pericardium. The borders of the two lungs lie posterior to the sterno-clavicular articulations, pass obliquely behind the manubrium, and meet in the midline at the junction of the manubrium with the gladiolus (*body of the sternum*). From this point the edge of the right lung is directed vertically downward, behind the mid-sternal line, to the junction of the sixth costal cartilages with the sternum, from which point it follows the line of the sixth rib. The anterior border of the left lung observes the same relation as that of the right, until it reaches the junction of the sternum with the fourth costal cartilage. From here it passes along the fourth costal cartilage for four centimeters (one and one-half inches), then curves convexly laterally and downward to a point two finger-breadths to the left of the middle of the sterno-ensiform (*sterno-xiphoid*) articulation. This leaves a wide notch on the anterior border of the left lung, the incisura cardiaca, which leaves a portion of the pericardium uncovered by lung. On account of the presence of the thymus gland there is a greater separation anteriorly between the lungs in a young child than in an adult. The two edges of the lungs do not overlap at any place. The right reaches to the midline and the left one to the left edge of the sternum (Symington).

The **posterior border** is full, round, and thick, being the most bulky part of the organ and lying in the deep, wide sulcus upon the side of the vertebral bodies and the angles of the ribs. It is almost twice as long as the anterior border and becomes wider as it descends.

Lobes.—Each lung is divided into an upper and a lower lobe by an oblique fissure, penetrating almost to the root, which begins posteriorly about seven and a half centimeters (three inches) from the apex and ends in the anterior border near the base. Upon the surface of the chest the position of this fissure may be indicated by a line drawn from the spinous process of the second dorsal vertebra downward and forward to the intersection of the mid-clavicular line and the sixth rib. It will thus be seen that the upper and smaller lobe forms nearly the entire anterior portion of the lung, embracing the apex and anterior border, while the lower lobe, the larger, forms the posterior portion, including the base and nearly all the posterior border. On the right side the upper lobe is divided by a second nearly horizontal fissure which is directed forward from the middle of the preceding one to the anterior border, thus dividing the right lung into three lobes. The right lung, besides having three lobes, is larger and heavier than the left; its transverse diameter is greater owing to the inclination of the heart to the left

side; its vertical diameter is shorter owing to the diaphragm lying higher on the right side, being carried up by the liver. The left lung is smaller and narrower but longer than the right.

In lung abscess or interlobar empyema care must be exercised so that a pyothorax does not result. The parietal and visceral pleura must either be sutured at a first operation or adhesions between the two must be encouraged by packing.

Roots.—The lungs are attached by the structures composing their roots, and by the ligamentum latum pulmonis (*pulmonary ligament*). The structures constituting their roots are the pulmonary vessels, the bronchial vessels, the lymphatic vessels and glands, the bronchi, and the pulmonary plexuses of nerves. The ligamentum latum pulmonis (*pulmonary ligament*) attaches the portion of the lungs below the roots to the sides of the pericardium and to the diaphragm at the pericardial margin. It has been described with the pleura (at p. 148). Anterior to the root of the right lung are the superior vena cava, the upper part of the right auricle, the ascending portion of the arch of the aorta, the phrenic nerve, part of the anterior pulmonary plexus of nerves, and the terminal part of the vena azygos major (*azygos*), which is at first posterior and then winds over the upper border, terminating in front. In front of the root of the left lung are the phrenic nerve and part of the anterior pulmonary plexus, and above it is the arch of the aorta. Behind the root of each lung are the vagus nerve and part of the posterior pulmonary plexus of nerves. Below the root is the ligamentum latum pulmonis (*pulmonary ligament*). In the root are collected the bronchus, the branch of the pulmonary artery, two pulmonary veins, two bronchial arteries and their accompanying veins, the pulmonary plexus of nerves, lymphatics, bronchial glands, and areolar tissue, all of which are surrounded by pleura. The relations of the pulmonary veins, the branch of the pulmonary artery, and the bronchus in the root of each lung, from above downward and from before backward, are as follows: In the roots of both lungs, from before backward, the relations are: the pulmonary veins, the branches of the pulmonary artery, and the bronchus; from above downward, in the root of the right lung, the relation is the bronchus, the branch of the pulmonary artery, and the pulmonary veins; from above downward, in the root of the left lung, the relation is the branch of the pulmonary artery, the bronchus, and the pulmonary veins. The difference in the relations of the two bronchi may be accounted for by the left one being at a lower level than the right in order that it may pass under the aorta.

Division of the Bronchi. The right bronchus about two centimeters (three-fourths of an inch) from its origin gives off a considerable branch, which passes above the pulmonary artery to the upper lobe of the right lung; it is known as the

eparterial bronchus, in contradistinction to all the other branches which come off below the pulmonary artery and are known as **hyparterial bronchi.** There is no eparterial bronchus on the left side. The bronchus passing to the upper lobe of the left lung comes off nearly five centimeters (two inches) lower down than the eparterial bronchus; consequently it would seem that the air has more direct access to the right upper lobe, and to this fact, together with the closer proximity of that lobe to the lumen of the trachea, may perhaps be attributed the differences in the auscultatory and tactile phenomena of the upper portions of the two sides of the chest.

Each bronchus continues its course toward the lower and posterior portion of the lung, giving off in its course four "ventral" and four "dorsal" branches; the right one has an additional or "accessory" bronchus which passes into the lower lobe.

The *weight of the lungs* is about one thousand two hundred and sixty grams (forty-two ounces); the left lung weighs six hundred grams and the right six hundred and sixty grams, though this is subject to considerable fluctuation, depending upon the size of the individual.

Blood Supply.—The blood supply for the lung tissue is derived from the bronchial arteries.

Nerve Supply.—The nerve supply is derived from the anterior and posterior pulmonary plexuses which are formed by branches of the vagi and sympathetic.

The *consistency of the lungs* is soft, spongy, and elastic, the tissue crepitating when compressed between the fingers, and floating when placed in water. They may be compressed within a very small space or enlarged by inflation considerably beyond their maximum expansibility during life, when this is restricted by the environing walls.

The *color of the lungs* varies with age, being a clear pink in infancy, and gradually changing to a slate color in adult life, when it is mottled with dark patches of pigment. In some occupations, as in coal-mining, or in stoking, the lungs become almost black, the exuding fluid on section staining the hands. Most pigment is deposited at the bases and posterior borders. The surface of the lungs is finely wrinkled when partly collapsed, but smooth and glistening when fully inflated, and is covered with polyhedral markings indicating the shape of the underlying air cells.

Hernia of the lung, or pneumatocele may follow perforating injuries of the chest wall with rupture of the pleura, resulting in a soft compressib e tumor, resonant on percussion. The hernia may be subcutaneous but is more often complete, part of the lung being forced through the opening in the chest wall by a violent expiratory effort.

Hypostatic congestion is a soggy condition of the posterior margin and base of the lung, due partly to cardiac weakness and to the influence of gravity, and is met with in patients who have been lying in one position for a long time. The base of the lining is dark in color and on section exudes a stream of frothy pink or red serum. In advanced cases the air vesicles no longer contain air and parts of the lung sink in water; to these cases the term hypostatic pneumonia is applied.

In **pneumonia,** or **pneumonitis,** the lower lobe is most often affected, and because of the direction of the interlobular fissure, the physical signs, when the lower lobe is affected, are found upon the side and back.

In **phthisis** the upper lobe is the one almost always primarily affected, the apex particularly. In this affection the physical signs must be looked for particularly in the front and upper part of the chest, and in the suprascapular regions behind.

The lung has been known to be penetrated by a sword or a bullet, causing wounds that have ended in complete recovery by rational local and supporting general treatment.

Infarctions of the lung are marked by their pyramidal shape, with the apex always directed toward the interior of the lung, and the base invariably extending to the surface. This is due to the shape of the area of distribution of the pulmonary arteries which branch out symmetrically in all directions, so that when one of them becomes suddenly clogged by a clot of blood, the entire distributive area beyond is cut off from further supply, for the inosculations of these vessels are meager and not sufficient to carry on a collateral circulation. The lung is the only organ that can have an infarct due to a clot formed in a systemic vein, although the liver may be damaged in part by an embolus in the portal vein. A pulmonary infarct may end in gangrene, or abscess, or may become organized and decolorized.

Emphysema is a condition in which the air cells are ruptured and partially destroyed from increased intrapulmonary pressure, which may be caused by playing upon wind instruments, by asthma, by whooping-cough, and by chronic coughs generally. By this unusual distention of the lung its elasticity is diminished so that it does not collapse post mortem. The gradual destruction of its aerating surface, by the breaking down of its vascular walls and the coincident disappearance of their contained capillaries, renders its victims "short-winded" despite their enlarged chests, distended by the increased pressure. Emphysematous lungs often overlap behind the sternum and bear the indentations of the ribs. When the rupture of a vesicle permits the air to get into the connective tissue of the lung, it may eventually extend into the connective tissue of the neck and face, and finally over the entire body.

THE POSTERIOR MEDIASTINUM (Plate CCCLXIII)

The **posterior mediastinum** is the space running parallel with the vertebral column, bounded anteriorly by the pericardium and the posterior surface of the roots of the lungs; posteriorly by the vertebral column, and on either side by the pleura. It extends from the level of the lower border of the fourth thoracic vertebra to the diaphragm.

Dissection.—The posterior mediastinum should be studied from the anterior surface and from both sides. It will be necessary, therefore, to remove the heart, the pericardium, and the lungs, as well as a portion of the ribs as far back as the angles. To expose the contents of the posterior mediastinum from the right side (Plate CCCLXIV), the ribs on the right side should be cut away as far as their angles, and the right lung lifted out of the chest cavity and displaced to the left; the posterior part of the costal pleura, as well as the pleura covering the posterior surface of the root of the right lung and the ligamentum latum pulmonis (*pulmonary ligament*), should then be removed. By careful dissection, the greater part of the space and its contents, with the exception of the upper portion of the descending thoracic aorta, and the left upper and left lower azygos (*hemiazygos*) veins, with some of the left aortic intercostal arteries and veins, will be exposed. The same thing should then be done on the left side (Plate CCCLXV), the left lung displaced to the right, and the aorta and its branches, and the vena azygos minor superior (*hemiazygos accessoria*) and the lower left vena azygos (*hemiazygos*) studied. After removal of the lungs the posterior mediastinum should be studied from in front.

Contents.—The contents of the posterior mediastinum are the descending, or thoracic, aorta with the vertebral portion of the right and left intercostal arteries, the origin of the bronchial, pericardiac, esophageal, and mediastinal arteries; the arteria aberrans (when present), part of the bronchial veins, the lower portion of the esophagus, the vagus nerves, and the thoracic duct; the sympathetic nerves, the splanchnic nerves, the lymphatic glands, the left upper and left lower azygos (*hemiazygos*) veins, the vena azygos major (*azygos*), and the posterior pulmonary plexus.

The Thoracic Aorta.—The thoracic aorta extends from the lower border of the fourth thoracic vertebra to the aortic opening in the diaphragm opposite the twelfth thoracic vertebra. From there it continues as the abdominal aorta. At first it lies to the left of the dorsal spine, but gradually approaches the middle, so that at the diaphragm it lies nearly in the median line.

Relations.—In front of it are the root of the left lung, which crosses it, the esophagus, the pericardium, and the heart, and, below, the diaphragm. Behind

PLATE CCCLXIII.

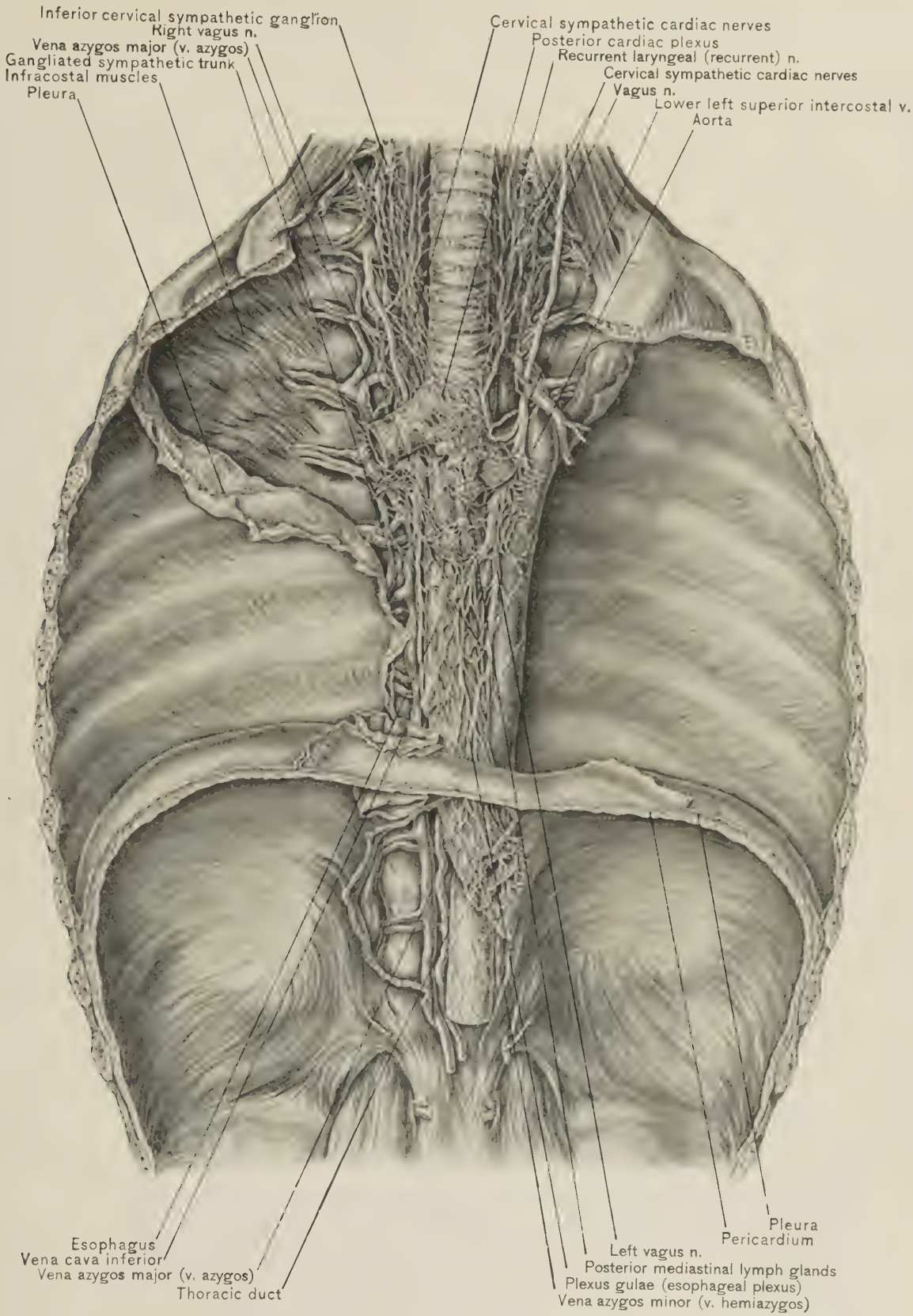

THE POSTERIOR MEDIASTINUM, VIEWED FROM THE FRONT.

PLATE CCCLXIV.

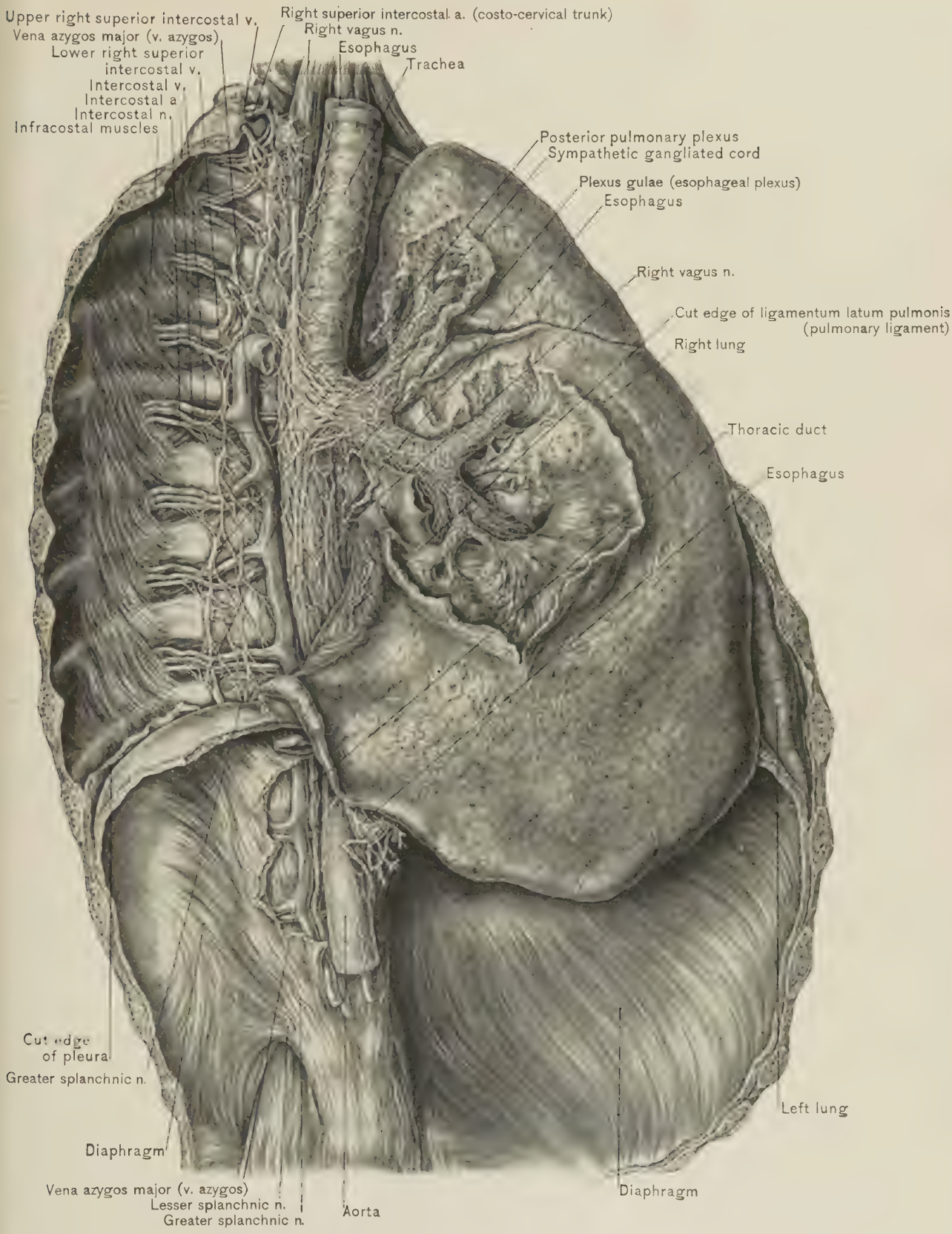

THE POSTERIOR MEDIASTINUM, VIEWED FROM THE RIGHT SIDE.

PLATE CCCLXV.

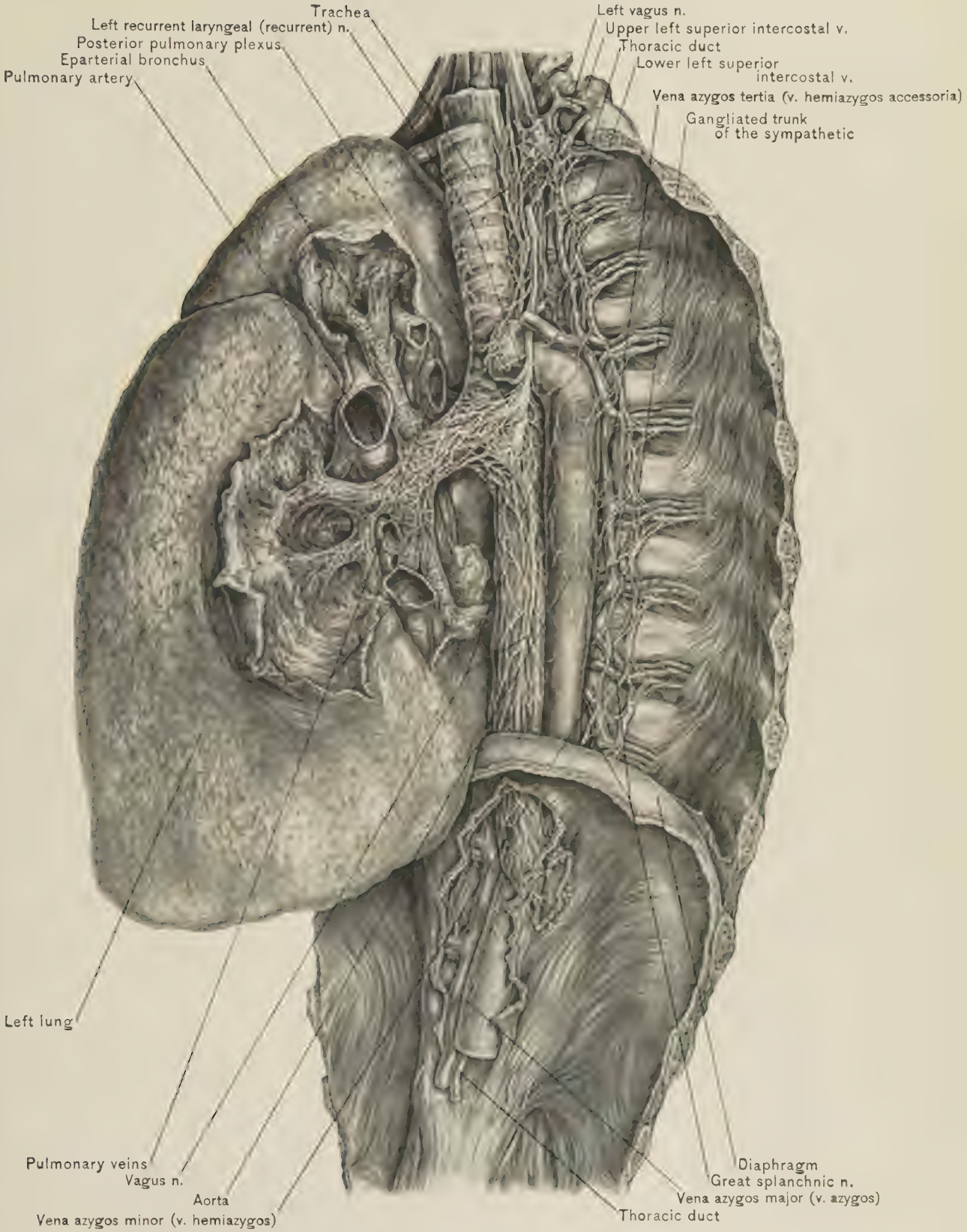

THE POSTERIOR MEDIASTINUM, VIEWED FROM THE LEFT SIDE.

it are the bodies of the lower thoracic vertebræ joined by the anterior common ligament. The vena azygos minor (*hemiazygos*) usually crosses behind it at the seventh, eighth, or ninth dorsal vertebra, and the lower end of the lower superior intercostal vein, or the vena azygos tertia (*hemiazygos accessoria*), or one or more left intercostal veins cross behind it at the fifth, sixth, or seventh thoracic vertebra. On the right side are the esophagus, pleura, and lung, and a little posterior and to the right are the vena azygos major (*azygos*) and the thoracic duct.

On the left side are the pleura, lung, esophagus, and the upper and lower left azygos (*hemiazygos*) veins.

The esophagus at first lies to the right of the aorta, but as these structures approach each other in their course downward and medialward the esophagus comes to lie in front of the aorta, and at the diaphragm it is even a little to the left of it.

The branches of the thoracic aorta are the intercostal and subcostal, the bronchial, pericardial, esophageal, mediastinal, and diaphragmatic arteries, and the arteria aberrans.

The **intercostal arteries** number ten on each side. The upper nine intercostals of each side supply the lower nine intercostal spaces, while the tenth lies below the twelfth rib and is named the **subcostal artery** (Walsham). The upper two intercostal spaces are usually supplied by the superior intercostal artery, a branch of the subclavian. The right intercostal arteries are longer than the left, since the thoracic aorta lies to the left of the median line of the vertebral column. They are given off from the posterior part of the aorta and run lateralward across the bodies of the vertebræ to the intercostal spaces; those of the right side pass posterior to the esophagus, the thoracic duct, the vena azygos major (*azygos*), the sympathetic nerve, and the pleura; those of the left side pass behind the left superior intercostal vein, the left upper and the left lower azygos (*hemiazygos*) veins, the sympathetic nerve, and the pleura. The upper two or three left aortic intercostal arteries may come off from the aorta by a single stem. In the intercostal spaces each artery divides into two branches, an anterior and a posterior. The anterior branches anastomose with the anterior intercostal and musculophrenic branches of the internal mammary. These arteries have been described with the thoracic wall.

The **bronchial arteries,** two or more, are the nutrient vessels of the lung. The right bronchial artery arises either in common with one of the left bronchials from the thoracic aorta or alone from the first aortic intercostal. The left bronchial arteries, usually two in number, arise from the thoracic aorta. Each vessel runs along the back part of the corresponding bronchus, to which it adheres, and

ramifies upon the bronchial tubes, supplying them, the areolar tissue of the lungs, the bronchial glands, and the esophagus.

The **bronchial veins** receive the blood that has been supplied by the bronchial arteries for the nourishment of the lungs, the right conveying its contents to the vena azygos major (*azygos*) just before it joins the vena cava, and the left, to the left superior intercostal.

The **pericardial arteries** are a few small vessels distributed to the posterior part of the pericardium and to the posterior mediastinal glands.

The **esophageal arteries,** four or five in number, arise at different points from the front of the thoracic aorta and pass obliquely downward to the esophagus, around which they ramify. They anastomose with one another, with the esophageal branches of the inferior thyroid above, and with branches of the left gastric and phrenic below. They supply the walls of the esophagus.

The **posterior mediastinal arteries** arise from the posterior part of the thoracic aorta and go to the lymph glands and loose connective tissue in the posterior mediastinum.

The **diaphragmatic branches** are small vessels given off near the diaphragm to supply the upper surface of the vertebral portion of that structure.

The **arteria aberrans** is regarded as the remains of the right aortic stem; it is a small vessel that passes upward behind the esophagus and frequently anastomoses with the arteria aberrans of the superior intercostal artery.

Aneurysm of the aorta is a frequent affection of middle and later life. If the descending aorta is affected, it may cause erosion of the bodies of the thoracic vertebræ resulting in spinal curvature; it may also irritate the intercostal nerves and cause pain that is often referred to other causes. It is well to remember that the neuralgia of vertebral caries is bilateral, while that resulting from aortic aneurysm is more likely to be unilateral. Its bruit may be heard at the costal angles posteriorly, where, if large, its pulsations may also be seen. Anteriorly it may push the esophagus forward, or compress the lung, or embarrass the heart, causing dysphagia, dyspnea, palpitation, and circulatory disturbances. Compression of the thoracic duct causes rapid wasting—a significant sign. Finally, the aneurysm may rupture, with fatal hemorrhage, through the skin, or into the mediastinum, esophagus, pleura, pericardium, or one of the bronchi.

The **esophagus,** or **gullet** (Plate CCCLXIII), is a hollow muscular tube about twenty-five centimeters (ten inches) in length. It commences at the termination of the pharynx, on a level with the lower border of the cricoid cartilage opposite the fifth or sixth cervical vertebra, and ends at the cardiac opening of the stomach, opposite the eleventh dorsal vertebra. It has been described with the superior mediastinum and neck at p. 175. In the posterior mediastinum it lies at first to

PLATE CCCLXVI.

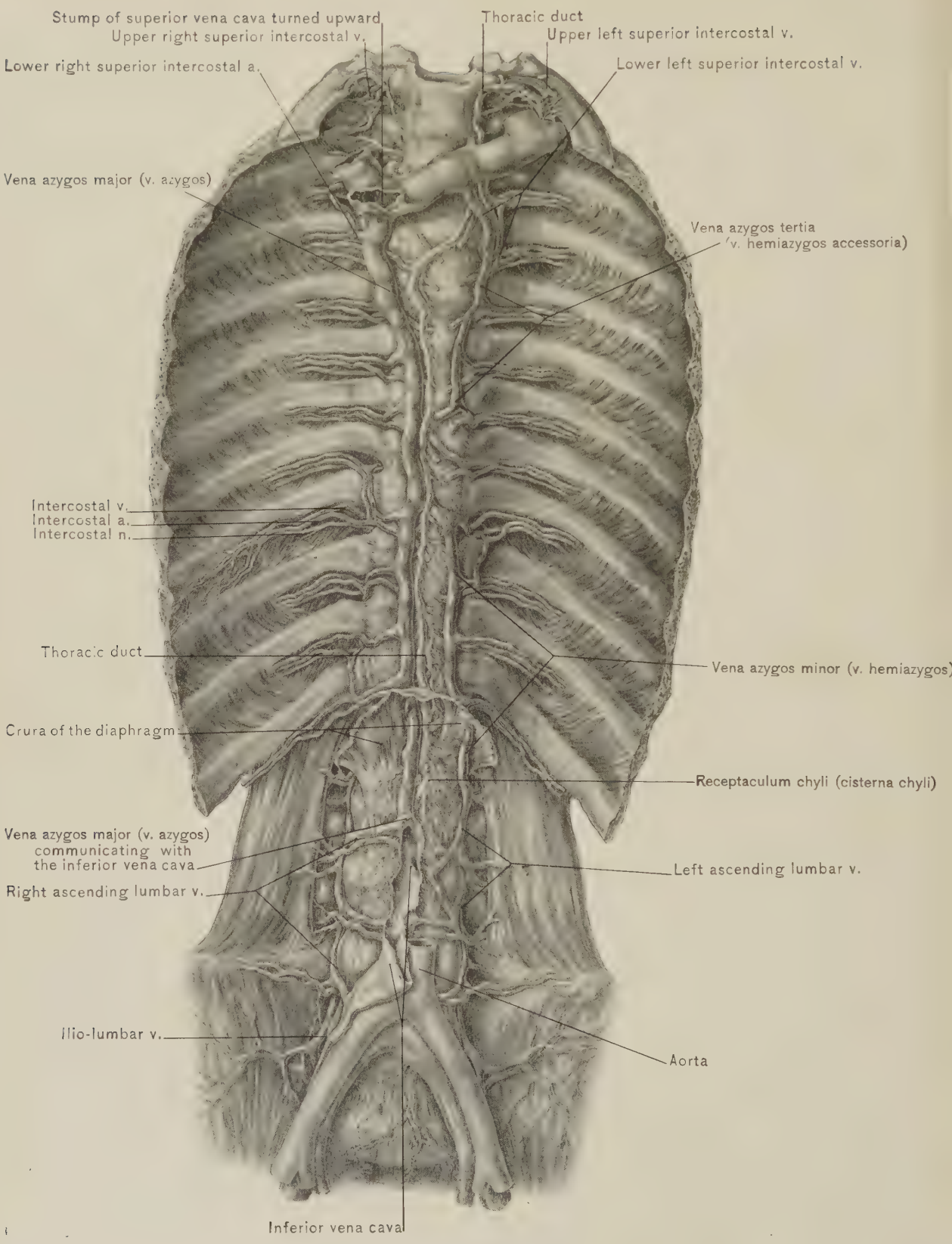

THE VENAE AZYGOS, THORACIC DUCT, INTERCOSTAL VESSELS AND NERVES.

the right side of the thoracic aorta and at the diaphragm passes in front of the thoracic aorta and into the abdomen through the esophageal opening of the diaphragm.

The **vagus nerves,** which accompany the esophagus, form the *esophageal plexus*, or *plexus gulæ*, which surrounds it. Each nerve then descends as two trunks along the esophagus, the left nerve at first to the left, and later in front of the esophagus, the right nerve to the right and behind the esophagus. Beyond the plexus gulæ (*esophageal plexus*) each nerve descends as a single trunk, the left to the anterior, the right to the posterior surface of the stomach.

The **thoracic duct** (Plate CCCLXVI) conducts the lymph from the receptaculum chyli (*cisterna chyli*), anterior to the body of the second lumbar vertebra, to the left internal jugular vein at its union with the subclavian. The receptaculum chyli (*cisterna chyli*) is an irregularly elongated expansion of the lower end of the duct lying upon the second lumbar vertebra posterior to the aorta. The duct is found in the loose tissue between the vena azygos major (*azygos*) and the aorta. It is very elastic and no larger than a whipcord. It passes through the aortic opening of the diaphragm on the right of the aorta, then ascends with a gradual sinistral inclination that brings it posterior to the aortic arch and esophagus opposite the body of the fourth thoracic vertebra, from which point it continues upward in the superior mediastinum to the left of the esophagus. The duct contains valves, mostly in its upper part. During its ascent it may divide into several branches which usually reunite before its termination in the internal jugular vein, although instances have been met with where it emptied by two or more orifices. It leaves the thorax upon the left of the esophagus until opposite one of the last two cervical vertebræ, where it bends lateralward and forward, and then downward to the pleural apex, thus reaching its destination. Its arch is higher than the subclavian artery. A double valve guards its entrance into the vein. The duct may be injured in operations on the lower part of the neck or may be compressed by growths in the posterior mediastinum.

The **vena azygos major** (**vena azygos**) begins in the abdomen and is the continuation of the right ascending lumbar vein. Entering the thorax through the aortic opening in the diaphragm, it runs upward in the posterior mediastinum to the right side of the bodies of the thoracic vertebræ to the fourth thoracic vertebra, where it arches anteriorly over the right bronchus to empty into the superior vena cava, just above the pericardial investment of the latter.

Relations.—In the abdomen it lies behind the right crus of the diaphragm upon the first or second lumbar vertebra, and to the right of the thoracic duct and the abdominal aorta. It may communicate with the renal vein, or the inferior

vena cava, and, by means of the ascending lumbar vein, connect the iliac veins with the superior vena cava. In the posterior mediastinum it lies to the right of the esophagus and aorta, and anterior to the lower right intercostal arteries and the thoracic vertebræ. On its right side are the pleura and lung, and in front of it are the root of the right lung and the pleura. Its valves are imperfect.

It receives the vena azygos minor (*hemiazygos*); the vena azygos tertia (*hemiazygos accessoria*), or some of the left intercostal veins; the lower end of the lower left superior intercostal vein occasionally; the lower esophageal veins of the right side; the right bronchial vein; the lower right superior intercostal vein; the mediastinal veins; the nine lower intercostal veins of the right side, and the right subcostal vein.

The **vena azygos minor** (**vena hemiazygos**), also called the **lower left azygos vein,** begins at the left ascending lumbar vein in the abdomen and ends by emptying into the vena azygos major (*azygos*), thus establishing communication between the iliac or renal vein below and, through the vena azygos major (*azygos*), the superior vena cava above. It enters the thorax behind or through the left crus, and in its course upward in the posterior mediastinum, lies to the left of the body of the seventh or eighth thoracic vertebra, and passes anterior to the lower intercostal arteries. It may cross at various levels behind the esophagus, thoracic duct, and aorta, but probably most usually at the eighth dorsal vertebra, to empty into the vena azygos major (*azygos*). It may communicate with the lower end of the vena azygos tertia (*hemiazygos accessoria*) when that vessel is present. It is covered by pleura.

Into it empty the left subcostal vein, the lower three or four intercostal veins, the lower end of the vena azygos tertia (*hemiazygos accessoria*) occasionally, small mediastinal veins, and the lower left esophageal vein.

The **vena azygos tertia** (**vena hemiazygos accessoria**), **or upper left azygos vein,** also lies in the posterior mediastinum, to the left side of the bodies of the fifth, sixth, and seventh thoracic vertebræ. Above it communicates with the lower left superior intercostal vein and below very frequently with the vena azygos minor (*hemiazygos*), or with the vena azygos major (*azygos*) after crossing to the right side at the sixth or seventh thoracic vertebra. This vein varies considerably in size and arrangement, and may be absent. In the latter event the left intercostal veins intervening between the lower left superior intercostal vein and the vena azygos minor (*hemiazygos*) cross anterior to the spinal column to empty into the vena azygos major (*azygos*). This vein crosses some of the left intercostal arteries and is covered by pleura.

Into it empty usually the fifth, sixth, and seventh left intercostal veins, the left bronchial vein, and the lower left superior intercostal vein. It frequently

communicates by its lower end with the vena azygos minor (*hemiazygos*) or with the vena azygos major (*azygos*) by crossing anterior to the spinal column.

The **intercostal veins** have been described with the thoracic walls at p. 129.

The **thoracic sympathetic** (Plate CCCXV), in addition to the pulmonary and cardiac plexuses, consists of the double chain of ganglia that lie on each side of the spinal column near the heads of the ribs. There is one ganglion upon each rib close to its head, and these are connected by non-medullated nerve-fibers; the lower two lie on the dorsal vertebræ. The upper six ganglia supply mainly the thoracic aorta, while the lower six do likewise and also supply the abdominal viscera through the splanchnic nerves. All these ganglia communicate by two or more external branches apiece (rami communicantes) with the corresponding intercostal nerves.

The **greater splanchnic nerve** is formed by branches from the sixth to the tenth thoracic ganglia, passes through the crus of the diaphragm to the semilunar (*celiac*) ganglion, and sends branches to the renal and suprarenal plexuses.

The **lesser splanchnic nerve** arises from the tenth and eleventh ganglia, perforates the crus of the diaphragm with the former, and goes to the celiac plexus.

The **smallest,** or **lowest, splanchnic nerve,** also called the renal nerve, originates in the twelfth ganglion, pierces the diaphragm, and ends in the renal plexus and lower part of the celiac plexus. It is frequently absent. For splanchnic anesthesia see page 136.

The *lymph glands* found in the posterior mediastinum are the *posterior intercostal glands* and the *posterior mediastinal glands*. The former receive the lymphatics from the intercostal spaces, the spinal canal, part of the diaphragm, and back, and are found in the posterior ends of the interspaces near the heads of the ribs. The efferent vessels of the left and the lower right glands empty into the thoracic duct. Those of the upper right glands may join the efferent bronchial lymphatics to empty into the right lymphatic duct. The posterior mediastinal glands, situated along the aorta and esophagus, receive the lymphatics from the back of the pericardium and left side of the heart, from the esophagus, from the posterior part of the diaphragm, and from a part of the right lobe of the liver. Their efferent vessels pass to the thoracic duct, a few only to the bronchial lymphatics.

These lymph glands may become enlarged, giving rise to pressure symptoms. They may also be the seat of secondary carcinoma.

The **joints of the thorax,** from behind forward, are: thirty-five between the bodies and articular surfaces of the thoracic vertebræ; forty-four between the vertebral bodies and their transverse processes with the ribs; fourteen between the costal cartilages and the sternum; ten between the cartilages of the lower true

and upper false ribs, and two between the sternum and clavicles, being a total of one hundred and five, all of which, except the two sterno-clavicular joints, permit but very limited motion. This enumeration does not include possible joints at either or both ends of the gladiolus sterni (*body of the sternum*).

The **ligaments of the vertebral bodies** are the anterior and the posterior common ligaments, and the intervertebral substance.

The **anterior common** (**anterior longitudinal**) **ligament** is a thick, broad fibrous band attached along the front of the vertebral bodies, prolonged upward and downward over the cervical and lumbar vertebræ, where it is narrower than in the chest. It is firmly united to the anterior edge of the intervertebral substance and adjacent edges of the bodies of the vertebræ, but is loosely attached between the edges of each body, where it is also thickest and serves to fill the anterior vertical concavities. It is composed of layers of longer and shorter fibers extending between adjacent and more distant vertebræ, the deepest and most lateral being the shortest, and the most superficial the longest, extending between four or five vertebræ.

The **posterior common** (**posterior longitudinal**) **ligament** is arranged like the preceding except that it is narrower and placed upon the back of the bodies of the vertebræ along the anterior wall of the spinal canal, being separated from a portion of each vertebra by two large, thin-walled veins, the venæ basis vertebræ. It is separated from the dura mater of the spinal cord by loose connective tissue which is sometimes the seat of a serous infiltrate.

The **intervertebral substance** is composed of concentric layers of fibrous tissue and fibrocartilage, with their edges facing the adjacent vertebræ forming the *annulus fibrosus*, and within them a soft, pulpy, highly elastic mass, the *nucleus pulposus*. Of the concentric layers, the outer ones bulge outward and the inner ones inward. The intervertebral segments act as buffers, and are thicker posteriorly than anteriorly, in the thoracic region, thus assisting in forming the backward bend of the thoracic portion of the column.

The laminæ are united by the **ligamenta subflava** (**ligamenta flava**), which extend almost vertically from the lower margin of the upper lamina to the top and back of the lamina below, throughout their entire length.

The articular processes are united by a **capsular ligament** attached to their circumference except upon their medial side, where the capsule is replaced by part of a ligamentum subflavum (*ligamentum flavum*). The capsular ligament is lined with synovial membrane.

The spinous processes are united by a strong fibrous **supraspinal ligament** extending across the tips of the spines, its fibers being of varying length, with arrangements similar to the anterior and posterior common (*longitudinal*) liga-

ments. The spines are also united by their membranous **interspinal ligaments,** connecting the adjacent margins of the spines of adjoining vertebræ.

The **intertransverse ligaments** are round fibrous cords extending between the transverse processes.

The joints between the heads of the ribs and the vertebral bodies have an anterior costo-vertebral, a capsular, and an interarticular ligament.

The **anterior costo-vertebral,** or **stellate, ligament** (**ligamentum radiatum**) consists of three radiating fibrous bands attached to the front of the heads of the ribs, whence they diverge medialward for attachment to the sides of the vertebral body immediately above and immediately below, and to the intervertebral substance between them, opposite the head of the rib. The thoracic sympathetic ganglia lie upon them, and also the vena azygos major (*azygos*) on the right side. Behind them are the synovial membranes and interarticular ligaments.

The **capsular ligament** is a very thin and loose bag, deficient anteriorly, where it is replaced by the preceding ligament. It is attached to the margins of the joint and is thickest on top.

The **interarticular ligament** extends between the sharp crest on the head of the rib and the intervertebral substance, thus dividing the joint into two cavities, lined by two distinct and non-communicating synovial sacs; it does not exist in the joints of the first, tenth, and twelfth ribs, as the intervertebral substance does not enter into their formation.

The joints between the neck and the tubercle of the rib and the vertebral transverse process have the following four ligaments: the anterior, middle, and posterior costo-transverse, and the capsular.

The **anterior costo-transverse ligament** consists of strong, short fibers extending between the upper surface of the costal neck and the lower edge of the transverse process above it, its lower or costal attachment being the wider. The intercostal vessels and nerves pass it in front, and the longissimus dorsi muscle hugs it behind. Its medial edge, together with the lateral side of the articular process, forms an opening for the transmission of the posterior branches of the intercostal vessels and nerves. It does not exist at the first and last ribs.

The **middle costo-transverse,** or **interosseous, ligament** (**ligament of neck of rib**) lies posterior to the preceding, and extends from the top of the back of the costal neck to the front of the transverse process above. It is rudimentary at the last two ribs.

The **posterior costo-transverse ligament** (**ligament of tubercle of rib**), short, thick, and strong, connects the tip of the transverse process with the rough portion of the costal tubercle. It varies in direction according to location, changing from an ascending course above to a descending one below.

The **capsular ligament** is attached to the adjacent peripheries of the joint surface of the costal tubercle and transverse process, and is lined with a synovial membrane.

The chondro-sternal joints have anterior and posterior, superior and inferior chondro-sternal and capsular ligaments.

The **anterior chondro-sternal,** or **costo-sternal, ligaments** are attached to the front of the sternal ends of the costal cartilages of the true ribs, whence they diverge for attachment to the adjacent part of the front of the sternum, and to blend with those of the other side, and with the tendinous origin of the pectoralis major muscle.

The **posterior chondro-sternal,** or **costo-sternal, ligaments** are the counterparts of the preceding at the back of the chondro-sternal joints, but are less distinct, and blend with the subjacent periosteum.

The **superior and inferior ligaments** are strong, well-marked bands connecting the upper and lower borders of the cartilage, respectively, with the lateral edges of the sternum. Owing to the close proximity of some of the cartilages, these ligaments are very closely allied, the superior ligament of the seventh even blending with the inferior of the sixth.

The **capsular ligaments** are united to the edges of the chondro-sternal joints; they blend with the anterior and the posterior ligaments, and are strengthened by a few fibers above and below, extending between the sternum and cartilage.

The **synovial membrane** varies at some of the joints, the first (uppermost) chondro-sternal joint having none, the second having two synovial membranes, one for each segment of the sternum, the third also having two, the remaining four having one each.

The **interchondral joints** are formed by the union of the seventh, eighth, ninth, and tenth costal cartilages by their adjacent margins, and usually by a separate joint between the sixth and seventh, and sometimes the fifth and sixth. They are united by a capsule lined with synovial membrane, the most constant joints being between the sixth, seventh, eighth, and ninth cartilages.

The **costo-chondral union** is secured by the union of periosteum and perichondrium.

Anterior and posterior sternal ligaments, running longitudinally, the latter the less marked, are found. They blend with adjoining fibrous tissue and are not so needful in adult life as during earlier years, when the different parts of the sternum are not yet united.

THE ABDOMEN

The **abdomen** includes the general abdominal cavity, its contents, and its boundaries.

The superficial boundaries of the abdomen are: above, the lower margin of the chest; below, the crests of the ilia, the creases of the groins, and the crests of the pubic bones, and laterally, the lateral margins of the erector spinæ (*sacrospinalis*) muscles.

The deep boundaries of the abdomen are those of the general abdominal cavity.

Form of the Abdomen.—The abdomen varies in form and extent in different individuals, in the two sexes, at different times of life, and as the result of pregnancy and pathologic conditions.

In the infant it is somewhat conical, being wider above than below, this difference being due to the relatively great size of the liver and small size of the pelvis. In the infant the bladder and the lower part of the sigmoid flexure are found in the abdomen, while in the adult they are in the pelvis.

In the female adult the abdomen is wider below than in the male, because of the greater width of the pelvis, and longer, on account of the greater length of the lumbar portion of the spinal column. The larger relative size of the adult female abdomen is also due to flabbiness of the abdominal muscles and the accumulation of fat. The lower portion of the thorax is narrower; the lower portion of the anterior abdominal wall is more prominent, and the greater amount of subcutaneous fat causes the general outlines to be more rounded than in the male; the greater obliquity of the female pelvis also leads to the greater prominence of the lower part of the anterior wall of the abdomen in this sex.

In the male adult a transverse section of the abdomen is oval and flattened anteroposteriorly; in muscular individuals the positions of the linea alba, lineæ semilunares, and lineæ transversæ (*tendinous inscriptions*) are indicated by slight depressions of the surface with intervening prominences.

In certain conditions the form of the abdomen is more or less characteristic; for instance, in ascites there is bulging in the flanks, and the abdomen is rather flat and is symmetrical; in tympanites the abdomen is uniformly distended and is rounded; an ovarian cyst causes the abdomen to be rather conical and to bulge anteriorly; in chronic diseases associated with great emaciation it is hollowed out anteriorly, or is scaphoid.

A pendulous or prominent abdomen in the adult is caused by excess of fat in the superficial fascia, which is thickest at the lower part of the abdomen, and

by relaxation of the belly-wall from stretching produced by pregnancy, ascites, or tumors.

The ease with which abdominal palpation can satisfactorily be practised depends upon the amount of subcutaneous fat and the degree of relaxation of the abdominal wall. In women who have borne a number of children and who have but a small amount of adipose tissue in the superficial fascia the wall of the abdomen is usually lax, and in such cases even small tumors can be detected; whereas, in a muscular adult with considerable adipose tissue palpation is rendered very difficult.

SURFACE ANATOMY (Plate CCCLXVII)

The **skin** covering the front of the abdomen is usually loosely attached, and especially in the regions of the groins; it is more adherent to the subjacent aponeurosis at the lineæ transversæ (*tendinous inscriptions*) and linea alba, but at the latter it is not so adherent as to hinder the spread of subcutaneous inflammation from one side of the abdominal wall to the other. In both sexes the skin over the bodies of the pubic bones and for some distance above is covered with hair. The skin of the lower part of the abdomen in parous women is often found to contain scar-like white lines, *lineæ albicantes*. These are due to atrophy of the skin, produced by stretching, and most commonly result from pregnancy, but may also be produced by distention from ascites or from ovarian or other large tumors. The skin may be furrowed in proportion to the subcutaneous fat or muscular development. In obese individuals two transverse furrows are found. The upper one intersects the umbilicus. The lower one passes just above the pubic crests, and the point where it intersects the linea alba is a convenient landmark for tapping a distended bladder.

The **linea alba,** the median line of the abdomen, extends from the ensiform cartilage (*xiphoid process*) to the symphysis pubis, and is the thinnest part of the abdominal wall, because no muscle tissue is found in that line. It is formed by the union of the medial borders of the sheaths of the recti, and is wider in its upper portion. Like the median line of the trunk elsewhere, it is the least vascular part of the abdominal wall; and hence is often preferred for incision in abdominal operations. In most cases the author prefers to operate through one of the rectus muscles or the flat muscles of the abdominal wall, as hernia is less likely to occur in a cicatrix including muscle and fascia than in one including only fascia or aponeurosis. Through the linea alba the abdomen is tapped for ascites, and the bladder is aspirated or opened in the suprapubic operation.

Above the umbilicus the course of the linea alba is indicated by a groove situated between two ridges formed by the rectus muscles, but below the umbilicus there is no depression marking the location of that line.

PLATE CCCLXVII.

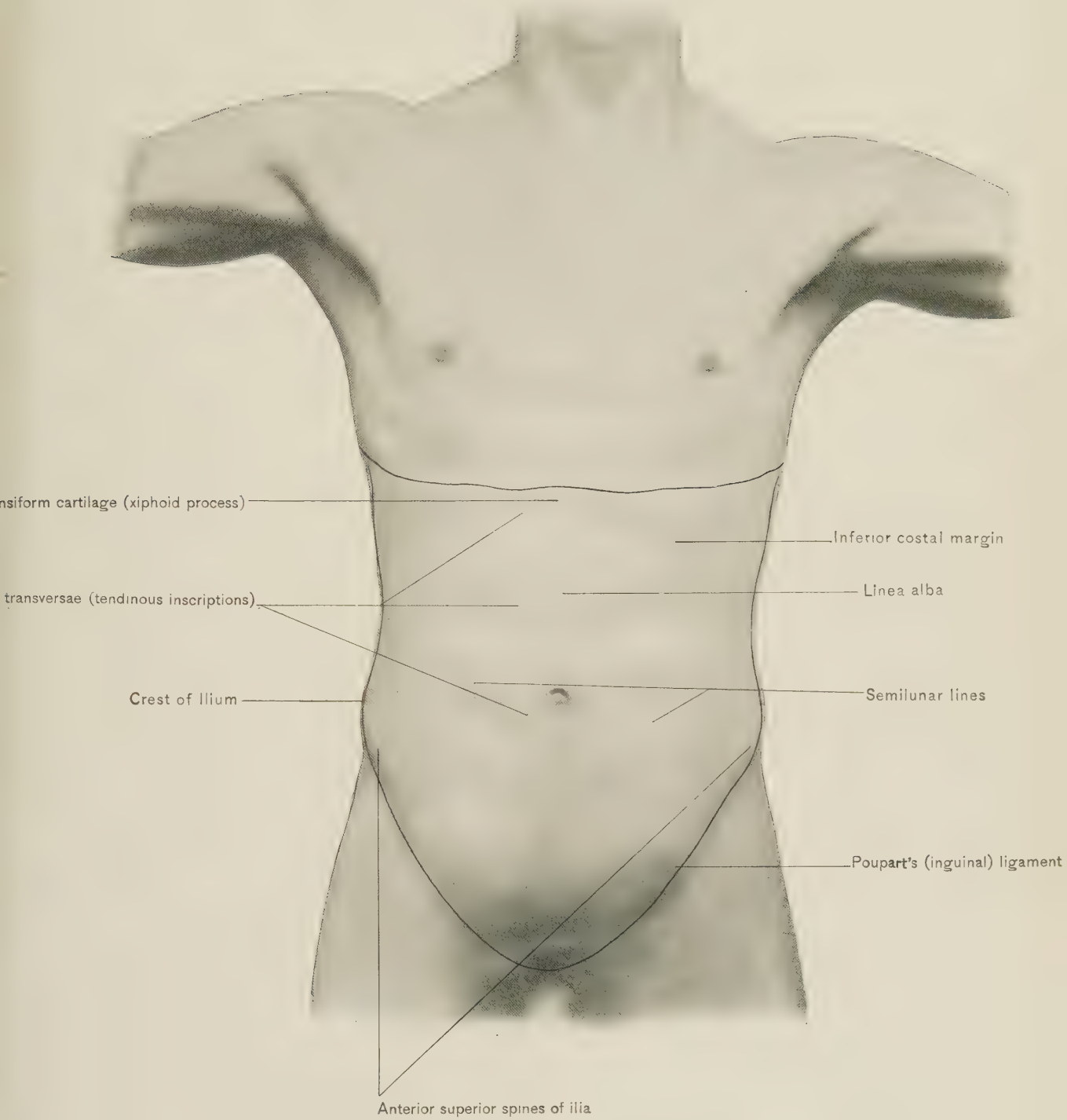

SURFACE ANATOMY OF ANTERIOR ABDOMINAL WALL.

Behind the linea alba, throughout its length, the peritoneum is in contact with the anterior abdominal wall, except at its lower two to four centimeters (three-fourths to one and a half inches) where the summit of the bladder intervenes. The left lobe of the liver extends across the upper four to five centimeters (one and a half to two inches) of the line. Below the liver is the stomach, which has a very extensive contact with the abdominal wall when distended, but which, when empty, is retracted or shrunken up behind the liver and left chest. It is when the latter condition is present that the upper part of the abdomen in the median line is sunken, and called the Pit of the Stomach. Below the stomach, but above the umbilicus, is the transverse colon, which occupies a varying space, depending upon the amount of gas and fecal matter it contains and the degree of ptosis present. Below the umbilicus the small intestine, covered by the greater omentum, lies behind the median line down to the crests of the pubic bones, except in the latter half of pregnancy, or when displaced by a large cyst or other tumor having its origin low down, or when the bladder is full of urine. When the bladder is distended, it carries the peritoneum upward and lies behind the lower five centimeters (two inches) of the linea alba, and may extend upward as far as the umbilicus.

The **lineæ semilunares,** one on each side of the linea alba, extend along the lateral margin of the rectus abdominis muscle, describing a curved line, with the concavity medialward, from the tip of the cartilage of the ninth rib to the medial side of the spine of the pubis. Each linea semilunaris in the upper three-fourths of the abdomen is about seven centimeters (three inches) from the linea alba, in the adult. Near the crest of the pubis this distance is not so great The lineæ semilunares mark the point of division of the abdominal aponeuroses to form the rectus sheath. They also form a line of limitation for extravasations in the lateral intermuscular spaces.

The **lineæ transversæ** (**tendinous inscriptions**) are caused by the adherence of the anterior wall of the sheath of the rectus abdominis muscle to the superficial fascia and the tendinous intersections of the rectus abdominis muscles; they extend between the linea alba and the lineæ semilunares. There are usually three on each side, the lowest being at the level of the umbilicus, the highest at the ensiform cartilage (*xiphoid process*), and the middle one about midway between the other two; sometimes there is one below the umbilicus. During contraction the rectus muscle forms elevations between these lines, which are more pronounced in muscular individuals. These elevations are plainly seen when the individual leans the trunk backward and extends both arms above the head, thus necessitating strong contraction of the rectus abdominis muscles.

The **umbilicus** is a depressed cicatrix situated slightly below the middle of the linea alba, but above the mid-point of the body in the adult and below it in the young child. Normally, it is opposite the third lumbar vertebra, or the disc between the third and the fourth lumbar vertebræ, but when the abdominal wall is pendulous it may be lower. In the fetus it is patulous, and gives passage to the vitello-intestinal duct and vessels, the allantoic duct, the two hypogastric (*umbilical*) arteries, and the umbilical vein. After separation of the umbilical cord after birth it is closed. Its chief interest lies in the fact that a hernia frequently protrudes at this point.

After separation of the stump of the umbilical cord there may be an **umbilical fistula** from which feces or urine escape. The feces escape through a persistent vitello-intestinal duct. The urine may escape as the result of a patent urachus which is derived from the allantois. The vitello-intestinal duct connects the yolk sac with the alimentary canal of the young embryo, and may persist as a canal or cord extending from the lower part of the ileum to the umbilicus. A small patent portion which sometimes remains at the junction with the ileum is known as Meckel's diverticulum (*diverticulum ilei*).

As the result of failure of union between the lateral halves of the abdominal wall at the median line below the umbilicus there occurs a defect known as **exstrophy of the bladder,** from the fact that the bladder-wall protrudes through the abnormal opening. In these cases the anterior wall of the bladder is also absent, and the posterior wall of that organ is the one which is seen. There is frequently associated with this condition a defective junction of the two halves of the pelvis at the symphysis pubis. The penis may be rudimentary, and the urethra open on the dorsum of that organ; the latter abnormality is known as **epispadias.**

The **limits of the anterior and lateral abdominal wall** are the lower border of the thorax, the lateral margins of the quadratus lumborum muscles, the crests and anterior superior spines of the ilia, Poupart's (*inguinal*) ligaments, and the spines (*tubercles*), crests, and symphysis of the pubic bones.

The **ensiform cartilage** (**xiphoid process**) lies in the angle of the infrasternal space. It is irregular in size, shape, and direction: it may be broad and flaring, narrow and pointed, long or short, bifid or perforated; it may curve forward or laterally, or may incline backward and cause pain by pressure upon subjacent structures.

The **infracostal,** or **infrasternal, angle** is formed by the divergence of the anterior portions of the lower margins of the thorax, and varies considerably in different individuals, from the wide flaring angle of the professional runner to the long narrow angle of the "pigeon-breast." It is artificially narrowed to a

considerable extent in women who wear tight belts. When this angle is almost, or more than a right angle and its margins are freely movable, respiration is deep and complete; whereas, a small infracostal angle is associated with a contracted chest, which is considered a predisposing cause of chronic pulmonary disease.

The **anterior superior iliac spines** are readily located even in stout individuals. They are valuable landmarks in the diagnosis of disease of the abdomen, pelvis, hip, and lower extremity, because of their fixity and ease of identification. They are used in estimating the size of the pelvis, and are guides in some abdominal operations and in ligating the iliac and femoral arteries. From them the length of the lower limbs can be measured.

The anterior parts of the crests of the ilia are grasped to test for crepitus and unnatural mobility in fracture of the pelvis. A line drawn through the highest points of the crests of the ilia passes about two centimeters (three-fourths of an inch) below the umbilicus and about four centimeters (one and a half inches) below the lower extremities of the kidneys. This line also passes through the spinous process of the fourth lumbar vertebra.

The **spine of the pubis** (**pubic tubercle**) is a valuable landmark in the differential diagnosis of femoral and inguinal herniæ. The guide to it is the adductor longus muscle. Abduction of the thigh increases the tension of the tendon of origin of the adductor longus, which is attached to the body of the pubis just below and medial to the spine (*tubercle*), and will guide the finger to the spine (*tubercle*). The spine of the pubis (*pubic tubercle*) is a guide to the external abdominal (*subcutaneous inguinal*) ring, which is most readily found by invaginating the scrotum with the finger and carrying it upward under the superficial fat. In the differential diagnosis between inguinal and femoral herniæ the spine of the pubis (*pubic tubercle*) should be located; if the neck of the hernia lies above and medial to the spine of the pubis (*pubic tubercle*), it is an inguinal hernia; if it is below and lateral, it is a femoral hernia.

The **crease of the groin** extends from the anterior superior spine of the ilium toward the spine of the pubis (*pubic tubercle*), and is continuous with the crease between the thigh and the scrotum or the labium majus. It is produced by the attachment of the deep layer of the superficial fascia to the fascia lata immediately below Poupart's (*inguinal*) ligament.

The **external abdominal** (**subcutaneous inguinal**) **ring** is situated upon the medial side of, and above the pubic spine (*pubic tubercle*). The opening readily admits the tip of the little finger when introduced by invaginating a fold of the scrotum.

The **internal abdominal** (**abdominal inguinal**) **ring** is from one to two centimeters (one-half to three-fourths of an inch) above and slightly lateral to

the middle of Poupart's (*inguinal*) ligament. The abdominal rings are called internal and external, with reference to their proximity to the abdominal cavity and not to the median line, for their relation to the median line of the body is the reverse of the positions which their names imply.

The **inguinal canal** is a space within the lower part of the anterior abdominal parietes, above and parallel with the medial half of Poupart's (*inguinal*) ligament; it is occupied by the spermatic cord, or round ligament of the uterus, the ilio-inguinal nerve, and the genital (*external spermatic*) branch of the genito-crural (*genito-femoral*) nerve. The canal, as such, does not actually exist, for the structures forming the walls are united, though loosely, to the contents. Its direction is downward and medialward; its length is from four to five centimeters (one and a half to two inches). Because of its obliquity, any hernia passing through it is called oblique.

The **spermatic cord,** after its exit from the external abdominal (*subcutaneous inguinal*) ring, is easily identified as a complex, soft, round cord, and the vas (*ductus*) deferens is readily felt at its posterior part.

The **deep (inferior) epigastric artery** runs upward and medially from midway between the anterior superior spine of the ilium and the symphysis pubis toward the umbilicus. Its line is frequently given from the point of junction of the medial and middle thirds of Poupart's (*inguinal*) ligament to the umbilicus. The line has a slight medial curve and crosses the lateral edge of the rectus muscle at a point about one-third of the distance between the symphysis pubis and the umbilicus. It passes behind the lateral part of the inguinal canal, immediately to the medial side of the internal abdominal (*abdominal inguinal*) ring, and bears an important relation to direct and indirect inguinal herniæ. The direct hernia passes to the medial side of the artery, whereas the indirect hernia, which first traverses the internal (*abdominal inguinal*) ring, passes to the lateral side of the artery.

The **solar plexus** and the origin of the **celiac axis** (**celiac artery**) are from ten to twelve centimeters (four to five inches) above the umbilicus, and opposite the spinous process of the twelfth thoracic vertebra.

The **superior mesenteric** and **suprarenal arteries** arise immediately below the celiac axis (*celiac artery*). The **renal arteries** arise about one centimeter (three-eighths of an inch) below the celiac axis (*celiac artery*), opposite the interval between the spinous process of the twelfth thoracic and that of the first lumbar vertebra.

The **inferior mesenteric artery** arises about two to three centimeters (three-fourths to one and one-eighth inches) above the umbilicus.

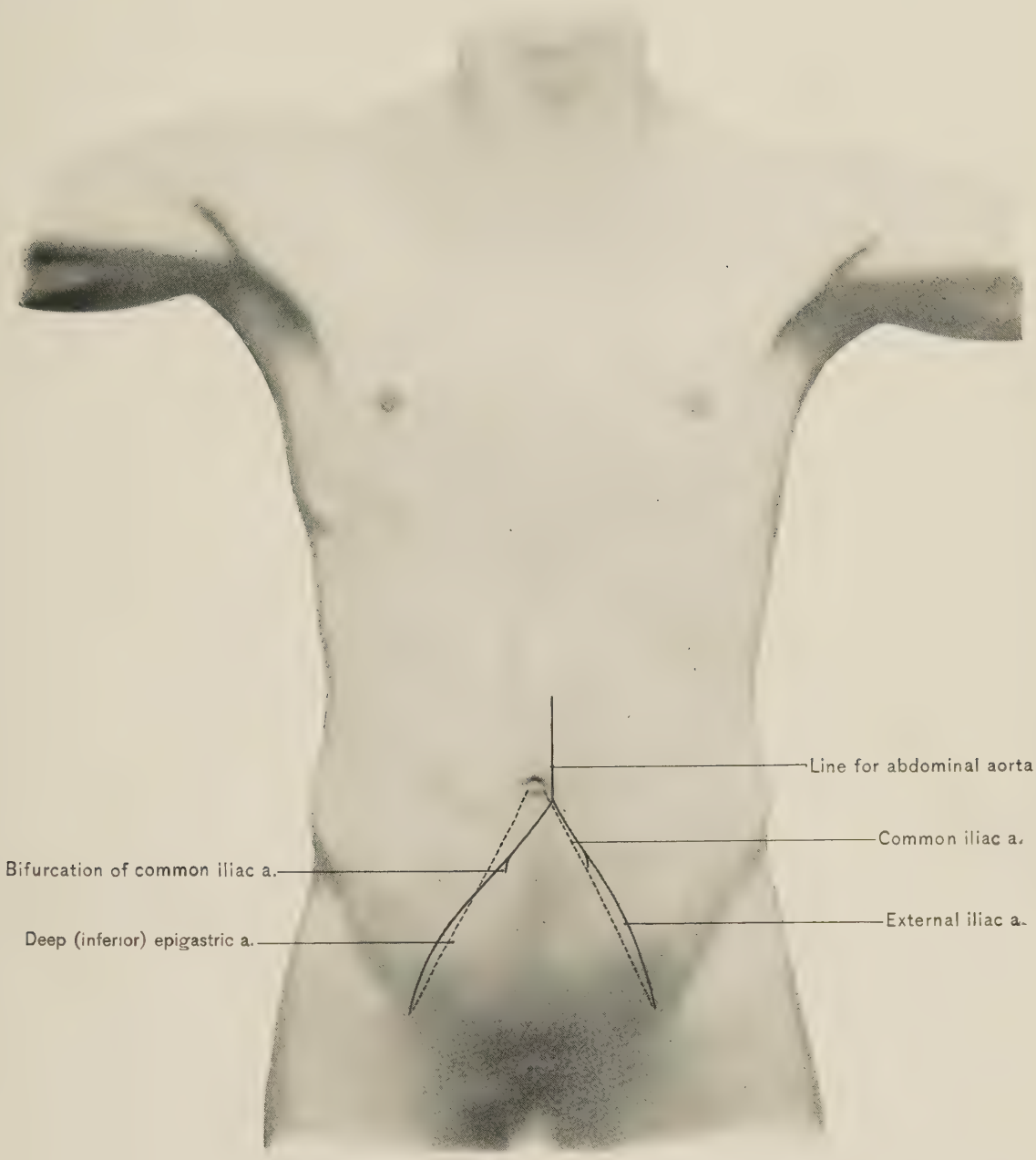

LINES OF ARTERIES.

PLATE CCCLXIX.

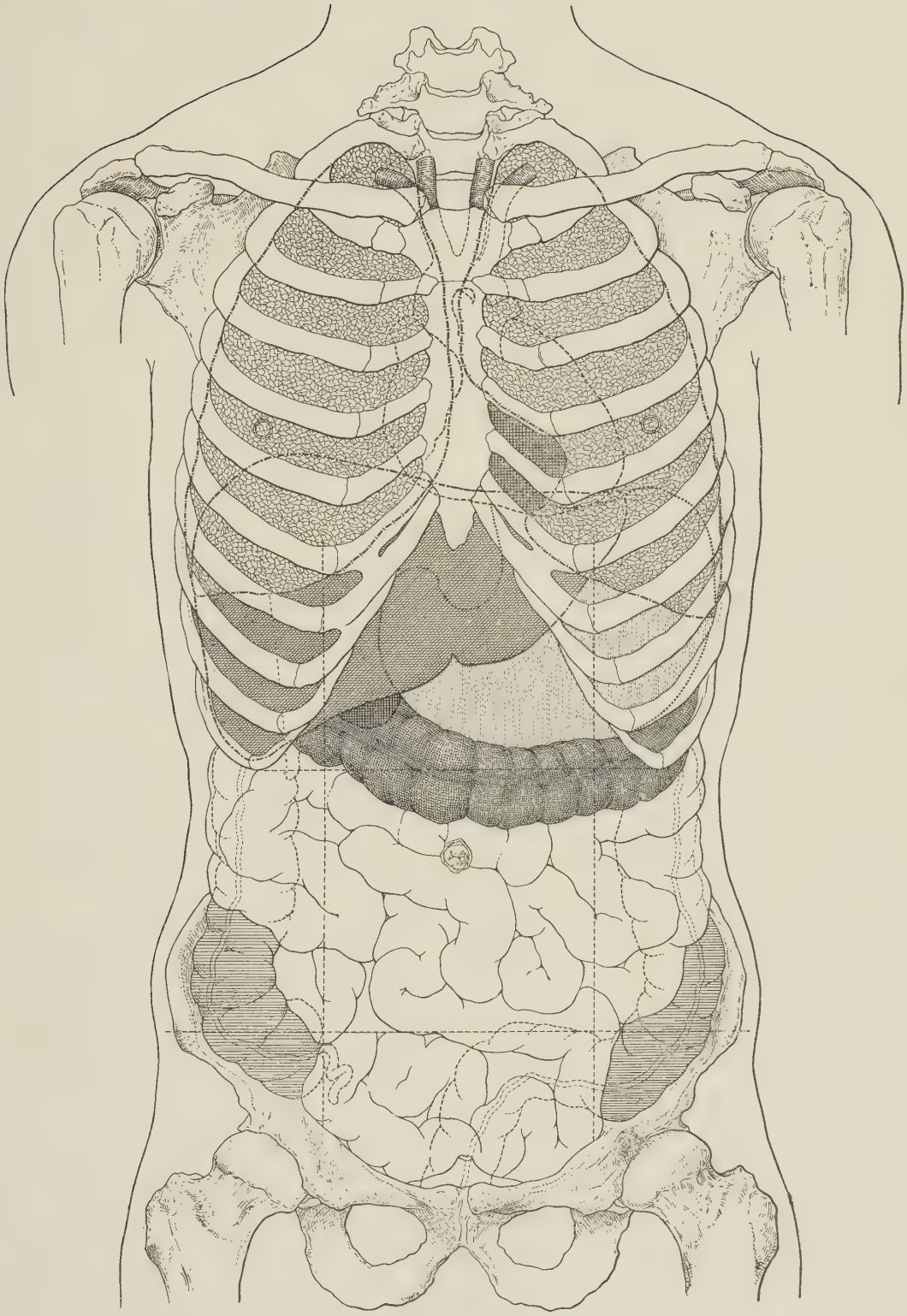

DIAGRAM OF ABDOMINAL VISCERA AND LUNGS,—ANTERIOR VIEW.

PLATE CCCLXX.

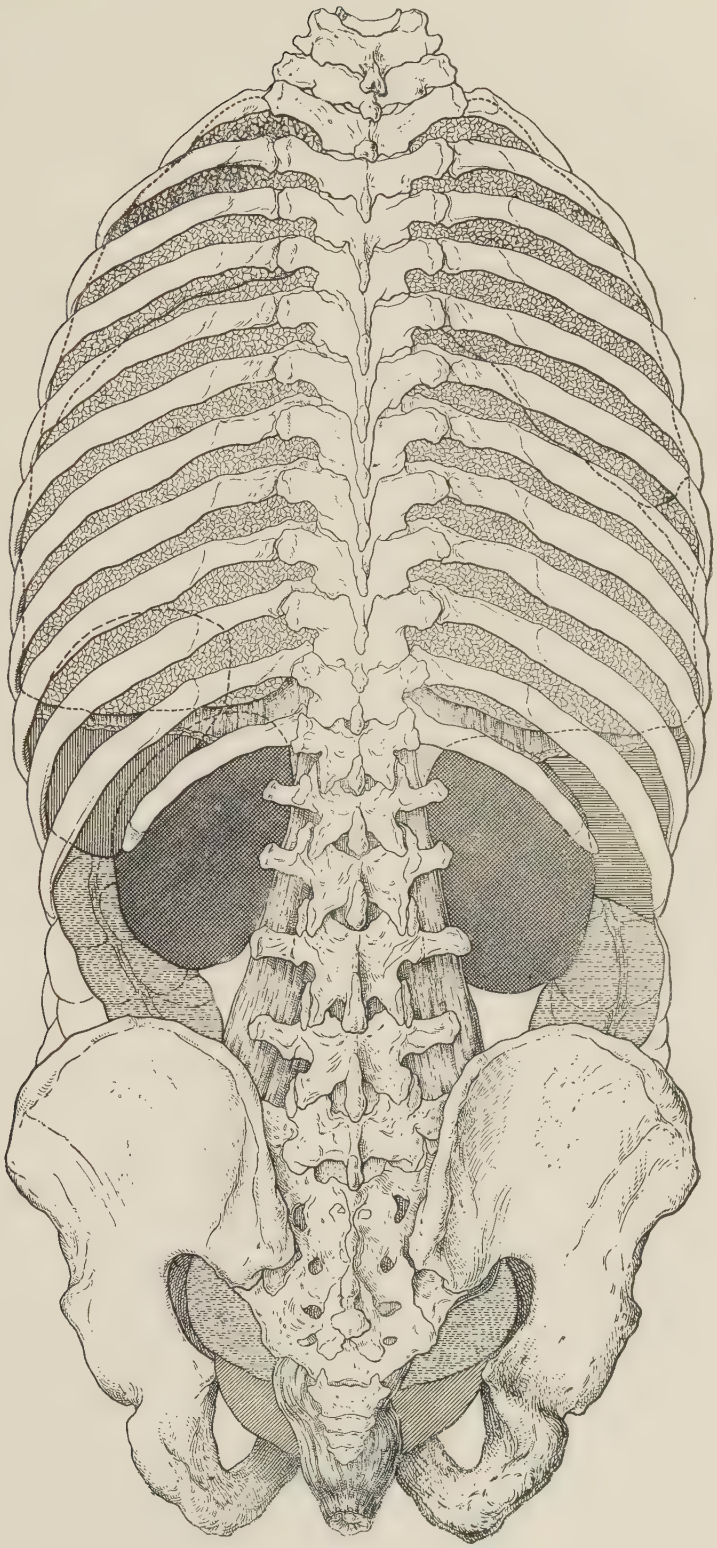

DIAGRAM OF ABDOMINAL VISCERA AND LUNGS,—POSTERIOR VIEW.

PLATE CCCLXXI.

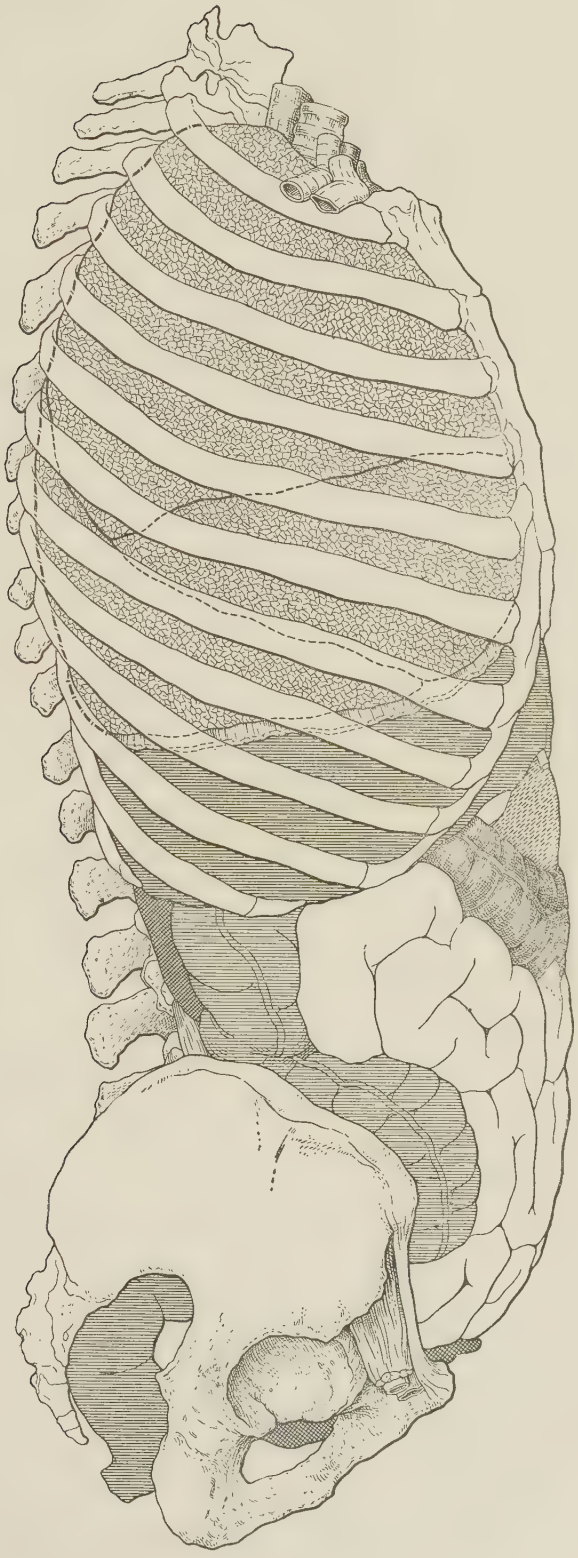

DIAGRAM OF ABDOMINAL VISCERA AND LUNGS,—RIGHT SIDE.

PLATE CCCLXXII.

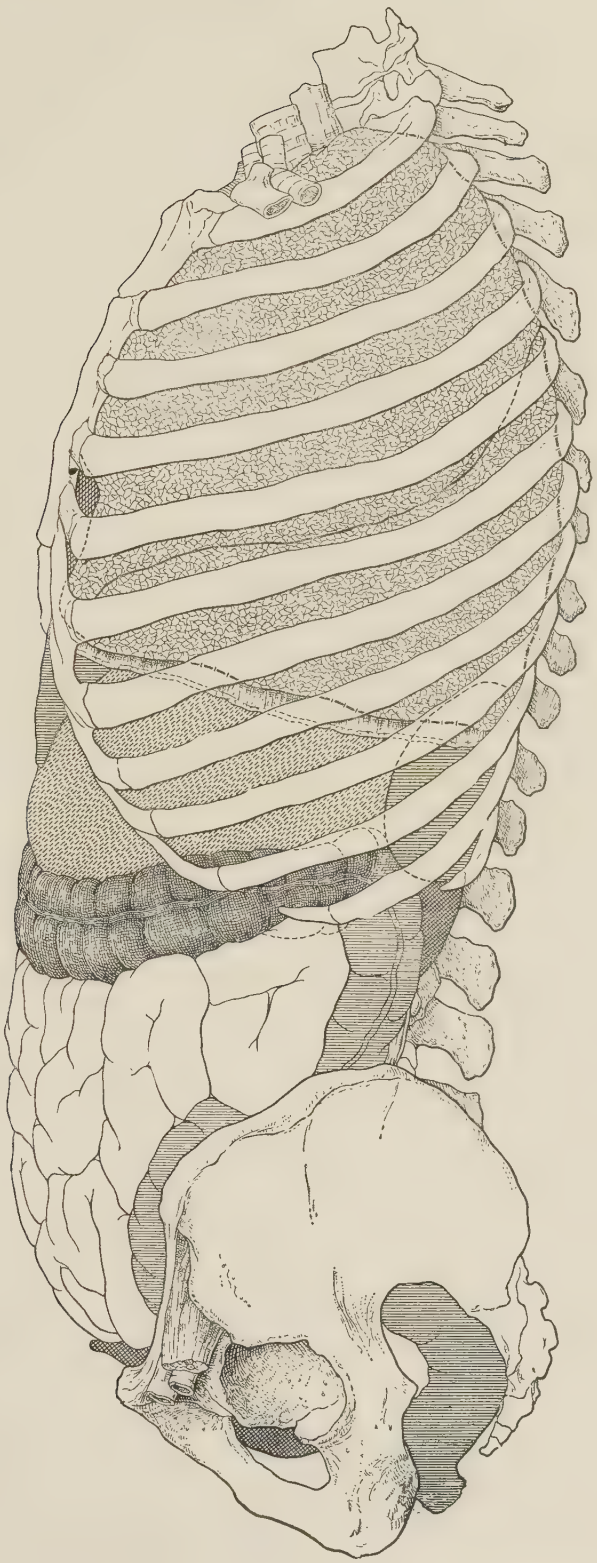

DIAGRAM OF ABDOMINAL VISCERA AND LUNGS,—LEFT SIDE.

Compression of the abdominal aorta is best effected by backward pressure applied just below and slightly to the left of the umbilicus, immediately above the division of the aorta into the common iliac arteries. As the position of the umbilicus is variable it is preferable to use a point about one centimeter (half an inch) to the left of where a line joining the iliac crests crosses the linea alba. This is the site of the bifurcation of the aorta. Here it is most superficial, whereas higher up it is covered by important structures, and gives off branches whose current the surgeon does not wish to check, also the thorax would prevent approximation of the anterior abdominal wall to the vertebræ.

The pulsations of the aorta can be felt along the left side of the linea alba; in thin subjects they are felt so distinctly that the pulsating aorta may be mistaken for an aneurysm or other tumor.

The **bifurcation of the aorta** (Plate CCCLXVIII) is usually situated two centimeters (three-fourths of an inch) below, and slightly to the left side of the umbilicus; but as the umbilicus itself varies somewhat in location, a more fixed guide is desirable, so it is preferably stated that the bifurcation of the aorta is opposite a point about one centimeter (a half an inch) to the left of the intersection of the linea alba with a line connecting the highest points of the iliac crests.

The **line for the common iliac artery and the external iliac artery** is one slightly curved, with its concavity directed toward the pubic bone, and drawn from the point representing the location of the bifurcation of the aorta to a point midway between the anterior superior spine of the ilium and the symphysis pubis. The first five centimeters (two inches) of this line mark the course of the common iliac artery, and the remainder of the line, that of the external iliac artery. The length of these two vessels may vary, but the relations to the external line remain substantially the same.

The **locations of the abdominal viscera** (Plates CCCLXIX, CCCLXX, CCCLXXI, and CCCLXXII) should be outlined with considerable accuracy in both medical and surgical practice, as success in diagnosis depends largely upon a correct knowledge of the relations of the organs to the abdominal wall. In all examinations of the abdomen the patient should lie upon the back with the knees raised and the head and shoulders slightly elevated on pillows so that the muscles of the anterior abdominal wall are relaxed. Palpation should be practiced with the palm of the hand flat on the abdomen, and not merely with the finger-tips, as the latter method induces reflex contraction of the muscles which prevents manipulation. After the parts have been manipulated for a few moments they become less sensitive, palpation can be more active and more localized and can then be made with the finger-tips.

Position of the Diaphragm.—The partition between the abdomen and thorax is formed by the diaphragm. A transverse plane passing backward through the body at the level of the seventh chondro-sternal junction represents the level of the central tendon, which is the highest part of the diaphragm. The attachments of the margins of the diaphragm correspond to a line running along the inferior and lateral margins of the ensiform cartilage (*xiphoid process*), thence from the seventh chondro-sternal junction along the lower borders of the costal cartilages to the tip of the last rib, and thence to the tip of the transverse process of the first lumbar vertebra, about two and a half centimeters (one inch) from the spinous process of that vertebra.

A knowledge of the line of attachment of the diaphragm is important in connection with operation on the kidneys through the loin, as the pleural cavity has been known to be opened during a lumbar nephrolithotomy. A knowledge of the position of the diaphragm is also important in performing thoracentesis, as the aspirating needle may puncture the muscle and enter the peritoneal cavity.

The **liver** lies in the right hypochondriac, the epigastric, and sometimes extends into the left hypochondriac region as far as the left mid-clavicular line. The anterior margin of the right lobe projects about one centimeter below the costal border, where, during respiration, it can be felt moving upward and downward with the diaphragm, to which it is attached. This border is not so easily recognized as the anterior margin of the left lobe, which extends across the epigastric region, below the ensiform cartilage (*xiphoid process*) and is pushed prominently forward by the stomach when that organ is distended. The liver may extend further downward from various causes, such as hypertrophy or congestion, the accumulation of fluid, or the presence of a tumor above it in the pleural cavity. The liver ascends as high as the right dome of the diaphragm, within two and a half centimeters (one inch) of the level of the nipple, and to a position opposite the lower end of the gladiolus (*body*) of the sternum. Therefore below this level, which is that of the fifth intercostal space in the mid-clavicular line, hepatic dulness is elicited upon deep percussion over a normal right lung. At the side of the spinal column the liver approaches the surface at the level of the tenth and eleventh thoracic spines, or at the posterior part of the base of the lung.

The liver extends as high as the diaphragm, which conforms to its upper surface. The *outline of the liver*, as marked on the surface of the body, can only be approximated, because the organ descends during inspiration and ascends during expiration, and its shape and position may also be slightly altered by tight corsets. The liver usually extends only four centimeters (one and a half inches) beyond the left side of the sternum, or it may reach the left mid-clavicular

line. It reaches as high as a transverse line drawn through the lower end of the mesosternum (*body of the sternum*); in the mid-clavicular line this transverse line passes over the fifth intercostal space or lower border of the fifth rib. The upper surface of the left lobe of the liver is opposite a transverse line drawn through the lower end of the mesosternum (*body of the sternum*). The upper surface of the right lobe is opposite the lower border of the fifth rib, in the right mid-clavicular line; in the right midaxillary line, opposite the seventh rib; in the mid-scapular line, opposite the ninth rib, and at the side of the spinal column, it is opposite the tenth thoracic spinous process. The lower surface of the right lobe posteriorly, or at the side of the spinal column, is opposite the eleventh thoracic spinous process; at the right midaxillary line, it is opposite the costal margin. Between the midaxillary line and the right linea semilunaris the thin anterior margin of the liver extends about one centimeter (half an inch) below the costal margin; this margin passes across the epigastrium in a line drawn from the ninth right, through the left eighth costal cartilage.

The **gall-bladder** is almost covered by the liver, but when filled, its fundus projects beyond the anterior border of this gland at the lateral margin of the right rectus abdominis muscle, just below the ninth costal cartilage. This is known as Mayo-Robson's point.

The **stomach** varies in size, being smaller when empty and larger when distended; its relations, therefore, are not always the same. The stomach holds an oblique position, lying behind the diaphragm and left chest-wall below the level of the sixth chondro-sternal junction, and behind the anterior abdominal wall and left lobe of the liver. When distended, it is in contact with the anterior abdominal wall in a triangle bounded by the anterior margin of the liver, the left ninth and tenth costal cartilages, and a line drawn between the tenth costal cartilages. It is at this point that gastrotomy and gastrostomy are performed.

The **cardiac orifice** of the stomach is opposite a point two and a half centimeters (one inch) to the left of the left seventh chondro-sternal junction anteriorly at the level of the eleventh thoracic vertebra. The **pyloric orifice** lies beneath the liver; when empty, it lies about seven centimeters (three inches) below the sterno-xiphoid articulation, slightly to the right of the median line at about the level of the first lumbar vertebra, but as the stomach becomes distended it approaches the right linea semilunaris. The **transpyloric plane** is a horizontal plane midway between the upper border of the sternum and the crest of the pubis, and midway between the ensiform cartilage (*xiphoid process*) and the umbilicus. It is at the level of the following viscera: the pylorus, the first portion of the duodenum, the gall-bladder, and the duodeno-jejunal flexure. Along this plane may also be found the hila of the kidneys, the beginning of the ureters, the

body of the pancreas, the beginning of the mesentery, and the body of the first lumbar vertebra.

The **line for the lesser curvature** of the stomach is drawn from the position of the cardiac orifice to that of the pyloric orifice. The **line for the greater curvature** extends upward and to the left from the position of the cardiac orifice to the fifth rib, slightly lateral to the left mid-clavicular line, and thence to the position of the pyloric orifice. The line for the lesser curvature is curved toward the outlined area of the stomach, and that for the greater curvature away from that area.

The **spleen** is in contact with the greater curvature of the stomach at its cardiac end. It is situated medial to the ninth, tenth, and eleventh ribs, from which it is separated by the diaphragm and a wedge-shaped portion of the lung. Its anterior margin is in a line drawn from the left sterno-clavicular articulation to the tip of the eleventh rib. Its extent under the ribs can be estimated by its area of dulness on percussion. This can be most reliably elicited when the stomach is either distended or fully contracted, as either condition forms a background of relatively uniform density. A duller note is heard over the tenth and eleventh ribs than over the ninth, because of the presence of the lung between the diaphragm and the chest-wall opposite the uppermost part of the spleen. The spleen is enlarged in various diseases, chief among which are malaria, the splenic anemias, hepatic cirrhosis, kala-azar, Gaucher's disease, von Jaksch's anemia, etc. It may be so enormously enlarged as to reach the crest of the ilium, and may weigh from seven to nine kilograms (fifteen to twenty pounds). Its normal weight is two hundred and twenty-five grams (eight ounces).

The **pancreas** crosses the spinal column, the inferior vena cava, and the aorta behind the stomach, at the first lumbar vertebra. It can be felt only by firm, deep pressure five to seven centimeters (two to three inches) above the umbilicus, through a thin abdominal wall and with the viscera empty. It may sometimes be mistaken for cancer of the colon or stomach, or aneurysm of the aorta. The tail of the pancreas reaches from the left side of the twelfth dorsal spine to the tenth rib above the transpyloric plane. The head lies below the transpyloric plane on a level with the second lumbar vertebra.

The **kidneys** lie upon the posterior abdominal wall, against the psoas magnus (*psoas major*) and quadratus lumborum muscles, opposite the spinous processes of the lower two thoracic and upper two lumbar vertebræ, the right kidney being situated slightly nearer the median line, and two centimeters (three-fourths of an inch) lower than the left, because of the position of the liver. The *pelves of the ureters* are about opposite the spinous process of the first lumbar vertebra. Deep inspiration depresses both kidneys about one centimeter (half an inch), a fact

worth remembering in their examination. Although it is difficult to distinguish the kidney under the last rib, unless there exists a degree of nephroptosis, its degree of tenderness can readily be determined there. Neoplasms of the kidney may be detected by palpating the loin. Care should be exercised not to mistake morbid growths, portions of the spleen or liver, or hardened fecal accumulations in the colon for the kidney. A transverse plane through the umbilicus passes just below the lower border of the kidneys, and each kidney is bisected by a line drawn vertically upward from the middle of Poupart's (*inguinal*) ligament. The intersection of the transverse and vertical lines, therefore, marks the middle of the lower pole of the kidney. A kidney may be removed through an oblique or a longitudinal incision made in the loin, or through an incision along the linea semilunaris. In the last-named incision, but not in either of the loin operations, the peritoneum is opened.

The **large intestine** is divided into the cecum, the colon, and the rectum; and the colon, into the ascending, transverse, and descending colon. The colon has three flexures, the hepatic (*right colic*), splenic (*left colic*), and sigmoid.

The **cecum,** with its **vermiform appendix,** lies in the right iliac fossa below the intertubercular plane, one-third medial and two-thirds lateral to the mid-Poupart (*inguinal*) line. The **ascending colon** extends up the right side of the abdomen, through the right lumbar region, until it reaches the under surface of the right lobe of the liver, where, in the right hypochondriac region, it makes a bend to the left, called the **hepatic (right colic) flexure;** then, as the **transverse colon,** it crosses the abdomen, making a downward curve, almost to the umbilicus. The **splenic (left colic) flexure** lies in the left hypochondrium, in relation with the anterior surface of the spleen, and is the curving downward of the transverse colon to become the **descending colon,** which is narrower and more deeply situated than the ascending colon. The descending colon extends downward through the left lumbar region to the left iliac fossa, where it becomes the **sigmoid flexure (iliac colon).** Each vertical portion of the colon lies against a kidney and the quadratus lumborum muscle. The **sigmoid flexure (iliac colon)** forms one or two folds in the left iliac fossa and the hypogastrium before it passes into the pelvis, to become the **rectum.** The entire colon, with the exception of the hepatic (*right colic*) and splenic (*left colic*) flexures, is accessible to palpation, so that masses of hardened feces in the colon and tumors of the colon can be felt.

The **small intestine** is suspended by its mesentery in the median portion of the abdomen, below the umbilicus, and its area of tympany is bounded above by the transverse colon, and laterally by the ascending and descending colon. The mesentery extends from two and one-half centimeters (one inch) to the left

of the middle of the transpyloric plane and a little below it to a point midway between the right anterior superior iliac spine and the midline.

The **bladder,** when empty, lies entirely in the pelvic cavity below the level of the crests of the pubic bones, but when filled with urine it extends above the brim of the pelvis, sometimes as high as the umbilicus, displacing the small intestine, posteriorly and laterally. A distended bladder is recognized by prominence of the lower portion of the abdomen and by a dull percussion note and by fluctuation. Fluctuation is best elicited by placing the finger in the rectum in the male or in the vagina in the female, against the base of the bladder, and tapping the summit through the abdominal wall with the fingers of the disengaged hand.

THE ABDOMINAL PARIETES

The **thickness of the abdominal wall** varies in different locations and in different individuals; it is thinnest at the linea alba. At the upper portion of the linea alba the superficial fascia and the blended aponeuroses are comparatively so thin that an instrument will more easily enter the abdominal cavity at this point than elsewhere. The variation in the thickness of the wall in different individuals is chiefly produced by the superficial fascia. In emaciated persons the abdominal parietes may be so thin that the outlines of some of the viscera and the movements of the stomach and intestines can be seen, although imperfectly, and the organs can readily be palpated; the loss of subcutaneous and extraperitoneal fat causes the parietes to collapse and become concave instead of convex.

Dissection (Plate CCCLXXIII).—In dissecting the abdomen, a block should be placed beneath the pelvis and a smaller block under the shoulders. When the abdominal wall is lax and flaccid, the dissection is facilitated by distending the abdomen with air, by means of a blow-pipe inserted through the umbilicus into the peritoneal cavity.

In reflecting the skin from the front and sides of the abdomen, only two incisions should be made. Each is commenced above, at the side of the chest, on a level with the xiphoid joint, and carried downward in a straight line to the crest of the ilium; next, along the crest to the anterior superior spine of the ilium, and thence along the line of Poupart's (*inguinal*) ligament to the symphysis pubis, where the two incisions meet. Commencing below, the skin is dissected upward from the superficial fascia in one large flap. This large flap of skin gives an excellent covering for the remaining layers of the abdominal wall, and when the flap is replaced, allows the student to review the surface anatomy of the part and study the relations which the deeper parts bear to the surface.

PLATE CCCLXXIII.

INCISIONS FOR DISSECTION.

PLATE CCCLXXIV.

SUPERFICIAL FASCIA OF THE ABDOMEN AND SUPERFICIAL VESSELS.

The **superficial fascia of the abdomen** (Plate CCCLXXIV) is continuous with the superficial fascia of the neighboring parts; it consists of two layers, which are readily demonstrable by dissection, especially over the iliac regions. Running in this fascia are the following subcutaneous vessels and nerves: the superficial epigastric and the superficial circumflex iliac arteries and veins, branches of the superior epigastric, deep (*inferior*) epigastric, and lower intercostal vessels; the lateral and anterior cutaneous branches of the lower thoracic nerves, branches of the ilio-hypogastric and ilio-inguinal nerves, and some lymph vessels and glands.

The **superficial layer of the superficial fascia,** or **Camper's fascia,** contains the greater bulk of the subcutaneous fat of this region. It is continuous with the same layer of the superficial fascia of the thigh, with the cellular tissue layer of the penis and the scrotum, and with the superficial layer of the superficial fascia of the perineum. In very corpulent individuals the layer of subcutaneous fat, sometimes called the panniculus adiposus, is thicker here than elsewhere, sometimes being from ten to fifteen centimeters (four to six inches) in thickness. In such individuals an incision can be carried to some depth into this layer without dividing blood-vessels of any significance, since they are in the deeper part of the superficial fascia. The superficial layer is separated from Poupart's (*inguinal*) ligament by the superficial epigastric and superficial circumflex iliac vessels, the upper set of inguinal lymph glands, and the deep layer of the superficial fascia. This superficial layer is sometimes divisible into a number of layers, while again it is very thin and somewhat membranous near the thigh. In the female a thick deposit of fat in the superficial layer immediately above and over the bodies of the pubic bones produces the elevation known as the *mons veneris* (*mons pubis*).

The **deep layer of the superficial fascia,** or **Scarpa's fascia,** of the abdomen is thinner and more membranous than the superficial layer, and contains yellow elastic fibers. In this respect it resembles the tunica abdominalis of the lower animals, which assists in the support of the abdominal viscera. It is closely attached to the lateral lip of the crest of the ilium, the fascia lata immediately below Poupart's (*inguinal*) ligament, and the aponeurosis of the external oblique muscle, at the linea alba and the lineæ transversæ (*tendinous inscriptions*). Elsewhere it is loosely attached by areolar tissue to the underlying aponeurosis of the external oblique muscle.

The Scroto-abdominal Passageway.—Between the spine of the pubis and the symphysis pubis the deep layer of the superficial fascia is loosely attached to the underlying structures, and passes downward over the spermatic cord and the body of the pubis, where it becomes continuous with the dartos of the penis and

scrotum. The space between the body of the pubis and the arch of the deep layer of the superficial fascia is the **scroto-abdominal passageway.** Extravasated urine which has reached the scrotum and distended it to its fullest capacity will pass upward to the abdominal wall through these two intervals, which are placed one upon each side of the symphysis pubis. Having reached the abdominal wall, the urine is unable to pass downward upon the thigh or upon the gluteal region, on account of the attachment of the deep layer of the superficial fascia to the fascia lata near Poupart's (*inguinal*) ligament, and to the crests of the ilia, nor can it pass over the linea alba, on account of the attachment of the fascia to the aponeurosis along this line. Fluid beneath this layer is prevented from entering the inguinal canal by the intercolumnar (*external spermatic*) fascia, which closes the external abdominal (*subcutaneous inguinal*) ring. Emphysematous collections following an injury to the chest, such as fracture of the ribs, when beneath the deep layer of the superficial fascia, cannot descend beyond the crest of the ilium or Poupart's (*inguinal*) ligament, nor pass over the linea alba, on account of the attachments of the fascia, but the air can pass into the scrotum, and through it reach the perineum. If the air passes superficial to this layer, the emphysema may extend to the thighs. What has been said about a collection of air beneath this layer is equally true of a collection of pus.

An extension and a thickened portion of the deep layer of the superficial fascia, attached to the lower part of the linea alba and to the symphysis pubis, passes to the dorsum and sides of the penis, constituting the **suspensory ligament of the penis.** Like the fascia from which it is derived, it is composed of fibro-elastic tissue.

The arrangement of the superficial fascia of the lower part of the abdomen of the female is similar to that of the male, except that in the female the deeper layer is continuous with the dartos of the labia majora.

Dissection.—Upon one side of the lower part of the abdomen a quadrilateral area of the superficial layer of the superficial fascia should be reflected downward, slightly beyond the position of Poupart's (*inguinal*) ligament, to demonstrate the two layers of the superficial fascia. On the other side, trace the superficial circumflex iliac and superficial epigastric vessels, and note the oblique or superior set of inguinal lymph glands which are placed in the superficial fascia above and along the crease of the groin.

The **superficial epigastric artery** is a branch of the femoral, and ascends over Poupart's (*inguinal*) ligament near its center, running upward and medially between the superficial and deep layers of the superficial fascia of the abdominal wall, toward the umbilicus. It gives off branches to adjacent lymph nodes and the integument, anastomosing with cutaneous branches of the deep (*inferior*)

epigastric artery. Usually it is a very small vessel with large venæ comites. From the relation which the superficial epigastric artery bears to the coverings of the inguinal canal it is quite evident that it will be divided in an operation for the relief of an inguinal hernia.

The **superficial circumflex iliac artery** is a branch of the femoral. It pierces the fascia lata lateral to the saphenous opening (*fossa ovalis*), runs upward and laterally upon the upper part of the thigh, crosses the lateral end of Poupart's (*inguinal*) ligament, and divides into two branches which supply the integument of the lower part of the abdomen. It anastomoses with the deep circumflex iliac artery.

Superficial Veins.—The superficial epigastric and superficial circumflex iliac veins empty into the long saphenous (*great saphenous*) vein; those accompanying the cutaneous twigs of the intercostal, deep (*inferior*) epigastric, and superior epigastric arteries empty into the veins accompanying the arteries from which they arise.

The numerous superficial veins upon the front of the abdomen are only distinct when they are varicose or when the return circulation is obstructed. A lateral vein extending from the axilla to the groin and connecting the axillary and femoral veins may be rendered prominent. The surface abdominal vessels may or may not act as collateral blood channels in obstruction of the inferior vena cava. Clinical experience shows that these veins may also be enormously varicosed even when the return circulation through the inferior vena cava is not disturbed. It has been shown, moreover, that the valves of these vessels are so arranged that the blood in the surface veins above the umbilicus passes to the axilla, while that in the surface veins below the umbilicus passes to the groin. Small veins connecting the portal vein with the epigastric veins at the umbilicus are sometimes described.

The **superior set of inguinal lymph glands** is situated between the two layers of the superficial fascia, over the line of Poupart's (*inguinal*) ligament. The glands are four or five in number. They receive the superficial lymphatics from the lower part of the abdominal wall, the anterior part of the urethra, and from the integument of the perineum, anus, and gluteal regions in both sexes. In the male they also receive the lymphatics from the integument of the penis and scrotum, and in the female from the lower part of the vagina and the integument of the clitoris and labia. The **inferior set of inguinal lymph glands** is situated around the saphenous opening (*fossa ovalis*).

The **superficial lymphatic vessels** of the abdominal wall accompany the superficial blood-vessels, those above the umbilicus going to the axillary glands, and those below to the superior set of inguinal glands.

The **cutaneous nerves** seen in the superficial fascia of the abdominal wall are the lateral and the anterior cutaneous branches of the lower five or six intercostal nerves, and branches of the ilio-hypogastric and ilio-inguinal nerves.

The **lateral cutaneous nerves** emerge between the digitations of the external oblique muscle, in a line with the corresponding nerves found at the side of the upper part of the chest, the lower nerves emerging more posteriorly. They are accompanied by branches of the intercostal arteries. They divide into anterior and posterior branches. The *anterior branches* extend far forward, almost to the lateral margin of the rectus muscle, and are distributed to the overlying integument and the digitations of the external oblique muscle. The *posterior branches* are distributed to the skin over the latissimus dorsi muscle, where they inosculate with the dorsal cutaneous nerves. The lateral cutaneous, or iliac, branch of the last dorsal nerve is the largest, and, unlike the others, does not divide; it pierces both the internal and the external oblique muscles, and passes downward over the crest of the ilium, in front of the iliac (*lateral cutaneous*) branch of the ilio-hypogastric nerve, to supply the integument of the buttock and of the front of the hip, some of its filaments extending as low as the greater trochanter.

The **anterior cutaneous nerves** are the terminal branches of the intercostal nerves, and are smaller, less numerous, and less regularly situated than the lateral cutaneous nerves. They pierce the sheath of the rectus muscle, and supply the integument of the front of the abdomen. They are accompanied by the anterior cutaneous branches of the intercostal arteries.

In Pott's disease of the vertebræ the pain may be referred to the front of the abdomen, along the lower intercostal nerves.

The **hypogastric (anterior cutaneous) branch of the ilio-hypogastric nerve** enters the superficial fascia above and somewhat medial to the external abdominal (*subcutaneous inguinal*) ring. Contrary to general opinion, it is entirely a sensory nerve and has no part in the innervation of the internal oblique.

The **ilio-inguinal nerve,** a branch of the first lumbar nerve, enters the superficial fascia at the external abdominal (*subcutaneous inguinal*) ring, through which it emerges from the inguinal canal to supply the integument of the upper and medial part of the thigh and of the scrotum or the labia.

Dissection.—The superficial fascia should be reflected downward in one large flap. The deep fascia covering the external oblique muscle and the aponeurosis of the muscle will thus be exposed. While reflecting the superficial fascia, the cutaneous vessels and nerves previously described should be traced. Before removing the deep fascia, notice that the dartos of the penis and scrotum is continuous with the superficial fascia of the abdominal wall.

PLATE CCCLXXV.

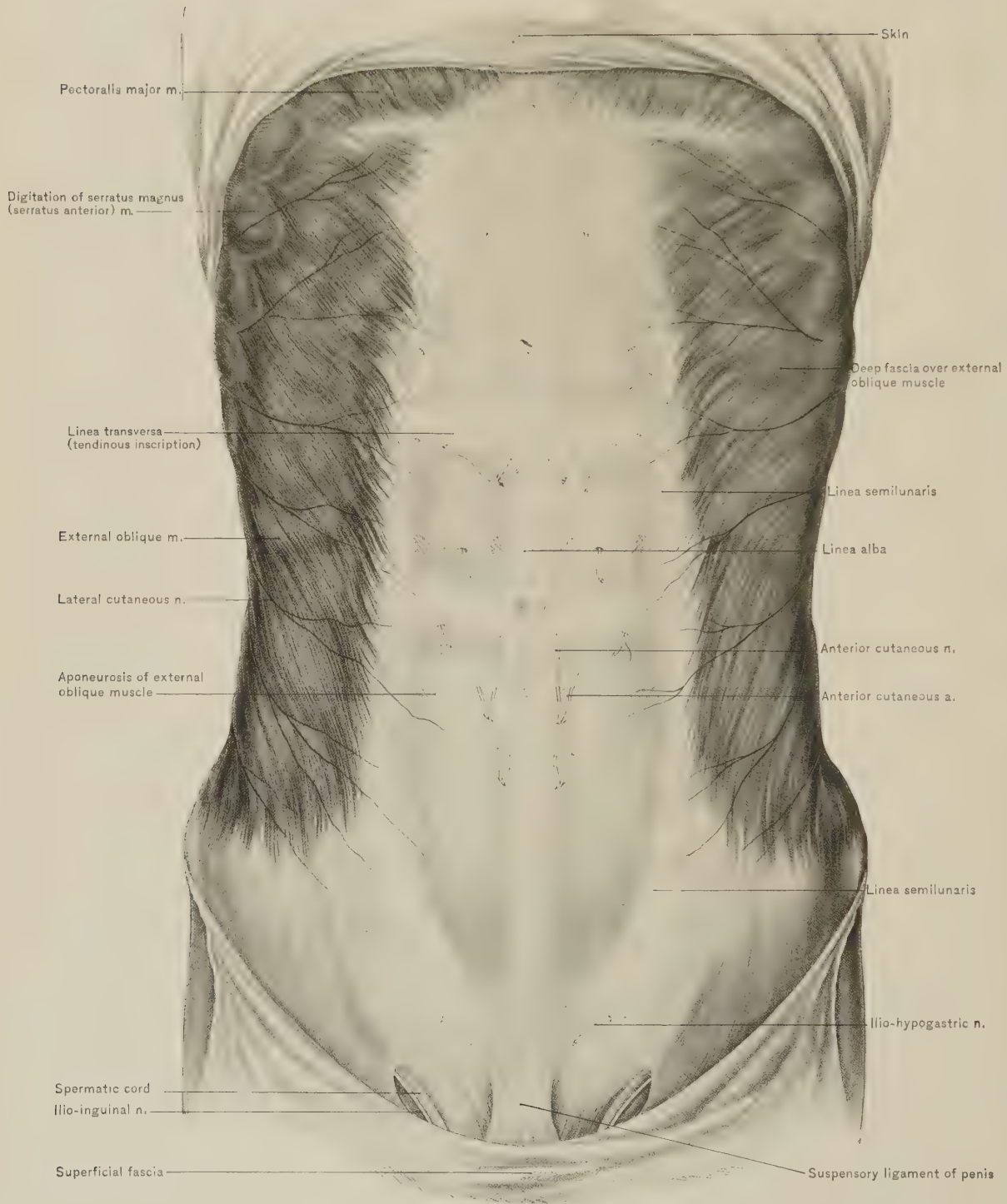

DEEP FASCIA, CUTANEOUS NERVES, EXTERNAL OBLIQUE MUSCLE AND ITS APONEUROSIS.

PLATE CCCLXXVI.

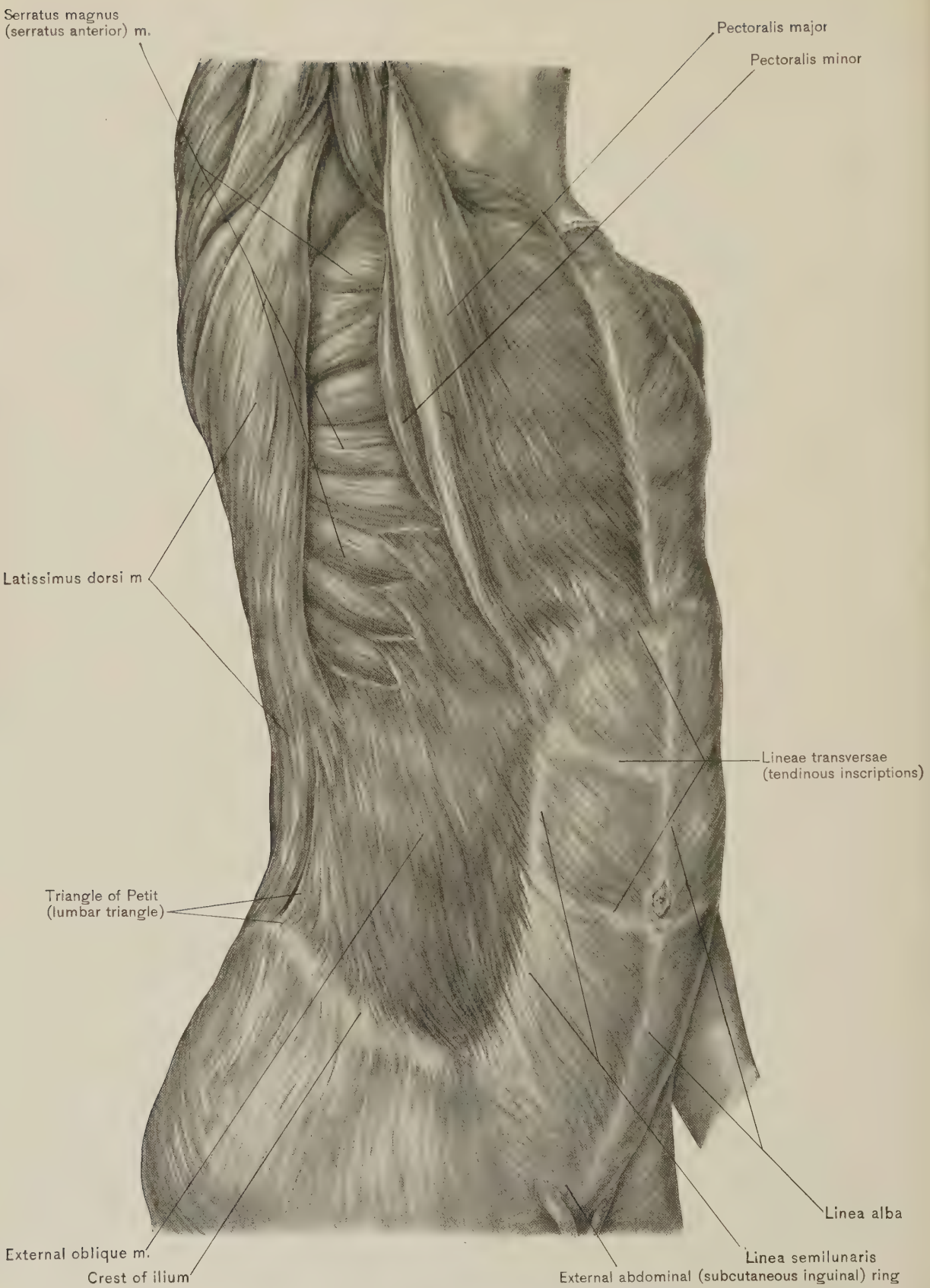

EXTERNAL OBLIQUE AND LATISSIMUS DORSI MUSCLES, AND TRIANGLE OF PETIT (LUMBAR TRIANGLE).

The **deep fascia of the abdominal wall** (Plate CCCLXXV) covers the external oblique muscle, and is a thin sheet of fascia readily demonstrable over the fleshy portion of the muscle, but intimately blended with the aponeurosis of the external oblique. This fascia is pierced by the lateral cutaneous nerves and their accompanying blood-vessels. It is continuous with the deep fascia of the chest, back, and thighs, and with that over the gluteal muscles.

Dissection.—The deep fascia should be reflected posteroanteriorly, cutting across or at right angles to the line of the muscle fibers.

The **external oblique muscle** (Plate CCCLXXVI) *arises* from the lateral and lower surface of the lower seven ribs by seven or eight fleshy digitations. The upper five serrations interdigitate with corresponding processes of the serratus magnus (*serratus anterior*); the lower three, with similar processes of the latissimus dorsi muscle. From this origin the fibers arising high up pass downward and forward, to terminate in the aponeurosis; those arising lower pass almost vertically downward, to be inserted into the anterior half of the lateral lip of the crest of the ilium. The upper half of the posterior free border of the muscle is overlapped by the latissimus dorsi. The muscle is *inserted* by muscle fibers into the anterior half of the lateral lip of the crest of the ilium and by aponeurotic fibers into the anterior superior spine of the ilium, the deep fascia of the thigh, the spine (*tubercle*) of the pubis, the front of the body of the pubis, the symphysis pubis, and the linea alba.

Blood Supply.—From the lower intercostal arteries and the deep circumflex iliac artery.

Nerve Supply.—From the lower intercostal and the ilio-inguinal nerves.

Action.—The function of the external oblique muscle is to aid in micturition, defecation, parturition, and expiration. Acting together, the two muscles flex the pelvis on the thorax, or vice versa; separately, each acts as a lateral flexor of the thorax on the pelvis, and also rotates the thorax on the pelvis, turning the thorax and the upper part of the body toward the opposite side.

Dissection.—Before taking up the study of the aponeurosis of the external oblique muscle, the body should be turned slightly on the side opposite to that upon which the dissection is being made. Dissecting the skin and fasciæ backward for a short distance will expose a triangular intermuscular interval, the triangle of Petit (*lumbar triangle*), situated immediately above the middle of the crest of the ilium.

The **triangle of Petit** (**lumbar triangle**) is bounded below by the crest of the ilium, in front by the external oblique muscle, and behind by the latissimus dorsi muscle. In many instances, especially in very muscular bodies, this interval does not appear as a triangle on account of the overlapping of the external oblique and

latissimus dorsi muscles. It is important surgically because it is a weak place and one at which a lumbar hernia or lumbar abscess bulges.

The **aponeurosis of the external oblique muscle** covers the abdomen anteriorly, extending from the chest, where it is continuous with the origin of the pectoralis major muscle, to the pelvis. Laterally, it extends to a line drawn from the end of the cartilage of the ninth rib to a point about four centimeters (one and one-half inches) medial to the anterior superior spine of the ilium.

At the lower part of the abdomen it is broader, thicker, and, therefore, stronger, than it is above, greater strength being required at the lower part of the abdominal wall, where it supports the abdominal viscera.

The upper portion of the aponeurosis carries the lymphatics from the medial inferior portion of the breast on their way toward the umbilicus. The aponeurosis contains a number of small openings for the passage of cutaneous nerves and vessels, and a larger and more important opening, the external abdominal (*subcutaneous inguinal*) ring. In the fetus the umbilicus is an opening which pierces the aponeuroses of the two external oblique muscles, and of the internal oblique and transversalis (*transversus abdominis*) muscles, and the transversalis fascia.

The **external abdominal (subcutaneous inguinal) ring** (Plate CCCLXXVII) is situated in the lower part of the aponeurosis of the external oblique muscle, immediately above and slightly to the lateral side of the spine of the pubis. It is somewhat triangular in shape, and is formed by the divergence of the fibers of the aponeurosis. The base of this triangular opening is at the pubic crest, the apex being directed obliquely upward and lateralward. Its longest diameter measures about two centimeters (three-fourths of an inch). The diverging fibers of the aponeurosis forming the lateral boundaries of the opening constitute its **crura,** or **pillars,** of which there are two, the inferior, or external, and the superior, or internal. The **external pillar,** or **inferior crus,** blends with the medial end of Poupart's (*inguinal*) ligament, and is attached to the spine (*tubercle*) of the pubis. The spermatic cord, or the round ligament of the uterus rests upon it. The **internal pillar,** or **superior crus,** is attached to the front of the body and symphysis of the pubis.

The external abdominal (*subcutaneous inguinal*) ring gives passage, in the male, to the spermatic cord, the ilio-inguinal nerve, and the genital (*external spermatic*) branch of the genito-crural (*genito-femoral*) nerve; in the female, to the round ligament of the uterus, the ilio-inguinal nerve, and the genital (*external spermatic*) branch of the genito-crural (*genito-femoral*) nerve.

The external abdominal (*subcutaneous inguinal*) ring is readily felt by invaginating the scrotum over the end of the finger, and carrying it to the spine (*tubercle*) of the pubis, where it can be made to engage in the opening, which, in

PLATE CCCLXXVII.

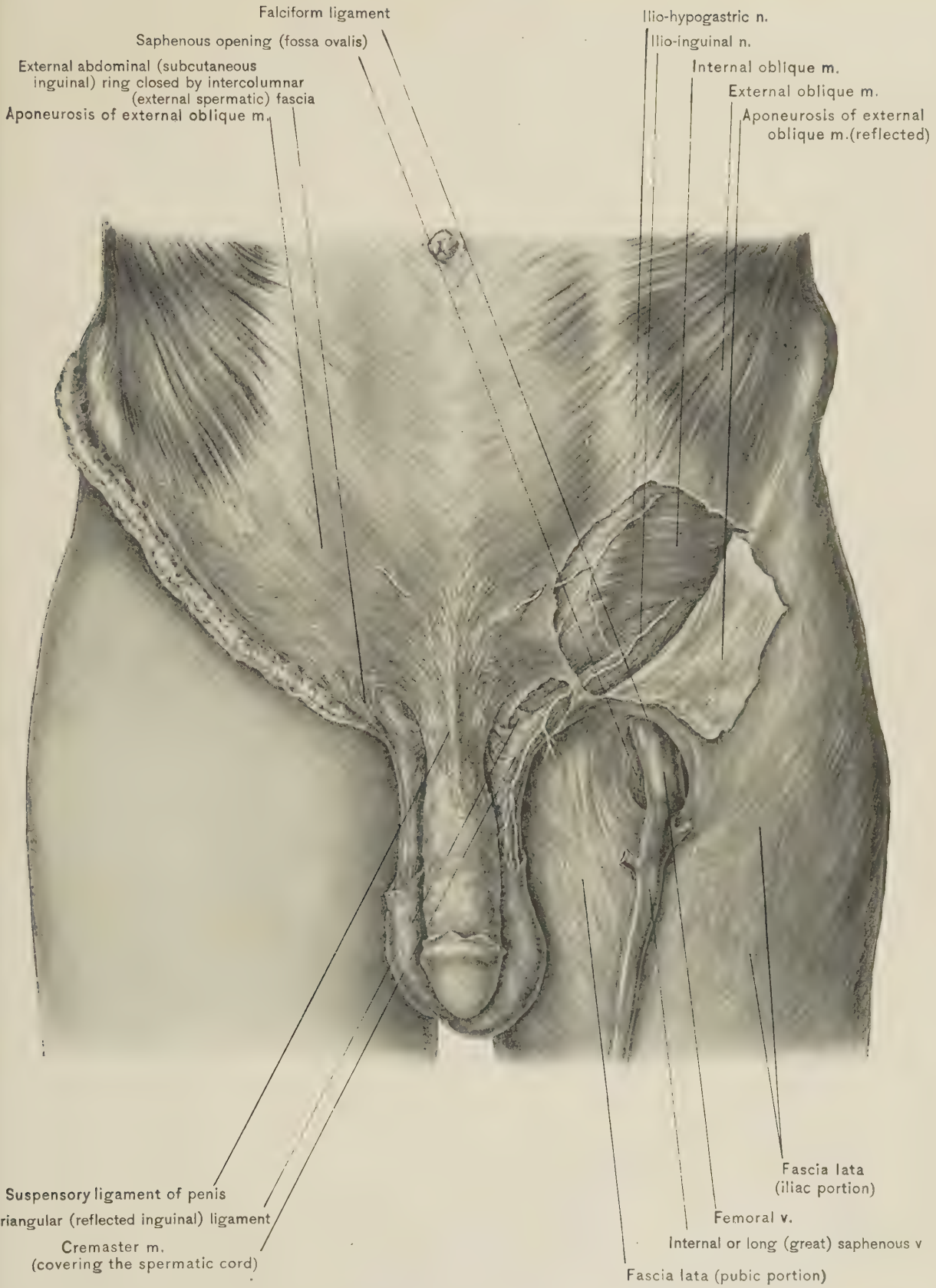
Falciform ligament
Saphenous opening (fossa ovalis)
External abdominal (subcutaneous inguinal) ring closed by intercolumnar (external spermatic) fascia
Aponeurosis of external oblique m.
Ilio-hypogastric n.
Ilio-inguinal n.
Internal oblique m.
External oblique m.
Aponeurosis of external oblique m.(reflected)
Suspensory ligament of penis
Triangular (reflected inguinal) ligament
Cremaster m. (covering the spermatic cord)
Fascia lata (iliac portion)
Femoral v.
Internal or long (great) saphenous v
Fascia lata (pubic portion)

EXTERNAL ABDOMINAL (SUBCUTANEOUS INGUINAL) RING, INTERCOLUMNAR (EXTERNAL SPERMATIC) FASCIA, SPERMATIC CORD, AND ILIO-INGUINAL NERVE.

the average subject, will admit the tip of the index-finger. When there is doubt as to the presence of a small inguinal hernia, the diagnosis is materially assisted by engaging the tip of the finger first in the external abdominal (*subcutaneous inguinal*) ring of the side supposed to be affected, and then in the ring of the opposite side, and noting the impulse received when the patient coughs. The impulse is more pronounced while the patient is in the erect posture.

The **intercolumnar, or external spermatic, fascia** stretches across and closes the external abdominal (*subcutaneous inguinal*) ring, to the pillars of which it is attached. It is a continuation of the deep fascia which overlies the external oblique muscle, and is adherent to the aponeurosis of that muscle. The external abdominal (*subcutaneous inguinal*) ring forms the outlet of the inguinal canal; therefore, anything which passes out of the canal through its external opening must have for one of its coverings the intercolumnar, or external spermatic, fascia.

Derivatives of the External Oblique Muscle.—The aponeurosis of the external oblique muscle assists in forming the linea alba, and forms three ligaments: Poupart's (*inguinal*), Gimbernat's (*ligamentum lacunare*), and the reflected inguinal ligament, or triangular ligament, of the abdominal wall.

The **linea alba** extends from the ensiform (*xiphoid*) cartilage to the symphysis pubis, and is wider above than below. It is the band of fibrous tissue which is situated between the rectus abdominis muscles, and is formed by the union of the aponeuroses of the flat muscles of the two sides of the abdominal wall by interlacement of their fibers. The linea alba is often chosen as the site of the incisions in abdominal operations because of its thinness and the absence of blood vessels.

The width of the linea alba is increased by distention of the abdominal cavity by tumors, gas, or fluid.

Protrusion of a mass of preperitoneal fat (hernia adiposa) may occur through a hole in the aponeurosis at the linea alba; or a true epigastric hernia may occur in the median line. The latter may cause digestive disturbances by dragging on the stomach, thus simulating gastric or duodenal ulcer.

The **fibrous ring of the umbilicus** is situated in the blended aponeuroses of the linea alba, at or immediately below the center of that line. It is formed by the fibers of the aponeuroses, and is filled with cicatricial tissue which contains the remains of the two hypogastric (*umbilical*) arteries, the umbilical vein, the vitello-intestinal duct, and the allantoic duct. The cord-like remains of these structures diverge as they leave the umbilicus, the round ligament of the liver, or the remains of the umbilical vein, passing upward, and the urachus, or the remains of the allantoic duct, and the remains of the hypogastric (*umbilical*) arteries passing downward.

The tension produced by the urachus depresses the scar downward and backward, thus attenuating the cicatricial tissue in the upper part of the ring; consequently herniæ more frequently protrude at the upper part of the ring.

Poupart's (inguinal) ligament (the crural, or femoral, arch) (Plate CCCLXXVIII) is the lower border of that portion of the aponeurosis of the external oblique muscle which extends between the anterior superior spine of the ilium and the spine (*tubercle*) of the pubis. It crosses over the psoas and iliacus muscles, the external cutaneous, the anterior crural (*femoral*), the crural (*lumbo-inguinal*) branch of the genito-crural (*genito-femoral*), and the accessory obturator nerves, and the femoral vessels. The ligament is slightly curved, with the convexity downward. Continuous with its lower border is the fascia lata of the thigh. Since this ligament results from thickening of the lowest fibers of the aponeurosis of the external oblique, and as the internal oblique and transversalis (*transversus abdominis*) arise from its lateral half, and since the ligament is continuous with the fascia lata of the thigh, extension of the thigh on the trunk results in increased tension of the abdominal wall. The attachment of the fascia lata to Poupart's (*inguinal*) ligament is also important when attempting to reduce either an inguinal or a femoral hernia by flexing the leg on the thigh and the thigh on the abdomen, and adducting the entire limb. By this manipulation the fascia lata and the ligament are rendered lax, thus placing the hernial orifice in the most favorable condition for the reduction of the protrusion. The ligament is more pronounced in men than in women, but in both it is the dividing line between the iliac and the inguinal regions. The lateral half of the ligament gives partial origin to the internal oblique muscle, and the lateral third to the transversalis (*transversus abdominis*) muscle. It is firmly united with the subjacent transversalis and iliac fasciæ.

Gimbernat's ligament (**ligamentum lacunare**) is that portion of the aponeurosis of the external oblique muscle attached to the ilio-pectineal line for about two centimeters (three-quarters of an inch) lateral to the spine of the pubis, and is, therefore, a reflection of Poupart's (*inguinal*) ligament. It is triangular in shape, with its base concave, free, and directed lateralward, forming the medial boundary of the femoral ring.

The **triangular ligament of the abdominal wall** (**reflected inguinal ligament**) is a small extension of the aponeurosis of the external oblique. As the name indicates, it is triangular in shape, the apex of the triangle corresponding to its point of origin, and the base to its point of insertion at the linea alba. It is reflected superomedially from the medial portions of Poupart's (*inguinal*) ligament and Gimbernat's ligament (*ligamentum lacunare*). It passes upward in front of the inferomedial portions of the aponeuroses of the internal

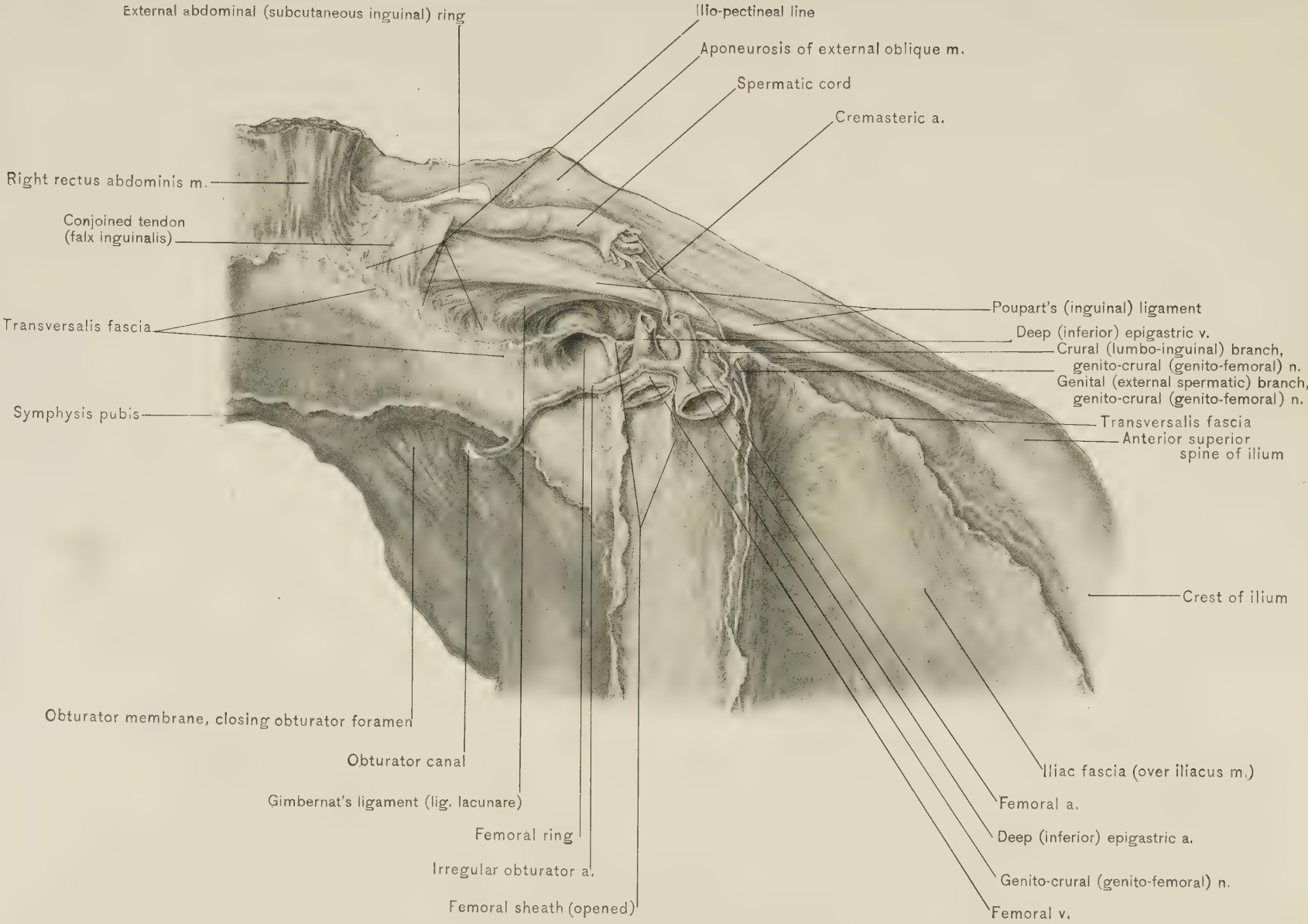

PLATE CCCLXXVIII.

PLATE CCCLXXIX.

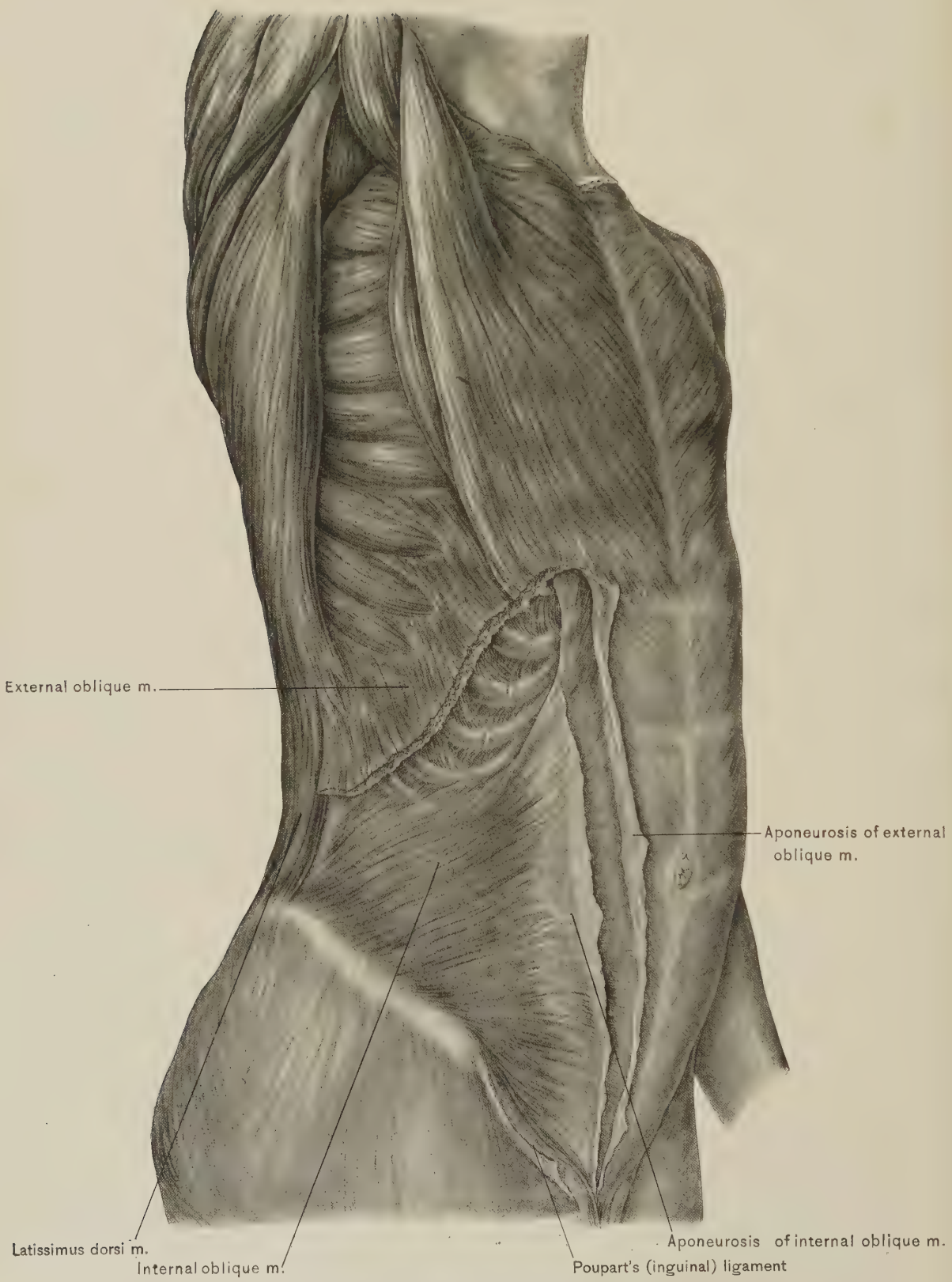

INTERNAL OBLIQUE MUSCLE.

oblique and transversalis (conjoined tendon) to the anterior layer of the rectus sheath.

Dissection.—The external oblique muscle on one side should now be reflected forward. Detach it from the ribs by cutting through the muscle in front of the origins of the serrations. Divide the muscle just above the crest of the ilium, and the aponeurosis above and along Poupart's (*inguinal*) ligament, almost to the inferior crus, or external pillar, of the external abdominal (*subcutaneous inguinal*) ring. Above the crest of the ilium the interval between the external and internal oblique muscles can be recognized by a layer of fascia. The muscle should then be carefully separated from the subjacent tissue and displaced medially, exposing a distinct layer of fascia covering the internal oblique muscle, some nerves, and the space immediately above the medial half of Poupart's (*inguinal*) ligament, the inguinal canal. The spermatic cord, which lies in the inguinal canal, is seen to be partly covered by the cremaster muscle. The layer of fascia should next be removed carefully, postero-anteriorly, thus exposing the internal oblique muscle, the hypogastric (*anterior cutaneous*) branch of the ilio-hypogastric nerve, and the ilio-inguinal nerve. The hypogastric (*anterior cutaneous*) branch of the ilio-hypogastric nerve pierces the aponeurosis of the external oblique muscle, and the ilio-inguinal nerve passes into the inguinal canal and runs anterior to the spermatic cord in the male, and the round ligament of the uterus in the female.

The **interabdominal fasciæ,** so named from their position between the abdominal muscles, are two in number. The more superficial one is situated between the external and the internal oblique muscles, while the deeper one lies between the internal oblique and the transversalis (*transversus abdominis*) muscles. These fasciæ are guides to the dissector in reflecting the external and internal oblique muscles, and also to the surgeon in operating through the muscles of the abdominal wall.

The **internal oblique muscle** (Plate CCCLXXIX) *arises* from the lateral half of Poupart's (*inguinal*) ligament, from the anterior two-thirds of the middle lip (*intermediate line*) of the crest of the ilium, and from the posterior lamella of the lumbar fascia.

The fibers arising from the lateral half of Poupart's (*inguinal*) ligament pass downward and medialward, to terminate in the conjoined tendon (*falx inguinalis*) with similar fibers of the transversalis muscle. These lower or **arching fibers of the internal oblique and transversalis** (**transversus abdominis**) **muscles** are *inserted,* by means of the **conjoined tendon** (**falx inguinalis**) into the crest of the pubis, and for a short distance into the ilio-pectineal line and Poupart's (*inguinal*) ligament. The conjoined tendon (*falx inguinalis*) is directly posterior to the external abdominal (*subcutaneous inguinal*) ring and the triangular ligament of

the abdominal wall (*reflected inguinal ligament*). At the point where the internal oblique muscle arises from Poupart's (*inguinal*) ligament it gives off, from its lower border, a detachment of fibers which passes downward with the spermatic cord and is called the **cremaster muscle.**

The fibers of the internal oblique arising from the anterior part of the middle lip (*intermediate line*) of the crest of the ilium pass upward and medially, terminating in the aponeurosis of the muscle. The fibers arising from the posterior part of the middle lip (*intermediate line*) of the crest of the ilium and the lumbar fascia pass almost directly upward, to be attached to the cartilages of the lower four ribs, blending with the internal intercostal muscles of the lower three intercostal spaces.

The **aponeurosis of the internal oblique muscle** extends from the chest to the pubis, being wider above than below. Along the lateral border of the rectus muscle the aponeurosis, throughout its upper three-fourths, divides into two layers, one of which passes anterior and the other posterior to the rectus muscle, to join the aponeuroses of the external oblique and transversalis muscles and the corresponding layers of the aponeuroses of the opposite side at the linea alba. The anterior layer merges into the aponeurosis of the external oblique muscle. The line of junction of the aponeuroses of the external oblique and the internal oblique muscles is along the lateral margin of the rectus muscle, at the upper part of the abdominal wall; but below the umbilicus the line of junction is anterior to the rectus muscle and approaches the linea alba, thus forming two layers in the lower part of the anterior wall of the sheath of the rectus muscle. The posterior lamella of the aponeurosis of the internal oblique muscle blends with that of the transversalis muscle. Thus is formed the upper three-fourths of the **sheath of the rectus muscle** (Plate CCCLXXX). The sheath is described as being incomplete posteriorly at its lower fourth, where almost all the fibers of the aponeuroses of the internal oblique and transversalis muscles pass anterior to the rectus, a few aponeurotic fibers passing behind the muscle. It must be clearly understood that the lower fourth of the posterior wall of the sheath of the rectus muscle is adherent to the transversalis fascia, and is so thin that this portion of the sheath may be considered absent. The lower border of the thicker portion of the posterior wall of the sheath of the rectus is concave, and receives the name **semilunar fold of Douglas** (**linea semicircularis**). This fold marks the point at which the deep (*inferior*) epigastric artery enters the substance of the rectus muscle.

Blood Supply.—From the superior epigastric, deep (*inferior*) epigastric, deep circumflex iliac, and lower intercostal arteries.

Nerve Supply.—From the lower four intercostal nerves, and the ilioinguinal nerve.

PLATE CCCLXXX.

TRANSVERSE SECTIONS OF ABDOMINAL WALL AND SHEATH OF RECTUS ABDOMINIS MUSCLE.

Action.—The internal oblique muscle renders the abdominal wall tense, depresses the lower ribs, and compresses the viscera, assisting in defecation, micturition, parturition, and expiration.

Contraction of one muscle alone tends to rotate the chest to that side and to flex the thorax laterally. Acting from its insertion, it will flex the pelvis laterally and rotate it to the opposite side.

The **cremaster muscle** passes along the spermatic cord, through the inguinal canal and the external abdominal (*subcutaneous inguinal*) ring into the scrotum. It reaches the portion of the internal spermatic fascia which covers the tunica vaginalis, and turns upward to be *inserted* into the spine (*tubercle*) and crest of the pubis, and the anterior layer of the sheath of the rectus. The arrangement of the bundles of fibers of the muscle in the scrotum is in a series of loops united by connective tissue, known as the **cremasteric fascia.** The size of the cremaster muscle depends upon the size of the testicle. The cremaster muscle is poorly developed in the female.

Blood Supply.—From the cremaster branch of the deep (*inferior*) epigastric artery.

Nerve Supply.—From the genital (*external spermatic*) branch of the genito-crural (*genito-femoral*) nerve.

Action.—To support and elevate the testicle. Irritation of the skin of the upper and anterior part of the thigh at the area of distribution of the crural (*lumbo-inguinal*) branch of the genito-crural (*genito-femoral*) nerve will usually be followed by drawing up of the testicle of the same side. This is known as the **cremasteric reflex.**

Dissection.—The internal oblique muscle should next be reflected on one side by taking it up postero-anteriorly, first from the crest of the ilium, by making an incision parallel with, and a short distance above the latter bone. This exposes the deep circumflex iliac artery and veins and the deep interabdominal fascia between the internal oblique and transversalis muscles, which are important landmarks in the separation of these muscles, as well as portions of the lower intercostal, ilio-inguinal, and ilio-hypogastric nerves. The part of the muscle arising in common with the transversalis from the lumbar fascia should next be lifted, and lastly, that arising from the lateral half of Poupart's (*inguinal*) ligament. Note that the lower fibers of the internal oblique muscle form part of the anterior boundary of the superolateral portion of the inguinal canal. The muscle should be thrown forward and the deep interabdominal fascia removed, in order more fully to expose the lower intercostal nerves, the anterior branch of the last, or twelfth, thoracic nerve, the ilio-hypogastric and ilio-inguinal nerves, the deep circumflex iliac artery and veins, the transversalis muscle,

and the upper portion of the spermatic cord or round ligament of the uterus and of the inguinal canal.

The **lower six intercostal nerves,** or anterior branches of the lower six thoracic nerves, are known as abdominal intercostal nerves (Plates CCCLXXXI and CCCLXXXII), since they supply the abdominal as well as the thoracic wall. The seventh to the eleventh intercostal nerves run for a distance between the ribs, and then pass between the transversalis and internal oblique muscles. They pierce the posterior lamella of the aponeurosis of the internal oblique, to supply the rectus muscle, and finally pierce the anterior wall of the sheath of the rectus as the **anterior cutaneous nerves.** At about the middle of their course, at the side of the body, like the upper intercostal nerves, they give off **lateral cutaneous branches.** The anterior branch of the last, or twelfth, thoracic nerve is not an intercostal nerve because it runs below the last rib. It pierces the lumbar fascia near the origin of the transversalis muscle, and runs forward between the transversalis and internal oblique muscles. It gives off a lateral cutaneous branch, the **iliac branch,** which passes over the crest of the ilium to the gluteal region. The lower intercostal nerves supply the intercostal muscles, the levatores costarum, serratus posterior inferior, transversalis, internal oblique, external oblique, rectus, and pyramidalis muscles. Their lateral cutaneous branches supply the external oblique muscle. Their course in the belly-wall is in the direction of the ribs, the tenth intercostal nerve supplying the region of the umbilicus.

The **ilio-hypogastric and ilio-inguinal nerves** are branches of the first lumbar nerve. They pierce the transversalis muscle close to the crest of the ilium, and run forward along the crest of the ilium, between the transversalis and internal oblique muscles. The ilio-hypogastric nerve gives off an **iliac (lateral cutaneous) branch** which pierces the internal and external oblique muscles six to seven centimeters (two and a half to three inches) behind the anterior superior iliac spine, and runs obliquely forward, to supply the skin as low as the greater trochanter. The **hypogastric (anterior cutaneous) branch** is the continuation of the nerve. It pierces the internal oblique muscle on a level with the anterior superior spine of the ilium, runs medially, and pierces the aponeurosis of the external oblique above the external abdominal (*subcutaneous inguinal*) ring, supplying the skin in this region. The nerve has no motor fibers. The **ilio-inguinal nerve** pierces the internal oblique muscle below and to the medial side of the anterior superior iliac spine, runs downward and medially over the cremaster muscle, near and above Poupart's (*inguinal*) ligament, and passes through the external abdominal (*subcutaneous inguinal*) ring to supply the skin around it and the integument of the scrotum, or labium majus.

PLATE CCCLXXXI.

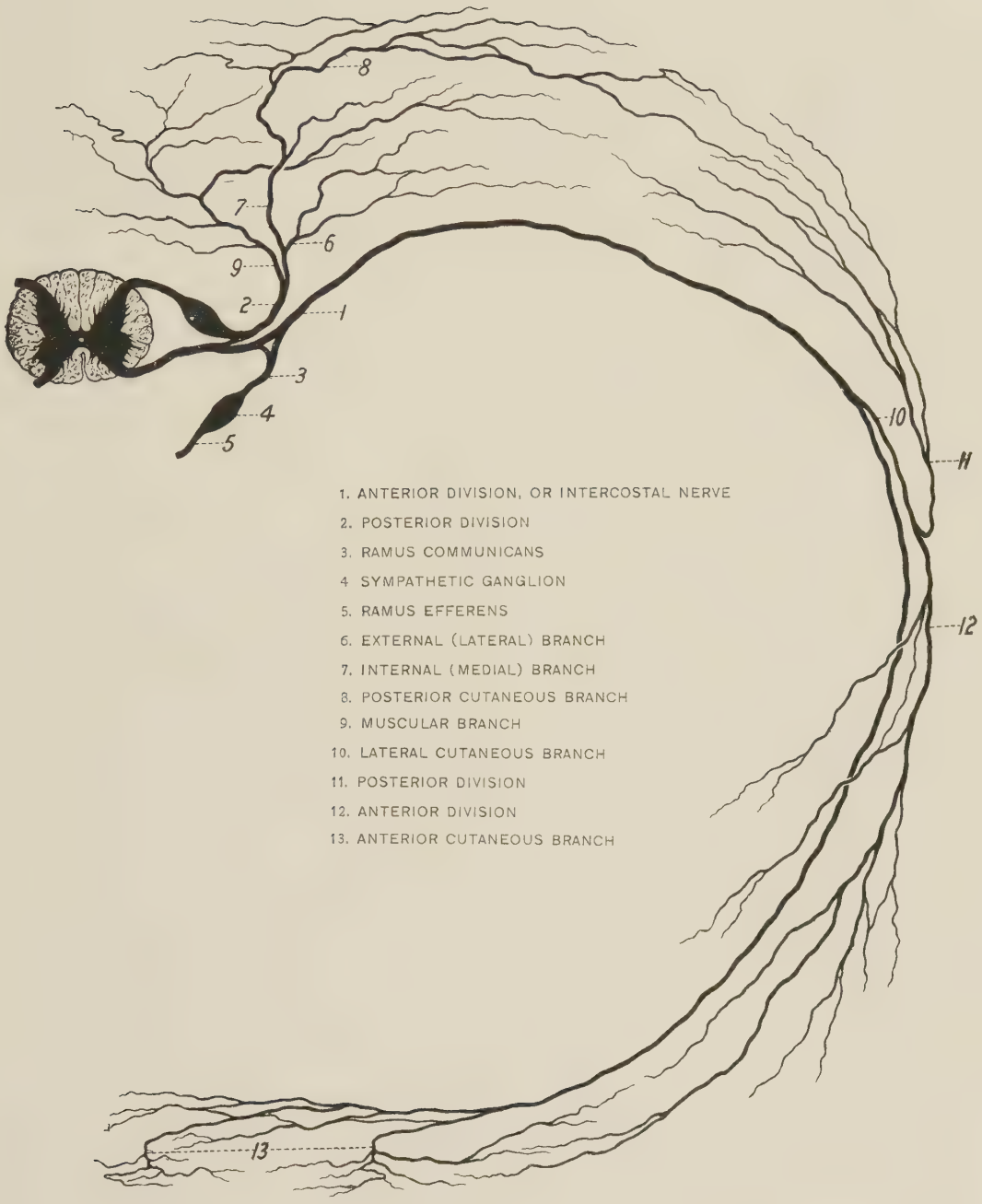

1. ANTERIOR DIVISION, OR INTERCOSTAL NERVE
2. POSTERIOR DIVISION
3. RAMUS COMMUNICANS
4. SYMPATHETIC GANGLION
5. RAMUS EFFERENS
6. EXTERNAL (LATERAL) BRANCH
7. INTERNAL (MEDIAL) BRANCH
8. POSTERIOR CUTANEOUS BRANCH
9. MUSCULAR BRANCH
10. LATERAL CUTANEOUS BRANCH
11. POSTERIOR DIVISION
12. ANTERIOR DIVISION
13. ANTERIOR CUTANEOUS BRANCH

DIAGRAM OF A LOWER INTERCOSTAL NERVE.

PLATE CCCLXXXII.

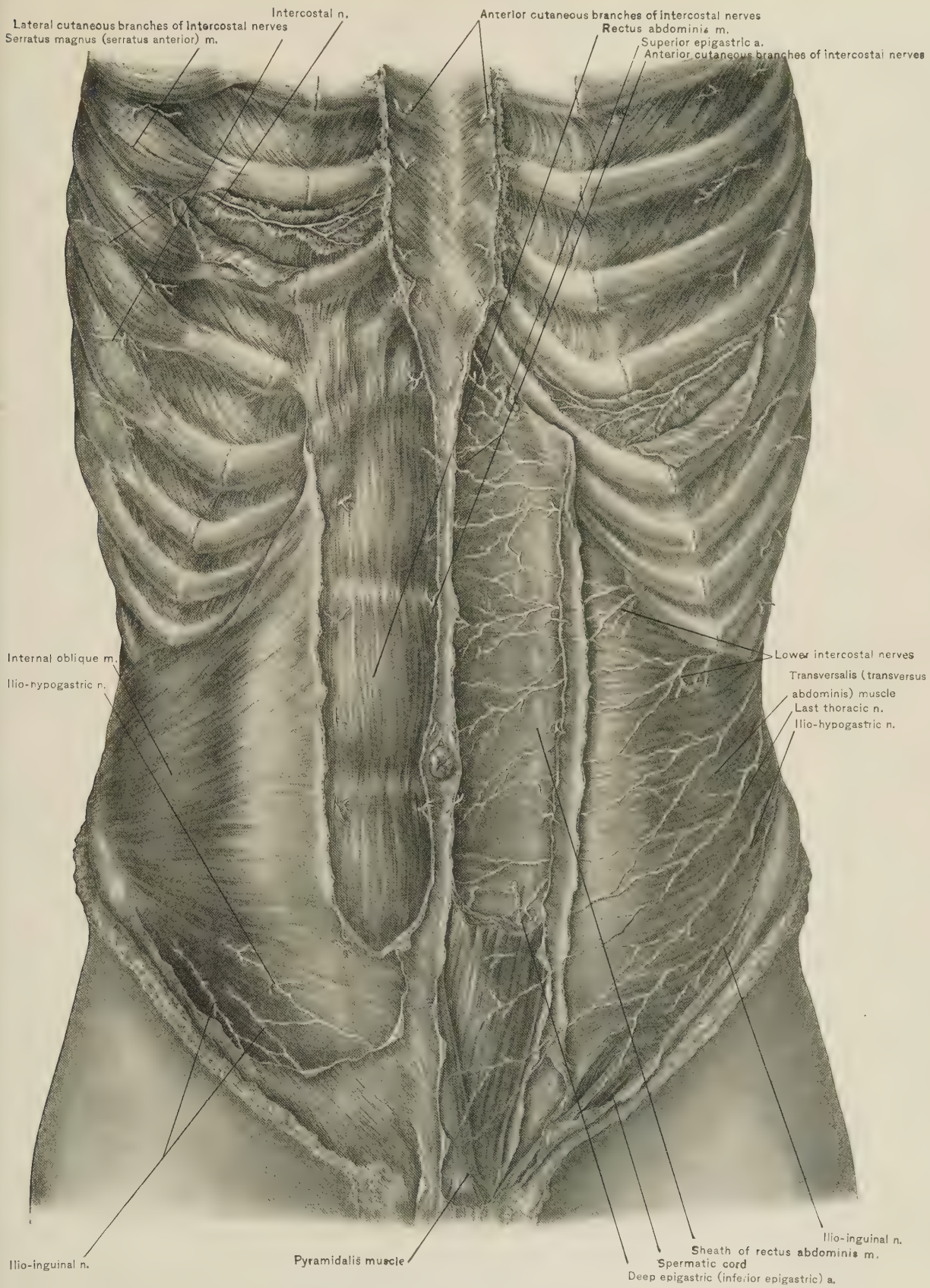

LOWER INTERCOSTAL NERVES, TRANSVERSALIS (TRANSVERSUS ABDOMINIS) AND RECTUS ABDOMINIS MUSCLES.

PLATE CCCLXXXIII.

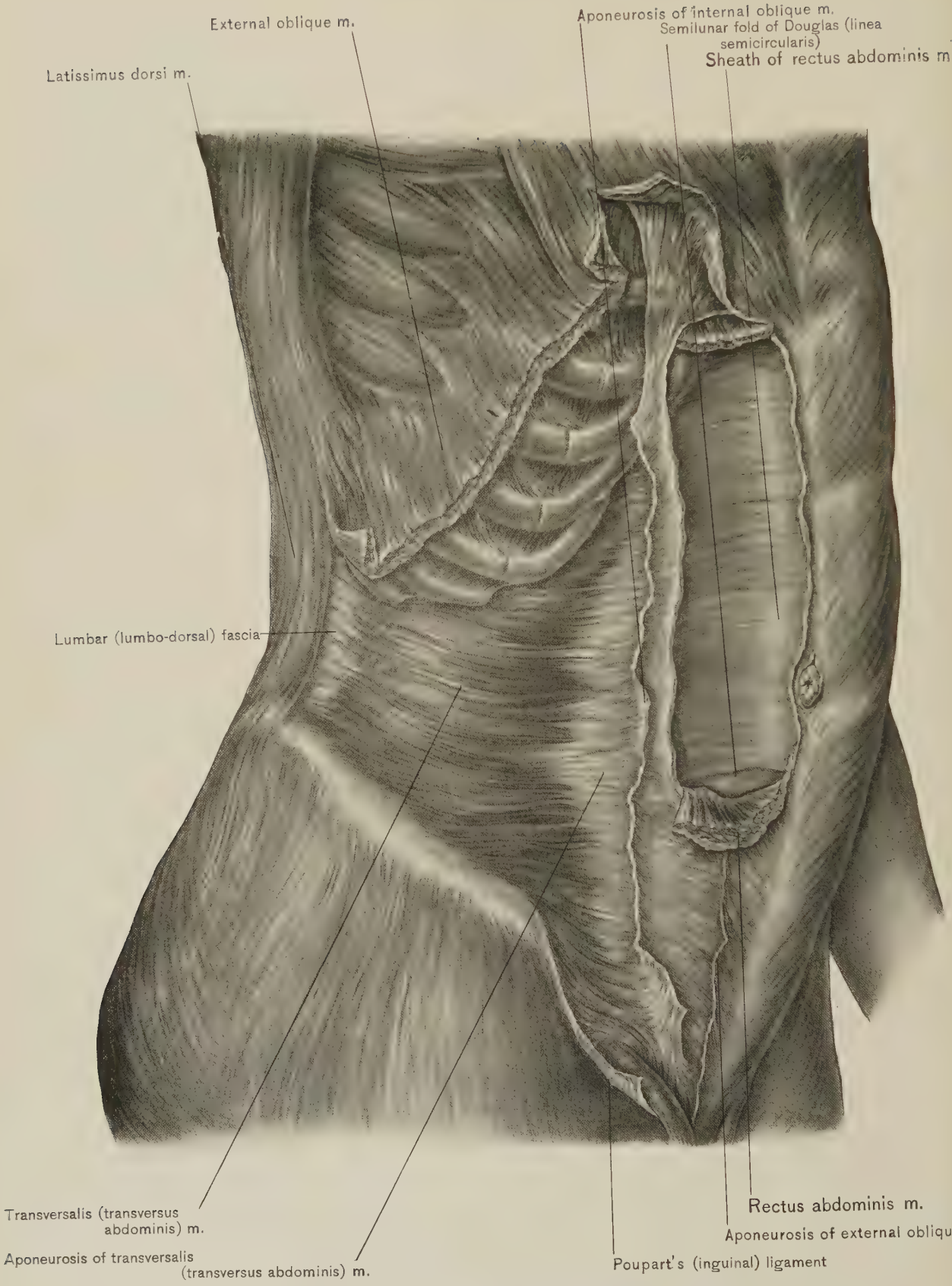
External oblique m.
Aponeurosis of internal oblique m.
Semilunar fold of Douglas (linea semicircularis)
Sheath of rectus abdominis m
Latissimus dorsi m.
Lumbar (lumbo-dorsal) fascia
Transversalis (transversus abdominis) m.
Aponeurosis of transversalis (transversus abdominis) m.
Rectus abdominis m.
Aponeurosis of external oblique m.
Poupart's (inguinal) ligament

TRANSVERSALIS (TRANSVERSUS ABDOMINIS) MUSCLE AND SHEATH OF RECTUS ABDOMINIS MUSCLE.

The **deep circumflex iliac artery** arises from the lateral side of the external iliac artery, about one-half centimeter above Poupart's (*inguinal*) ligament. It runs laterally under Poupart's (*inguinal*) ligament, in the subperitoneal fat, or between the peritoneum and the transversalis fascia, and along the line of junction of the iliac and transversalis fascia. Just medial to the anterior superior spine of the ilium it pierces the transversalis fascia and transversalis muscle, and runs laterally between the transversalis and internal oblique muscles just above, and parallel with the crest of the ilium. It gives off an ascending branch which passes upward between these muscles. It is accompanied by two veins, which unite into a single vein running across the external iliac artery and emptying into the external iliac vein. It anastomoses with the lower intercostal, the lumbar, ilio-lumbar, superficial circumflex iliac, and the superior gluteal arteries.

The **transversalis** (**transversus abdominis**) **muscle** (Plate CCCLXXXIII) *arises* from the lateral third of Poupart's (*inguinal*) ligament, the anterior two-thirds of the medial lip of the crest of the ilium, the lumbar fascia, and the inner surface of the lower six costal cartilages, interdigitating with the diaphragm. All the fibers of the transversalis muscle with the exception of those which arise from the lateral third of Poupart's (*inguinal*) ligament pass transversely medialward, terminating near the lateral border of the rectus muscle in an aponeurosis which is wider below than above, and widest in the center. The uppermost fibers of the muscle almost reach the linea alba before becoming aponeurotic. It is *inserted*, by means of an aponeurosis, into the linea alba, the crest of the pubis, and the ilio-pectineal line. In its upper three-fourths the aponeurosis, together with the posterior layer of the aponeurosis of the internal oblique, passes behind the rectus, while its lower fourth passes with the undivided portion of the aponeurosis of the internal oblique in front of the rectus, to join the aponeurosis of the transversalis of the opposite side along the midline, to be inserted into the linea alba. A stratum of aponeurotic fibers also passes behind the lower fourth of the rectus, but it is much thinner than the posterior wall of the upper three-fourths of the sheath, the sudden diminution in the thickenss of which produces the **semilunar fold of Douglas** (**linea semicircularis**). The fibers of the transversalis muscle arising from the lateral third of Poupart's (*inguinal*) ligament take a downward and medialward course, as do similar fibers of the internal oblique muscle, terminating with the latter in the conjoined tendon (*falx inguinalis*). These fibers, unlike those of the internal oblique arising from the lateral half of Poupart's (*inguinal*) ligament, do not normally form any part of the anterior boundary of the inguinal canal, but simply a part of the upper boundary. Occasionally the spermatic cord pierces the lower border of the transversalis

muscle; in these circumstances the transversalis muscle would enter into the anterior boundary of the canal.

The **conjoined tendon** (**falx inguinalis**) (Plates CCCLXXXVI and CCCLXXXVII), situated immediately behind the external abdominal (*subcutaneous inguinal*) ring, and anterior to the inferior part of the rectus muscle, is the common tendon of insertion of the fibers of the internal oblique and transversalis muscles arising from Poupart's (*inguinal*) ligament, thus forming the lower part of the common aponeurosis of these muscles. The aponeurosis of the transversalis muscle forms the greater part of the tendon, which is attached to the crest and tubercle of the pubis and the ilio-pectineal line. In closing the inguinal canal in the operation for the radical cure of inguinal hernia, the conjoined tendon (*falx inguinalis*), the internal oblique, the transversalis muscle, and the transversalis fascia are stitched to the shelving posterior border of Poupart's (*inguinal*) ligament. It may vary in its size and strength. Absence or weakness of this tendon is an important contributing factor in direct inguinal hernia.

Blood Supply.—From the deep (*inferior*) epigastric, superior epigastric, deep circumflex iliac, lumbar, and lower intercostal arteries.

Nerve Supply.—From the anterior primary branches of the lower intercostal nerves and the ilio-inguinal nerve.

Action.—The action of the transversalis (*transversus abdominis*) is to compress the contents of the abdomen, assisting in micturition, defecation, parturition, and expiration.

A collection of pus in the abdominal wall between two of these large flat muscles may burrow along the interabdominal fascia; vertically, it may work its way from the attachments of the muscles and fasciæ to the thorax, to the crest of the ilium and Poupart's (*inguinal*) ligament, and along the spermatic cord into the scrotum, and laterally, it may burrow in the anterior and lateral abdominal wall from about opposite the middle of the crest of the ilium, where the fasciæ spring from the lumbar fascia, to an irregular line just medial to the linea semilunaris, where the aponeuroses blend in the walls of the sheath of the rectus muscle. Hemorrhagic and emphysematous effusions take the same course.

The **difference in direction of the fibers of the three flat abdominal muscles** serves to strengthen the parietes of the abdomen. In some operations the incision through the muscles is made in the direction of the muscle fibers; an incision which transversely divides the fibers of one of these muscles will be more likely to be followed by weakening of the abdominal wall and a hernia than if the incision were made parallel with the fibers of the muscles. There is one notable exception to this, that is Kocher's incision for exposure of the gall-bladder.

PLATE CCCLXXXIV.

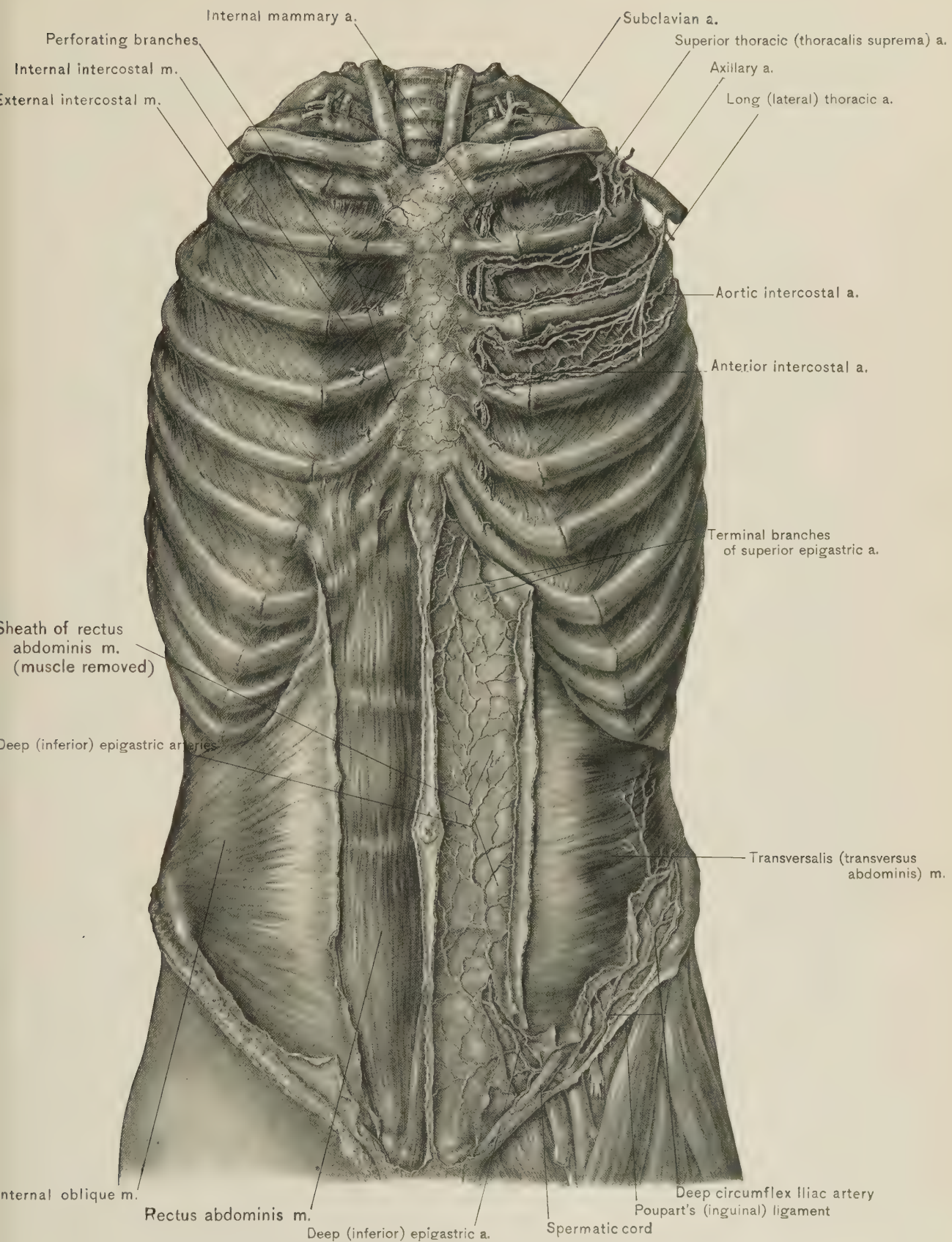

EPIGASTRIC AND DEEP CIRCUMFLEX ILIAC ARTERIES.

PLATE CCCLXXXV.

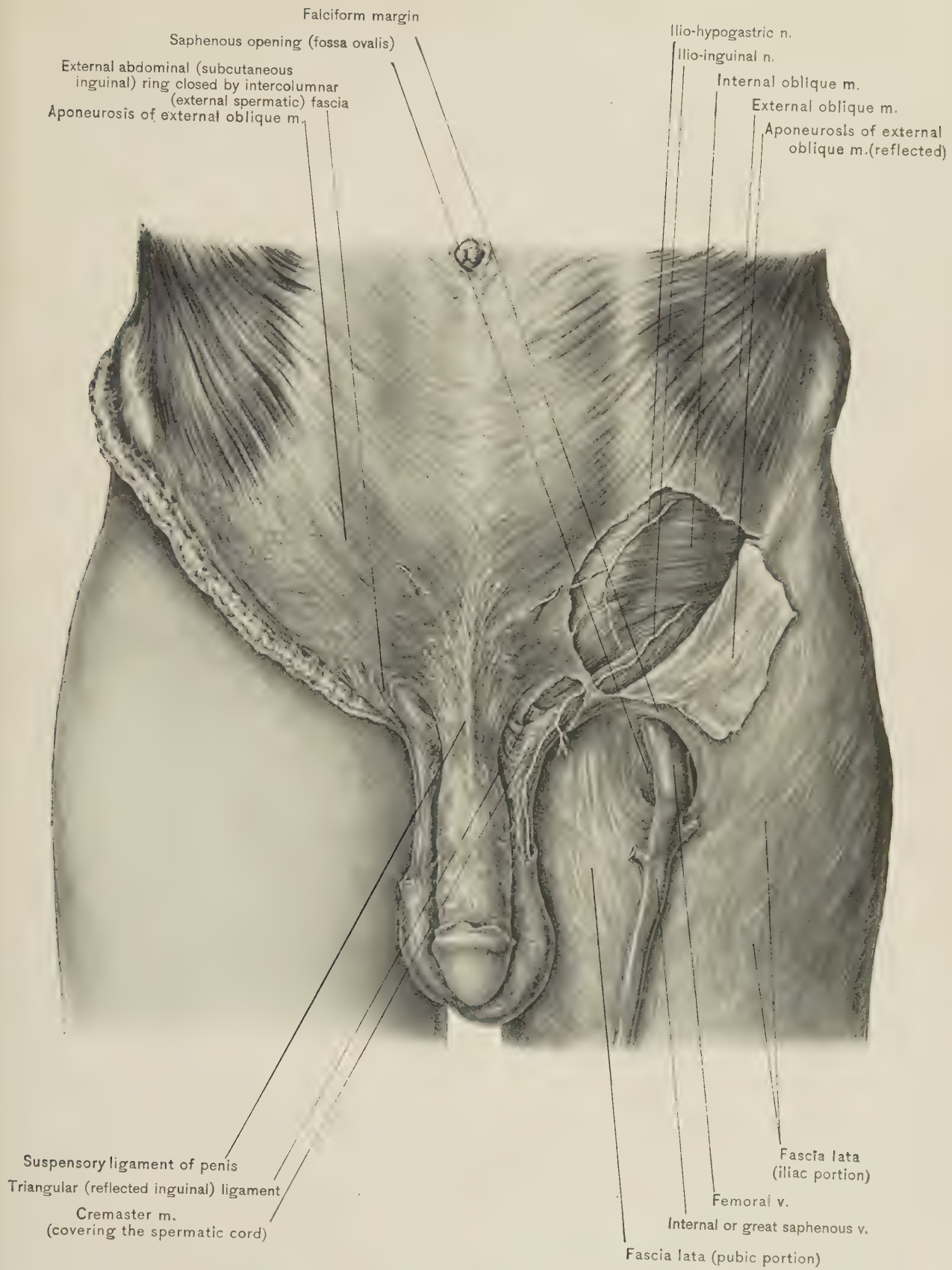
Falciform margin
Saphenous opening (fossa ovalis)
External abdominal (subcutaneous inguinal) ring closed by intercolumnar (external spermatic) fascia
Aponeurosis of external oblique m.
Ilio-hypogastric n.
Ilio-inguinal n.
Internal oblique m.
External oblique m.
Aponeurosis of external oblique m.(reflected)
Suspensory ligament of penis
Triangular (reflected inguinal) ligament
Cremaster m. (covering the spermatic cord)
Fascia lata (iliac portion)
Femoral v.
Internal or great saphenous v.
Fascia lata (pubic portion)

INGUINAL CANAL, CREMASTER MUSCLE, SPERMATIC CORD, AND ILIO-INGUINAL NERVE.

PLATE CCCLXXXVI.

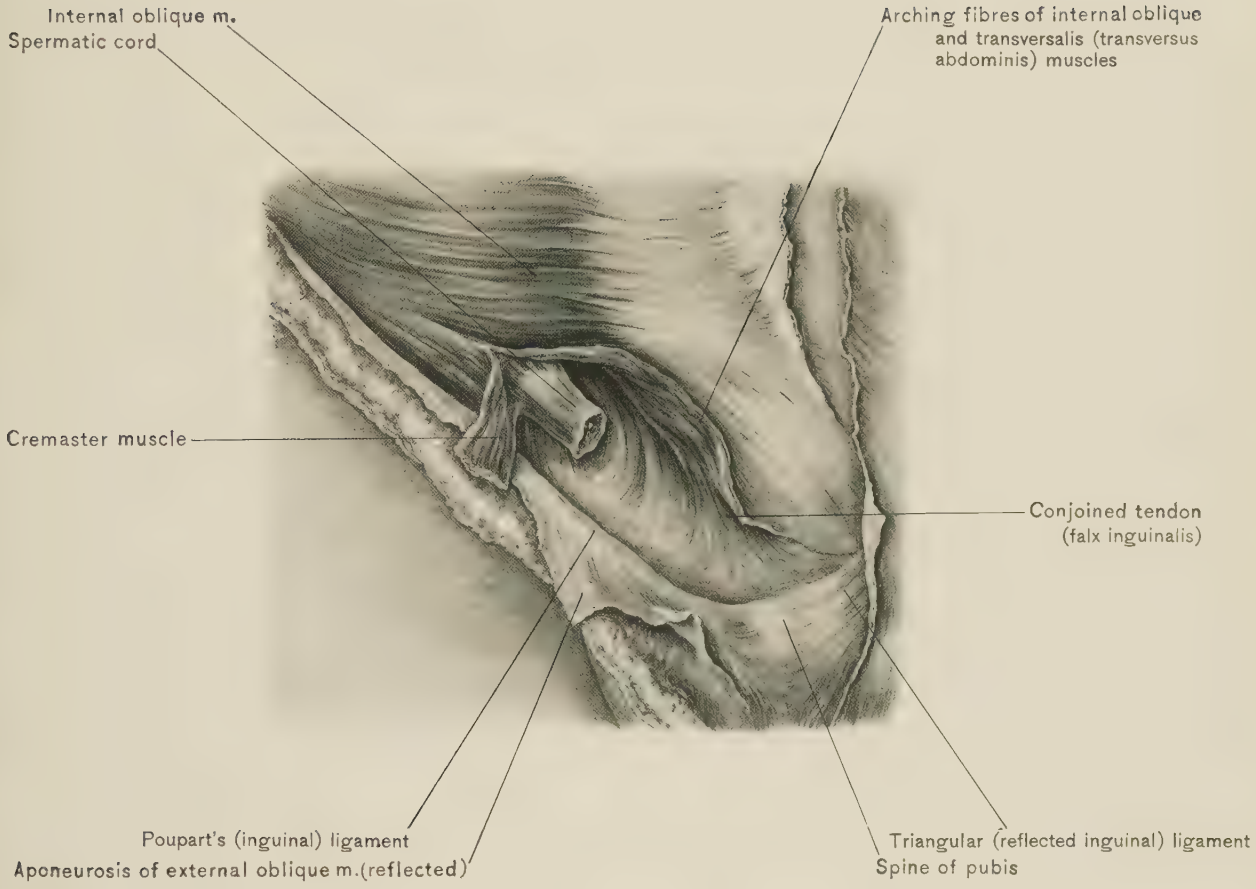
Internal oblique m.
Spermatic cord
Arching fibres of internal oblique and transversalis (transversus abdominis) muscles
Cremaster muscle
Conjoined tendon (falx inguinalis)
Poupart's (inguinal) ligament
Aponeurosis of external oblique m.(reflected)
Triangular (reflected inguinal) ligament
Spine of pubis

INGUINAL CANAL, CONJOINED TENDON (FALX INGUINALIS), AND TRIANGULAR (REFLECTED INGUINAL) LIGAMENT.

PLATE CCCLXXXVII.

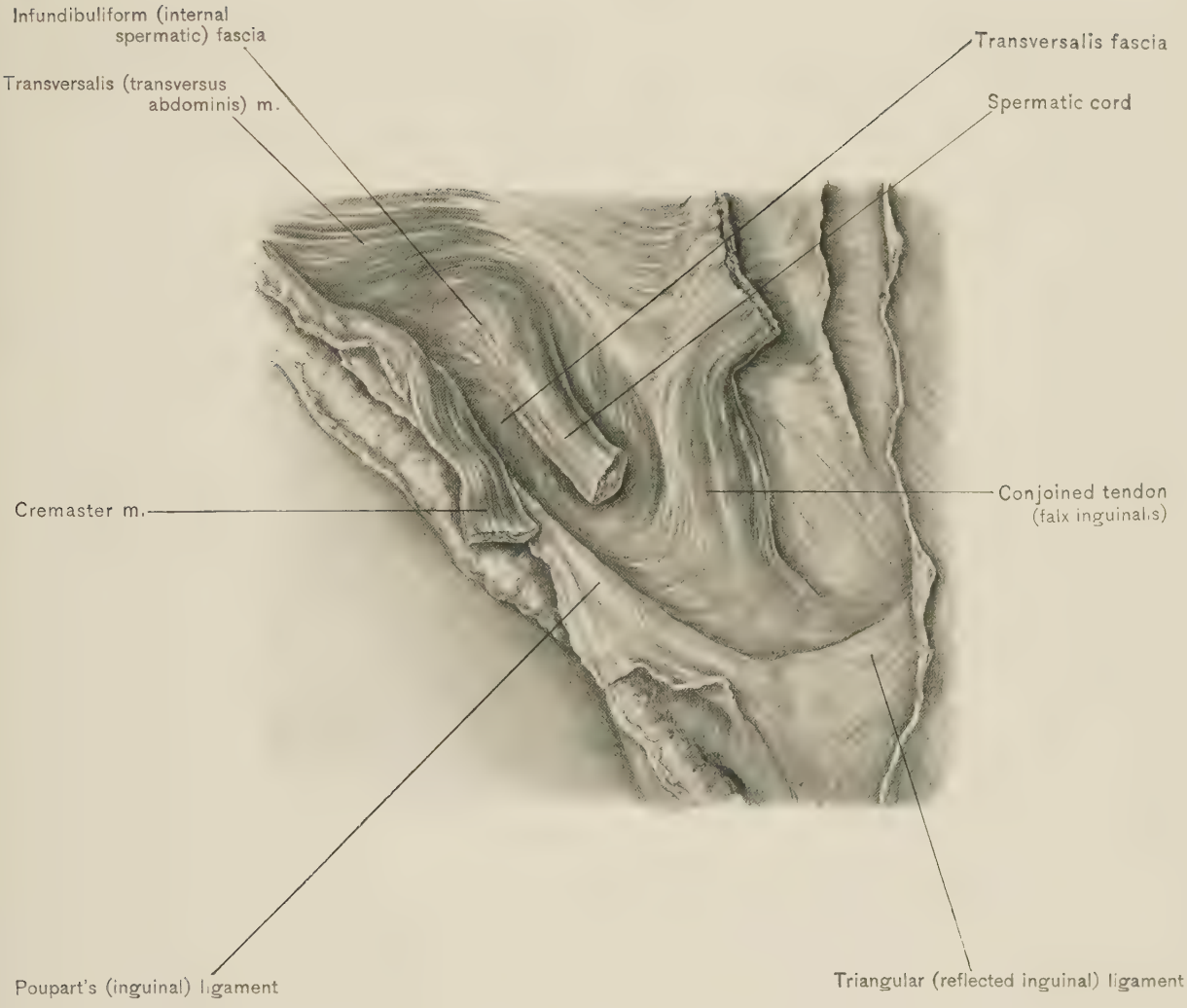

INGUINAL CANAL, CONJOINED TENDON (FALX INGUINALIS), INFUNDIBULIFORM (INTERNAL SPERMATIC) FASCIA.

Here the incision so closely parallels the ribs as to injure very few nerves. Properly sutured, Moynihan says he has never seen a hernia result after its use. When the vertical incision through the rectus is made, care should be exercised to place it well to the medial side of the muscle, since if it is made close to the linea semilunaris the nerves supplying this portion of the muscle are destroyed. In the McBurney incision for removal of the appendix, the muscles are not cut at all, the aponeurosis of the external oblique being divided in the line of its fibers, and the fibers of the internal oblique and transversalis (*transversus abdominis*) muscles simply being separated.

Dissection.—Expose the rectus abdominis muscle by making a vertical incision extending from the chest to the body of the pubis, through the anterior layer of the sheath of the muscle. Reflect the two portions of the sheath laterally by dividing the adhesions between the upper part of the anterior wall of the sheath and the tendinous intersections in the rectus, the lineæ transversæ (*tendinous inscriptions*). In addition to the rectus muscle the pyramidalis muscle, situated immediately above the pubis, in front of the rectus, should be exposed.

The **rectus abdominis muscle** is long, thin, and ribbon-like, and is situated between the linea alba and linea semilunaris, inclosed by a sheath formed by the aponeuroses of the three flat muscles of the abdomen. It extends from the pubis to the chest, and is separated from its fellow of the opposite side by the linea alba. It is narrowest below and widest above. It *arises* by two heads: the medial, or smaller, head springs from the ligamentous tissue in front of the symphysis pubis, where it blends with the medial head of the corresponding muscle of the opposite side; the lateral, or larger, head arises from the crest of the pubis. It passes upward, becoming broader and thinner, and is *inserted* into the superficial surface of the chondral end of the fifth rib and the fifth, sixth, and seventh costal cartilages. Sometimes fibers of the muscle are attached to the ensiform (*xiphoid*) cartilage. There are three *tendinous intersections* (*tendinous inscriptions*) in the rectus muscle: one is situated opposite the umbilicus, one between the umbilicus and the ensiform (*xiphoid*) cartilage, and one on a level with the ensiform (*xiphoid*) cartilage. These fibrous intersections are closely adherent to the anterior wall of the sheath of the rectus, but not to the posterior wall, so that pus formed within the upper part of the sheath of the muscle would not necessarily be confined by the intersections. On account of its length and ribbon-like form, some of the bundles of muscle fibers of the rectus abdominis are occasionally ruptured by muscular violence.

Blood Supply.—From the superior epigastric, deep (*inferior*) epigastric, and intercostal arteries.

Nerve Supply.—From the anterior divisions of the lower seven intercostal nerves.

Action.—The rectus abdominis muscles, when acting from below, depress the thorax and flex the vertebral column; when acting from above, they flex the pelvis upon the vertebral column.

The **pyramidalis muscle** is situated in front of the lower end of the rectus, and is triangular in shape. It *arises* by its base from the front of the body of the pubis and from the anterior pubic ligament. It passes obliquely upward and is *inserted* by its apex for a variable distance into the linea alba. It is sometimes absent on one or both sides.

Nerve Supply.—From the lower intercostal nerves.

Action.—To make tense the linea alba.

In opening the lower abdomen through the linea alba or through the linea semilunaris, when neither line is exposed directly by the incision through the skin and superficial fascia, the anterior layer of the sheath of the rectus muscle should be immediately opened, as the anterior wall of the sheath can then be stripped from the muscle and either the linea alba or the linea semilunaris quickly reached.

The **sheath of the rectus abdominis muscle**, which has been described with the internal oblique muscle, contains the rectus abdominis and pyramidalis muscles, the superior epigastric artery and its venæ comites, the terminal portion of the deep (*inferior*) epigastric artery and its venæ comites, and is traversed by the lower intercostal nerves.

The **superior epigastric artery** is the more medial of the two terminal branches of the internal mammary artery, of which it is the continuation. It emerges from the thorax by passing between the costal and xiphoid origins of the diaphragm and behind the seventh costal cartilage, to enter the sheath of the rectus abdominis muscle. It runs between the muscle and the posterior wall of its sheath, about midway between the borders of the muscle, enters the muscle, and anastomoses with the deep (*inferior*) epigastric artery about midway between the umbilicus and the xiphoid cartilage which is the longest anastomosis in the body. Its branches are: phrenic, xiphoid, muscular (to the rectus and the oblique muscles), cutaneous, and hepatic (to the falciform ligament of the liver where they anastomose with branches of the hepatic artery).

The **deep (inferior) epigastric artery** (Plate CCCLXXXIV) arises from the external iliac artery immediately above Poupart's (*inguinal*) ligament. It passes upward and medially in the extraperitoneal fat, or between the peritoneum and the transversalis fascia, toward the semilunar fold of Douglas (*linea semicircularis*), just below which it pierces the transversalis fascia and enters the sheath

PLATE CCCLXXXVIII.

INGUINAL CANAL, POUPART'S (INGUINAL) LIGAMENT, SPERMATIC CORD, AND CREMASTER MUSCLE.

of the rectus abdominis muscle. It runs upward between the rectus and the posterior wall of its sheath, about midway between the borders of the muscle, finally ramifying in the muscle and anastomosing with the superior epigastric artery. Just above its origin as it passes on the medial side of the internal abdominal (*abdominal inguinal*) ring, the spermatic vessels and vas deferens (*ductus deferens*), in the male, and the round ligaments of the uterus in the female and the genital (*external spermatic*) branch of the genito-crural (*genito-femoral*) nerve hook around the front and the lateral side of the artery, curving it slightly medialward. All oblique inguinal herniæ pass on the lateral side of the artery and direct inguinal herniæ pass on its medial side. It gives off cremasteric (*external spermatic*), pubic, peritoneal, muscular, and cutaneous branches.

The **cremasteric (external spermatic) branch of the deep (inferior) epigastric artery** supplies the cremaster muscle and the other coverings of the spermatic cord, and anastomoses with the spermatic (*internal spermatic*), superficial external pudendal, and superficial perineal (*perineal*) arteries. Through its anastomosis wih the spermatic artery it furnishes the blood supply of the testicle, after division of the spermatic (*internal spermatic*) artery in the operative treatment of varicocele. The **pubic branch** passes medialward, either above or below the femoral ring, to the posterior surface of the body of the pubic bone. This artery gains importance from being abnormally large and continuing as the obturator artery in about twenty-eight per cent. of subjects. When the anomalous obturator artery runs above and on the medial side of the femoral ring, which occurs in about two per cent. of subjects, it passes at a distance of only about three millimeters from the margin of the femoral ring, so that it may be severed by a deep incision to relieve constriction of a hernia at the femoral ring.

The muscles of the abdominal wall form an elastic support and a protection for the abdominal viscera.

Blows upon the abdomen, if anticipated, would not necessarily do much harm to the viscera since in anticipation of the blow the muscles would be tense and ready to protect the abdominal organs. An anticipated blow may bruise the abdominal wall extensively and not injure the viscera, whereas an unexpected blow may injure the abdominal viscera seriously without inflicting visible injury on the wall. A blow upon the epigastrium may cause death by concussion of the solar (*celiac*) plexus; the abdominal wall moves so freely over the viscera that the liver, intestines, stomach, or bladder may be ruptured with slight or no external signs of traumatism.

Dissection.—Reflect the transversalis (*transversus abdominis*) muscle forward in the same manner as the internal oblique, to expose the transversalis fascia.

The **transversalis fascia** lines the internal surface of the transversalis (*transversus abdominis*) muscle. It is a thin layer of fascia which is placed between the extraperitoneal fatty tissue and the abdominal muscles and their aponeuroses. The fascia of one side is continuous with that of the other at the linea alba, and thus forms an extensive lining membrane for the muscles of the anterior and lateral portions of the abdominal wall. It is attached laterally to the medial lip of the crest of the ilium, where it becomes continuous with the iliac fascia. In front it is attached to the lateral half of Poupart's (*inguinal*) ligament, where it is continuous with the iliac fascia. Opposite the femoral vessels it dips beneath Poupart's (*inguinal*) ligament to form the anterior part of the sheath of those vessels. To the medial side of the femoral vessels it is attached to the ilio-pectineal line, lying behind the conjoined tendon (*falx inguinalis*), to which also it is partially attached. It is closely adherent to the deep surface of the aponeuros is of the transversalis muscle. The transversalis fascia is quite thin above, where it becomes continuous with the thin fascia on the abdominal surface of the diaphragm; below, it is firmer and thicker. In the inguinal region it closes the gap between Poupart's (*inguinal*) ligament and the arching fibers of the internal oblique and transversalis muscles. At from one and one-fourth to one and a half centimeters (one-half to three-fourths of an inch) above the middle of Poupart's (*inguinal*) ligament the transversalis fascia contains an opening, the **internal abdominal** (**abdominal inguinal**) **ring** through which pass the constituents of the spermatic cord; these structures are covered by a funnel-shaped prolongation of the transversalis fascia known as the **infundibuliform**, or **internal spermatic, fascia.** This opening in the transversalis fascia is very important, as it forms the inlet to the inguinal canal, through which an indirect, or oblique, inguinal hernia must pass. The internal abdominal (*abdominal inguinal*) ring is round in the infant, but in the adult it is oval, as a result of the traction produced by the vas deferens (*ductus deferens*). As it is about one and a quarter centimeters (one-half inch) above the center of Poupart's (*inguinal*) ligament, it is covered by the lower fibers of the internal oblique muscle.

Dissection.—Upon the side from which the muscles have not been reflected mark out, just above the medial two-thirds of Poupart's (*inguinal*) ligament, a quadrilateral flap of the aponeurosis of the external oblique about five centimeters (two inches) in width, and reflect it downward to Poupart's (*inguinal*) ligament, thus giving an instructive view of the inguinal canal.

The **inguinal canal** (Plates CCCLXXXV, CCCLXXXVI, and CCCLXXXVII) is a space in the lower part of the abdominal wall, immediately above and nearly parallel with the medial half of Poupart's (*inguinal*) ligament. It extends from the internal abdominal (*abdominal inguinal*) ring

to the external abdominal (*subcutaneous inguinal*) ring, and is four centimeters (one and a half inches) in length in the male; in the female, it is five centimeters (two inches) in length, owing to the wider separation of the iliac bones. Accurately speaking, it is not a space, but is occluded by the apposition of its anterior and posterior walls to the structures within it. However, the union is a weak one and the fasciæ, muscle and cord structures are easily separated. It is bounded in front by the aponeurosis of the external oblique muscle throughout, and the lower fibers of the internal oblique at its lateral third; behind, by the triangular ligament of the abdominal wall (*reflected inguinal ligament*) at its medial end, and by the conjoined tendon (*falx inguinalis*) and transversalis fascia; above, by the arching fibers of the internal oblique and transversalis muscles, and below, by Poupart's (*inguinal*) ligament, to the posterior shelving margin of which the transversalis and pelvic fasciæ are attached, and for a short distance at its medial end by Gimbernat's ligament (*ligamentum lacunare*). The upper end of the canal is about twelve millimeters (one-half inch) above Poupart's (*inguinal*) ligament. This is marked by a depression on the posterior surface of the anterior abdominal wall and is termed the internal (*abdominal inguinal*) ring. This is due to the transversalis fascia being continued downward over the spermatic cord in what is known as the infundibuliform, or internal spermatic, fascia. Its *contents* in the male are the spermatic cord, the ilio-inguinal nerve, which lies in front of the cord, and the genital (*external spermatic*) branch of the genito-crural (*genito-femoral*) nerve, which runs in the cremasteric fascia on the posterior surface of the cord. Its contents in the female are the round ligament of the uterus, the ilio-inguinal nerve, and the genital (*external spermatic*) branch of the genito-crural (*genito-femoral*) nerve.

The **spermatic cord** (Plate CCCLXXXVIII) is the structure which extends from the internal abdominal (*abdominal inguinal*) ring, where its component parts are collected, to the testicle. It is the result of the descent of the testicle to the scrotum. The cord is fifteen to eighteen centimeters (six to seven inches) in length, passes through the inguinal canal and the external abdominal (*subcutaneous inguinal*) ring into the scrotum to the testicle. As it passes through the external abdominal (*subcutaneous inguinal*) ring it lies on the lateral pillar of the ring. The left spermatic cord is the longer, and therefore allows the left testicle to hang lower than the right one. The greater length of the left cord may be explained by the fact that embryologically the structures going to the left testicle are longer. This is due to the higher abdominal position. Its *contents* are the spermatic duct, or vas deferens (*ductus deferens*), the vessels of the vas (*ductus*) deferens, the spermatic (*internal spermatic*) artery, spermatic (*internal spermatic*) veins, or pampiniform plexus, sympathetic nerves, lymph vessels, the

cord-like remains of the processus vaginalis, the remains of the gubernaculum testis (*genito-inguinal ligament*), fat, and connective tissue.

The **spermatic duct** (**ductus deferens**) lies behind the other structures of the cord, and gives a cord-like sensation to the finger. It is two or three millimeters in diameter.

The **spermatic** (**internal spermatic**) **artery and its veins** —the pampiniform plexus—lie in front of the duct. The veins of this plexus are often varicose, constituting a **varicocele.** These veins have no valves, except for a pair usually present at the entrance of the right vein into the vena cava, which partly accounts for their tendency to become varicose. The left plexus of veins is more frequently affected. Various anatomical reasons are given for this phenomenon, the most common ones being that the left spermatic vein is much longer and its course more vertical than the right; that it empties into the left renal vein at a right angle, while the right vein empties at an acute angle into the inferior vena cava, and running beneath the sigmoid flexure, it is constantly subjected to compression from accumulated fecal matter.

The sympathetic nerves and the lymphatics accompany the spermatic vessels.

The fat and connective tissue which occupy the interstices between the other constituents of the spermatic cord are continuous with the extraperitoneal fat. Hypertrophy of the fat or lipoma in the spermatic cord (hernia adiposé) produces a swelling which simulates an inguinal hernia or a hydrocele of the spermatic cord.

The *coverings of the spermatic cord* are the structures which in the embryo are carried downward by the processus vaginalis and the testicle on their descent into the scrotum. Embryologically, at the internal abdominal (*abdominal inguinal*) ring the processus vaginalis pushes forward a funnel-shaped process of the transversalis fascia, which is the **infundibuliform fascia, or internal spermatic fascia,** then it takes part of the interabdominal fasciæ and a few fibers of the internal oblique, which form the **cremaster muscle, cremasteric fascia, or middle spermatic fascia,** and, finally, in passing through the external abdominal (*subcutaneous inguinal*) ring, it carries along part of the **intercolumnar fascia, or external spermatic fascia.** Therefore the coverings of the cord in the inguinal canal are the cremaster muscle or cremasteric fascia, and the infundibuliform (*internal spermatic*) fascia; in the scrotum, the intercolumnar (*external spermatic*) fascia, cremasteric fascia, and infundibuliform (*internal spermatic*) fascia.

The spermatic cord in early fetal life does not exist as such, nor does it lie in the inguinal canal until after the descent of the testicle, which carries with it the spermatic vessels and vas deferens (*ductus deferens*), and, in dragging

PLATE CCCLXXXIX.

ENCYSIED HERNIA.

INFANTILE HERNIA.

HERNIA INTO THE TUNICA VAGINALIS.

HERNIA INTO THE FUNICULAR PROCESS (PROCESSUS VAGINALIS)

DIAGRAMS OF THE VARIETIES OF CONGENITAL HERNIA.

them through a narrow passageway, the internal abdominal (*abdominal inguinal*) ring, brings the duct and vessels together.

Descent of the Testicle and Formation of the Spermatic Cord.—During the early part of intra-uterine life the testicle lies in the abdominal cavity at the level of the first two lumbar vertebræ behind the peritoneum, so that the peritoneum covers its anterior surface and sides, but not its posterior surface. The development of the sexual glands in both the male and female is attended by a unique migration from their original position opposite the lower pole of the kidney. At about the third month of fetal life a band which extends from the site of the internal abdominal (*abdominal inguinal*) ring to the testicle and thence upward toward the diaphragm is formed. This constitutes the **gubernaculum testis** (**genito-inguinal ligament**). Later the peritoneum surrounds the testicle entirely, making a mesentery, or mesorchium, which is composed of two folds, one extending above and the other below the organ. The upper one of these ultimately contains the spermatic vessels, and the lower transmits the gubernaculum testis (*genito-inguinal ligament*). The gubernaculum (*genito-inguinal ligament*) increases in size in its lower part, while the part above the testicle atrophies. At the lower end of this band a tube-like process of peritoneum is formed, the **processus vaginalis,** which extends into the inguinal canal. This process of the peritoneum and the gubernaculum (*genito-inguinal ligament*) gradually descend until they have reached the bottom of the scrotum. After this the gubernaculum (*genito-inguinal ligament*) ceases to grow, and consequently the testicle is drawn downward as the body increases in size. The gubernaculum (*genito-inguinal ligament*) also atrophies to a certain extent. After the testicle has reached the scrotum, the processus vaginalis atrophies, with the exception of that portion in relation with the testicle which becomes the tunica vaginalis of the testicle. The upper opening of the processus vaginalis is closed, and its thread-like remains can be seen in relation with the spermatic duct as a constituent of the spermatic cord.

Normally the entire canal of the processus vaginalis, except that part in relation with the testicle which forms the tunica vaginalis, closes shortly after the descent of the testicle; but sometimes this canal fails to close, or is only partially obliterated. As a result of this condition a hernia is likely to occur. This is called a **congenital hernia** (Plate CCCLXXXIX)—one which occurs because of the presence of a patulous embryonic canal. If this pouch of peritoneum, the processus vaginalis, remains patulous throughout, the cavity of the processus vaginalis, tunica vaginalis, will be in free communication with the general peritoneal cavity. In these conditions a hernia may enter the pouch and descend until it is in direct contact with the visceral portion of the tunica vaginalis of the

testicle. This constitutes a **hernia into the tunica vaginalis**—a hernia of rapid formation. This type is frequently called a congenital hernia, though in reality, this hernia and the infantile funicular and encysted herniæ are all congenital in the strict sense of the term. Sometimes the processus vaginalis will remain patulous down to a short distance above the testicle, so that a funnel-shaped pouch, or **funicular process,** is formed. A hernia which enters this pouch is known as a **hernia into the funicular process** of the processus vaginalis. If the pouch closes only at the internal abdominal (*abdominal inguinal*) ring and remains patulous throughout the rest of its extent, we may find one of two varieties of hernia—infantile or encysted. In the **infantile hernia** the hernial mass pushes against the peritoneum in the vicinity of the internal abdominal (*abdominal inguinal*) ring, forcing it to yield. Thus it forms a sac for itself which descends behind the tunica vaginalis, or processus vaginalis, and, as a result, an infantile hernia presents three coverings of peritoneum in front—the two of the tunica vaginalis and that of the sac. In the **encysted hernia** the protruding mass pushes against the septum, which occludes the processus vaginalis at the internal abdominal (*abdominal inguinal*) ring and forces it to yield. It is, therefore, a hernia of slow formation. Thus the septum forms the sac, which descends within the pouch of the processus vaginalis. The encysted hernia, therefore, presents a sac within a sac, and has two layers of peritoneum in front. The outer layer is the tunica vaginalis, and the inner layer is formed by the septum which is invaginated into the pouch of the tunica vaginalis.

Inguinal hernia.—It will be seen that the direction of the spermatic cord in its passage through the abdominal wall is downward and medially, a little above, and nearly parallel with, the medial half of Poupart's (*inguinal*) ligament. Its constituent parts converge at the internal abdominal (*abdominal inguinal*) ring, which is situated in the transversalis fascia, about one and one-fourth centimeters (one-half inch) above the middle of Poupart's (*inguinal*) ligament, and pass medially and downward through the inguinal canal and the external abdominal (*subcutaneous inguinal*) ring, to reach the scrotum. The cord rests in the groove formed by the union of Poupart's (*inguinal*) ligament and the transversalis fascia. Above it are the arching fibers of the internal oblique and transversalis muscles; in front of it are, from the surface inward: the skin, superficial fascia, and the external oblique aponeurosis along the entire length of the inguinal canal, and the fibers of the internal oblique muscle along the lateral third of the canal; behind it are, in the same order, the triangular ligament of the abdominal wall (*reflected inguinal ligament*), the conjoined tendon (*falx inguinalis*) of the internal oblique and transversalis muscles, the transversalis fascia, extraperitoneal areolar tissue, or preperitoneal fat, and peritoneum. It should be noted that the arching fibers

PLATE CCCXC.

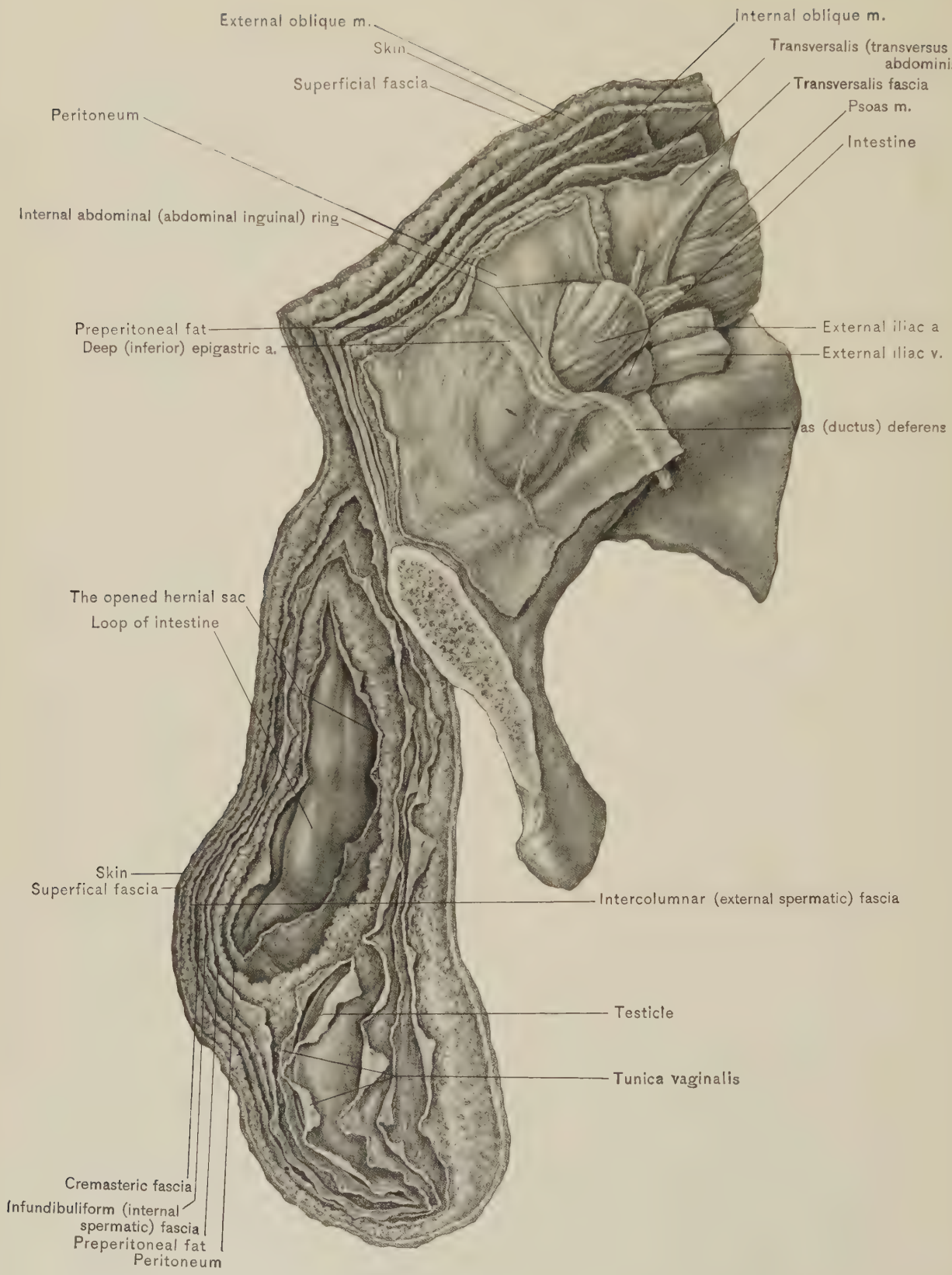

AN ACQUIRED OBLIQUE INGUINAL HERNIA.

of the transversalis muscle do not pass in front of the spermatic cord, but occupy a higher position, and that the arching fibers of the internal oblique cover the upper end of the cord. The latter are the fibers which are divided at their origin in Halstead's operation for the radical cure of oblique inguinal hernia. A proper understanding of the boundaries of the inguinal canal and the course, relations, and coverings of the spermatic cord simplifies the study of inguinal hernia.

A hernia is an extrusion of a viscus, or part of a viscus, into or through the wall of its containing cavity. Therefore, we may have herniæ of the brain, lung, intestine, omentum, or other viscera. An extrusion of any of the viscera of the abdominal cavity, or part of them, through either of the abdominal rings is known as an inguinal hernia. A hernia which passes through the internal abdominal (*abdominal inguinal*) ring follows the spermatic cord in an oblique direction, and is therefore known as an *oblique inguinal hernia;* it is called an *indirect inguinal hernia* because it does not pass perpendicularly through the abdominal wall; it is also called an *external inguinal hernia* because it passes external, or lateral, to the deep (*inferior*) epigastric artery. A *direct inguinal hernia* passes directly through the abdominal wall at the position of the external abdominal (*subcutaneous inguinal*) ring, without having traversed the entire inguinal canal; it is also called an *internal inguinal hernia* because it passes internal, or medial, to the deep (*inferior*) epigastric artery.

Oblique inguinal herniæ (Plate CCCXC) are subdivided into those which do not pass beyond the inguinal canal and are called incomplete oblique inguinal herniæ, and those which pass through the canal and external abdominal (*subcutaneous inguinal*) ring and are called complete oblique inguinal herniæ. An incomplete oblique inguinal hernia is also called a *bubonocele*, because it forms a swelling near the common site of buboes. From the standpoint of treatment a hernia which passes just to the medial side of the deep (*inferior*) epigastric artery may be considered as an oblique inguinal hernia.

In an oblique inguinal hernia the extrusion begins by pushing into the internal abdominal (*abdominal inguinal*) ring the depressed portion of the peritoneum in relation with that ring. The depression at this point is called the *hernial fossa of the peritoneum.* This pouch of peritoneum pushes before it the superimposed extraperitoneal areolar tissue (preperitoneal fat) and the infundibuliform process of the transversalis fascia, the whole mass lying in front of the spermatic vessels and duct. Thus far the hernia is covered by peritoneum, subserous areolar tissue, and infundibuliform (*internal spermatic*) fascia. As the hernia passes beyond the lower margin of the internal oblique muscle it becomes covered by the cremaster muscle or cremasteric fascia, and as it emerges from the external abdominal (*subcutaneous inguinal*) ring it carries with it the

intercolumnar (*external spermatic*) fascia. Beyond this point, as it descends into the scrotum, it is also covered by the superficial fascia and skin. The *coverings*, therefore, *of a complete oblique inguinal hernia*, from without inward, are: skin, superficial fascia, intercolumnar (*external spermatic*) fascia, cremaster muscle (*cremasteric fascia*), infundibuliform (*internal spermatic*) fascia, preperitoneal fat, or extraperitoneal areolar tissue, and peritoneum. The *coverings of an incomplete oblique inguinal hernia*, one which does not pass out of the inguinal canal, are: skin, superficial fascia, aponeurosis of the external oblique muscle, cremaster muscle, infundibuliform (*internal spermatic*) fascia, preperitoneal fat, and peritoneum.

Stricture of the hernial mass may take place at any part of its passage through the belly-wall, at either ring, between them, or in the neck of the sac. If the constriction is at the external abdominal (*subcutaneous inguinal*) ring, it is relieved by incision of the medial pillar of the opening; if at the internal (*abdominal inguinal*) ring, the obstruction is in one, two, or all three of the innermost coverings, peritoneum, extraperitoneal areolar tissue, and infundibuliform (*internal spermatic*) fascia; if between the two rings, the constriction is in the sac itself. Section of these constrictions should be made in an upward direction. The incision at the internal (*abdominal inguinal*) ring should always be made upward, to avoid division of the deep (*inferior*) epigastric vessels.

In a *direct inguinal hernia* the extruding mass passes directly through the belly-wall at the external abdominal (*subcutaneous inguinal*) ring, through which it emerges. It lies wholly upon the medial side of the deep (*inferior*) epigastric artery, and passes through *Hesselbach's triangle*, which is situated in the inferior part of the abdominal wall. This triangle is bounded laterally by the deep (*inferior*) epigastric artery; medially, by the lateral margin of the rectus abdominis muscle, and below, by Poupart's (*inguinal*) ligament. The abdominal wall at the medial two-thirds of this triangle is strengthened by the conjoined tendon (*falx inguinalis*), while at the lateral third it is much weaker, because of the absence of muscular and tendinous tissues in the interval between Poupart's (*inguinal*) ligament and the arching fibers of the internal oblique and transversalis muscles. This lateral corner of Hesselbach's triangle may appropriately be called the *weak angle* of the triangle, as it is devoid of the protection of the conjoined tendon (*falx inguinalis*) and contains no substitute for it. Through this weak angle a direct inguinal hernia may pass into the inguinal canal and be covered by the cremasteric and intercolumnar (*external spermatic*) fasciæ, the same as an oblique inguinal hernia; all coverings of such a direct inguinal hernia would be the same as in a complete oblique inguinal hernia, except that the general transversalis fascia is substituted for the infundibuliform (*internal*

spermatic) fascia. It is however the opinion of most surgeons and anatomists that a weak or deficient conjoined tendon (*falx inguinalis*) is the most important factor in the production of a hernia of the direct type. Herniæ of the direct type present more of a bulge of the peritoneum than a true sac, as in the indirect type.

Sometimes the protrusion either passes between the fibers of the conjoined tendon (*falx inguinalis*), or pushes this structure before it as one of its coverings, which are the same as those of a complete oblique inguinal hernia, except that the conjoined tendon (*falx inguinalis*) takes the place of the cremaster muscle, and the general transversalis fascia that of its infundibuliform process (*internal spermatic fascia*). Therefore the coverings of a direct inguinal hernia are: skin, superficial fascia, intercolumnar (*external spermatic*) fascia, conjoined tendon (*falx inguinalis*), transversalis fascia, preperitoneal fat, and peritoneum.

Stricture of a direct inguinal hernia is most likely to occur at the external abdominal (*subcutaneous inguinal*) ring. It may be situated in the edges of the separated conjoined tendon if the gut has passed through it. It is relieved by upward section, thus avoiding the deep (*inferior*) epigastric artery.

The relation of the direct and indirect inguinal herniæ to the spermatic cord differs. The contents of the cord are spread over the posterior surface and sides of the sac of an oblique inguinal hernia, whereas the cord and its two inner coats lie behind and lateral to a direct inguinal hernia.

Inguino-crural (inguino-femoral) hernia is the name given to an uncommon form of indirect inguinal hernia which, for some reason, such as obstruction by a partially descended testicle or from a constriction in a preformed sac does not pass into the scrotum, but, after passing through the external abdominal (*subcutaneous inguinal*) ring, turns lateralward along Poupart's (*inguinal*) ligament and lies in the subcutaneous tissues.

Intraparietal herniæ, which include **preperitoneal** and **intermuscular herniæ,** are those in which the sac dissects one or more of the layers of the abdominal wall and occupies a space between the parietal peritoneum and muscle layers or between the muscle layers themselves. These are rare herniæ and exact preoperative diagnosis is difficult.

The reduction of herniæ by taxis requires, previous to manipulation, a maximum amount of relaxation of the parts involved. This is best effected by putting the patient upon his back, with the head and shoulders well raised and the thigh of the affected side flexed and adducted, thus relieving the tension caused by the fascia lata of the thigh and the aponeurosis of the external oblique muscle. The hips also are elevated so that gravity may aid in reducing the hernia. The hernial mass should be slightly drawn downward, so as to oblit-

erate any folds or overlapping at the constriction; in front of the point of constriction the mass must be held so as to avoid local bulging; gentle pressure is then made toward the abdomen in the line of the path by which the hernia descended. In reduction of an oblique inguinal hernia pressure is directed upward, lateralward, and backward; the direction of the pressure upon a direct hernia is backward. The reduction of herniæ by taxis, however, is not recommended except in expert hands and where its use is limited to one or two attempts. The danger of reduction by taxis is hemorrhage into the mesentery and the bowel wall and reduction *en masse*, all of which are serious.

An oblique inguinal hernia will in time, as it enlarges, drag the internal abdominal (*abdominal inguinal*) ring almost opposite to the external abdominal (*subcutaneous inguinal*) ring, so that in reduction it takes nearly the same course as a direct inguinal hernia. This is due to the long-continued traction of the extruded hernial mass tending to bring the abdominal rings one directly behind the other, the external (*subcutaneous inguinal*) ring enlarging laterally and the internal (*abdominal inguinal*) ring, medially. Such an old indirect hernia is called a **straight hernia,** and is always distinguishable from a direct hernia by the presence of the deep (*inferior*) epigastric artery upon its medial side.

In the female a congenital oblique inguinal hernia may enter the canal of Nuck (*vaginal process of peritoneum*). An incomplete oblique inguinal hernia, or bubonocele, is the same in both sexes, having the same relations and the same coverings. The scrotal hernia of the male corresponds to the **labial hernia** of the female. The latter has the same coverings as in the male, except that there is no counterpart of the cremaster muscle.

Acquired inguinal hernia.—Many factors favor this region for acquired hernial protrusions. It is, however, not unlikely that even in the acquired form their exists some congenital deformity at the internal (*abdominal inguinal*) ring or in the region of the conjoined tendon (*falx inguinalis*) to explain the production of the protrusion. Many so-called acquired herniæ are truly congenital since, although the preformed sac may be present at birth, the hernia may not become discernible until the intra-abdominal pressure is suddenly increased and the abdominal muscles are in such a position as to take tension off the neck of the sac.

(1) The descent of the testicle through the internal (*abdominal inguinal*) ring carries with it an infundibuliform process of peritoneum which, even though it closes, leaves behind a small funnel-shaped process of peritoneum which constitutes a weak spot. (2) The area is subjected to increased pressure by any intra-abdominal readjustment necessary when the cavity is reduced in size. (3) The transversalis-iliacus fascia to the lateral side of the internal (*abdominal inguinal*) ring is very strong and helps to prevent herniæ in this region. (4)

Deficiency or weakness of the conjoined tendon (*falx inguinalis*) allows increased intra-abdominal pressure to play upon a relatively unprotected area. (*5*) To the lateral side of the tendon, especially if it is weak, or if the lateral portion is separated into its two components, is found an especially vulnerable area since it leaves a space adjacent to the internal (*abdominal inguinal*) ring wholly unprotected.

Operations for inguinal hernia.—The incision should be made slightly above and parallel to Poupart's (*inguinal*) ligament, over the hernial mass and parallel with its long axis. It passes through the different coverings of the various herniæ, these differing but little, as will be seen by a reference to the anatomic coverings of the several varieties. It must be borne in mind that the deep (*inferior*) epigastric artery lies to the medial side of the neck of an indirect inguinal hernia, and to the lateral side of that of a direct inguinal hernia. In operating upon an *incomplete indirect inguinal hernia* the incision will sever the skin, the superficial fascia, the superficial epigastric and the superficial circumflex iliac vessels, and the aponeurosis of the external oblique muscle; the ilio-inguinal nerve is displaced lateralward, and the cremasteric fascia, the infundibuliform (*internal spermatic*) fascia, and the preperitoneal fat are divided to expose the hernial sac. In operating upon a *complete oblique inguinal hernia* the skin, superficial fascia, superficial epigastric and superficial external pudendal vessels, intercolumnar (*external spermatic*) fascia, and aponeurosis of the external oblique muscle are divided, the ilio-inguinal nerve is displaced lateralward, and the cremaster muscle, infundibuliform (*internal spermatic*) fascia, and preperitoneal fat are divided to expose the hernial sac. In operating upon a *direct inguinal hernia* the incision severs the skin, the superficial fascia, the superficial external pudendal vessels, the intercolumnar (*external spermatic*) fascia, the aponeurosis of the external oblique muscle, the conjoined tendon (*falx inguinalis*) (only when the hernia is strangulated), the transversalis fascia, and the preperitoneal fat to expose the hernial sac. At times a direct hernia escapes around the lateral side of the conjoined tendon (*falx inguinalis*), the structures lying over it being then the same as those found in a complete indirect inguinal hernia, with the exception that a portion of the transversalis fascia instead of the infundibuliform (*internal spermatic*) fascia forms a covering for such a direct hernia. Although in each case these layers of tissue cover the hernia, they are not always readily recognized separately.

In a hernia due to congenital defects, the structures severed are practically the same as in the acquired forms, except for the difference in the number of layers of peritoneum found overlying each. In a hernia into the processus vaginalis or into its funicular process there is but one layer of peritoneum in

front of the gut. In an infantile hernia the sac descends behind the unobliterated portion of the processus vaginalis, so that there are three layers of peritoneum in front of the hernia. In an encysted hernia the sac descends within the processus vaginalis and has two distinct sacs, one being within the other, a single and a double layer of serous membrane lying in front of the gut.

The relation of the hernial mass to the spermatic cord must be remembered. The constituents of the spermatic cord are usually spread over the posterior and lateral aspects of the sac of the hernia.

It should be remembered that frequently an indirect and a direct hernia occur on the same side. It is important to look for this in order to cure the patient by operation. The coexistence of both forms on the same side is known as an inguinal hernia of the *pantaloon type*. The correction of only one of the herniæ does not establish a cure and the apparent rapid recurrence after operation is incorrectly interpreted. When such a condition exists the deep (*inferior*) epigastric vessels can be freed or divided and the direct bulge can be transferred into a portion of the indirect sac, or each sac may be dealt with separately.

In relieving the constriction in a strangulated, indirect inguinal hernia the nick in the constriction should be made upward and lateralward, in order to avoid the deep (*inferior*) epigastric artery, and in a direct inguinal hernia, it is made upward and medialward for the same reason. It is generally safer, however, to relieve the constriction by an upward incision in both cases, as it sometimes is difficult to differentiate between an indirect inguinal hernia of long standing and a direct inguinal hernia, because the former tends to bring the two abdominal (*inguinal*) rings nearly opposite each other. If the incision is made upward in relieving the constriction, there is no danger of wounding the artery.

After opening the sac in a strangulated hernia, the sac should be evacuated and cleaned before relieving the constriction, otherwise when the peritoneal cavity is opened, the resulting relief of the constriction will allow the fluid to escape and, if infected, thus expose the peritoneal cavity to contamination. The constriction should then be relieved at once, and the bowel examined before returning it to the abdominal cavity, in order to determine whether its blood supply will return and the gut regain its normal condition. In order to favor return of the circulation in the discolored bowel traction should be made on the loop of gut until from five to seven centimeters (two to three inches) of healthy bowel are drawn into the wound at both ends of the loop. If it fails to show signs of recovery after treatment with hot, moist, sterile gauze, and gangrene seems likely to occur, it is advisable either to do a resection and anastomosis, or to fix the gut in the wound with a view to establishing an artificial

anus after the gangrenous portion of the intestine has been separated. After resection of the gangrenous bowel the continuity of the intestine is re-established by an end-to-end or lateral anastomosis. In no case is it permissible to return the hernia *en masse*. If there are any signs of gangrene in the omental contents of the hernial mass all such portions should be tied off and removed.

In operating upon either an irreducible or a strangulated hernia the sac should be separated from the spermatic cord, and the hernial openings and canal treated by one of the various operations for the permanent cure of the defect.

In the operations for the radical cure of oblique inguinal hernia described below, the same structures are divided in exposing the sac. These are the skin, superficial fascia, superficial epigastric and superficial external pudendal vessels, aponeurosis of the external oblique muscle, intercolumnar (*external spermatic*) fascia, cremaster muscle, infundibuliform (*internal spermatic*) fascia, and preperitoneal fat.

The operation of choice for all indirect inguinal herniæ and, in my opinion, for most direct inguinal herniæ is the Bassini operation. Bassini, in 1888, published a new principle in closing the canal, namely the transplantation of the cord. Since that time surgical literature has been filled with modifications of this procedure. Many differ so slightly as not to warrant separate names. An important recent contribution is that of Gallie, whereby strips of fascia are utilized for suturing the internal oblique and transversalis (*transversus abdominis*) muscles to Poupart's (*inguinal*) ligament.

Bassini's Operation.—The anterior wall of the inguinal canal, excepting the lower fibers of the internal oblique muscle, is divided, the sac is freed from the surrounding structures, tied off at the neck, and the portion in front of the ligature is removed. The spermatic cord is then lifted up and the sutures are carried under it, by which the border of the rectus abdominis muscle, the conjoined tendon (*falx inguinalis*), the arching fibers of the internal oblique and transversalis muscles, and the transversalis fascia are fastened to the posterior shelving margin of Poupart's (*inguinal*) ligament. The cord is then placed upon the arching fibers of the internal oblique and transversalis muscles and the conjoined tendon (*falx inguinalis*), and the wound in the aponeurosis of the external oblique muscle is closed over the cord. In this way the inguinal canal is entirely obliterated, and a new passageway is formed for the spermatic cord. The superficial fascia and skin are then closed as usual.

The Ferguson, or Bull and Coley, operation is suitable in children. Here the sac is isolated and ligated at the neck but the cord is not transplanted, while the internal oblique and transversalis muscles and the conjoined tendon (*falx*

inguinalis) are sutured to the shelving edge of Poupart's (*inguinal*) ligament anterior to the cord.

In the Halstead operation the cord is transplanted more superficially (beneath the skin and superficial fascia); the internal oblique is cut upward for a distance of two and a half to five centimeters (one to two inches) before it is sutured to Poupart's (*inguinal*) ligament, and the major portion of the pampiniform plexus is resected. I have never been able to convince myself of the merits of this operation.

For the direct form of hernia I still believe that in the majority of cases the Bassini operation is the superior procedure. However in cases with a deficient conjoined tendon (*falx inguinalis*) it is true that recurrences following the Bassini operation are greater than in the indirect form. Many modifications of recognized procedures have been devised to correct the anatomic defects which give rise to hernia of the direct type. None of these operations is suitable in all cases. Downes' operation of suturing the rectus muscle, after opening the rectus sheath, to Poupart's (*inguinal*) ligament and then doing a Bassini operation, has been widely adopted. The fallacy of this procedure has been shown by Seelig who has convincingly demonstrated that muscle does not form a firm union to ligamentous structures. It is better to use the rectus sheath for support than to depend upon the muscle.

Umbilical herniæ are of three varieties: congenital, infantile, and acquired.

A **congenital hernia of the umbilical cord is rare.** It usually is present at birth, and occurs more frequently in females. It is due to a defect in the anterior abdominal wall, failure of the two somatopleuræ to unite. The hernia may be of large size, and may contain not only intestine, but the spleen, the liver, and other organs; or it may be small, appearing as a tumor at the root of the umbilical cord, between the structures of which the sac protrudes. Before being ligated the umbilical cord, particularly if it is at all bulky, should be examined carefully for fear of including in the ligature the contents of such a hernia. The coverings of this variety of hernia usually appear as a translucent membrane.

An **infantile umbilical hernia** appears after detachment of the umbilical cord, and is due to yielding of the umbilical cicatrix. It is generally small, and the tendency is toward spontaneous cure. The coverings of this variety are skin, superficial fascia, transversalis fascia, preperitoneal fat, and peritoneum.

An **acquired umbilical hernia** most commonly develops in adults. It does not always occur through the umbilicus, but sometimes through the linea alba above, below, or to one side of the umbilicus. When the hernia takes place through the umbilicus, it is usually at the upper part, above the urachus and the obliterated hypogastric (*umbilical*) arteries, which is the weakest part of the scar.

Acquired umbilical herniæ occur most frequently in women who have borne children and whose abdominal walls are more or less pendulous from the deposit of fat. These herniæ may be quite small, but often are of considerable size. The skin covering a large umbilical hernia is frequently ulcerated, due to interference with its circulation by pressure of the contents. The contents are the greater omentum and small intestine, and frequently a loop of the transverse colon. They are usually irreducible, on account of the presence of omental adhesions. Theoretically, the coverings of this variety of hernia are: skin, superficial fascia, transversalis fascia, preperitoneal fat, and peritoneum, but practically they are: skin, connective tissue, and peritoneum, the layers beneath the skin becoming fused into one layer with the peritoneum.

Radical cure of umbilical hernia.—In the operation for the radical cure of long-standing acquired umbilical hernia it is more difficult to free the sac than in either inguinal or femoral herniæ. The operation differs from those in the two last-named forms in that the sac is not dissected free except at its neck, which is exposed by carrying an elliptical incision through the integument and fascia overlying this portion of the hernia. The neck of the sac having been exposed, it is separated from the margins of the opening. The sac is next laid open, and the contents, if not already reducible, are rendered so. After the gut and omentum are reduced, the whole of the sac with the overlying integument is cut away. The wound now is similar to that made in opening the abdomen through the midline, except that the umbilicus is cut out. The wound may be closed by interrupted sutures, including all the layers of the belly-wall, or by tiers of sutures, all of which are buried, except the tier that closes the wound in the skin and the superficial fascia. The skin and superficial fascia may be apposed by the subcuticular stitch.

The *Mayo operation* is the one most commonly used today because it considerably reduces the chance of recurrence. This operation is done through a double horizontal elliptical incision around the umbilicus and the hernia. The fibrous coverings at the neck of the sac are divided in a circular manner and the sac opened as in the classic operation. The closure of the ring is in whatever direction is easiest. The aponeurosis is now cut horizontally for two or more centimeters more at each side and separated from the peritoneum beneath. The aponeurotic flaps are then overlapped by mattress sutures, the peritoneum being closed as traction is made on the mattress sutures by a continuous stitch. The mattress sutures are then tied, thus pulling the entire lower flap between the upper flap and the peritoneum. The lower edge of the upper flap is then sutured to the lower one, thus making two layers of aponeurosis over the hernial orifice.

The prognosis of a strangulated umbilical hernia is not so favorable as of the other common forms of strangulated hernia, because involvement of the jejunum, the part of the intestine most frequently involved, results in early toxemia after obstruction. While operation at the earliest possible moment is important in any case of strangulated hernia, it is especially so in the umbilical form since the operation is more difficult, due to the greater percentage of omental and intestinal adhesions within the sac.

Nerve Supply.—The nerve supply of the abdominal wall is derived from the lower seven intercostal nerves and the ilio-hypogastric and ilio-inguinal branches of the anterior division of the first lumbar nerve. As these nerves supply both the skin and the muscles of the anterior and lateral walls of the abdomen, irritation of the skin of the belly causes contraction of the muscles of the belly-wall. This is one reason why palpation of the abdomen should be done with the palm of the hand, rather than with the tips of the fingers, and with warm hands, since sudden pressure with the tips of the fingers or contact with cold causes irritation of the cutaneous nerve-fibers and contraction of the muscles. After a few moments the nerves become accustomed to the pressure of the hand, the muscles relax, and the abdominal organs can be palpated.

In caries of the lower thoracic vertebræ and in tabes dorsalis irritation of the nerves may cause pain in the abdomen and girdle sensations, which are compared to constriction of the abdomen with a cord. The pains referred to the abdominal wall in tabes dorsalis produce the **gastric crises** of that disease.

The close connection between the nerve supply of the anterior and lateral abdominal walls and that of the abdominal viscera explains some peculiar instances of referred irritation causing pain and spasm. The abdominal viscera and the peritoneum are supplied by branches derived from the solar (*celiac*) plexus, which receives fibers from the splanchnic (sympathetic) nerves. These nerves arise from the fifth to the twelfth thoracic ganglia of the sympathetic trunk inclusive, and these ganglia are connected with the lower thoracic nerves by the rami communicantes. Thus the central spinal connection is the same. The lower intercostal nerves, which are branches of the anterior divisions of the lower thoracic nerves, supply both the muscles and integument of the upper three-fourths of the anterior and lateral abdominal walls. In peritonitis or irritation of the peritoneum or viscera, as in appendicitis, irritation reflected along the spinal nerves causes the spasm and rigidity of the muscles of the belly-wall, and the pain which, in the earlier stages of the disease, is usually referred to the epigastric and umbilical region.

The sympathetic nerves probably do not carry pain fibers. Visceral pain is initiated by the stimulus of visceral tension. The afferent sympathetic fibers

which have a central connection exactly like the somatic sensory nerves carry the stimulus to the spinal segments and the brain consciously interprets the stimulus as coming from the end root of the somatic sensory branches. This, at least, is the present interpretation of visceral pain. When the peritoneal inflammation spreads so as to irritate the subperitoneal somatic nerves, then the pain becomes localized to the exact location at which the lesion exists.

The direction of the nerves in the abdominal wall should be considered in making incisions; their direction is oblique, from behind forward and downward. A vertical incision of considerable length through the abdominal wall at or lateral to the linea semilunaris would divide several of the intercostal nerves and the muscles supplied by them. For instance, the segments of the rectus abdominis would be paralyzed and thus, of course, rendered less able to resist intra-abdominal pressure.

Wounds of the abdominal wall which extend through the external oblique muscle or aponeurosis and perhaps involve the other two flat muscles are likely to gape and allow the underlying muscles, fascia, peritoneum, or abdominal viscera to protrude. Fragments of glass, wood, or steel may be concealed in the intermuscular connective-tissue planes and not be found. The connective-tissue planes also favor the retention of pus and extension of an abscess, should suppuration occur. Frequent contraction of the muscles retards healing of the wound if the patient is not kept at rest in bed.

If the wound penetrates the abdominal cavity, contraction of the muscles of the abdominal wall may cause protrusion of a portion of one or more viscera; in reducing the protruding viscus, a portion may be pushed into one of the intermuscular planes or into the preperitoneal fat. In all cases where it is suspected that the wound has penetrated the peritoneal cavity a formal laparotomy should be done by enlarging the incision, reducing the protruding viscera, and carefully closing the abdominal wall by tier suture.

Dissection.—In reflecting the transversalis muscle the portion of the transversalis fascia lining that muscle has probably been removed with the muscle. The remaining portion of the transversalis fascia is likely to be that part which closes the gap between Poupart's (*inguinal*) ligament and the arching fibers of the transversalis muscle.

The **extraperitoneal connective tissue** (subperitoneal, or preperitoneal, fat) is seen after removal of the transversalis fascia. Composed of loose areolar tissue and fat, it attaches the rough external surface of the peritoneum to the walls of the abdominal cavity and the viscera in relation with the peritoneum, and transmits the blood-vessels of the abdomen. At the sides of the upper lumbar

vertebræ, where it is thickest, it invests and forms a soft, elastic bed for the kidneys. It envelops also the uretèrs, suprarenal glands, abdominal aorta and vena cava. It is continuous with the fibrous coats of the abdominal viscera and the true sheaths of the blood-vessels of the abdomen, and extends into the spermatic cord, within the tube formed by the infundibuliform (*internal spermatic*) fascia. At this point it is found as the areolar tissue of the spermatic cord, which invests the spermatic vessels, nerves, lymphatics, and ducts, and may contain an excess of fat, thus forming a swelling (*hernia adiposé*) which may resemble an oblique inguinal hernia. It also extends into the femoral canal, or medial compartment of the femoral sheath. The part of the extraperitoneal connective tissue which fills the femoral ring is called the **septum crurale** (**femoral septum**). Processes of the extraperitoneal fat may protrude through openings in the aponeurosis at the linea alba, and form a button-like tumor resembling an omental hernia.

The laxity of the extraperitoneal connective tissue favors stretching of the peritoneum, as in herniæ and in certain extraperitoneal operations, such as extraperitoneal ligation of the external iliac artery, and in operations upon the kidney through the loin in which extensive areas of the peritoneum are displaced by tearing the extraperitoneal connective tissue.

Like the peritoneum, the extraperitoneal connective tissue is divided into a parietal and a visceral portion.

The **parietal portion** connects the parietal portion of the peritoneum with the various fasciæ—transversalis, lumbar, iliac, pelvic, and recto-vesical—which line the muscular wall of the abdominal cavity. It is absent in relation to the diaphragm. This portion is best developed at the sides of the lumbar vertebræ, where it forms the **perirenal fat.**

The **visceral portion** extends between the folds of the peritoneum, such as the mesentery, transmits the blood-vessels, lymphatics and nerves to the viscera, and assists largely in retaining the abdominal organs in their various positions. Through this portion abscesses arising from the viscera reach the parietal portion of the extraperitoneal connective tissue, in which, as this tissue is lax and offers but slight resistance, they burrow extensively. This is notably true of abscesses produced by appendicitis. These abscesses may burrow from one side of the abdomen to the other, or from one end of the abdomen to the other, and be evacuated above by way of the thorax and respiratory tract, or below by way of the rectum.

Dissection.—The deep circumflex iliac and deep (*inferior*) epigastric arteries can now be traced to their origin through the extraperitoneal connective tissue, and their accompanying veins can be followed to their termination in the

external iliac vein. These arteries and their venæ comites have been previously described.

Hesselbach's triangle can now be observed. It is an important guide and is an aid in remembering that the neck of the sac of a direct inguinal hernia is situated on the medial side of the deep (*inferior*) epigastric artery. The triangle is bounded laterally by the deep (*inferior*) epigastric artery, medially by the lateral border of the rectus muscle, and below by Poupart's (*inguinal*) ligament. All direct inguinal herniæ pass through it.

DISSECTION OF THE ABDOMINAL CAVITY

Dissection.—Expose the cavity of the abdomen and its contents by making an incision from the ensiform cartilage (*xiphoid process*) to the os pubis, keeping slightly to the left of the linea alba and the umbilicus, thus avoiding cutting the round ligament of the liver, which extends from the umbilicus to the longitudinal (*left sagittal*) fissure of the liver, and the urachus, which extends from the summit of the bladder to the umbilicus. A second incision is carried through the umbilicus, and transversely lateralward as far as the lateral edge of the quadratus lumborum muscle. The four flaps thus formed are then turned lateralward. These incisions divide the anterior parietal peritoneum.

Before studying the exposed abdominal viscera *in situ*, the round ligament of the liver, the urachus, the obliterated hypogastric (*umbilical*) arteries, and the inguinal fossæ should be examined.

The **round ligament,** or **ligamentum teres, of the liver** is the obliterated umbilical vein, whose function in the fetus is to carry arterial blood from the placenta. It is a fibrous cord running from the umbilicus within the free border of the falciform ligament to the umbilical notch of the liver, and thence upward in the umbilical, or longitudinal (*left sagittal*), fissure of the liver to join the left branch of the portal vein.

The **urachus,** or **median umbilical ligament,** extends from the summit of the bladder to the umbilicus, and is a remnant of the allantoic stalk. It sometimes remains patulous, causing an **umbilical urinary fistula. Cysts of the urachus** may be mistaken for ovarian cysts.

The **obliterated hypogastric (umbilical) arteries** are two cords which form a ridge upon each side of the urachus, extending from the side of the summit of the bladder to the umbilicus. These are the obliterated hypogastric (*umbilical*) arteries, and it is their function in the fetus to return the venous blood to the placenta. This portion of the obliterated artery is called the **lateral umbilical ligament.** They pass downward along the sides of the bladder, to join the superior vesical arteries. Hemorrhage from these arteries may occur in the infant when the stump of the umbilical cord becomes detached.

The **inguinal fossæ** (**foveæ inguinales**) are three depressions in the internal surface of the peritoneum, situated on the internal surface of the abdominal wall, just above Poupart's (*inguinal*) ligament (Plate CCCXCI).

The **external, or lateral, inguinal fossa** is small, and lies lateral to the deep (*inferior*) epigastric artery. In this location the peritoneum presents a small depression, which is situated at the position of the internal abdominal (*abdominal inguinal*) ring, and is known as the hernial fossa of the peritoneum. Through this fossa an oblique inguinal hernia passes.

The **middle inguinal fossa** is bounded medially by the obliterated hypogastric (*umbilical*) artery; laterally by the deep (*inferior*) epigastric artery, and below by Poupart's (*inguinal*) ligament. Quite a large pouch is frequently found leading from this fossa downward and medialward, behind the obliterated hypogastric (*umbilical*) artery.

The **internal,** or **medial, inguinal,** or **supravesical, fossa** is bounded laterally by the obliterated hypogastric (*umbilical*) artery, medially by the urachus, and inferiorly by the bladder. A direct inguinal hernia passes through either the middle or the internal inguinal fossa.

The abdominal cavity being open, remove the anterior abdominal wall and reflect the anterior parietal peritoneum, which will bring into view some of the organs and more or less of other ones, according to the degree of distention, hypertrophy, collapse, or atrophy of the organs. The *liver* occupies the right hypochondriac and the epigastric regions, and sometimes extends into the left hypochondriac region as far as the left mid-clavicular line. Its right lobe projects slightly below the costal margin. The quadrate lobe and the left lobe extend downward at the subcostal angle to a line from the ninth costal cartilage on the right side, to the eighth cartilage on the left side. The *gall-bladder* is on the under surface of the right lobe of the liver, and its fundus is opposite the intersection of the lateral margin of the right rectus muscle with the costal margin or the lower margin of the ninth costal cartilage. In the left hypochondriac and in the epigastric region a *part of the stomach* is seen extending below the left lobe of the liver and the ribs, depending on the degree of distention. Descending from the stomach and extending beyond the umbilical region is the *greater omentum*, a broad fold of peritoneum which reaches to the pelvis, covers the small intestine, and contains more or less fat; in some cases the greater omentum is so small and shrunken as to be barely visible, thus leaving the small intestine uncovered. If the greater omentum is absent, *the small intestine* will be seen immediately occupying the lower part of the abdomen and part of the pelvis. If *the bladder* is distended, a small part of it will be seen just above the pubes. In the right iliac fossa is the *cecum*, or *caput coli*. If the *appendix* is situated anteriorly to the

PLATE CCCXCI.

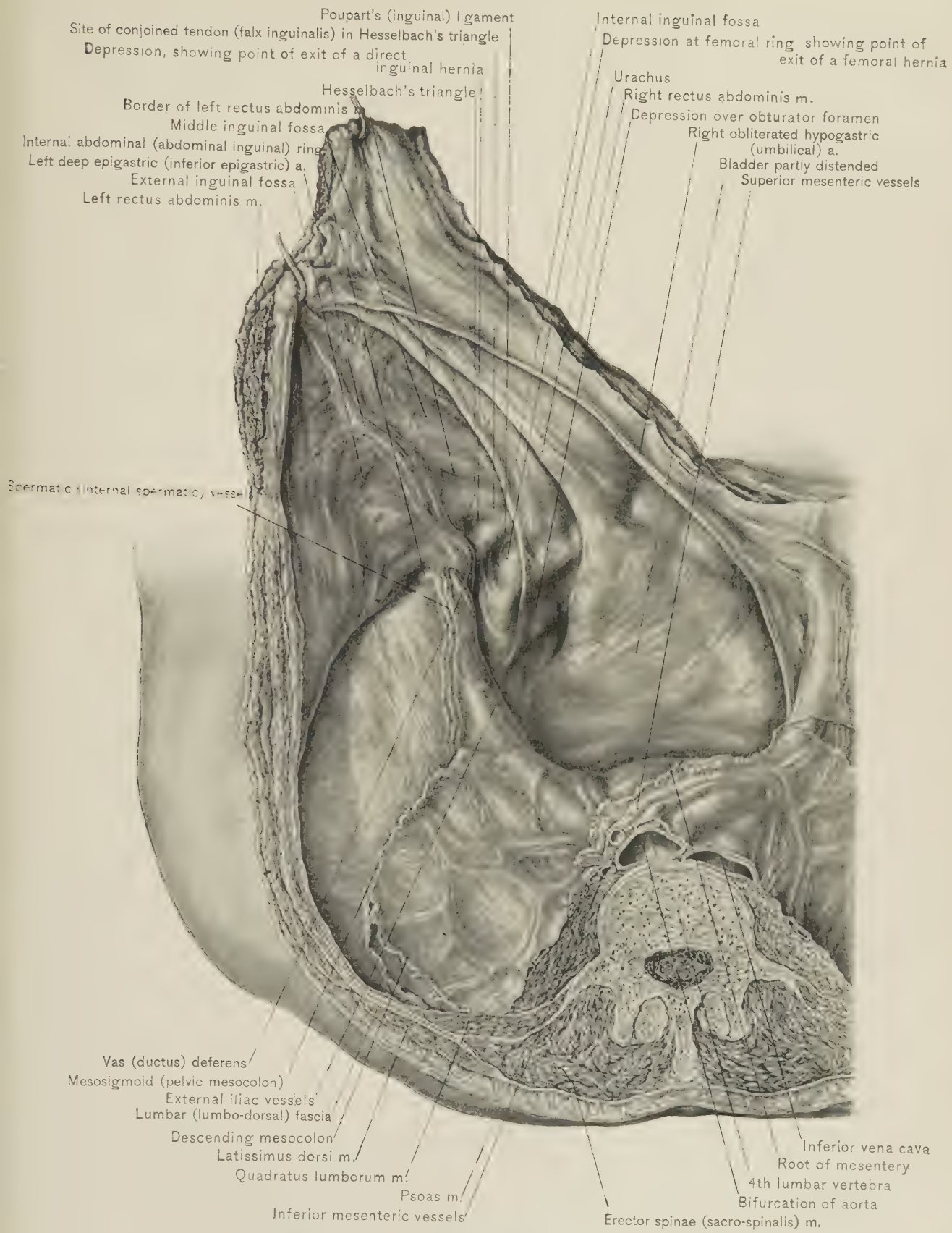
Poupart's (inguinal) ligament
Site of conjoined tendon (falx inguinalis) in Hesselbach's triangle
Depression, showing point of exit of a direct inguinal hernia
Hesselbach's triangle
Border of left rectus abdominis m.
Middle inguinal fossa
Internal abdominal (abdominal inguinal) ring
Left deep epigastric (inferior epigastric) a.
External inguinal fossa
Left rectus abdominis m.
Internal inguinal fossa
Depression at femoral ring showing point of exit of a femoral hernia
Urachus
Right rectus abdominis m.
Depression over obturator foramen
Right obliterated hypogastric (umbilical) a.
Bladder partly distended
Superior mesenteric vessels
Spermatic (internal spermatic) vessels
Vas (ductus) deferens
Mesosigmoid (pelvic mesocolon)
External iliac vessels
Lumbar (lumbo-dorsal) fascia
Descending mesocolon
Latissimus dorsi m.
Quadratus lumborum m.
Psoas m.
Inferior mesenteric vessels
Erector spinae (sacro-spinalis) m.
Inferior vena cava
Root of mesentery
4th lumbar vertebra
Bifurcation of aorta

INGUINAL FOSSÆ.

cecum, one of its unusual positions, it also will be seen without disturbing the viscera. The *ascending colon* in the right, and the *descending colon* in the left lumbar region are usually found contracted and lying at the back of the abdomen, and unless distended, can not be seen upon superficial inspection. The *transverse colon* can usually be seen crossing the abdomen just below the stomach and above the small intestine.

The **abdominal cavity** is the largest cavity in the body, the next in size being the thoracic. These two cavities originally formed the pleuro-peritoneal cavity of the embryo, which was subdivided by the development of the diaphragm. The abdominal cavity is bounded in front and laterally by the lower ribs, the flat muscles of the abdominal wall, and the transversalis fascia; behind by the bodies of the lumbar and sacral vertebræ, the ilium, the iliac and lumbar fasciæ, and the psoas, iliacus, and quadratus lumborum muscles; above by the diaphragm and the diaphragmatic fascia, and below by the tissues which fill the outlet (*inferior opening*) of the pelvis.

Contents.—The abdominal cavity contains all that part of the alimentary canal intervening between the terminal part of the esophagus and the anus, the liver, spleen, kidneys, suprarenal glands, pancreas, many blood-vessels, lymphatics, lymph glands, and nerves. The contents of the pelvic division of the abdominal cavity are the bladder, the uterus and upper portion of the vagina and adnexa in the female, and the lower part of the rectum. It also contains the peritoneum, which facilitates movement of the viscera. The size of the cavity is influenced by the varying conditions of its boundaries. Its depth is lessened by contraction and descent of the diaphragm, and by contraction and ascent of the levatores ani and coccygei muscles; its width is diminished by contraction of the muscles of the anterior and lateral walls of the abdomen.

Owing to the conformation of the viscera to one another and the presence of extraperitoneal fat and a small quantity of serum in the peritoneal cavity, there are no vacant spaces in the abdominal cavity. The gas in the stomach and intestine and the tonic state of contraction of the muscles in the walls of the abdomen produce a varying degree of *intra-abdominal pressure.* In punctured wounds of the intestine the intra-abdominal pressure is believed to be a more important factor in preventing escape of feces into the peritoneal cavity than hernial protrusion of the mucous membrane of the bowel. The cure or temporary improvement following exploratory abdominal section is believed to be due to some influence exercised upon the vessels and nerves of the diseased tissues by change in the intra-abdominal pressure.

The abdominal cavity is composed of two divisions: the abdominal cavity proper, extending between the diaphragm above and the ilio-pectineal lines

below, and the pelvic cavity, the portion below the ilio-pectineal lines. The former may be said to consist of an upper portion, which is above the level of the crests of the ilia, and of a lower portion, the false pelvis (*pelvis major*), which is between the level of the crests of the ilia and that of the ilio-pectineal lines.

The *abdominal cavity proper* is bounded above by the vault of the diaphragmatic fascia; below by the ilio-pectineal lines; in front and laterally by the lower ribs, the flat muscles of the anterior abdominal wall, the ilia, and the transversalis fascia, and behind by the spinal column, the quadratus lumborum, psoas, and iliacus muscles, and the lumbar, psoas, and iliac fasciæ. The *pelvic cavity* is bounded above by the ilio-pectineal lines; below by the tissues filling in the outlet of the pelvis: the recto-vesical fascia, the levatores ani and coccygei muscles, the anal fascia, and the triangular ligament of the perineum (*urogenital diaphragm*); in front and laterally by the pelvic fascia, which covers the pubic bones, the ischia, and obturator internus muscles, and behind by the pelvic fascia, the pyriformes muscles, the sacrum, the coccyx, and the great sacro-sciatic (*sacro-tuberous*) ligaments.

The **openings in the walls of the abdomen** for the passage of structures to and from the abdominal cavity proper are: the umbilicus, which, in the fetus, transmits the umbilical vessels,—the umbilical vein and the two hypogastric, or umbilical, arteries; the quadrate opening in the diaphragm, which gives passage to the inferior vena cava; the aortic opening in the diaphragm, through which pass the aorta, the vena azygos major, and the thoracic duct; the esophageal opening in the diaphragm, through which pass the esophagus and the vagus nerves; two internal abdominal (*abdominal inguinal*) rings, which are situated on each side in the transversalis fascia about one to two centimeters (one-half inch) above, and slightly lateral to the middle of Poupart's (*inguinal*) ligament, and the space beneath Poupart's (*inguinal*) ligament, the femoral arch.

The internal abdominal (*abdominal inguinal*) ring in the male gives passage to the spermatic duct, the spermatic (*internal spermatic*) vessels, the artery of the vas (*ductus*) deferens, the remains of the processus vaginalis, the sympathetic nerves, the lymph vessels, the cremasteric artery, and the genital (*external spermatic*) branch of the genito-crural (*genito-femoral*) nerve; in the female it transmits the round ligament and the genital (*external spermatic*) branch of the genito-crural (*genito-femoral*) nerve. The space beneath Poupart's (*inguinal*) ligament, the crural, or femoral, arch, gives passage to the common femoral vessels, the anterior crural (*femoral*) nerve, the crural (*lumbo-inguinal*) branch of the genito-crural (*genito-femoral*) nerve, the external (*lateral*) cutaneous nerve, the psoas and iliacus muscles, and, sometimes, the accessory obturator nerve.

PLATE CCCXCII.

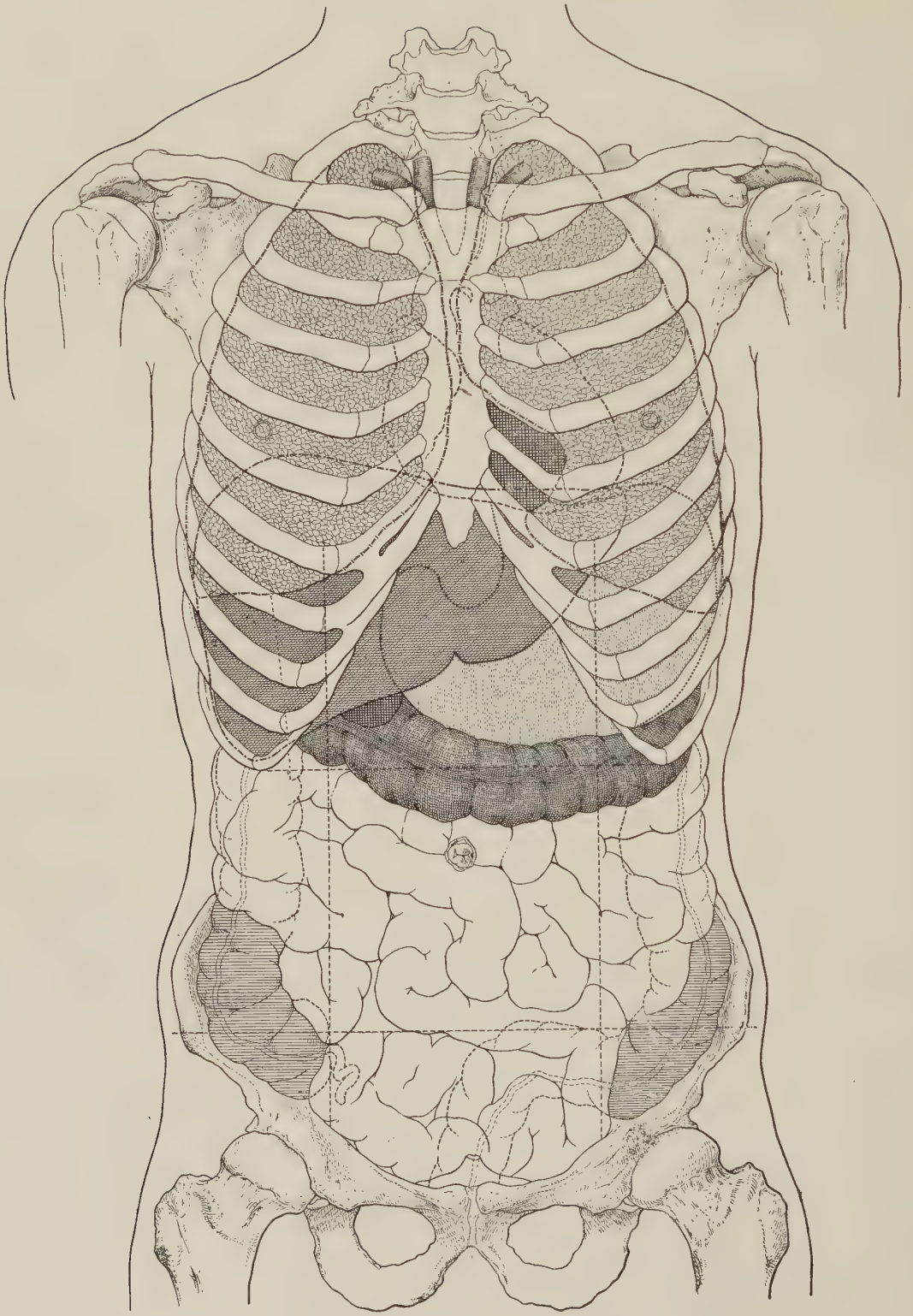

DIAGRAM OF ABDOMINAL VISCERA AND LUNGS. REGIONS OF THE ABDOMEN.

The following table shows the viscera that are found in each abdominal region in a normal individual. It should be remembered that the positions of the abdominal viscera not only vary slightly in different individuals, but that these organs change their positions and relations somewhat with almost every movement of the body. Although the localization of the abdominal viscera, as stated below, can be only approximate, it is of great value in physical diagnosis.

Right Hypochondriac	Epigastric	Left Hypochondriac
Liver (part of right lobe).	Liver (left lobe, quadrate, caudate (*caudate process*), and Spigelian (*caudate*) lobes).	Liver (small portion of left lobe occasionally).
Gall-bladder (divided by the longitudinal line).	Gall-bladder (divided by the longitudinal line).	Spleen.
Kidney (upper and lateral parts).	Stomach (pyloric and middle portions with the cardiac and pyloric orifices).	Pancreas (tail).
Colon (hepatic (*right colic*) flexure and part of ascending colon).	Intestine (first, second, and fourth portions, and the termination of the third portion, of duodenum and part of the transverse colon).	Kidney (upper and lateral parts).
	Pancreas (head and body).	Stomach (cardiac end).
	Kidneys (upper and medial parts, with sinus and pelvis of the ureters).	Colon (splenic (*left colic*) flexure and part of descending colon).
	Suprarenal glands.	
	Spleen (upper and medial parts).	

Longitudinal plane at lateral border of right rectus muscle. — Longitudinal plane at lateral border of left rectus muscle.

Upper transverse plane at level of lowest point in costal border.

Right Lumbar	Umbilical	Left Lumbar
Kidney (lower and lateral parts).	Kidneys (lower and medial portion).	Kidney (lower and lateral parts).
Intestine (ascending colon, part or all of cecum, and part or all of the vermiform appendix. Some small intestine, mostly ileum).	Ureters.	Intestine (small intestine, mostly jejunum; descending colon, and part of the sigmoid flexure).
	Intestines (lowest part of third portion of duodenum; part of jejunum, ileum, and transverse colon, and, usually, part of the sigmoid flexure.	
	Uterus in pregnancy.	

Lower transverse plane through anterior superior spines of ilia.

Right Iliac	Hypogastric	Left Iliac
Intestine (small intestine, mostly ileum; sometimes the tip of the cecum and part or all of the vermiform appendix).	Intestine (jejunum and ileum of small intestine, and part of the sigmoid flexure).	Intestine (small intestine and part of the sigmoid flexure).
	Ureters.	
	Bladder (in children and, when distended, in adults).	
	Uterus in pregnancy.	

Regions of the Abdomen (Plate CCCXCII).—For convenience in locating its contained organs, the general abdominal cavity is divided into nine regions by planes indicated by lines drawn on the surface of the body (see Table, p. 335). Although these lines have been drawn in various ways, the following method seems to be the most desirable. The regions outlined are only of general use in describing the location of a mass or viscus. Two transverse circular lines are drawn around the body. One passes through the lowest point on the inferior costal border, which is usually the lower margin of the eleventh, sometimes of the tenth, costal cartilage (transpyloric plane), and the other through the anterior superior spines of the ilia. These divide the abdominal cavity into three segments. Each of these is subdivided into three parts by two planes passing through two lines which are drawn over the vertical portions of the lateral borders of the two rectus muscles; these lines correspond practically to lines drawn vertically upward from the middle of Poupart's (*inguinal*) ligament. The three regions in the median line, named from above downward, are the epigastric, umbilical, and hypogastric regions; those on each side are the hypochondriac, lumbar, and iliac regions.

The **peritoneum** is the serous membrane which lines the walls of the abdominal cavity, and more or less completely covers the viscera within that cavity, as well as the processes of the extraperitoneal connective tissue that transmit the vessels and nerves to the viscera. Its inner mesothelial surface is smooth and glossy; its deeper layer, the tunica propria, is fibro-elastic tissue and is attached to the abdominal walls and viscera by the extraperitoneal connective tissue. Its surface area, together with its reflections and folds, almost equals that of the integument of the body; it is the most extensive serous surface in the body. In the male it forms a closed sac, but in the female it has an orifice of communication with the exterior of the body at the fimbriated extremity of the Fallopian (*uterine*) tube, where the lumen of the tube communicates with the peritoneal cavity. Its arrangement is more complicated than that of other serous membranes, each of which is in relation with one viscus, whereas the peritoneum is in relation with a number of viscera, over and partially around which it passes.

The peritoneum is divided into a **parietal portion,** in relation with the walls of the abdominal cavity, and a **visceral portion,** in relation with the viscera.

The **peritoneal sac** is a large lymph-space which acts as a bursa for the abdominal viscera and the abdominal wall, permitting their movement without friction. Within this sac is a small quantity of serous fluid, which is distributed over the internal surface of the peritoneum and should be sufficient to lubricate that surface of the membrane. This fluid is constantly carried away by lymph vessels which are in free communication with the inner surface of the peritoneum

between the endothelial cells lining that surface. These lymphatics eventually empty into the receptaculum chyli (*cisterna chyli*). Obstruction of the thoracic duct therefore is one of the causes of **ascites,** or excess of peritoneal fluid. Ascites is caused also by any of the common causes of edema, by obstruction of the portal vein, or by chronic peritonitis.

The absorptive power of the peritoneum is one of its chief characteristics. The great rapidity with which material can be absorbed from the peritoneal cavity is explained partly by the bountiful supply of lymph vessels which drain the inner surface of the peritoneum, and partly by the extensive area of the membrane thus so freely drained.

Owing to the great absorptive power of the peritoneum, toxemia is more likely to follow and occurs much earlier after the introduction of infectious matter into the peritoneal sac than into the pleural sac or other serous cavities. This is explained partly by the greater area of the peritoneum and partly by the tendency of the more movable contents of the abdomen to disseminate the infectious matter. Absorption through the stomata of the subperitoneal lymph vessels on the abdominal surface of the diaphragm is very rapid, and for this reason the sitting posture after operation or when peritonitis is present is used to let septic material drain to the pelvis. The portion of the peritoneum in relation with the small intestine is more sensitive to infection than other portions, on account of the tendency of the small bowel to spread the infection by movement.

Localized **peritonitis** is more apt to exist in those regions which are not occupied by coils of small intestine, as between the diaphragm and the level of the transverse colon, on the lateral side of the cecum, and in the pelvis. This explains why peritonitis of perihepatic inflammation, appendicitis, or salpingitis is often circumscribed and not necessarily fatal.

Pus in relation with the fibrous surface of the peritoneum, as in perinephritic abscess, is unlikely to cause diffuse peritonitis unless it ruptures into the peritoneal cavity, not only because it cannot spread rapidly over a large area of the peritoneum but also because of the lower absorptive power and lesser susceptibility of this portion of the peritoneum. Infectious matter on the external surface of the peritoneum is less likely to cause rapid septic intoxication than on its internal surface because in the latter case the infectious matter will be widely distributed over the peritoneum if it comes into contact with the jejunum or ileum; also because a more extensive surface offers greater opportunity for absorption, and the area of peritoneum in relation with the small intestine and mesentery is extensive. The parietal portion of the peritoneum is also less vulnerable to infection than the visceral portion.

Peritonitis may lead to the development of various forms of connective-tissue bands or adhesions, beneath which a loop of intestine may become strangulated.

The peritoneum admits of great stretching, provided the force is applied gradually. This is seen in the development of abdominal herniæ, especially of the umbilical variety, in which a circumscribed portion of the peritoneum is stretched to form the sac of the hernia. The sudden application of force to the peritoneum ruptures it. The parietal portion of the peritoneum may be ruptured with or without injury to the viscera.

Attachments of the peritoneum.—The loose attachment of the peritoneum, except at the umbilicus and the diaphragm, explains the readiness with which pus from a hepatic abscess rupturing extraperitoneally finds its way to the linea alba through the subperitoneal connective tissue between the transversalis fascia and peritoneum; or how a perinephritic abscess may burrow under the peritoneum, finally to reach the opposite side of the vertebral column. The ease with which the peritoneum can be stripped up from the iliac fossa in ligating the external iliac artery or in exposing the ureter is another demonstration of the same fact. Its attachment to the abdominal walls is not very firm, except in two locations—the lower surface of the diaphragm and the region immediately surrounding the umbilicus. The sac of an umbilical hernia is not, therefore, formed so much by a protrusion of the peritoneum as by a gradual thinning of a circumscribed portion of the membrane immediately in relation with the umbilicus. The sac of an umbilical hernia may almost entirely disappear from this cause. It is more difficult to free the neck of the sac in performing an operation for the radical cure of this form of hernia than of other forms, on account of the adherence of the peritoneum, the transversalis fascia, and the transversalis aponeurosis at the umbilicus.

The **peritoneal cavity** is the cavity enclosed by the peritoneum, and is divided into the greater peritoneal cavity (*great sac*) and the lesser peritoneal cavity (*omental bursa*), which communicate with each other through a narrow passage—the foramen of Winslow (*epiploic foramen*). It contains a small quantity of serum, whose function it is to lubricate these layers in order to prevent friction during peristalsis. None of the abdominal viscera is in the peritoneal cavity, as the peritoneum is reflected over or partially around the organs.

Reflections of the peritoneum.—Besides forming a complete or partial covering for nearly all the abdominal viscera, in certain situations the peritoneum is reflected from one organ to another and from the organs to the walls of the abdomen, thus forming reflections or folds which receive special names according

PLATE CCCXCIII.

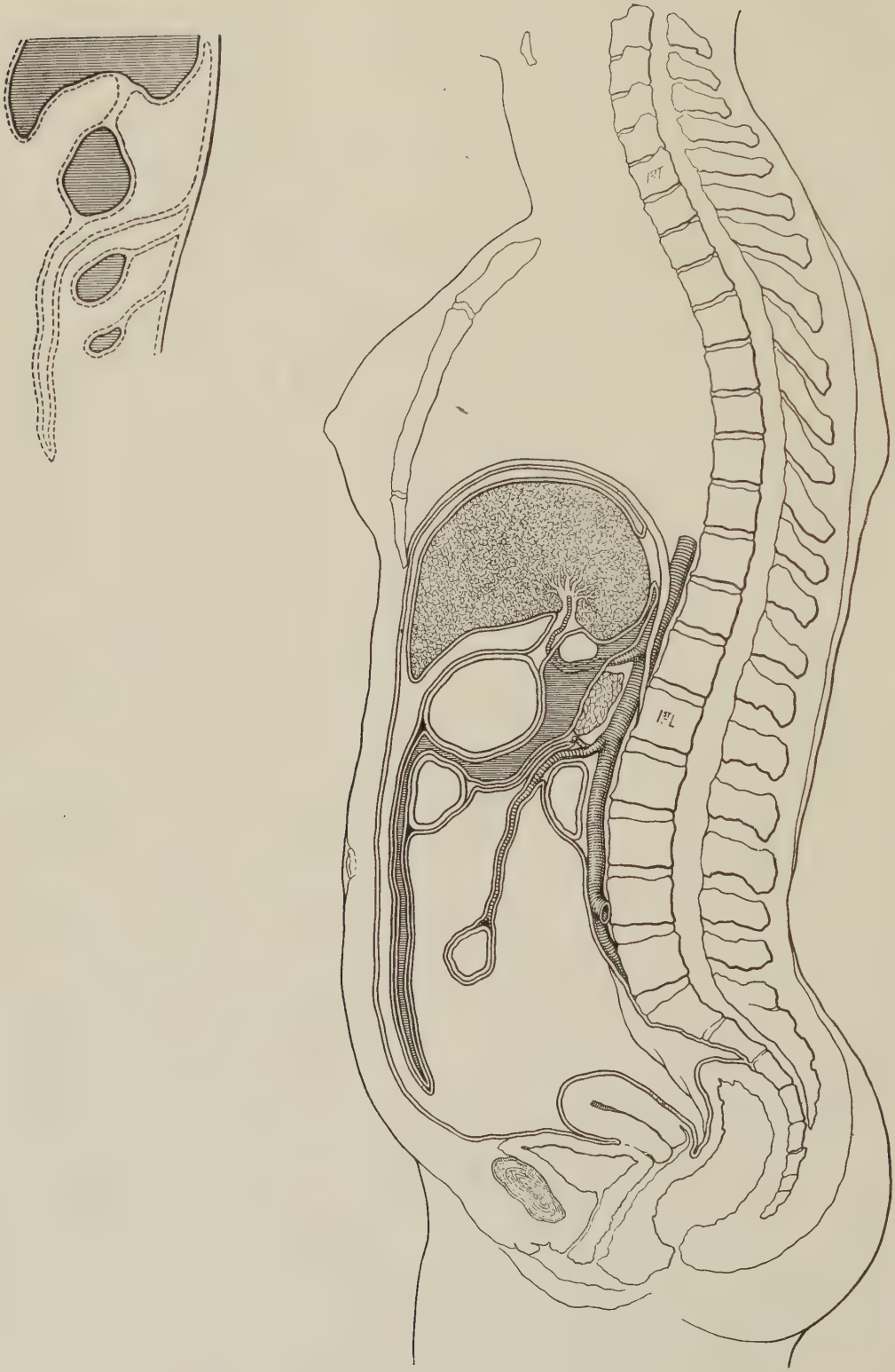

PERITONEUM TRACED VERTICALLY IN THE FETUS AND THE ADULT.

to their location, such as the mesentery, omentum, mesocolon, and certain ligaments.

Being a continuous membrane, the peritoneum can be traced both vertically and transversely.

Vertical course of the peritoneum (Plate CCCXCIII).—In tracing the peritoneum vertically a convenient point from which to start is the transverse fissure (*porta hepatis*) of the liver. With the liver drawn upward and lateralward, by grasping its lower edge with one hand while with the other the stomach is carried downward and to the left, a double fold, the gastro-hepatic, or lesser, omentum, is seen to descend to the lesser curvature of the stomach, and is stretched between these two organs. Reaching the stomach, the two layers separate to inclose that organ, one layer passing in front of it and the other behind it. At the greater curvature they again meet, and pass downward, like an apron, to the lower part of the abdomen, forming the two anterior layers of the greater omentum; they then turn on themselves and ascend to the transverse colon, this last reflection forming the two posterior layers of the greater omentum. They again separate and inclose this portion of the colon, one layer passing above and one beneath it. Along the posterior surface of the transverse colon these two layers again meet and form the transverse mesocolon, which passes to the posterior wall of the abdominal cavity; opposite the lower border of the pancreas they divide into an ascending and a descending layer. The ascending layer passes in front of the pancreas, the second portion of the duodenum, and the crura of the diaphragm, and then to the under surface of the diaphragm, from which it is reflected to the posterior surface of the liver, forming the inferior layer of its coronary and lateral (*triangular*) ligaments, and then to the under surface of the liver, as far as the transverse fissure (*porta hepatis*), the point of starting. Here it is continuous with the posterior layer of the lesser, or gastro-hepatic, omentum. The descending layer of the transverse mesocolon passes over the third portion of the duodenum, the posterior abdominal wall, and the superior mesenteric vessels to the jejunum and ileum, both of which it surrounds, and back again to the posterior part of the abdominal cavity, forming the mesentery. Thence it descends, passing in front of the aorta and inferior vena cava into the pelvis, and, surrounding the sigmoid flexure of the colon, connects it with the posterior part of the pelvic cavity by the mesosigmoid (*pelvic mesocolon*). It covers the anterior surface of the first portion of the rectum, from which, in the male, it is reflected upon the posterior wall and sides of the bladder, forming the posterior (*sacro-genital folds*) and lateral false ligaments of the bladder and the recto-vesical pouch.

In the male the sides of the **recto-vesical pouch** are formed by the posterior false ligaments (*sacro-genital folds*) of the bladder. The depth of the pouch

varies with the distention of the bladder, which, when full, carries the floor of the pouch up with it, thus lessening its depth. When the bladder is empty, the floor of the pouch is five centimeters (two inches) from the anus; when the bladder is distended, the floor of the pouch is carried about five centimeters higher, or to about ten centimeters (four inches) from the anus.

In the female the peritoneum is reflected from the rectum to the upper part of the vagina, and then covers the sides, back, summit, and slightly more than the upper half of the front of the uterus, forming the **recto-uterine pouch,** or **Douglas' pouch.** The folds of peritoneum forming the sides of Douglas' pouch are the recto-uterine folds, or posterior false ligaments of the uterus; they contain the utero-sacral ligaments, which are composed of muscular and connective tissue. From the sides of the uterus, as well as from the upper part of the posterior wall of the vagina, which it covers, the peritoneum is reflected to the sides of the pelvis, forming the lateral, or broad, ligaments of the uterus. From the sides and front of the uterus it is reflected to the sides and posterior wall of the bladder, forming the **utero-vesical pouch,** and from the sides and summit of the bladder it passes as in the male. The folds of peritoneum forming the sides of the utero-vesical pouch are the anterior false ligaments of the uterus, the utero-vesical false ligaments, or the posterior false ligaments of the bladder.

From the summit and sides of the bladder the peritoneum passes to the anterior and lateral abdominal walls. It is continued upward anteriorly, and lines the anterior wall of the abdomen and the under surface of the diaphragm, from the latter of which it is reflected upon the posterior surface of the liver, forming the superior layer of the coronary and lateral (*triangular*) ligaments of the liver. Thence it passes over the superior surface of the liver and around the anterior border to the under surface of that organ, where, at the transverse fissure (*porta hepatis*), the point of starting, it is continuous with the anterior layer of the lesser omentum.

In tracing the peritoneum in this manner it will be seen that the anterior layer forms the walls of the greater peritoneal cavity (*great sac*), while the posterior layer forms the walls of the lesser peritoneal cavity (*omental bursa*).

Transverse course of the peritoneum.—The peritoneum should be traced transversely at two levels—above and below the level of the transverse colon. In each instance start at the median line of the anterior abdominal wall, and begin to trace the peritoneum toward the right side.

Below the level of the transverse colon (Plate CCCXCIV), starting at the median line and tracing the peritoneum to the right, it will be seen to cover the internal surface of the abdominal wall nearly as far as the lateral border of the quadratus lumborum muscle, whence it is reflected upon the medial, anterior, and

PLATE CCCXCIV.

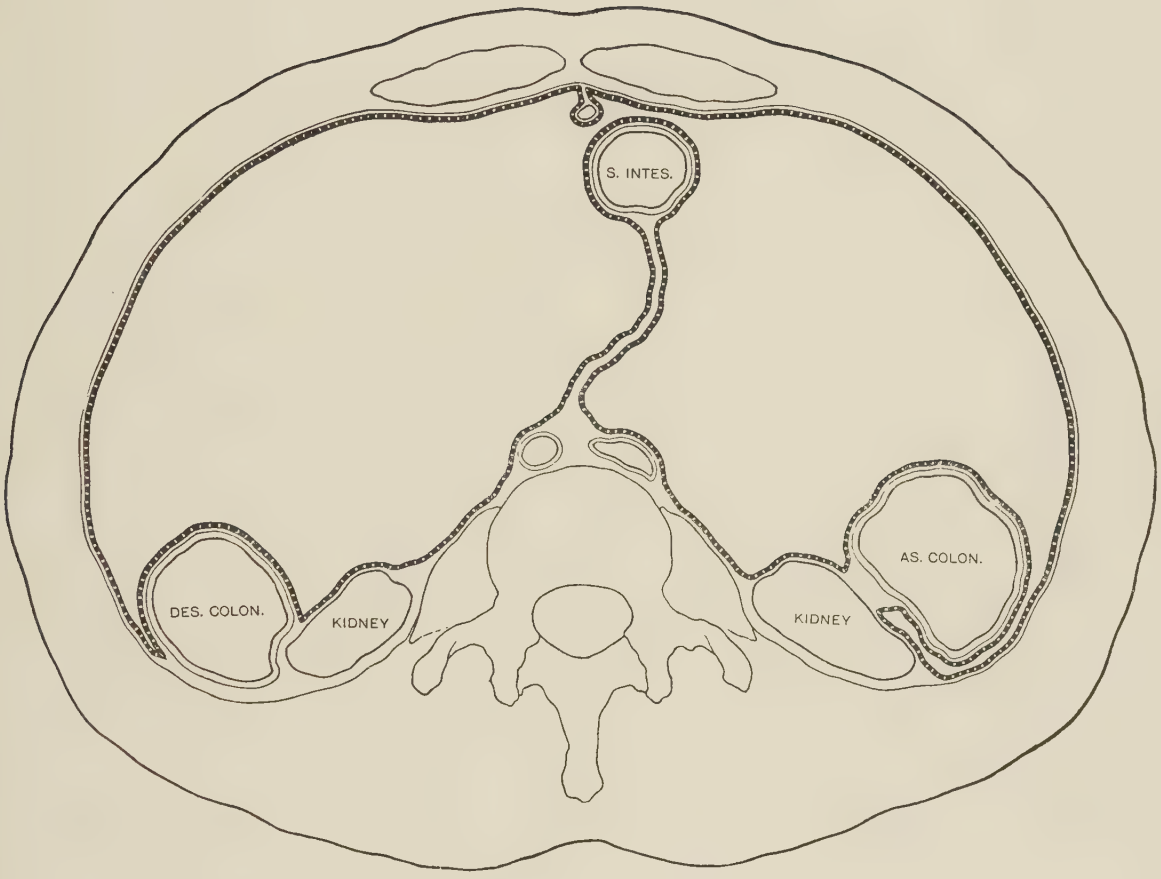

PERITONEUM TRACED BELOW THE LEVEL OF THE TRANSVERSE COLON.

PLATE CCCXCV.

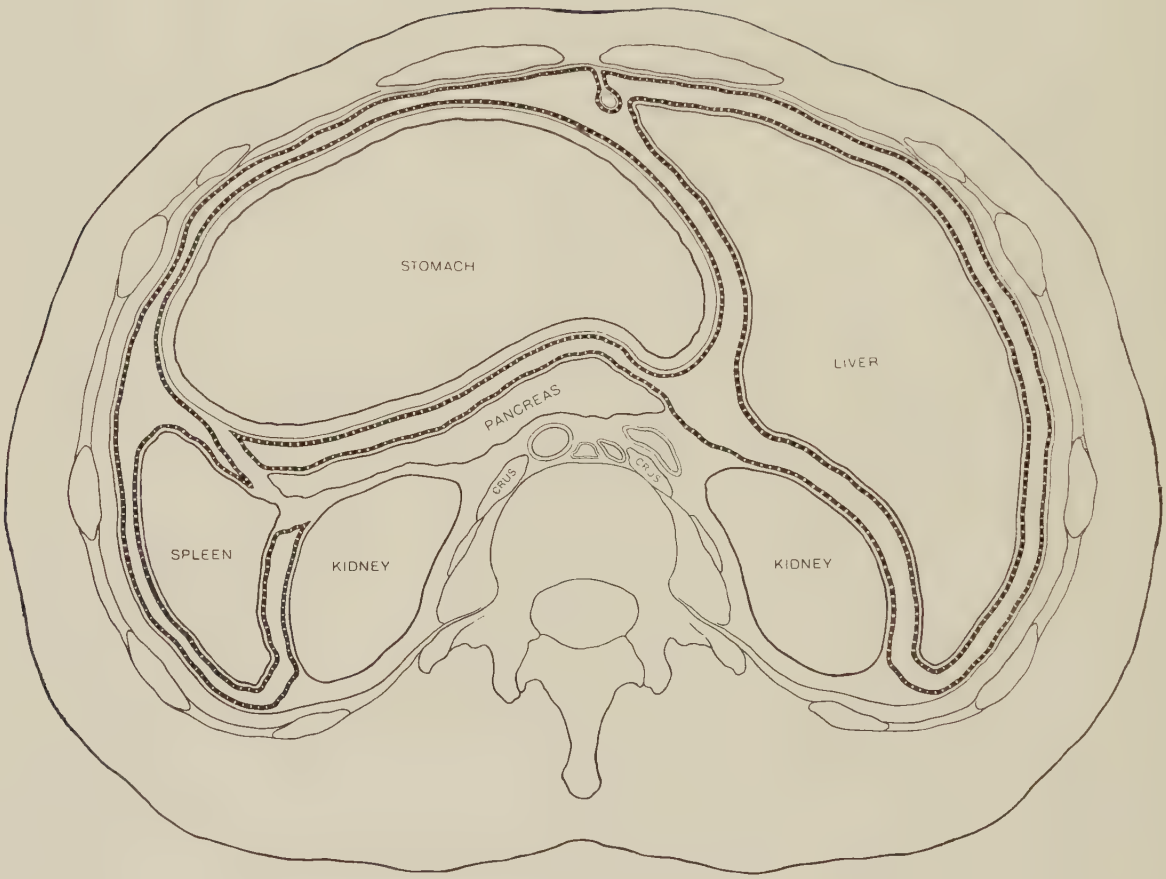

PERITONEUM TRACED ABOVE THE LEVEL OF THE TRANSVERSE COLON.

PLATE CCCXCVI.

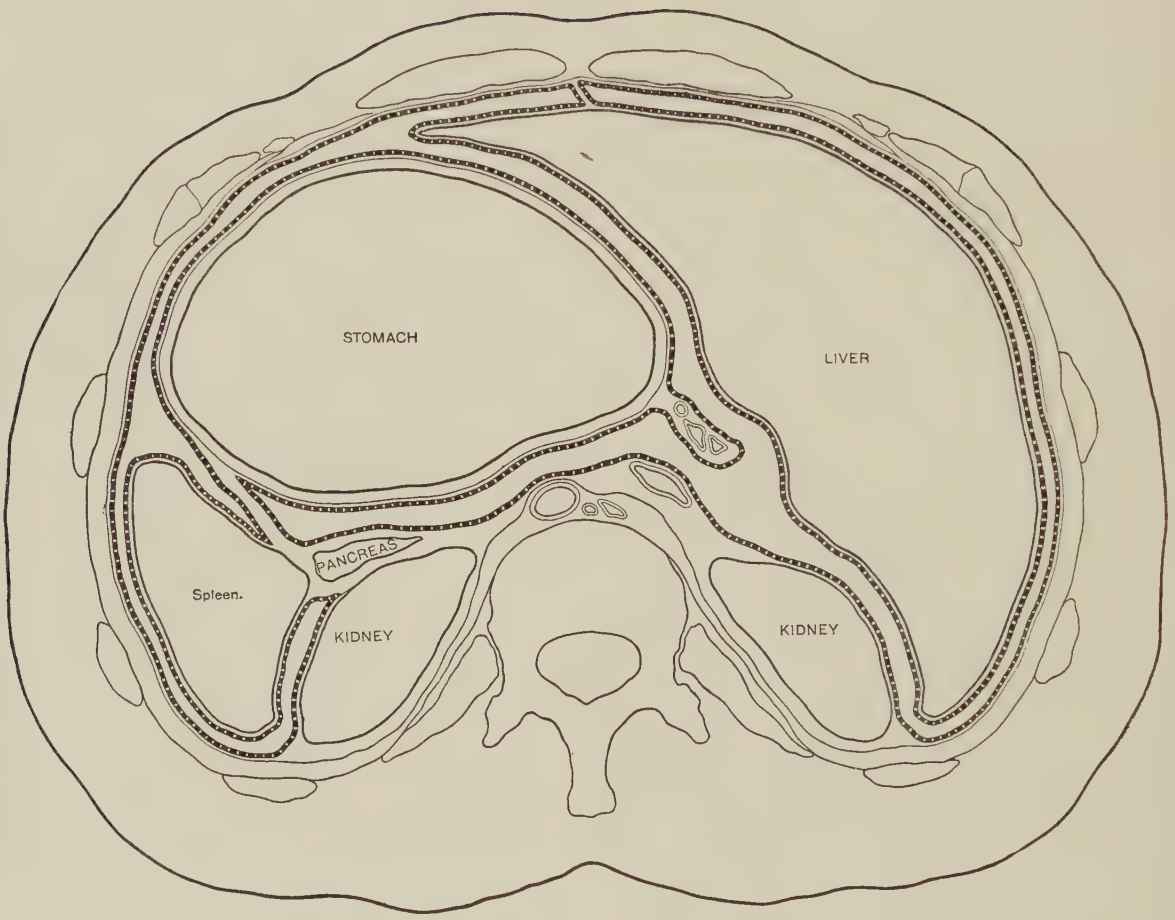

PERITONEUM TRACED AT THE LEVEL OF THE FORAMEN OF WINSLOW (EPIPLOIC FORAMEN).

lateral surfaces of the ascending colon, forming the ascending mesocolon. Having returned from the ascending colon to the posterior abdominal wall, it passes in front of the right kidney, superior mesenteric vessels, inferior vena cava, and duodenum. It is then reflected around the jejunum and ileum, and returns to the posterior abdominal wall, forming the mesentery. From the root of the mesentery it passes to the left, in front of the aorta, inferior mesenteric vessels, and left kidney, and is reflected over the sides and front of the descending colon, forming the descending mesocolon. Below it envelops the sigmoid flexure and returns to the posterior abdominal wall, forming the mesosigmoid (*pelvic mesocolon*). From the descending colon it passes along the lateral and anterior abdominal wall to reach the midline, the starting point.

Above the transverse colon, and at the level of the foramen of Winslow (*epiploic foramen*) (Plates CCCXCV; CCCXCVI), or at the level of the first lumbar vertebra, beginning at the median line and tracing it to the right, the peritoneum is reflected around the round ligament of the liver, forming part of the falciform, or broad, ligament of that organ. Thence it follows the abdominal wall, covering the right kidney, pancreas, inferior vena cava, aorta, and part of the left kidney. It passes from the anterior surface of the left kidney to the anterior surface of the spleen, just in front of the hilum, forming the right layer of the lieno-renal ligament, and thence to the cardiac end of the stomach, forming the posterior layer of the gastro-splenic omentum, or ligament. It passes over the posterior surface of the stomach to its pyloric extremity, where it turns around the first portion of the duodenum. In turning just above the level of the duodenum it forms the right or free border of the lesser, or gastro-hepatic, omentum, and incloses the hepatic, cystic, and common bile ducts, the hepatic artery, and the portal vein. It next follows the anterior surface of the stomach to its cardiae end, whence it passes to the anterior surface of the spleen, just in front of the hilum, forming the anterior layer of the gastro-splenic omentum. From the anterior margin of the hilum of the spleen it passes around that organ to the posterior margin of the hilum, and again to the posterior abdominal wall, to the front of the left kidney, forming the left layer of the lieno-renal ligament. From this position it passes over the lateral portion of the kidney and follows the abdominal wall to the median line to the point of starting.

The portions of the peritoneum inclosing each peritoneal cavity may also be traced separately in a vertical direction. To trace the portion of the **peritoneum in relation with the greater peritoneal cavity** (**great sac**)begin, as before, at the transverse fissure (*porta hepatis*) of the liver. From the transverse fissure (*porta hepatis*) of the liver the peritoneum passes to the lesser curvature of the stomach, forming the anterior layer of the gastro-hepatic, or lesser, omentum. It covers

the anterior surface of the stomach, and descends from the greater curvature of that organ, forming part of the anterior layer of the greater omentum. The portion extending to the transverse colon is frequently spoken of as the gastro-colic omentum. At the lower border of the greater omentum it turns upward to the transverse colon, forming part of the posterior layer of the greater omentum. It passes under the transverse colon and thence to the posterior abdominal wall, in the region of the body of the pancreas, forming the inferior layer of the transverse mesocolon. It next descends, on the posterior abdominal wall, in front of the transverse portion of the duodenum, the aorta, the inferior vena cava, and the superior mesenteric vessels, and is reflected around the ileum and jejunum and back to the abdominal wall, forming the two layers of the mesentery. It then runs over the aorta, the inferior vena cava, and inferior mesenteric vessels to the pelvis, where it envelops the termination of the sigmoid flexure, and covers the anterior surface of the first portion of the rectum, from which, in the male, it is reflected upon the posterior surface of the bladder, forming the floor of the recto-vesical pouch. In the female it is reflected from the rectum upon the upper portion of the posterior wall of the vagina and thence to the uterus, forming the floor of the recto-uterine, or Douglas', pouch. It passes around the uterus to its anterior surface, forming the broad ligaments at its sides. From the anterior aspect of the uterus it passes to the bladder, forming the utero-vesical pouch. In both sexes it covers the posterior surface, sides and a portion of the fundus of the bladder, and follows the anterior abdominal wall to the diaphragm, from the posterior part of which it descends to the liver, forming the anterior, or superior, layer of the coronary and lateral (*triangular*) ligaments of the liver. Thence it passes around the anterior aspect of the liver to the transverse fissure (*porta hepatis*), the point of starting.

The **peritoneum bounding the lesser peritoneal cavity** (**omental bursa**) is traced from the transverse fissure (*porta hepatis*) of the liver to the lesser curvature of the stomach, forming the posterior layer of the lesser, or gastro-hepatic, omentum. It follows the posterior surface of the stomach to its greater curvature, from which it descends in front of the transverse colon, forming the inner part of the anterior layer of the greater omentum. It turns within the lower border of the greater omentum, and ascends to the transverse colon, forming the internal part of the posterior layer of the greater omentum. It next runs in front of the transverse colon to the posterior abdominal wall, forming the upper layer of the transverse mesocolon. Thence it passes upward on the posterior abdominal wall, over the pancreas and great vessels to the diaphragm, from which it descends to the liver, forming the posterior or inferior layer of the coronary and lateral (*triangular*) ligaments of that organ. It next passes along

the under surface of the liver to the transverse fissure (*porta hepatis*), the starting point.

In the fetus the peritoneum of the greater peritoneal cavity (*great sac*), in relation with the transverse colon, takes a slightly different course. Beginning at the greater curvature of the stomach, it is traced downward, forming the outer part of the anterior layer of the greater omentum. It turns at the lower border of that omentum and ascends, forming the outer part of the posterior layer of the greater omentum. It next passes in front and free of the transverse colon to the posterior abdominal wall, at about the level of the pancreas, whence it turns downward to envelop the transverse colon and returns to the posterior abdominal wall, forming the transverse mesocolon. Below this point it takes the same course as in the adult. From this description it will be seen that the two layers of peritoneum forming the posterior layer of the greater omentum lie in front of the upper layer of the transverse mesocolon. In the adult these two layers become adherent to the colon and transverse mesocolon, so that the upper layer of this mesocolon is really composed of three layers of peritoneum.

This is easily understood if the embryology of the peritoneum is reviewed. The posterior layer of the greater omentum is the left layer of the original mesogastrium. It has no embryological connection with the transverse mesocolon, simply lying adjacent to it and fusing with it at about the time of birth.

The **lesser peritoneal cavity** (**omental bursa**), or the cavity of the greater omentum, is surrounded by the ascending and the descending layers of the greater omentum which, however, are usually fused in the adult, the lesser omentum, the transverse mesocolon, and that portion of the peritoneum which covers the posterior abdominal wall above the transverse mesocolon. It is bounded in front by the lobus Spigelii (*caudate lobe*), the lesser omentum, the stomach, the gastro-splenic omentum, and the descending layers of the greater omentum; behind by the ascending layers of the greater omentum, the transverse colon, the transverse mesocolon, and the peritoneum covering the pancreas, great vessels, left kidney, and suprarenal gland; above by the lobus Spigelii (*caudate lobe*) of the liver and by the diaphragm, and below by the turn of the greater omentum. On the left side it is limited by the spleen and the lieno-renal ligament and the junction of the anterior and posterior layers of the greater omentum.

The **greater peritoneal cavity,** or **great sac,** is the space seen after dividing the anterior parietal peritoneum. It is separated from the lesser peritoneal cavity (*omental bursa*) by the liver, the lesser omentum, stomach, greater omentum, gastro-splenic omentum, lieno-renal ligament, and the transverse mesocolon. It is usually said to communicate with the lesser cavity (*omental bursa*)

through the foramen of Winslow (*epiploic foramen*). This is however not the true entrance to the lesser cavity (*omental bursa*). Because of the median position of the original mesentery the opening could not be on the right of the median line. The true communication is contracted and is indicated by the median vertical fold of the original mesogastrium. This is known as the plica gastropancreatica and is made by the mesogastrium over the coronary (*left gastric*) artery as it arises from the celiac axis (*celiac artery*) to find its way to the cardiac orifice of the stomach. To the left of this fold is the lesser cavity (*omental bursa*) proper, while to the right and extending to the foramen of Winslow (*epiploic foramen*) is the vestibule to the lesser cavity (*omental bursa*).

The **foramen of Winslow** (**epiploic foramen**) may be located by drawing the liver upward and the stomach downward, and then carrying the finger behind the right, or free, border of the gastro-hepatic omentum, found just below the neck of the gall-bladder. This foramen is bounded anteriorly by the right, free border of the duodeno-hepatic ligament, the fold forming the right termination of the lesser omentum, between the two layers of which are the hepatic artery, the portal vein, and the hepatic duct; posteriorly, by the inferior vena cava, which is covered by the peritoneum; superiorly by the caudate lobe (*caudate process*) of the liver, and inferiorly, by the first portion of the duodenum and the hepatic artery, curving forward from the celiac axis (*celiac artery*). In the new-born child, before the layers of the greater omentum have become adherent, the lesser peritoneal cavity can be inflated by means of a blow-pipe introduced through the foramen of Winslow (*epiploic foramen*). When the foramen of Winslow (*epiploic foramen*) becomes closed by adhesive inflammation, the usual free communication between the two peritoneal cavities does not exist.

Hernia through the foramen of Winslow (*epiploic foramen*), one of the varieties of internal hernia, is not very frequent.

The **viscera almost entirely surrounded by the peritoneum** are: the liver, stomach, spleen, first portion of the duodenum, the jejunum, ileum, cecum, vermiform appendix, transverse colon, sigmoid flexure, and ovaries. Wounds and perforations of these organs almost invariably involve the peritoneum. Exceptions to this rule occur in perforations of the appendix near its base and along the attachment of the meso-appendix, and in wounds and abscesses involving the nonperitoneal portion of the posterior surface of the liver.

The **viscera partially surrounded by the peritoneum** are: the descending, the transverse, and the terminal ascending portion of the duodenum, the ascending and the descending colon, the first portion of the rectum, the vagina, the uterus, and the bladder. Wounds or perforations of these organs do not necessarily involve the peritoneum.

The **viscera which have no peritoneal covering** are: the second, or lower, portion of the rectum, the pancreas, the kidneys, and the suprarenal glands. It should also be noted that the neck, base, and anterior wall of the bladder and the anterior wall and the lower part of the posterior wall of the vagina are not covered by peritoneum. The organs which are behind the peritoneum, or the retroperitoneal structures, are the kidneys, the suprarenal glands, and the pancreas. These retroperitoneal organs can be wounded without inflicting injury to the peritoneum, and inflammatory diseases of these organs are unlikely to cause peritonitis, the pancreas being a notable exception.

The several **processes,** or **folds, of the peritoneum** extending between the various viscera and between the viscera and the abdominal walls are known as ligaments, omenta, mesenteries, or mesocolons. Their function is twofold: to hold the viscera in position and, as in the case of the omenta, the mesentery, the mesocolons, and the ligaments in the pelvis, to transmit vessels and nerves between their layers.

The **peritoneal ligaments** in the abdominal cavity proper are the suspensory (*falciform*), the lateral (*triangular*), and the coronary ligaments of the liver, the phrenico-splenic, or suspensory, ligament of the spleen and the lieno-renal, the gastro-phrenic, and the phrenico-colic ligaments.

The **suspensory,** or **falciform, ligament of the liver** extends from the upper convex surface of the liver to the diaphragm and the anterior abdominal wall. It is attached by its convex border to the diaphragm and the posterior surface of the sheath of the right rectus muscle as low down as the umbilicus, and by its lower concave border to the upper surface of the liver, between the anterior and posterior margins. Posteriorly, it is continuous with the coronary and lateral (*triangular*) ligaments of the liver. Its free border, which extends from the umbilicus to the anterior border of the liver, contains the round ligament between its two layers.

Of the **lateral** (**triangular**) **ligaments of the liver,** the left is much larger than the right. The right ligament is a small fold extending from the right extremity of the posterior nonperitoneal surface of the liver to the diaphragm; the left ligament passes from the posterior portion of the superior surface of the left lobe of the liver to the inferior surface of the diaphragm on the left of the esophageal opening and above the spleen.

The **coronary ligament of the liver** is situated at the junction of the lateral (*triangular*) and suspensory (*falciform*) ligaments, and consists of two layers which are separated from each other by a space equal to the breadth of the nonperitoneal area of the posterior surface of the liver.

The **suspensory ligament of the spleen,** an inconstant fold of peritoneum extending from the diaphragm near the esophageal opening to the top of the spleen, is a portion of the lieno-renal ligament extending between the upper border of the spleen and the diaphragm.

The **lieno-renal ligament** passes from the hilum of the spleen to the front of the left kidney; between its two layers are the splenic vessels, nerves, and lymphatics, and the tail of the pancreas.

The **gastro-phrenic ligament** is a small fold of peritoneum running between the diaphragm and the cardiac end of the stomach to the left of the esophagus.

The **phrenico-colic ligament** is a fold of peritoneum which extends from the splenic (*left colic*) flexure of the colon to the diaphragm, opposite the tenth and eleventh ribs.

The **peritoneal,** or **false, ligaments of the bladder** have little to do with the actual support of the bladder. They consist of two lateral, and a superior, or anterior, ligament. The peritoneum, as it is reflected from the superior surface of the bladder to the pelvic wall on either side, forms lateral folds, the lateral false ligaments. The lateral ligaments are continuous anteriorly at the bladder apex and as they cover the fibrous cord of the urachus (*the median umbilical ligament*) they form the superior, or anterior, false ligament, running from the apex of the bladder to the umbilicus. The term *posterior false ligament* (*sacro-genital fold*) is sometimes applied to a crescentic-peritoneal fold around the genito-rectal pouch which often joins the fold of the opposite side in the midline behind the posterior border of the bladder and the vasa deferentia (*ductus deferentes*).

The **omenta** are three folds of peritoneum which connect the stomach with adjacent viscera: the gastro-colic, or greater, omentum, the gastro-hepatic, or lesser, omentum, and the gastro-splenic omentum.

The **gastro-colic,** or **greater, omentum** (Plate CCCXCVII), the largest of all the peritoneal folds, is suspended from the greater curvature of the stomach and the free border of the transverse colon. It usually covers the small intestine as far as the pelvis, extending almost to the summit of the bladder. It consists of a double descending and a double ascending layer; between these layers is a large part of the lesser peritoneal cavity (*omental bursa*), which is, therefore, sometimes called the cavity of the greater omentum. The layers however are usually adherent, so the greater part of the cavity is obliterated. Between the two layers of the descending, or anterior, layer of the greater omentum, along the greater curvature of the stomach, is the arterial loop formed by the anastomosis between the right and left gastro-epiploic arteries. In corpulent persons the greater omentum contains a large quantity of fat, while in thin subjects it is thin

PLATE CCCXCVII.

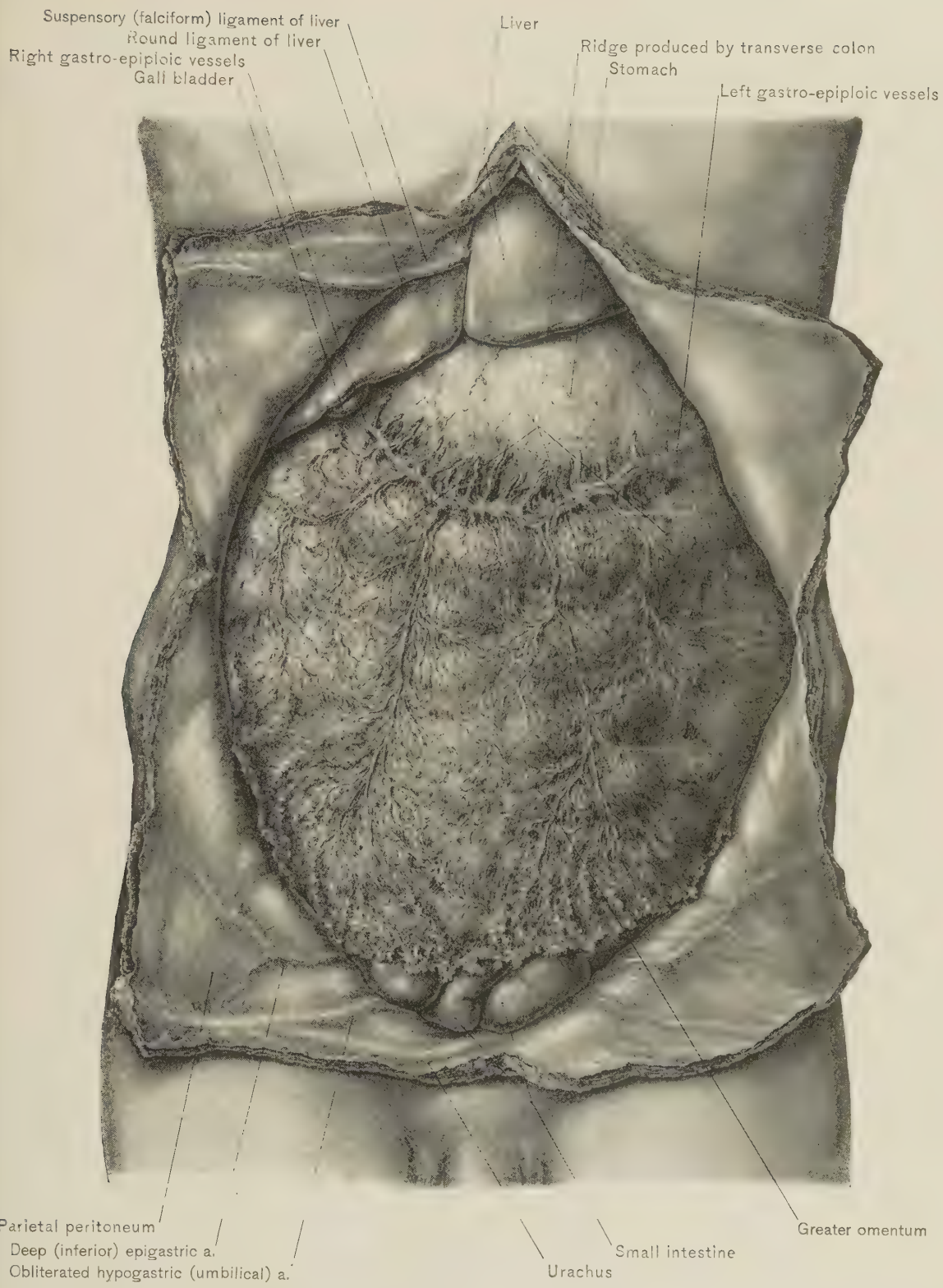

ABDOMINAL VISCERA AND GREATER OMENTUM.

and translucent. In the infant at birth it is quite short, scarcely extending to the umbilicus. The length of the greater omentum varies, sometimes being quite short and crumpled up, while at others it extends into the pelvis, in which case it is often difficult to keep it out of the way of the fingers in enucleating even a small pelvic tumor. This difficulty is overcome by placing the patient in the Trendelenburg posture (with the pelvis elevated) so that the intestines and omentum rise out of the pelvis, and then walling off the upper portion of the peritoneal cavity and the intestines with gauze. When the omentum is in the pelvis, it is also frequently found adherent to inflammatory masses located there. As a result of peritonitis the greater omentum may be found attached to the anterior wall of the abdominal cavity, the bladder, the uterus, the mesentery, or any adjacent viscus. In peritonitis the matting together of the viscera, greater omentum, and other portions of the peritoneum serves a useful purpose by checking extravasation of blood and visceral contents. In perforation of the viscera, as in appendicitis and acute infection of the gall-bladder, adhesions between the omentum and adjacent structures may prevent dissemination of infection throughout the peritoneal cavity. When performing an abdominal section for a pathologic condition in the pelvis it may be found advisable to break through an adherent omentum instead of dissecting it free. A rent or slit in the greater omentum, whether produced by operation or accident, should be sutured before closing the abdomen, for fear that a loop of intestine may subsequently find its way through the aperture and cause acute intestinal obstruction. If it is necessary to allow a drainage-tube to remain, the omental opening should be closed to the site of the tube. Omental herniæ, either inguinal or femoral, are more common in persons in whom the greater omentum is long. The vomiting and epigastric pain that sometimes occur in this form of hernia are explained by the traction of the omentum. When both omentum and intestine are contained in a hernial sac, the omentum usually lies in front of the bowel, and frequently becomes adherent to both the sac and the intestine. At times the omentum in a hernia becomes hypertrophied, elongated, or cystic, resembling either a testicle or the small intestine; at other times it is atrophied, and in congenital inguinal hernia an elongated thin band of the omentum is frequently found attached to the testicle. In a certain percentage of abdominal sections the greater omentum will form adhesions. These may produce much discomfort and pain from the resulting drag which may necessitate re-opening the cavity and freeing the adhesions. In closing an abdominal incision in corpulent individuals it is necessary to exercise great care to prevent the greater omentum from being included between the edges of the wound when tying the sutures. Lying, as it does, just internal to the abdominal walls, the greater omentum sometimes prevents the flow of fluid

through the trocar when the operation of paracentesis abdominalis is performed. The omentum or the intestine which prevents the flow of the serum may be pushed away by a probe introduced through the trocar. Because of its position the greater omentum almost always forms part of the contents of the sac of an umbilical hernia. The greater omentum lies so close to the anterior wall of the abdomen that it is frequently wounded, and may act as a plug, preventing protrusion of the intestine or other viscera. When the omentum is adherent to the abdominal wall, intestine, pelvic viscera, or mesentery, a loop of intestine may be caught over a band thus formed, causing acute intestinal obstruction.

A tumor deprived of its original source of blood supply, such as an ovarian cyst or a pedunculated fibroid twisted on its pedicle, may be nourished through accidental adhesions between it and the greater omentum, thus preventing gangrene of the tumor.

The **lesser omentum** extends between the transverse fissure (*porta hepatis*) of the liver and the lesser curvature of the stomach. Its right free border forms a fold, the duodeno-hepatic ligament, which forms the anterior boundary of the foramen of Winslow (*epiploic foramen*), while its left border is attached to the diaphragm and the greater curvature of the stomach. That portion of the lesser omentum which passes beyond the esophagus forms the gastro-phrenic omentum, or ligament.

The lesser omentum consists of two layers of peritoneum; these have been demonstrated in tracing the peritoneum vertically. Between these two layers, at the right, or free, border, pass the portal vein, the hepatic artery, the hepatic, cystic, and common bile ducts, and the nerves and lymphatics. The common bile duct, the hepatic artery, and the portal vein bear the following relation to one another: the duct lies to the right, the artery, to the left, and the vein, between and behind the two, but nearer to the duct than to the artery. Between the layers, along their attachment to the lesser curvature of the stomach, is the arterial loop formed by the anastomosis of the gastric (*left gastric*) artery and the pyloric (*right gastric*) branch of the hepatic artery.

The **gastro-splenic omentum,** or **ligament,** extends between the fundus of the stomach and the hilum of the spleen, and is continuous below with the greater omentum. It consists of two layers of peritoneum, between which pass the vasa brevia of the splenic artery, which run to the fundus of the stomach.

The **mesentery** (Plates CCCXCVIII; CCCXCIX) is the fan-shaped suspensory ligament of the jejunum and ileum, or all of the small intestine except the upper twenty-five to thirty centimeters (ten to twelve inches). It is composed of extraperitoneal connective tissue, blood-vessels, nerves, lymphatics, and an investment of peritoneum.

PLATE CCCXCVIII.

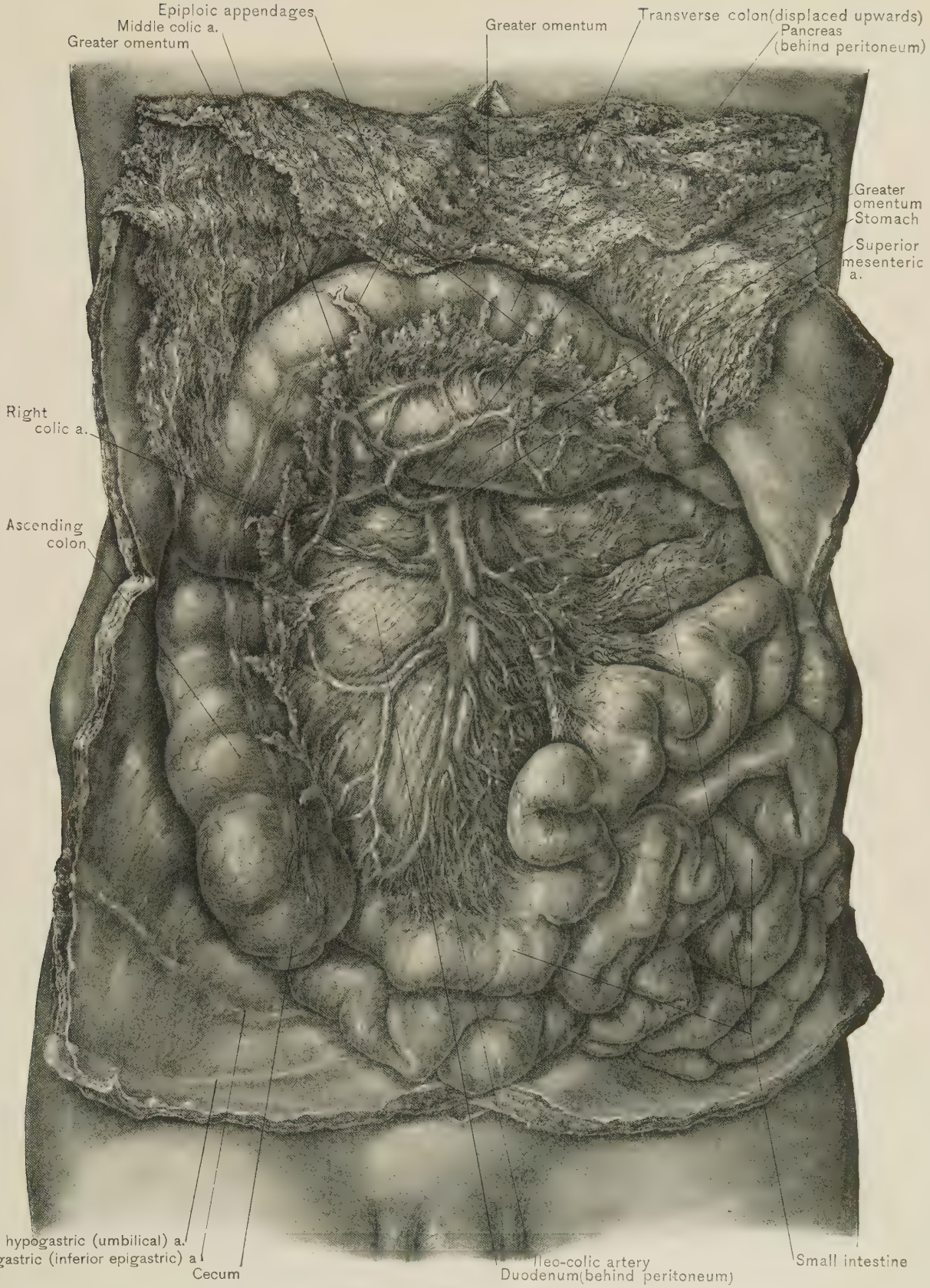

RIGHT SIDE OF MESENTERY, CECUM, AND ASCENDING COLON.

PLATE CCCXCIX.

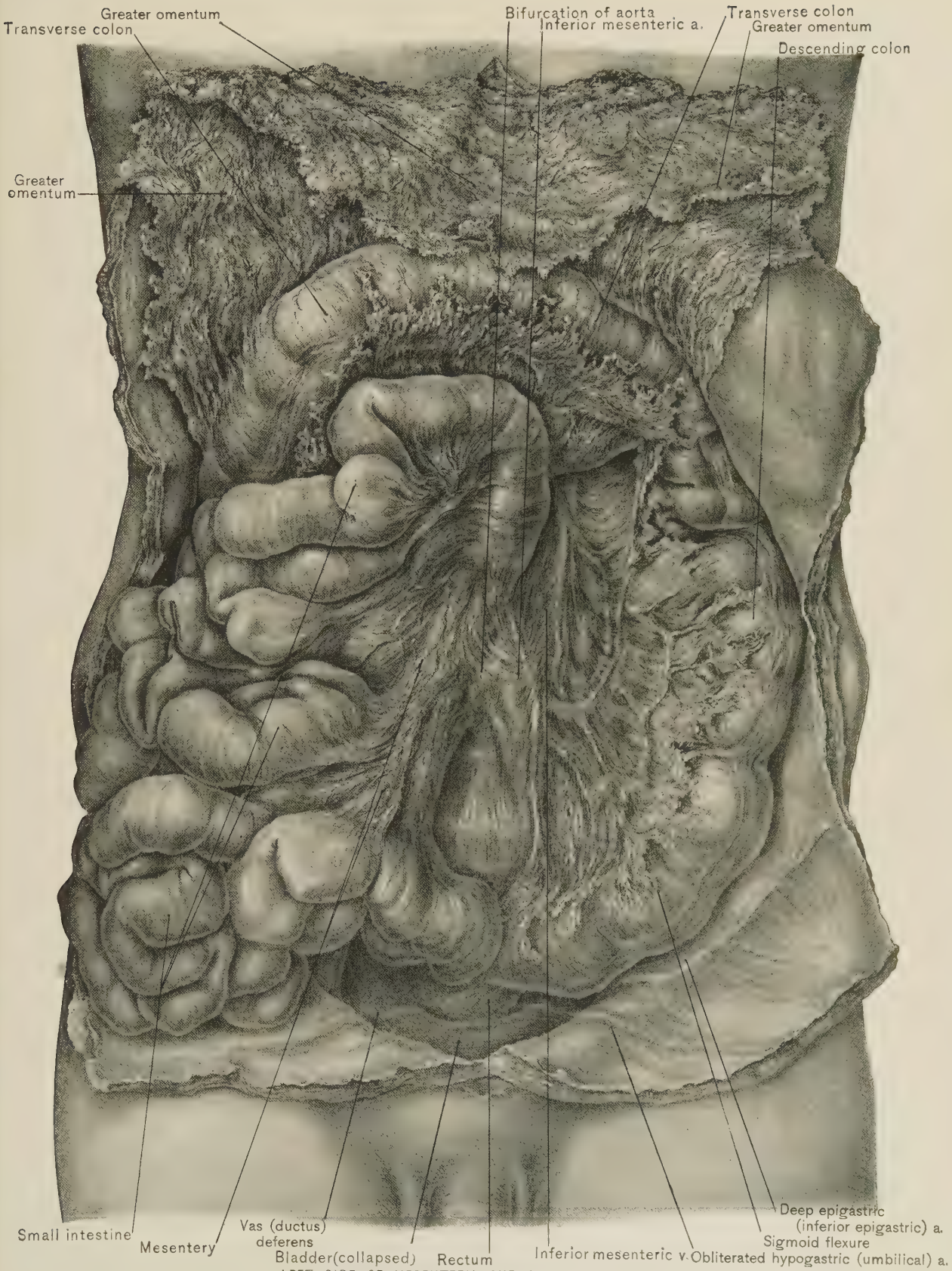

LEFT SIDE OF MESENTERY, AND DESCENDING COLON.

The base, or intestinal border, of the mesentery is about six and a half meters (twenty-two feet) in length and is attached to the small intestine. The great length of the base, or intestinal border, of the ligament is produced by plication of the mesentery along the greater part of this border for a depth of from six to eight centimeters (two and a half to three and a half inches). The root of the mesentery is about fifteen centimeters (six inches) in length, and is attached to the posterior wall of the abdominal cavity. The line of attachment of the apex or root of the mesentery is oblique, and extends from the point of termination of the duodenum, which is about on a level with the lower border of the pancreas, and at the left side of the second lumbar vertebra, to the base of the cecum, which is in the right iliac fossa, near the right sacro-iliac articulation. The position of the lower part of this attachment probably accounts for the more frequent incidence of right inguinal and femoral herniæ. Owing to the oblique attachment of the mesentery, it follows that when hemorrhage takes place in the abdomen on the right side of the mesentery, the blood is conducted first into the right iliac fossa, and when on the left side of the mesentery, the blood gravitates into the pelvis.

The average length of the mesentery, from its vertebral to its intestinal attachment, is from twenty to twenty-two centimeters (eight to nine inches) and is greater at that part which suspends the coils of the intestine lying between two and three meters (six and ten feet) from the duodenum, where it may reach the length of twenty-five centimeters (ten inches).

The mesentery presents two surfaces, both covered by peritoneum. The peritoneum on the right or upper surface is continuous with the lower layer of the transverse mesocolon and with the peritoneum which forms the inner layer of the ascending mesocolon; the peritoneum of the lower surface, with the peritoneum which forms the inner layer of the descending mesocolon and mesosigmoid (*pelvic mesocolon*).

In corpulent persons the mesentery, like the greater omentum, contains an additional quantity of fat. This increased weight tends to elongate the mesentery by dragging, and therefore predisposes to hernia. In the normal condition it is impossible to draw a coil of intestine through either the inguinal or the femoral canal; and it follows that before either of these herniæ can occur, there must be elongation of the mesentery.

Mesenteric openings.—Sometimes the mesentery is found to contain holes, either congenital or traumatic, through which a loop of intestine may pass and become strangulated, constituting a mesenteric hernia. The openings due to injury are slit-like, while the congenital ones are round. The latter have been shown by Treves to occupy the mesentery of the lower ileum in the oval area,

circumscribed by an anastomotic arch between the ileo-colic branch of the superior mesenteric artery and the last of the vasa intestini tenuis (*intestinal arteries*). This portion of the mesentery is often very thin, owing to the absence of fat, vessels, and glands, and thus presents a condition favorable for the protrusion of a loop of intestine.

The extraperitoneal connective tissue, which assists in forming the mesentery, transmits the blood-vessels, lymphatics and nerves to the jejunum and the ileum, and contains many lymph glands.

The blood-vessels are the superior mesenteric artery, its intestinal branches, or vasa intestini tenuis (*intestinal arteries*), and their accompanying veins which empty into the superior mesenteric vein. The lymph vessels are the lacteals which carry the chyle from the small intestine to the receptaculum chyli (*cisterna chyli*). The nerves are derived from the superior mesenteric ganglion of sympathetic nerves.

The mesentery contains numerous lymph glands known as **mesenteric glands.** Tuberculosis of the mesenteric glands (tabes mesenterica) is not uncommon. Inflammation of these glands may extend to the peritoneum and agglutinate adjacent coils of intestine, producing a mass which may be mistaken for an abdominal tumor. It may also result in abscess formation. The associated local or general peritonitis may produce adhesions, bands, or a bend or twist in the gut, which may cause intestinal obstruction.

In resection of the small intestine a triangular piece of the mesentery must be excised or the mesentery must be overlapped and fixed with sutures.

The **meso-appendix,** or **mesentery of the appendix,** is not strictly speaking a mesentery, but a fold of peritoneum which partially supports the vermiform appendix. The appendix being primarily an outgrowth of the large gut, since it represents morphologically the apex of the conical fetal cecum is without a true mesentery. What is usually termed the mesentery is the serous fold produced by the appendicular artery, a branch of the ileo-colic artery, finding its way to the appendix. It is therefore functionally a mesentery, but not morphologically. The ileo-cecal fold which runs from that part of the ileum most remote from its mesenteric attachment to the arterial meso is regarded by Treves as the remains of the true mesentery. It carries no blood vessels and has been called Treves' bloodless fold. The peritoneum of the left or superior surface of the meso-appendix is continuous with that of the inferior surface of the mesentery and of the left side of the mesocecum, and the peritoneum of its inferior or right surface is continuous with that of the right surface of the mesocecum. The mesocecum is usually absent when the vermiform appendix is directed upward and in close relation with the cecum.

PLATE CCCC.

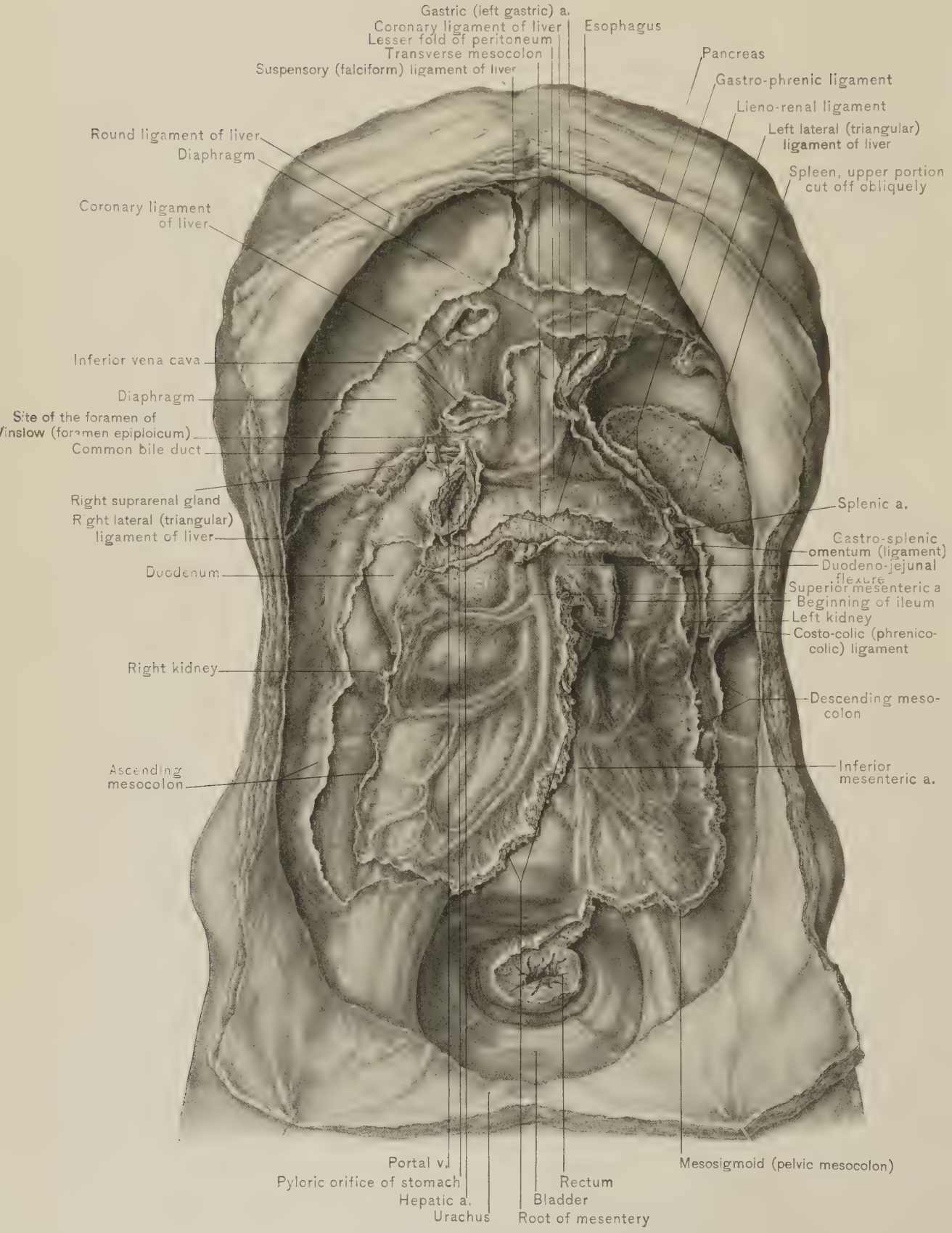

ATTACHMENTS OF MESENTERY AND MESOCOLON.

The meso-appendix unites with the serous covering of the appendix, which may be either complete or incomplete. In the majority of instances the entire appendix has a peritoneal covering. When only one portion is included in a peritoneal investment, the tip is the part destitute of peritoneum, making this portion of the organ extraperitoneal. In such instances if a perforation of the appendix should take place at this location it can readily be understood how infection of the retroperitoneal connective tissue may thus arise and result in the formation of an abscess which would be extraperitoneal. Perforation of the appendix between the layers of the meso-appendix would likewise cause infection of the retroperitoneal connective tissue. The meso-appendix is triangular in shape, its base corresponding to its free margin, and its sides to the appendix and the mesentery. It may be attached to the proximal one-third to two-thirds of the appendix, leaving the tip free, or it may be attached along its entire length. Sometimes it may be absent entirely, or it may be so small as to be considered absent. It consists of two layers of peritoneum, between which are extraperitoneal connective tissue, the appendicular artery and vein, nerves, and lymphatics. Occasionally, and almost invariably in corpulent persons, the meso-appendix contains a considerable quantity of fat, which, during operation renders the meso-appendix likely to be torn in the delivery of the appendix through the incision in the abdominal wall. The mobility of the appendix and the ease with which it can be delivered depend upon the extent of the attachment and the width of the meso-appendix.

The meso-appendix may contain an aperture through which a loop of small intestine may project and become strangulated. The iliac vessels have been known to pass through the layers of the meso-appendix. In the female it may have a prolongation, the appendiculo-ovarian ligament, which is lost in the broad ligament. Infection may be carried along this ligament from the appendix to the Fallopian (*uterine*) tube or the ovary, and thus produce a combined inflammation of both organs.

The outline of the appendix varies in accordance with the length of the meso-appendix. When the meso-appendix is short, the appendix presents an abrupt curve; if shortened in several places, the appendix may be of a corkscrew shape.

The **mesocolons** (Plate CCCC), the folds of peritoneum holding the large intestine in place, are four in number: the ascending, the transverse, and the descending mesocolon and the mesosigmoid (*pelvic mesocolon*).

The **ascending and the descending mesocolon** connect the corresponding portions of the colon to the posterior wall of the abdominal cavity; they are continuous with the transverse mesocolon. Both the ascending and the

descending colon are covered throughout their anterior two-thirds with peritoneum, leaving the posterior third, where the layers of the mesocolon diverge, destitute of peritoneum; this latter portion of the wall of the bowel is connected with the posterior wall of the abdominal cavity by loose connective tissue in which there is more or less fat. In lumbar colotomy, as the portion of the bowel devoid of peritoneum is the part attacked, this connective tissue and fat must be displaced before the posterior longitudinal muscle band can be seen. In some instances the ascending and particularly the descending colon are completely surrounded by peritoneum. The ascending and the descending mesocolon are seldom present as distinct double folds of peritoneum, nor do they often cover more than the front and sides of the ascending and the descending portion of the colon. The ascending and descending mesocolons consist of two layers, a lateral and a medial. Beneath the medial layer the blood-vessels, the lymphatics, and the nerves pass through extraperitoneal connective tissue to the ascending and the descending colon. In opening the retrocolic space through the anterior abdominal wall, as in removal of the kidney, the lateral layer of the mesocolon should be divided, and not the medial, on account of the relation the blood-vessels bear to the latter.

In the **mesocolic hernia of Cooper,** a retroperitoneal hernia, the small intestine reaches the retrocolic space of the left side by carrying before it that portion of the posterior parietal peritoneum continuous with the medial layer of the descending mesocolon.

The **transverse mesocolon** is the broad fold of peritoneum connecting the transverse colon to the posterior wall of the abdominal cavity. In the adult it is formed (as has been shown) by the ascending or posterior layer of the greater omentum. In the fetus (as previously described) the ascending layers of the greater omentum pass over the transverse colon to the posterior wall of the abdominal cavity, where they separate at the lower border of the pancreas, one layer passing in front of the pancreas, as in the adult, while the posterior layer turns downward, reaches the transverse colon, which it surrounds, and then passes backward to the abdominal wall and descends to form the mesentery, as in the adult. In the fetus, therefore, both descending and both ascending layers of the greater omentum lie in front of the transverse colon, while in the adult both descending layers and only one ascending layer lie in front of the transverse colon. In the adult the ascending layers of the greater omentum have merged with the upper layer of the transverse mesocolon, making it practically one layer. The transverse mesocolon is continuous, through its under layer, upon each side with the ascending and the descending mesocolon. Between its layers pass the blood-vessels, lymphatics, and nerves supplying the transverse colon. It divides the

abdominal cavity proper into two incomplete compartments: the upper compartment contains the liver, the stomach, and the spleen, and the lower, the intestines.

The **phrenico-colic ligament** is a fold of peritoneum which passes from the splenic (*left colic*) flexure of the colon beneath the spleen, to the under surface of the diaphragm, opposite the tenth and eleventh ribs. This ligament supports the spleen, the lower end of the organ resting upon it, and for this reason has also been called the *sustentaculum lienis.*

The **epiploic appendices** are pouches of peritoneum containing fat, and are attached here and there along the whole length of the large intestine except the rectum. They are situated chiefly opposite the medial muscle band, and are more numerous upon the transverse colon and sigmoid flexure (*iliac and pelvic colon*). They are of value in distinguishing the large from the small bowel. Sometimes they are quite long. The author has known a long epiploic appendix that was infiltrated and discolored by inflammation, the origin of which was in the vermiform appendix, to be mistaken for the latter in an operation for appendicitis. An epiploic appendix may become adherent to a neighboring coil of intestine or to the parietal layer of peritoneum, producing a band which may cause intestinal obstruction.

The **mesocecum** is a double fold of peritoneum extending between the cecum and the floor of the iliac fossa, connecting the cecum with the latter. However, in the majority of cases the cecum is completely covered with peritoneum and lies free in the abdominal cavity. The right peritoneal layer of the mesocecum connects the right side of the meso-appendix with the right layer of the ascending mesocolon, and the left layer connects the left peritoneal layer of the meso-appendix with the under layer of the mesentery. A well-developed mesocecum in the fetal or second type of cecum may prevent delivery of the cecum through the incision in the abdominal wall in the operation of appendicectomy.

The **mesosigmoid** (**pelvic mesocolon**), the continuation of the descending mesocolon, is the reflection of peritoneum which connects the sigmoid flexure with the posterior wall of the extreme lower portion of the abdominal cavity and with the posterior wall of the pelvic cavity. It extends from the termination of the descending colon in the iliac fossa, at the lateral border of the psoas major muscle, to the commencement of the rectum, opposite the middle portion of the sacrum. In following the line of attachment of the mesosigmoid (*pelvic mesocolon*) it will be seen to cross the psoas major muscle and the iliac vessels near their bifurcation, and, after passing slightly to the right, to descend obliquely, reaching almost to the floor of the pelvis. The whole of the mesosigmoid (*pelvic mesocolon*) lies to the left of the median line. The width of the mesosigmoid (*pelvic mesocolon*)—

the distance between the attachment to the parietes and to the bowel—varies from two to nine centimeters (one to three and one-half inches). The width of the mesosigmoid (*pelvic mesocolon*) permits the greater portion of the sigmoid flexure, when distended, to occupy the pelvic cavity, and often to extend into the hypogastric region. The terminal part of the mesosigmoid (*pelvic mesocolon*), if much infiltrated by extensions of carcinoma of the sigmoid flexure, can be felt by introducing the finger into the rectum. Between the layers of the mesosigmoid (*pelvic mesocolon*) are the sigmoid artery or arteries and the superior hemorrhoidal artery, with their accompanying veins, the lymphatic vessels and the nerves supplying the sigmoid flexure. The width of the mesosigmoid (*pelvic mesocolon*) is of extreme importance in operations on the sigmoid. This is especially true in cases of annular carcinoma where the Mickulicz technique is attempted. A long mesosigmoid (*pelvic mesocolon*) is also of considerable help in the Kraske operation or its modifications, when end-to-end suture is attempted after removal of the growth.

The **mesorectum** does not exist, if the description of the rectum as given below is accepted. What is described in many of the text-books as the mesorectum is here considered as the terminal portion of the mesosigmoid (*pelvic mesocolon*).

Within recent years much has been said and written in regard to ileo-cecal kinks and adhesions. Whether the kink described by Lane, which occurs a few centimeters below the termination of the ileum, is congenital, as he claims, or whether it is the result of peritoneal inflammation, is not yet settled. Certainly many of these cases are truly inflammatory. More recently, attention has been called to Jackson's membrane of the ascending colon and Harris' veil of the duodenum. In these two the etiology is uncertain. They may be the result of faulty development of the posterior mesentery and the mesogastrium, or they may be types of pericolitis.

The Peritoneal Fossæ.—In studying the course of the peritoneum, the various fossæ must be carefully observed. They are formed by folds and depressions of the peritoneum, and are of importance because of their relation to certain pathologic conditions. Some of the viscera may become herniated through the intersigmoid and duodeno-jejunal fossæ. The fossæ around the cecum, the ileo-colic, ileo-cecal, and subcecal (retrocecal) fossæ, are associated with the appendix, and may hide an inflamed appendix or occasionally make it possible for the peritoneum to wall off an appendiceal abscess. Inguinal herniæ pass through the inguinal fossæ, which have been previously described.

The **intersigmoid fossa** is a depression sometimes present on the left side of that portion of the mesosigmoid (*pelvic mesocolon*) occupying the iliac fossa, and is situated between the anastomoses of the sigmoid arteries. At the bottom of this fossa, posterior to the peritoneum, lies the ureter. It varies in depth from two

PLATE CCCCI.

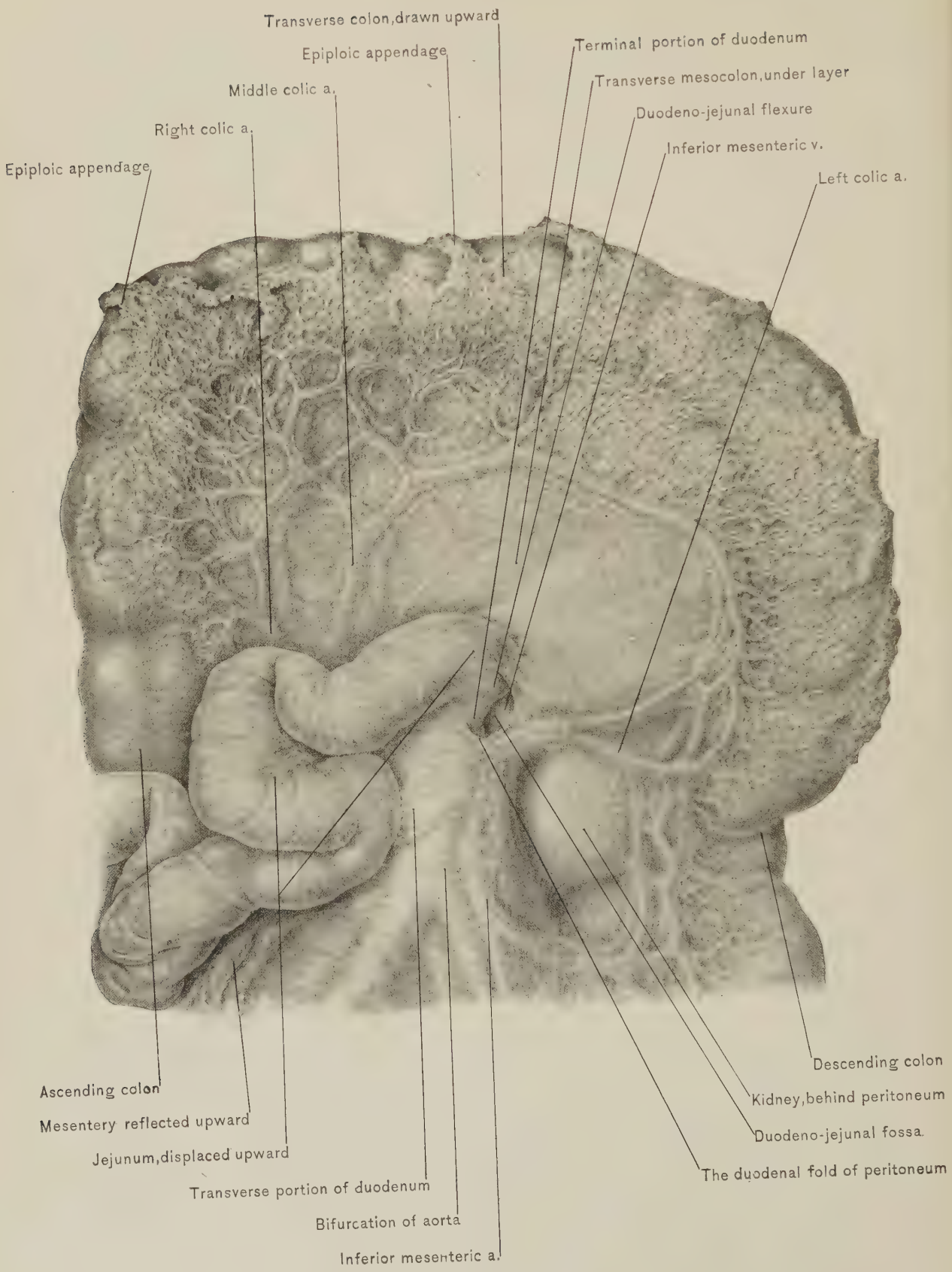

DUODENO-JEJUNAL FOSSA.

PLATE CCCCII.

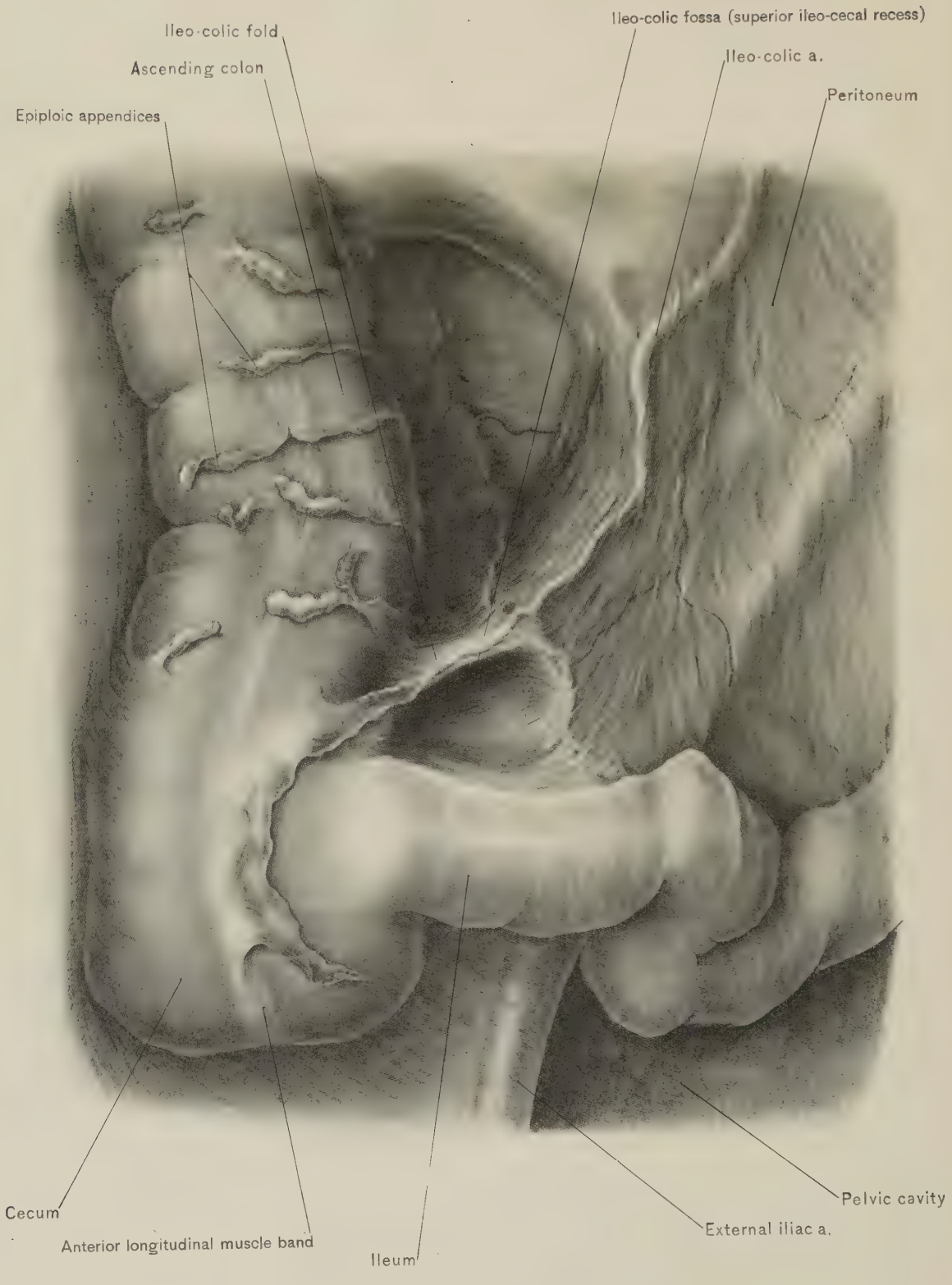

ILEO-COLIC FOSSA (SUPERIOR ILEO-CECAL RECESS).

PLATE CCCCIII.

ILEO-CECAL FOSSA (INFERIOR ILEO-CECAL RECESS).

and a half to four centimeters (one to one and a half inches), and may be the site of a sigmoid hernia, of which a number of cases have been recorded.

Another fossa is occasionally present in the parietal portion of the peritoneum, where the continuation of the under layer of the mesentery passes to the descending colon, to form the medial layer of the descending mesocolon. The mouth of this fossa is broadened by a branch of the inferior mesenteric artery.

The **duodeno-jejunal fossa** (Plate CCCCI) is situated close to the left side of the fourth portion of the duodenum, near the duodeno-jejunal flexure. The fossa is formed by a fold of the posterior parietal peritoneum extending toward the right side of the body, to a vertical line on the anterior surface of the fourth portion of the duodenum. Its orifice is directed upward. Sometimes there is an additional ridge of peritoneum which is situated near the upper limit of the duodeno-jejunal flexure and deepens the fossa. According to Treves, the fossa is present in about forty-eight per cent of cases, and admits the thumb up to the first joint. The fourth portion of the duodenum usually bulges against the peritoneal fold and closes the fossa. It is important as the site of retroperitoneal herniæ.

The *superior duodenal fossa* is a prolongation from the duodeno-jejunal fossa. Its opening is downward and it lies back of the duodeno-jejunal fold. The *inferior duodenal fossa*, also a prolongation from the duodeno-jejunal fossa, lies back of the duodeno-mesocolic fold, and has its opening directed upward. These two triangular folds have each one edge attached to the duodenum and one to the parietal peritoneum to the left of the duodenum, while the third edge is free, bounding the openings of the fossæ.

The **ileo-colic fossa** (**superior ileo-cecal recess**) (Plate CCCCII) is a peritoneal pouch formed in front of the mesentery, at the angle of the junction of the ileum and the colon. The floor is formed by the mesentery, and sometimes by a portion of the ileum. The ileo-colic fold of peritoneum forms its upper boundary, the ileum, its lower boundary, and the ascending colon, its lateral or right boundary. This pouch varies in size and depth, and, being situated high up, does not play an important part in appendicitis. The **ileo-colic fold** is a ridge produced by the colic branch of the ileo-colic artery.

The **ileo-cecal fossa** (**inferior ileo-cecal recess**) (Plate CCCCIII) is a peritoneal pouch, situated beneath or behind the mesentery, at the angle of the junction of the ileum and the cecum. To expose it, both the ileum and the cecum must be displaced upward and forward. It is bounded on the right by the medial layer of the meso-cecum and the meso-appendix, and on the left by the under surface of the mesentery. The roof is formed by the **ileo-cecal fold,** a thin fold of peritoneum extending from the free border of the ileum to the cecum, and finally

joining the surface of the meso-appendix. This fossa may be very deep and long, at times extending upward behind the ascending colon as far as the right kidney and the duodenum. The appendix is often found in this fossa, which explains why it is so often the site of the products of appendicitis. For this reason a knowledge of the ileo-cecal fossa (*inferior ileo-cecal recess*) is important.

The **subcecal (retrocecal) fossa** (Plate CCCCIV), as its names implies, is immediately under the cecum, so that this portion of the bowel must be raised in order to obtain a view of it. It is the recess beneath the cecum lateral to the meso-appendix and mesocecum. When there is a ridge in the peritoneum where the lateral layer of the mesocecum is continuous with the corresponding layer of the ascending mesocolon, the fossa is more definitely limited laterally. On account of its high position it does not play a prominent part clinically.

The appendix may occupy any one of these three fossæ in relation with the cecum, but most often it is found in the ileo-cecal (*inferior ileo-cecal recess*) or in the subcecal (*retrocecal*) fossa. The complications which may arise when the appendix occupies any of these fossæ are sometimes very misleading at operation. Thus, at times, the appendix may constitute a retroperitoneal hernia; or, if the appendix should occupy one of these fossæ and the mouth of the fossa close over the organ, the organ might be supposed to be absent. Suppuration around an appendix so walled in would be entirely circumscribed.

Relations of the Abdominal Viscera.—The course of the peritoneum having been traced, the natural positions of the viscera, their situation, their connections with the neighboring parts and the relation they bear to the surface marks of the body should next be studied. To become thoroughly familiar with the relations the viscera bear to the surface of the abdominal wall, the reflected portions of the latter should be replaced in position, and the parts then re-examined.

The Liver (Plates CCCCV; CCCCVI).—The larger portion of the liver is found in the right hypochondriac region, although the organ also occupies part of the epigastric, and may extend into the left hypochondriac region; it seldom extends more than five centimeters (two inches) beyond the left margin of the sternum. Its bulk entirely fills the anteroposterior diameter of the abdominal cavity in this location. In the infant the liver is proportionally much larger than in the adult. Its superior and posterior surfaces are in close contact with the under surface of the diaphragm, from which the organ is suspended; therefore, the liver, and tumors attached to it, move upward and downward with that muscle during respiration. The right lobe of the liver is protected by the chest-wall, while the left lobe extends across the epigastric region just below the xiphoid cartilage, where it lies behind the anterior abdominal wall. The

PLATE CCCCIV.

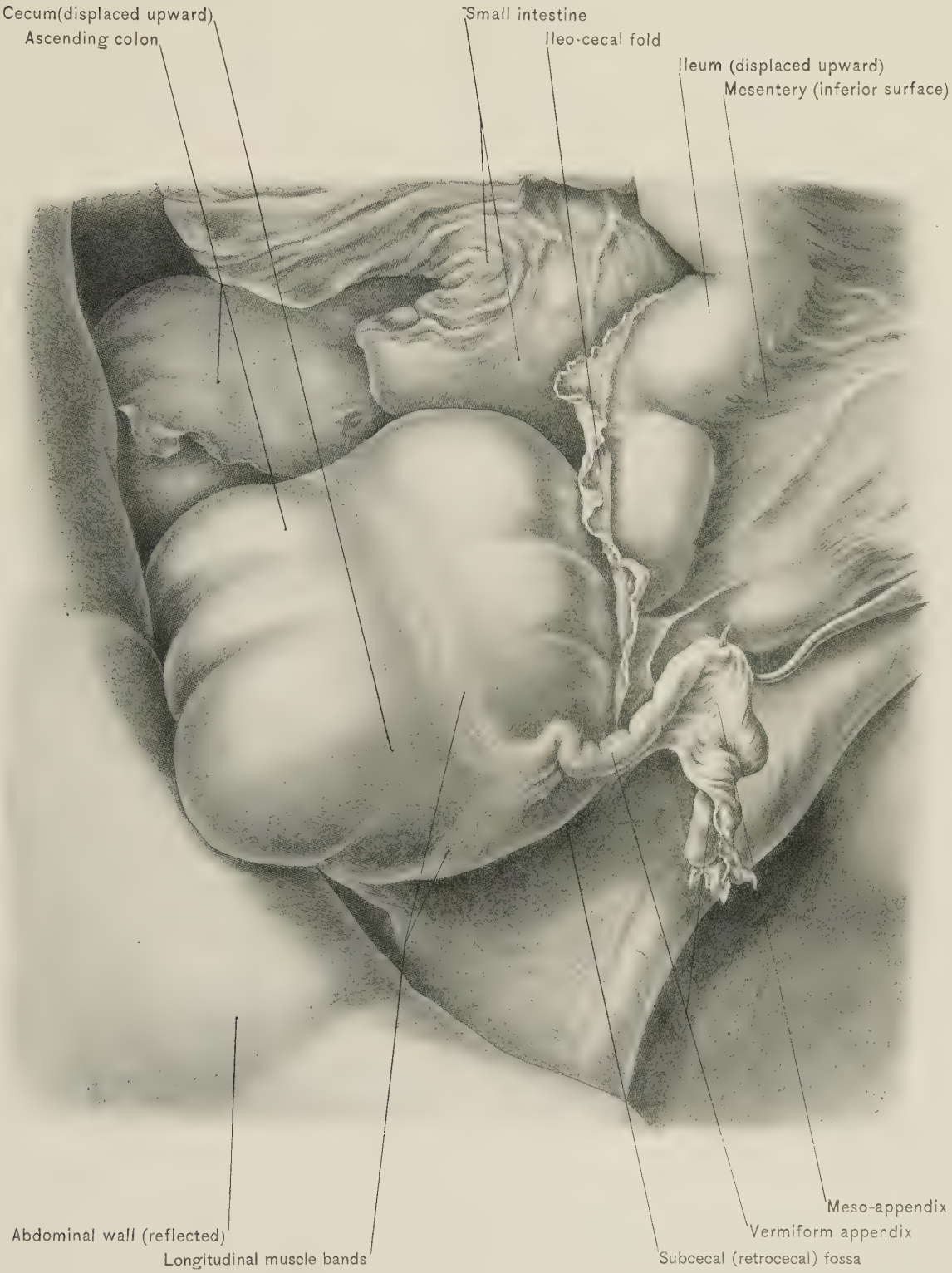

SUBCECAL (RETROCECAL) FOSSA.

PLATE CCCCV.

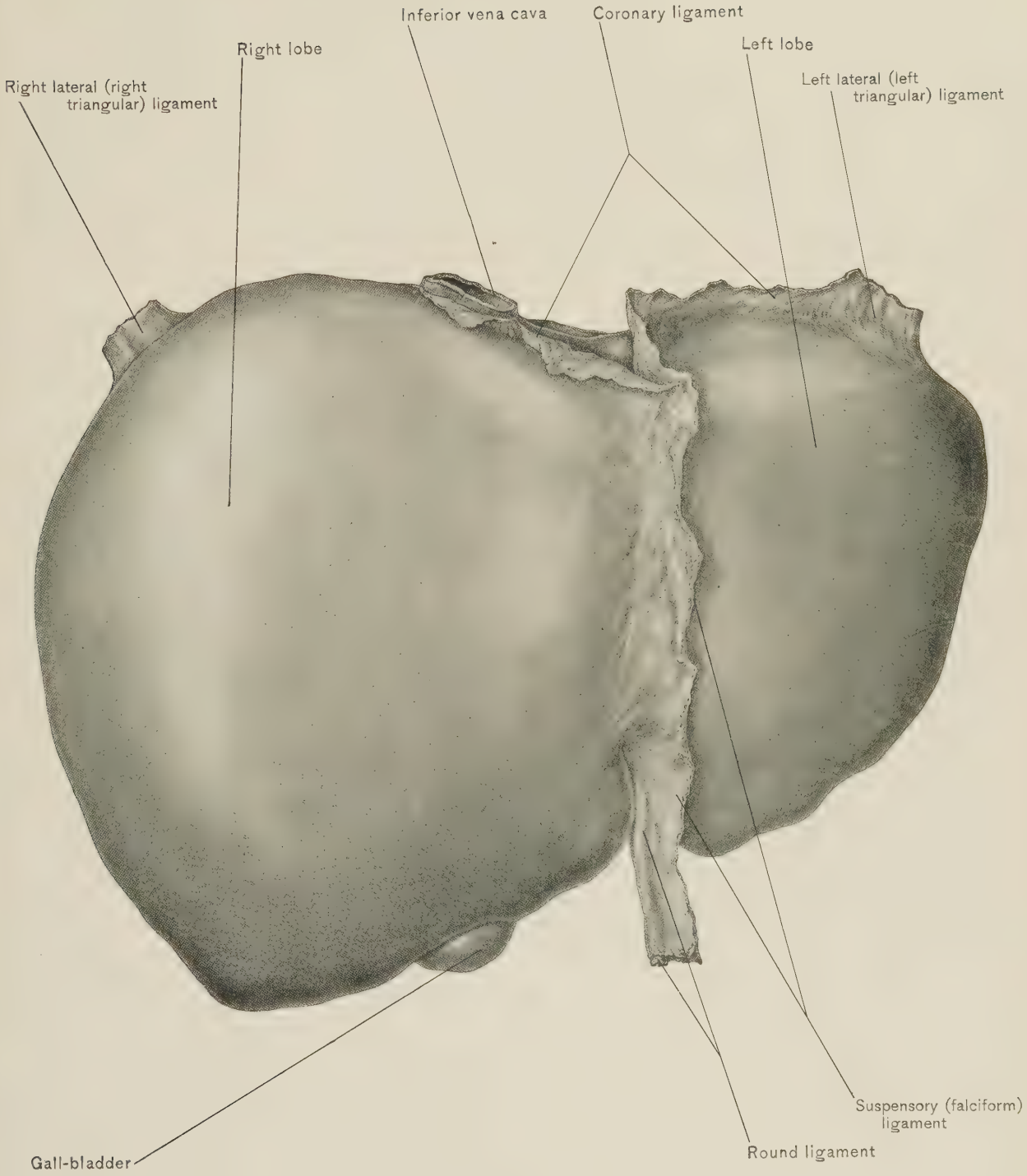

SUPERIOR SURFACE OF LIVER.

PLATE CCCCVI.

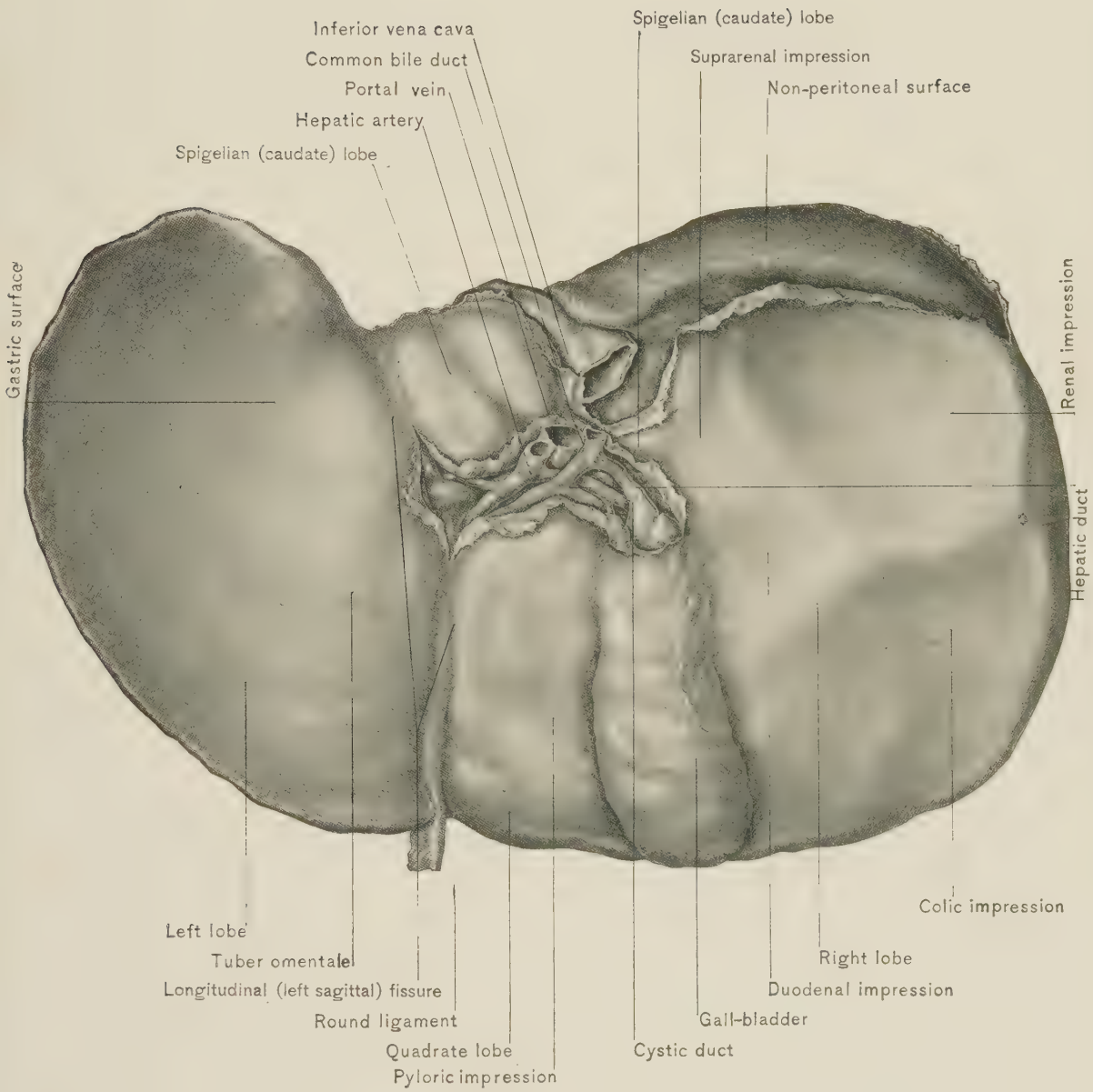

INFERIOR SURFACE OF LIVER.

outline of the liver, as drawn on the surface of the body, has been described with the surface anatomy of the abdomen, and may now be demonstrated by the dissector. When the subject assumes the upright position, the lower limit of the organ drops about one centimeter (one-half inch). Owing to its friability and because of the fact that it fills the anteroposterior diameter of the abdominal cavity, the liver is more frequently ruptured than any other viscus. This accident is usually followed by profuse hemorrhage and death. The hemorrhage is copious because the hepatic veins or their radicles must be torn, since their walls are adherent to the tissue of the liver. These short vessels empty into the inferior vena cava; they contain no valves, and are always held open by the surrounding hepatic tissue. Torn radicles of the portal vein and branches of the hepatic artery add to the severity of the hemorrhage. From the relation of the liver to the chest-wall it will be seen that one of the lower ribs, when fractured, may penetrate the liver. The liver, when enlarged, encroaches upon the abdominal cavity. Tumors of its lower surface also descend into that cavity, while those arising upon its upper surface infringe upon the thoracic cavity. Tight lacing alters the shape of the liver and pushes its anterior margin downward. Collections of fluid in the right pleural cavity also depress this organ, and in collapse of the lung or gaseous distention of the intestines (tympanites) it is elevated.

The liver is in relation above with the diaphragm and the anterior abdominal wall. Below it are the stomach, the lesser omentum, the gall-bladder, the hepatic (*right colic*) flexure of the colon, the right kidney, and the first and second portions of the duodenum. Behind it are the lower end of the esophagus, the right suprarenal gland, the aorta and inferior vena cava, the crura of the diaphragm, the tenth and eleventh thoracic vertebræ, and the structures just mentioned as being below it. In front of it are the diaphragm and the anterior abdominal wall.

The relations of the liver show that abscesses of its upper surface may ulcerate through the diaphragm, and the pus thus enter the pleural cavity and then the lung and be expectorated; or it may enter the lung directly by causing adhesion of the visceral and parietal pleura, thus sealing the general pleural cavity. Abscesses of its lower surface may open into the transverse colon, the stomach, or the duodenum. The walls of the abscess may become adherent to the abdominal parietes, and the pus may find its way to the surface of the body.

The organ is held in place by five **ligaments**: the round, the suspensory (*falciform*), the right and the left lateral (*triangular*), and the coronary; the first consisting of the obliterated umbilical vein, the others being reflections of the peritoneum. These ligaments can be readily studied with the organ *in situ*.

The **round ligament of the liver,** or **ligamentum teres,** is the fibrous remnant of the umbilical vein of the fetus. It extends from the umbilicus to the under surface of the anterior margin of the liver, along the anterior division of the longitudinal (*left sagittal*) fissure, to the transverse fissure (*porta hepatis*); thence it passes to the inferior vena cava as the remains of the ductus venosus. Between the umbilicus and the anterior margin of the liver it is held in the free margin of the suspensory (*falciform*) ligament of the liver.

The **suspensory (falciform) ligament of the liver** consists of a double crescentic peritoneal fold, the free margin of which envelops the round ligament. It is attached to the diaphragm and the anterior abdominal wall as far downward as the umbilicus, and to the superior surface of the liver from the notch in the anterior border at the longitudinal (*left sagittal*) fissure to the posterior surface. Behind the two layers separate, the right layer passing into the coronary ligament, the left into the left lateral (*triangular*) ligament.

The **coronary ligament of the liver** consists of two layers of peritoneum which are reflected from the posterior surface of the liver to the diaphragm. These two layers are separated by an interval which is filled with areolar tissue, and which leaves part of the posterior surface devoid of peritoneal covering. At each end of the posterior surface are the **right and the left lateral (right and left triangular) ligaments.** The right is the pointed right extremity of the coronary ligament; the left, which is the larger, is continuous with the left layer of the suspensory (*falciform*) ligament. The latter is attached to the upper surface of the left lobes and to the diaphragm. In addition to the ligaments it must be remembered that the inferior vena cava assists in holding the liver in place, for this large vessel passes nearly vertically upward in a groove on the posterior surface of the liver for a distance of about six centimeters (two and a-half inches), and is firmly adherent to the hepatic tissue. It may even be covered by liver tissue, such processes being called the pons hepatis. It is also supported by bands of fibrous tissue passing from the nonperitoneal portion of the posterior surface of the liver to the diaphragm, and also by intra-abdominal pressure.

On account of the firmness with which these ligaments hold the liver in position it is well to delay the study of its surfaces, borders, and fissures until it has been removed from the abdominal cavity.

The **gall-bladder** is seen in contact with the under surface of the right lobe of the liver. Its fundus is situated opposite the right ninth costal cartilage, or the angle formed by the right costal margin and the right margin of the right rectus muscle. Its long diameter extends anteroposteriorly. With the body in the erect posture, the fundus is the lowest portion of the gall-bladder. The fundus of the gall-bladder sometimes extends for a distance of four centimeters (an inch

and a half) beyond the anterior border of the liver; at other times it does not project beyond the border of the liver. When the gall-bladder projects beyond the anterior margin of the liver, it is, of course, more readily accessible for operative interference and can be more easily drawn into the abdominal wound. The organ may in rare cases be congenitally absent, or may become obliterated as the result of disease.

Gall-stones are usually formed within the gall-bladder, and may remain for years without giving rise to pronounced symptoms. In passing out, a gall-stone may produce severe colic in traversing the cystic and the common bile ducts. If the stone lodges in the cystic duct, drainage from the gall-bladder is prevented, so that bile can not enter, and mucus secreted within can not pass out. The suspension of drainage favors ulceration of the gall-bladder, so that the stones may escape by way of the adjacent transverse colon or the duodenum, or may enter the abdominal cavity. Obstruction of the cystic duct from any cause may be followed by great distention of the gall-bladder, produced by its mucous secretion. If no active infection is present this is termed hydrops, while if an acute infection also exists an empyema of the gall-bladder results. The procedure of choice in gall-bladder disease with or without stones is removal of the gall-bladder, cholecystectomy. Cholecystostomy, drainage of the gall-bladder, is apt to be used by the novice in surgery. The experienced surgeon uses it only in the very acute cases where experience has taught him that the friable structures which must be ligated when the gall-bladder is removed, cannot be tied with safety.

The **stomach,** the most dilated part of the alimentary canal, is situated in the left hypochondriac and the epigastric regions, between the esophagus and the small intestine, and is retained in position by the esophagus and by reflections of the peritoneum. Although the form of the stomach varies according to the degree of retention, its general shape is irregularly pyriform, its larger extremity, the **cardiac end,** being directed backward and to the left, and its narrow extremity, the **pyloric end,** running to the right to meet the duodenum. The portion of the cardiac end projecting to the left beyond the esophagus is the **fundus,** or **greater cul-de-sac,** of the stomach, and the slight dilatation of the stomach at the pyloric end is the **antrum of the pylorus,** or **lesser cul-de-sac.** The portion between is the **corpus, or body, of the stomach.** The stomach has an anterior and a posterior surface; these surfaces are somewhat crescentic in shape. The upper and shorter margin of the stomach is the **lesser curvature,** and its lower and longer border is the **greater curvature.** The line of the lesser curvature is drawn from the cardiac orifice to the fifth rib, slightly lateral to the left mid-clavicular line, and thence to the pyloric opening. The line of the greater curvature is convex downward and to the left.

The parts of the stomach occupying the left hypochondriac region are the cardiac end and the body, three-fourths of the organ lying in that region. The portion in the epigastric region is the pyloric end; it is in contact with the under surface of the liver and continuous with the duodenum.

The stomach, except for a very small surface below and to the left of the cardia, is completely covered by peritoneum. The folds of peritoneum attached to the stomach and serving to connect it with surrounding structures are: the gastro-colic, the gastro-hepatic, and the gastro-splenic omenta and the gastro-phrenic ligament.

The **gastro-colic ligament,** or **greater omentum,** connects the lower convex border or greater curvature of the stomach with the transverse colon.

The **gastro-hepatic ligament, or omentum, a portion of the lesser omentum,** connects the upper concave border, or lesser curvature, of the stomach with the transverse fissure (*porta hepatis*) of the liver.

The **gastro-splenic omentum** (**gastro-splenic ligament**) connects the cardiac end of the stomach with the hilum of the spleen.

The **gastro-phrenic ligament** is situated on the left side of the esophagus, and connects the fundus of the stomach with the diaphragm. This is joined by the gastro-pancreatic fold in which the coronary (*left gastric*) artery runs to the right of the cardiac opening.

Relations.—In front of the stomach are the diaphragm, the anterior abdominal wall, and the liver. Behind it are the spleen, pancreas, left kidney, left suprarenal gland, transverse mesocolon, diaphragm, aorta, inferior vena cava, and the solar (*celiac*) plexus. Above it are the diaphragm, the liver, and the lesser omentum. Below it are the transverse colon, the greater omentum, and the spleen.

The stomach is subjected to frequent alterations in position, depending upon certain conditions, such as: variations in size of the surrounding organs, accumulations of fluid in the chest or in the abdomen, respiration, pressure from without, as by tight lacing, and the quantity of food it contains. When the stomach is greatly distended, it pushes the transverse colon and the small intestine downward, and produces a prominence below the ensiform (*xiphoid*) cartilage, where normally a depression (scrobiculus cordis) exists; at the same time it forces the liver, diaphragm, and heart upward. Distension of the stomach causes it to encroach upon the heart and the lungs; this sometimes occurs after a heavy meal. The action of the heart is retarded when that organ is pushed upward and to the right, so that the capillaries of the brain and of the head are full of venous blood, thus disturbing the cerebral circulation and flushing the face. Consequently persons predisposed to apoplexy are likely

to have the "stroke" immediately after eating a heavy meal. When the stomach is distended, its shape and size may be outlined by percussion. Acute dilatation of the stomach occurs after abdominal operations and occasionally during acute infections, such as pneumonia. Pyloric spasm, pressure of the superior mesenteric vessels as they cross the third portion of the duodenum, excessive gastric secretion, or a nervous unbalance due to trauma of the solar (*celiac*) plexus have been suggested as causes, but it is probable that more than one factor is involved in different cases.

The stomach may be displaced downward, as in a large omental hernia; the greater curvature may even descend into the pelvis as in dilatation due to stricture of its pyloric end or in gastroptosis. The pyloric end being attached only by peritoneum is more movable than the cardiac end, so that the pyloric portion of the stomach is more readily displaced downward by tumors of the stomach. Since the thoracico-lumbar outflow of sympathetic nerves supplies both the stomach and the heart, pain impulses originating in the one may be consciously referred to the other. The white rami or connector neurons of the second to the fifth thoracic segments are directed chiefly upward to be distributed to the cardiac plexuses. The thoracic-lumbar outflow from the sixth dorsal to the second lumbar is directed to the inferior portions of the sympathetic trunk and thence to the abdominal viscera. Some of the uppermost fibers may inosculate with those which supply the heart, or the stimulus may be so violent as to cause a spinal overflow from one segment to another. The conscious interpretation of pain is referred to the cutaneous spinal segmental distribution. The fifth intercostal supplies the area just above the epigastric angle, while the sixth supplies the epigastric angle. The modus operandi is thus simple. It is for these reasons that the older clinicians were accustomed to advise that, "if the patient complain of his stomach, suspect heart disease; if he complain of his heart, suspect indigestion."

A distended stomach will cause dyspnea by pressing upon the lung and heart, thus interfering with their action. Pain in the region of the spleen, or the cardiac end of the stomach, or base of the left pleural cavity may be so confusing that a positive diagnosis cannot at once be made. A moderately distended stomach has its contained gas only in the cardiac end, which is its highest part when the body is in the upright position. Very often this is constantly present, and would yield a resonant sound over the base of the left lung even if considerable fluid were in the bottom of the pleural sac. This is an awkward complication, because the upright position, which sends the gas upward, drives the fluid downward, so that they overlap, and one masks the other. The

only remedy is to place the patient in a position which will cause the gas and liquid to diverge.

The close proximity of the heart to the stomach is illustrated by a case in which a thorn, one and a quarter centimeters (half an inch) long had been swallowed and had found its way into the cavity of the right ventricle through the diaphragm and the pericardium (Treves).

When the stomach is empty, its upper concave border, or lesser curvature, is directed upward, its lower convex border, or greater curvature, downward, and the pylorus behind the linea alba, about seven centimeters (three inches) below the ensiform (*xiphoid*) cartilage. When the stomach is distended, the upper border is directed backward and the lower forward, and the pylorus approaches the right semilunar line. Adhesions between the stomach and adjacent coils of intestine may give rise to pain and other disturbances of the gastro-intestinal tract. The X-ray has aided greatly in our studies of the distended and empty stomach, as it has in the study of motility and peristalsis.

Injuries of the stomach.—The stomach is much more exposed to injury when full than when empty. Wounds of the stomach are more dangerous if inflicted when the organ is full, as its contents escape into the peritoneal cavity and set up acute peritonitis. When empty, the stomach is but slightly exposed to injury, as it lies well back in the abdominal cavity, against the posterior abdominal wall.

The portion of the stomach which is immediately behind the abdominal wall is accessible for operative interference, and is located by a triangle, bounded on the right by the anterior margin of the liver, on the left by the cartilages of the eighth and ninth ribs, and below by a horizontal line passing between the tips of the tenth costal cartilages; the latter line nearly corresponds with the lower border when the organ is not much distended. While occasionally exposures of the cardiac end of the stomach are obtained for operative interference these are the exceptions. To expose the stomach, one of several incisions may be made: parallel to and about two centimeters (seven-eighths of an inch) from the free border of the left costal cartilages; through the linea alba; through the right or left rectus muscle.

Gastrotomy—cutting or opening the stomach—is performed for the removal of a foreign body, for exploration, or for cauterization or excision of ulcers on the posterior wall. Digital dilatation of the pylorus in cicatricial stenosis is seldom done at present, the operation having been supplanted by pyloroplasty with its various modifications. *Pyloroplasty* was originally done by cutting through the anterior wall of the pylorus, the incision dividing the stricture and extending two and one-half centimeters (one inch) into both the stomach and the

duodenum. The margins of the wound thus made are retracted, and the edges are apposed in a direction at a right angle to that of the incision, the sutures being passed parallel with the long axis of the stomach. In this manner a longitudinal incision is made to look like a sutured wound extending across the pylorus. Numerous operative procedures have been advanced for hypertrophic stenosis of the pylorus, the one more generally used being that advocated by Rammstedt. In this procedure an incision is made longitudinally over the pyloric mass, through the bloodless area above the pyloric vein, down to, but not into the submucosa. The serosa and muscularis are dissected free from the mucosa by blunt dissection for six millimeters (one-fourth of an inch) on each side, so as to allow this to pout out, thus enlarging the pyloric outlet. Another operation performed on the stomach is that of *gastrostomy*, the establishment of a gastric fistula for the purpose of introducing food into the stomach in obstructive disease of the esophagus. In the operation devised by Witzel, a rubber catheter or tube is introduced into a small opening in the anterior wall of the stomach, and from five to six centimeters (two to two and a half inches) of the projecting portion of the catheter are buried by folding over it two folds of the stomach-wall. The stomach, after being replaced, is then sutured to the parietal peritoneum, and the abdominal wound closed, except at the site of the catheter. *Pylorectomy*, excision of the pylorus, is nearly always associated with a *partial gastrectomy*. The operation is usually performed for cancer or ulcer. In this operation the stomach is exposed through a median or rectus incision and drawn out of the abdomen. The duodenum and stomach are then clamped at the point of selection, and the greater and the lesser omenta are divided and ligated. The stomach is divided between clamps from one curvature to the other, but closer to the pyloric side. After the first part of the duodenum is clamped, it is divided and the diseased part of the stomach including the pylorus is removed. This is followed by anastomosis of the remaining portion of the stomach and the duodenum. There are many modifications of this procedure which is known as the Billroth I. The Billroth II closes the duodenal and gastric stumps and adds a posterior gastro-enterostomy. The Polyá operation consists of closing the duodenal stump, and adding a gastro-jejunostomy preferably by the posterior method.

Gastrectomy, or removal of the stomach, is rarely resorted to for carcinoma in cases in which the disease is limited to the major part of that organ. One method is to clamp the esophagus and the duodenum, remove the stomach, and unite a loop of jejunum and the esophagus. *Gastro-enterostomy*, or more correctly, gastro-jejunostomy, is the establishment of a communication between the stomach and the intestine, preferably the upper portion of the jejunum. This operation is performed for ulcer of the duodenum, as well as for gastric or duodenal ulcer

associated with pyloric stenosis, and cases where excision of the ulcer is impractical or where after excision stenosis with infringement on the human results. It is also performed as a palliative procedure in pyloric cancer which is not amenable to partial gastrectomy. Oftentimes it is used in connection with partial gastrectomy.

Gastro-jejunostomy was first performed in 1881 by Wölfler at the suggestion of his assistant, Nicoladini. The anastomosis originally was made between the small bowel and the anterior wall of the stomach. The results, however, were disappointing, and various modifications were planned until, finally, in 1885, v. Hacker devised the posterior anastomosis, that is, joining the jejunum to the posterior wall of the stomach. This method, with modification, by individual operators, is the one now generally employed. (For the detailed technique of posterior gastroenterostomy and the other stomach operations the student is referred to the author's description in Surgery of the Upper Abdomen, 2nd Ed., Blakiston's Son & Co., Philadelphia, 1921.)

The arteries which supply the stomach are all derived from the celiac axis (*celiac artery*). They are the pyloric branch (*right gastric artery*) of the hepatic, the coronary (*left gastric*), right gastro-epiploic branch of the hepatic, the left gastro-epiploic and the vasa brevia branches of the splenic artery. The pyloric (*right gastric*) and coronary (*left gastric*) arteries anastomose along the lesser curvature; the two gastro-epiploic arteries, along the greater curvature; the vasa brevia supply the cardiac end of the stomach. These arteries can frequently be seen through the overlying peritoneum.

The **lymphatics of the stomach** run chiefly along the curvature between the layers of the omenta, and around the cardiac and pyloric extremities of the organ. They arise in the subserous and submucous coats, and are divided into three sets, accompanying corresponding blood-vessels: one set extends along the lesser curvature, collecting from both walls, and entering the pyloric glands; another extends along the greater curvature, receiving from both walls, and ending in one of the main lacteals at the root of the mesentery; a third set passes off the cardiac end, along the vasa brevia, to the splenic (*left suprapancreatic*) lymph glands. The **nerve supply** of the stomach is through the two vagus nerves and the solar plexus (*celiac plexus*) of the sympathetic.

The **Spleen** (**Lien**) (Plates CCCCVII and CCCCVIII) is found in the left hypochondriac region, although the superomedial extremity is in the posterior part of the epigastric region. With the abdominal viscera in their normal positions the spleen cannot be seen in the dissection, as it is covered by the stomach and the left ribs and costal cartilages. By drawing the stomach to the right and passing the hand beneath the diaphragm and the costal wall, the spleen can readily

PLATE CCCCVII.

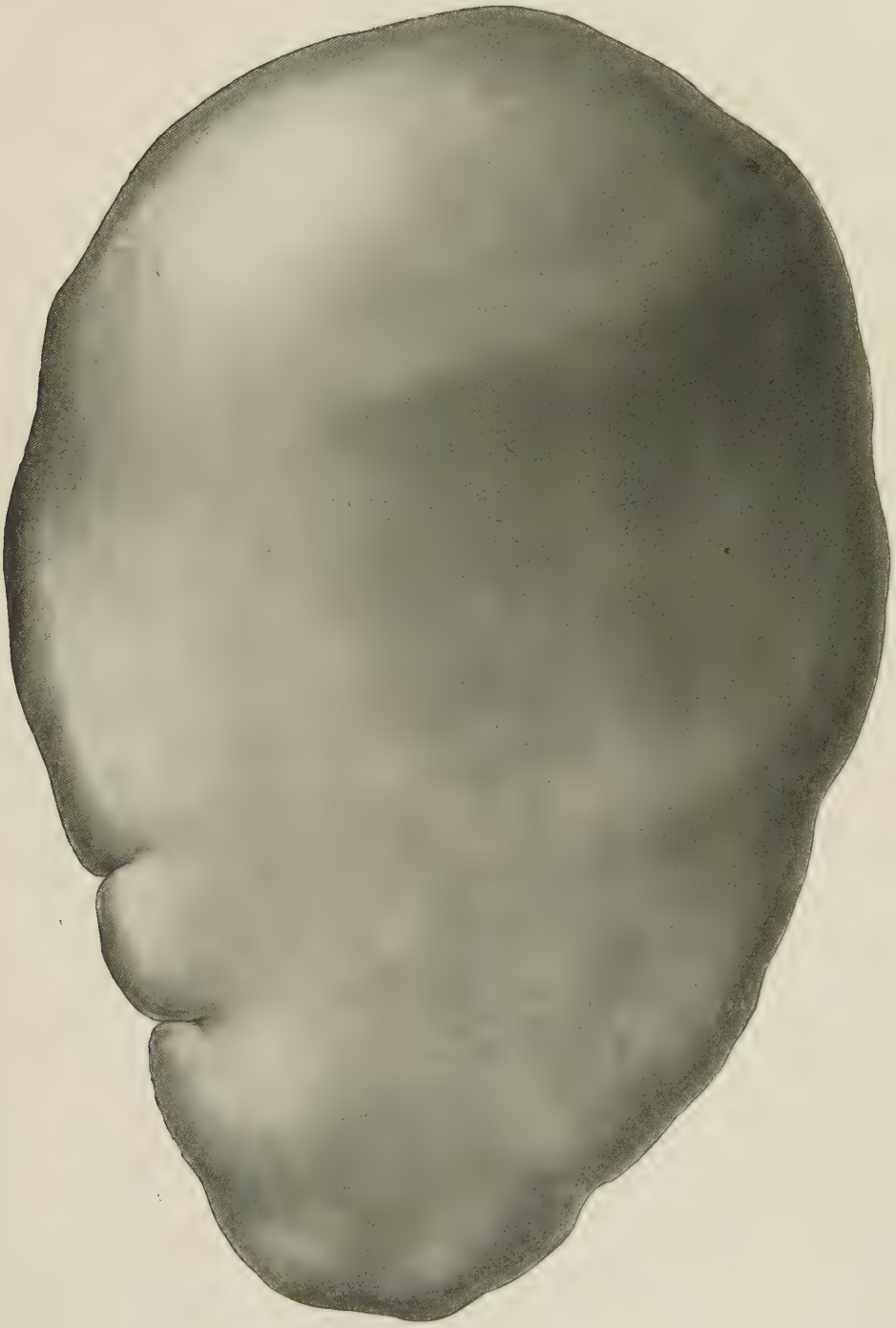

- THE LATERAL SURFACE OF THE SPLEEN.

PLATE CCCCVIII.

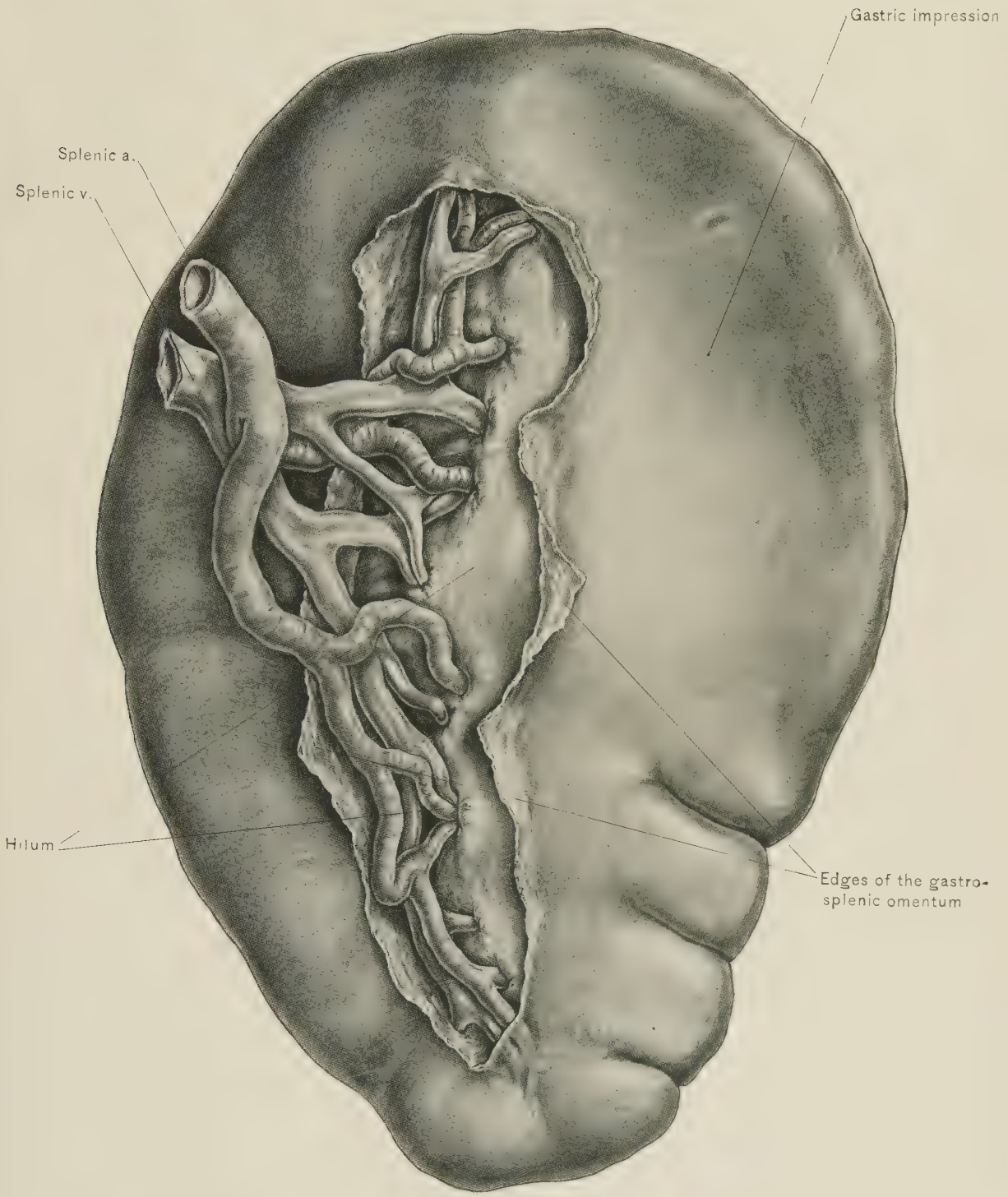

THE MEDIAL SURFACE OF THE SPLEEN.

be felt and drawn into view. It occupies an oblique position in the abdominal cavity, its superior extremity being nearer the median line than its inferior extremity. Anteriorly the spleen extends to the midaxillary line, although sometimes, and within the limits of health, it may reach to the anterior axillary line. When, by percussion, it is determined that the spleen extends beyond the anterior axillary line, it may safely be said that the organ is enlarged. It lies opposite the ninth, tenth, and eleventh ribs, but is separated from the chest-wall by the peritoneum and the diaphragm, and partly by the left pleura and lung. It is an exceedingly vascular, ductless organ, and is the largest of the ductless glands. It is oblong in shape, weighs about 200 grams (seven ounces), and measures from ten to twelve centimeters (four to five inches) in length, seven to ten centimeters (three to four inches) in width, and about two and one-half centimeters (one inch) in thickness. The spleen is enveloped by two coats or coverings, a peritoneal and a fibro-elastic coat. The peritoneal covering invests it very closely, being adherent to the underlying fibro-elastic coat, and can be removed only with difficulty. The fibro-elastic coat is the immediate covering of the spleen, and is so arranged that it cannot possibly be removed without destroying some of the gland tissue. Besides being very adherent to the organ, this tunic sends prolongations, or trabeculæ, into the gland substance. The reflection of peritoneum passing from the splenic (*left colic*) flexure of the colon to the diaphragm and supporting the spleen is known as the *phrenico-colic*, or *suspensory, ligament of the spleen:* that passing from the hilum of the spleen to the stomach is called the *gastro-splenic omentum*, or ligament, and that passing from the hilum to the front of the left kidney, the *lieno-renal ligament.*

The spleen has three surfaces: the phrenic, or diaphragmatic, the gastric, and the renal.

The **phrenic, or diaphragmatic, or posterior surface** is convex, and lies against the diaphragm, opposite the ninth, tenth, and eleventh ribs. The medial aspect of the organ is divided into two distinct concave surfaces by a sharp ridge and a groove, the *hilum*, through which pass the vessels, nerves, and lymphatics of the spleen. The larger of these divisions, the **gastric surface,** is in relation with the cardiac end of the stomach, the splenic (*left colic*) flexure of the colon, and the tip of the tail of the pancreas. The **renal surface** is the smallest division, and rests upon anterior portion of the superior pole of the left kidney and the suprarenal gland. The anterior border of the spleen is almost invariably notched. Sometimes two or more notches are present. Even in great enlargement the notching is still present.

The wedge-shaped, lateral edge of the base of the left lung descends in the costo-phrenic angle between the superior extremity of the spleen and the ribs.

The diaphragm separates the lung from the *spleen.* Left thoracic tumors or intrathoracic accumulations, such as pleural effusions, pneumothorax, or emphysema, may push the spleen downward; on the other hand, intra-abdominal accumulations of gas or fluids or abdominal tumors may push it upward.

The spleen does not descend below the chondral margin, even after deep inspiration; in the adult the normal spleen cannot be felt. When much enlarged, as in leukemia and malaria, its anterior notched edge may at once be detected. A hypertrophied spleen may weigh eight or nine kilograms (eighteen or twenty pounds).

Splenectomy, or removal of the spleen, is now performed for a large variety of diseases. Among these are Banti's disease, hemolytic ictero-anemia, and occasionally for pernicious anemia; also for the various splenomegalies, hepatic cirrhosis, etc. To these must be added the cases of traumatic rupture, abscess, cysts, and tumors of the spleen. Wounds of this organ are likely to be fatal from hemorrhage unless operation is performed early; but if the wound is very small, contraction of the fibro-elastic coat may close it and check the bleeding, but this should not be depended upon. Rupture of a normal spleen occurs from trauma, but not so often as it would if it were less mobile and less protected. When the organ is enlarged, it may be ruptured by either muscular or external violence. This accident is followed by death from hemorrhage unless splenectomy is promptly performed. When one of the left lower ribs is fractured it may pierce the diaphragm and enter the spleen.

The **vessels and nerves of the spleen** reach that organ by passing along the superior border of, or behind the pancreas and then between the two layers of the lieno-renal ligament. Just before it reaches the hilum the splenic artery (see p. 464) breaks up into branches which receive an investment from the fibro-elastic tunic of the spleen and do not anastomose. The arteries terminate and the veins begin in open extremities in the pulp of the organ. The venous radicles unite to form the splenic vein, which is larger than the artery. The splenic vein passes toward the kidney between the layers of the lieno-renal ligament, runs to the right across the left kidney and aorta, behind the pancreas, below the splenic and celiac arteries, above the left renal vein and joins the superior mesenteric vein behind the neck of the pancreas to form the portal vein. The nerve supply is derived from the solar (*celiac*) plexus and the right vagus nerve, filaments from which follow the splenic artery and its branches.

The **lymphatics of the spleen** are found at its hilum, where they receive the superficial and deep lymphatics, that is, from the surface and interior of the organ, respectively. After passing through several glands along the course of the splenic artery they terminate in the celiac (*middle suprapancreatic*) glands.

The **Small Intestine** commences at the pyloric end of the stomach and terminates in the right iliac region, at the junction of the cecum with the colon. Its length is variable. In the male the average length of the small intestine is seven meters (twenty-two and a half feet), the extremes being four and three quarter meters (fifteen feet, six inches) and nine and three-quarter meters (thirty-one feet, ten inches). Its length in the female is greater, the average being seven and one-tenth meters (twenty-three feet, four inches), the extremes being six meters (nineteen feet, ten inches) and nine meters (twenty-nine feet, four inches). Its diameter varies from forty-seven millimeters (nearly two inches) in the duodenum to twenty-seven millimeters (one inch) in the lower end of the ileum.

Position of the small intestine.—The coils of the small intestine occupy no certain fixed position in the abdomen; in the fetus, however, and during the earlier part of extra-uterine life, they are in greater part situated to the left of the midline, on account of the large size of the liver at this time of life. The following description of the arrangement of the coils of the small intestine in the adult is after that of Treves, who has given this subject careful study. Starting from the duodenum, the gut first occupies the contiguous parts of the left side of the epigastric and umbilical regions; the coils then fill some part of the left hypochondriac and lumbar regions; they then usually descend into the pelvis, reappear in the left iliac quadrant, then in the following order, occupy the hypogastric, lower umbilical, right lumbar, and right iliac regions. They then descend again into the pelvis, finally to reappear in the right iliac region. The coils of small intestine in the pelvis are those most likely to become involved and adherent in cases of pelvic peritonitis, which is frequently caused by appendicitis and inflammatory conditions of the uterine appendages. The coils may also be confused with diseased tubes or ovaries or with a cyst of the broad ligament. The coils of the small intestine in the pelvis are also the ones most likely to form the contents of an obturator, sciatic, pudendal, or perineal hernia. The number of coils occupying the pelvis of the adult male depends upon the degree of distention of the bladder and rectum; in the female, largely upon the size of the uterus. In cases of pelvic tumor the number of coils occupying the pelvis is smaller, in proportion to the size of the tumor.

The small intestine consists of three portions; these are the duodenum, the jejunum, and the ileum.

The **duodenum** cannot be satisfactorily studied at this time without dissecting the posterior parietal peritoneum. Since throughout the greater part of its extent it lies deep it will be studied later.

The **jejunum,** "empty intestine," the second portion of the small intestine, commences at the point where the small bowel abruptly turns downward, upon

the left side of the second lumbar vertebra, which is also the point where the mesentery begins, and which marks the termination of the fourth portion of the duodenum. This is the site of the duodeno-jejunal flexure and the muscle of Treitz.

The **ileum,** "twisted intestine", the third portion, has no fixed point of origin. It terminates at its junction with the cecum. The jejunum comprises about two-fifths, and the ileum three-fifths, of the small intestine, there is, however, no definite point where the jejunum can be said to end and the ileum commence. The jejunum and ileum are fixed to the posterior wall of the abdominal cavity by the mesentery, which has been described with the peritoneum.

The jejunum and ileum are protected anteriorly only by the greater omentum and the abdominal wall, and are therefore much exposed to injury; but they are so freely movable that they are rarely contused. Small punctured wounds are not always followed by the escape of septic matter into the peritoneal cavity, because of intra-abdominal pressure, contraction of the muscular coat of the bowel, and plugging produced by protrusion of the mucous membrane. Nature attempts to close larger wounds in the same manner, and the occlusion may be completed by the exudation of lymph and adhesions of adjacent peritoneum upon a coil of intestine or the greater omentum. Involvement of the jejunum, as in hernia, intestinal obstruction, or wounds is more serious than a similar condition of the ileum. The jejunum is distinguished from the ileum by its slightly greater caliber, six millimeters (one-fourth of an inch) greater, and its thicker walls, made so by the valvulæ conniventes (*plicæ circulares*), which nearly disappear in the lower part of the ileum. Obstruction of the small intestine may result from many causes such as: bands and adhesions, hernia, foreign bodies, volvulus, intussusception, stricture, external hernia, internal hernia, tumors, either within or without the bowel; or it may be the result of paralytic ileus. The higher in the bowel the site of the obstruction the earlier do the symptoms make their appearance and likewise the higher the obstruction the more severe the symptoms. This rule also applies to wounds and ruptures. Although the upper portion of the small bowel contains fewer pathogenic micro-organisms, the chemical peritonitis which is early initiated more than offsets the lack of bacterial flora. Fistulæ of the jejunum and duodenum are more apt to cause an excoriating dermatitis, than those of the lower ileum and large bowel. Duodenal and jejunal fistulæ do not show the same tendency to close spontaneously as the fistulæ in the lower bowel. Wounds of the small intestine are treated by suturing them so as to bring the serous surfaces into contact, after which they quickly adhere.

Dissection.—Displace the greater omentum and transverse colon upward, and the coils of the small intestine to the right, thus exposing the junction of the

duodenum and the jejunum on the left side of the vertebral column, opposite the second lumbar vertebra. At this junction the jejunum makes a sharp bend, forming the **duodeno-jejunal flexure.** The coils of intestine should next be displaced to the left, and the termination of the ileum in the cecum examined.

Meckel's diverticulum (**diverticulum ilei**), the remains of the vitello-intestinal duct, is a blind process or diverticulum occasionally springing from the lower part of the ileum, from thirty to ninety centimeters (one to three feet) from the termination of the ileum. It is found in about two per cent of cadavers. It is usually a diverticulum or cord a few centimeters long, springing from the free border of the bowel, but it may extend to the umbilicus as a cord or as a duct which may give rise to an umbilical fecal fistula. When it extends to the umbilicus or becomes adherent to an adjacent peritoneal surface, it forms a band beneath which a loop of small intestine may be caught and strangulated. It may also become acutely inflamed and gangrenous.

The **Large Intestine,** the terminal part of the alimentary tract, consists of the cecum, the colon, and the rectum. Its average length in the male is one and a half meters (four feet, eight inches), and in the female, one and a third meters (four feet, six inches), the extremes being one meter (three feet, three inches), and two meters (six feet, six inches).

The **cecum, or caput coli,** the commencement of the large intestine, is that part of the large bowel which lies below its junction with the ileum. It is about six centimeters (two and a half inches) long, and about seven and a half centimeters (three inches) broad. It rests upon the extraperitoneal connective tissue and the iliac fascia, which covers the iliac and psoas muscles. Its most dependent point, or apex, projects just beyond the medial edge of the psoas major muscle, and is opposite a point a little to the medial side of the middle of Poupart's (*inguinal*) ligament. The cecum may hang over the iliac vessels and the ilio-pectineal line, and occupy the cavity of the pelvis. After the second month of intra-uterine life the cecum gradually recedes from its original position, in the region of the umbilicus, and finally becomes fixed in the right iliac fossa. Non-descent of the cecum is not so frequent as is generally supposed. The long axis of the cecum is not in a straight line with the axis of the ascending colon, but is somewhat oblique, inclining to the left from above downward. The cecum may occupy the sac of a right inguinal or femoral hernia.

The *topographic anatomy of the cecum*, particularly with reference to its relation with the extraperitoneal connective tissue in its immediate neighborhood, as well as with the large vessels in its vicinity, is of importance in connection with the treatment of inflammatory lesions of the vermiform appendix (*vermiform process*). A knowledge of the relation of the postperitoneal connective tissue is of

special importance for a correct understanding of those cases of appendiceal abscess in which the appendix is only partly covered by peritoneum, and in which the perforation opens into the interval between the layers of the meso-appendix. A collection of pus thus formed in the retroperitoneal connective tissue may make its escape by following the sheath of the iliac muscle to the front of the thigh.

The **vermiform appendix** (**vermiform process**) is a narrow, musculo-membranous tube ending in a blind extremity, and is the lower end of the cecum which failed to grow as fast as the remainder of the cecum. It is present only in man and some of the higher species of apes; in other mammalia an elongated cecum is found. The appendix is usually attached to the medial and posterior wall of the cecum, the point which was originally the apex of the latter.

The cecum occurs in one of four different *types*, in each of which the appendix arises in a different manner. (1) The fetal type, in which the appendix is the narrow lower end of the conical cecum, the apex of the cone being continued into the appendix. (2) The cecum consists of two equally large sacculi at its lower end. In this type the appendix arises from the end of the cecum, between the sacculi, which are separated by the anterior longitudinal band. (3) The lateral sacculus is large, and the medial one small, thus bringing the base of the appendix nearer the ileo-cecal (*colic*) valve. In addition the anterior wall of the cecum grows more rapidly than the posterior, so that the root of the appendix is attached to the posterior surface of the cecum. (4) The medial sacculus has disappeared entirely, and the base of the appendix is attached to the posterior wall of the cecum behind the junction of the ileum and cecum. As a rule, the cecum is completely covered by peritoneum, although occasionally its posterior surface may be bound down in the right iliac fossa.

In cases of nondescent of the cecum the appendix will hold a corresponding abnormal position; and may then even lie to the left of the median line. Lennander mentions the case of a boy of sixteen in whom the cecum and the appendix, which was twenty-two centimeters (nine inches) long, were found in the left hypochondriac region, lying against the spleen.

The appendix varies in length from one to twenty-three centimeters (one-half to nine inches), the average length being from eight to ten centimeters (three to four inches). When the appendix is long, the cecum, as a rule, is small. Its diameter is that of a goose quill, or three to six millimeters (one-eighth to one-fourth of an inch). It is hollow, and has an opening of communication with the cecum, which is usually guarded by a valve of mucosa.

Position of the vermiform appendix (Plate CCCCIX).—The base or root of the vermiform appendix is usually attached to the posteromedial aspect of the cecum, just below the junction of the ileum with the cecum. This can be easily

PLATE CCCCIX.

Umbilicus
Appendix directed superomedialward under attachment of mesentery
Appendix directed inferiorly into pelvis
Appendix directed transversely medialward under mesentery and ileum
Psoas m.
External iliac a.
Iliacus m.
Anterior superior spine of ilium
Appendix directed superolateralward behind and in front of cecum
Mesentery
Ileum
Appendix directed superomedialward behind cecum and in front of ascending colon
McBurney's point
Appendix directed superolateralward behind cecum
Cecum
Appendix coiled behind cecum
Appendix directed downward
Transverse colon
Hepatic flexure
Ascending colon
Unusually long appendix, lying behind cecum and in front of hepatic flexure and transverse colon
Appendix directed laterally

DIAGRAM OF POSITIONS OF THE VERMIFORM APPENDIX.

located by tracing downward the anterior longitudinal band. The location of this portion of the appendix varies much less than the remainder of the organ. Usually the base of the appendix is nearly opposite **McBurney's point,** which is situated midway between the umbilicus and the anterior superior spine of the ilium; consequently in appendicitis tenderness on pressure is most constantly detected at this point, although tenderness may be most marked at a point some distance from this point, since the terminal part of the appendix may hold one of several positions. As previously stated, the position of the root of the vermiform appendix varies very little. The remaining and more movable portion of the organ may take any one of several directions or positions: (1) it may be directed superiorly or superolateralward, lying in front of, behind, or upon either the medial or the lateral side of the cecum and the ascending colon; (2) it may be directed under the mesentery, and superomedialward, medialward, or inferomedialward over the brim of the pelvis; (3) it may be coiled upon itself under the cecum; (4) it may be directed downward, and lie free under the cecum; (5) it may be directed lateralward, lying in front of, or behind the cecum.

The appendix may occupy the ileo-colic (*superior ileo-cecal*), ileo-cecal (*inferior ileo-cecal*), or subcecal (*retrocecal*) fossa, but it is most frequently found in the ileo-cecal (*inferior ileo-cecal*) fossa. When it occupies a deep ileo-cecal or subcecal (*retrocecal*) fossa which has become closed by local peritonitis, there occurs practically a retroperitoneal hernia of the appendix. Again, if it lies in one of these fossæ and the mouth of the fossa closes over it, it may be regarded by the inexperienced operator as absent. Suppuration due to inflammation of an appendix so walled in would be circumscribed. Among uncommon positions held by the appendix are: (1) behind the peritoneum, below the cecum, adherent to the under surface of the cecum and in contact with its muscular wall, and covered by its peritoneal coat; (2) adherent to the peritoneum along the right border of the cecum and ascending colon; (3) adherent to the peritoneum at any point in the neighborhood of the cecum; or (4) in the inguinal canal.

When the appendix is directed superiorly or superolaterally, and lies behind or upon the lateral side of the cecum, an abscess resulting from disease of the appendix frequently produces its local manifestations in the loin and simulates abscess of hepatic or renal origin. When the inflamed organ is directed downward or downward and medialward into the true pelvis, irritation of the bladder or ovaries may ensue, and the pain will then be on the left side.

The **colon,** the second portion of the large intestine, consists of an ascending, a transverse, and a descending portion; it makes three bends or flexures: the hepatic (*right colic*), splenic (*left colic*), and sigmoid (*iliac colon*).

The **ascending colon,** the average length of which in the adult is twelve centimeters (five inches), extends upward from the cecum through the right lumbar into the right hypochondriac region to the under surface of the right lobe of the liver, with which it comes in contact on the right side of the gall-bladder. Here the colon makes an abrupt turn, the **hepatic** (**right colic**) **flexure,** and passes across the abdomen as the transverse colon. It lies upon the quadratus lumborum muscle, the right kidney, and the descending portion of the duodenum; to its medial side are situated the convolutions of the small intestine. When the colon is collapsed, the convolutions of the small intestine lie in front of it; but when distended, the colon is immediately behind the anterior abdominal wall. It is fixed to the posterior wall of the abdomen by extraperitoneal connective tissue and the peritoneum, which covers it in front and on the sides, and usually leaves the posterior third of this portion of the colon destitute of a peritoneal coat. In about twenty-five per cent of cases the peritoneum surrounds it completely, forming a genuine mesocolon.

The **transverse colon** is about fifty centimeters (twenty inches) in length, and is the longest and most movable portion of the large intestine. It passes from the right hypochondriac region through the lower part of the epigastric and the upper part of the umbilical to the left hypochondriac region; there it approaches the spleen, and turns downward as the **splenic** (**left colic**) **flexure,** to become the descending colon. The splenic (*left colic*) flexure is situated higher than the hepatic (*right colic*) flexure, being under the costal margin. In the epigastric and umbilical regions the transverse colon lies just below the greater curvature of the stomach. It makes a long curve, the convexity of which is directed downward and forward. From its lower border is suspended the greater omentum. Above it are the liver, the gall-bladder, the stomach, and the lower extremity of the spleen; below are the greater omentum and the small intestine; behind are the transverse mesocolon, the descending and the transverse portion of the duodenum and in front are the greater omentum and the anterior abdominal wall. It is entirely surrounded by peritoneum, and is attached to the posterior wall of the abdominal cavity by the transverse mesocolon. Attached to it are a number of small pouches of peritoneum containing fat, the **appendices epiploicæ.**

In some instances, especially when posted, the transverse colon may curve so far downward that its most dependent part may reach the crest of the pubis or the pelvis, while the hepatic (*right colic*) and splenic (*left colic*) flexures continue to maintain their proper positions. The mobility of this part of the colon permits fecal accumulations to carry it downward. When examining obscure tumors of the abdominal cavity, it is important to bear in mind the possible variations in the position of this part of the large intestine.

The relation which the hepatic (*right colic*) flexure bears to the gall-bladder and the liver explains why it is found stained with bile after death, also how in calculus impaction of the gall-bladder a communication, the result of ulcerative inflammation, may be established between the gall-bladder and the transverse colon (cholecysto-colostomy), through which the former may empty itself; and, also, how an hepatic abscess may be evacuated spontaneously through the transverse colon. In the small space in the upper right abdomen are found the hepatic (*right colic*) flexure, the gall-bladder, and the duodenum. These, together with the fact that a high-lying appendix may become diseased in this location, may make diagnosis in this region very difficult.

The relation of the transverse colon and transverse mesocolon to the abdominal aorta explains how an aneurysm of that vessel may burst into the transverse colon, the blood first passing between the two layers of the transverse mesocolon. A fecal mass in the transverse colon may be mistaken for a tumor arising from the transverse colon, stomach, greater omentum, pancreas, or lymph glands.

The **descending colon,** about twenty centimeters (eight inches) in length, commences at the splenic (*left colic*) flexure of the colon in the left hypochondriac region, and descends almost vertically through the left lumbar region into the left iliac fossa, where, at the lateral border of the psoas muscle, it terminates in the sigmoid flexure of the colon (*iliac colon*). At its commencement it is attached to the diaphragm, opposite the tenth and eleventh ribs, by a fold of peritoneum, the **phreno-colic ligament,** upon which rests the lower end of the spleen. Like the ascending colon, it is fixed to the posterior wall of the abdomen by extraperitoneal connective tissue and the peritoneum which covers it in front and on the sides. A mesocolon with its two layers in contact is found more frequently on this side than on the right side, being present in about thirty-five per cent of cases. The descending colon is smaller than the ascending, more deeply situated, and more movable.

Relations.—Behind the descending colon are the left crus of the diaphragm, the left kidney, and the quadratus lumborum muscle; to its medial side and in front are the convolutions of the small intestine; on its lateral, or left, side is the abdominal wall.

From the relation which the ascending and the descending portions of the colon hold to the right and left kidney, respectively, and the quadratus lumborum muscles, it follows that a renal or vertebral abscess may be evacuated by the way of either part of the colon. In advanced malignant growths of the kidney either the ascending or the descending colon, according to which kidney is affected, may become involved.

The colon is capable of becoming so much distended as to give rise to shortness of breath and palpitation of the heart. Distention of the large intestine renders the sides (flanks) and upper abdomen especially prominent, while distention of the small intestine renders the central and inferior abdomen prominent.

The **sigmoid flexure** (**iliac and pelvic colon**), is also known as the sigmoid colon, pelvic colon, and because of its loop shaped like the Greek letter Ω, the omega loop. It is about forty-five centimeters (seventeen to eighteen inches) in length, commences at the termination of the descending colon, opposite the lateral border of the psoas muscle, in the left iliac fossa, and terminates opposite the middle piece of the sacrum, at the lower limit of the mesosigmoid (*pelvic mesocolon*). It is the narrowest portion of the colon, and, as here described, includes that which in many of the text-books is described as the first portion of the rectum. Normally, owing to its long mesosigmoid (*pelvic mesocolon*), the greater part of the sigmoid flexure (*iliac and pelvic colon*) occupies the pelvis. Although the peritoneum usually begins to surround the gut at this level, it frequently occurs that the meso is exceedingly short until the lower portion of the sigmoid (often called the pelvic) colon is approached. Here it lies in contact with the bladder, the uterus and its appendages, and those coils of the small intestine which lie in the pelvis. In the surgical anatomy of the pelvis, especially that of the female, the sigmoid flexure (*iliac and pelvic colon*) figures conspicuously. If distended with gas, it may rise out of the pelvis and enter the lower abdomen. It is completely surrounded by peritoneum, and is held in position by the mesosigmoid, which includes what many text-books describe as the mesorectum. The psoas muscle, external iliac vessels, spermatic vessels, and ureter lie behind the sigmoid flexure (*iliac and pelvic colon*). In constipation the resistance offered to the return flow of blood through the left spermatic vein, produced by pressure of the sigmoid flexure (*iliac and pelvic colon*) upon that vessel is one of the reasons for the more common occurrence of varicocele upon the left than upon the right side.

The **recto-sigmoid curve** is the abrupt bend formed at the junction of the sigmoid flexure (*pelvic colon*) and the rectum, caused by gravitation of the movable sigmoid flexure (*pelvic colon*) to the floor of the pelvis and the immobility of the rectum. It is this curve which oftentimes makes it difficult, to pass a long tube through the rectum into the sigmoid flexure (*pelvic colon*). This curve can be obliterated by having the patient assume the "knee-chest position." The recto-sigmoid junction is found at the middle of the third sacral vertebra. It is here that the mesentery of the sigmoid (*pelvic colon*) terminates. This is about twelve and one-half centimeters (five inches) from the rectal sphincters.

Digital examination for tumors of the recto-sigmoid.—The relative positions held by the terminal part of the sigmoid flexure (*pelvic colon*) and the first portion of the rectum should be borne in mind when examining for a suspected growth involving this part of the sigmoid. With the finger in the rectum, quite a small growth in the terminal part of the sigmoid flexure (*pelvic colon*) can sometimes be detected. The point of the finger is not brought into immediate contact with the growth, since the distance from the anal orifice varies from twelve to fifteen centimeters (five to seven inches), but the tumor can be felt through the intervening wall of the first portion of the rectum. It is a well-recognized fact that malignant growths of the large bowel are more commonly met with in the rectum than elsewhere, and, next in frequency in the sigmoid flexure (*iliac and pelvic colon*). I have been able to detect a very small growth in the terminal part of the simgoid flexure (*pelvic colon*) with the finger engaged in the rectum, and also to make the diagnosis of early cancer in several cases in which an autopsy subsequently proved the diagnosis to have been correct. The patient should lie on his left side with the legs and the thighs strongly flexed and the body curved well forward. Cases of malignant growths or infiltration of the walls of the terminal part of the sigmoid flexure (*pelvic colon*) and of the mesosigmoid (*pelvic mesocolon*) are sometimes diagnosed as rectal. Furthermore, owing to the relationship of the terminal part of the sigmoid flexure (*pelvic colon*) and the left ovary, carcinoma of this part of the bowel may be mistaken for a growth of the ovary. The relation which the sigmoid flexure bears to the uterus and its appendages, emphasizes the importance of having the lower bowel emptied in examining *per vaginam* a case of suspected mass or growth of small size.

Course of the sigmoid flexure (iliac and pelvic colon).—In tracing the sigmoid flexure (*iliac and pelvic colon*) from its origin, it will be seen, first to cross the psoas muscle and the external iliac vessels at a right angle, then to descend vertically to the floor of the pelvis along its left wall. From this point it runs along the floor near to the right wall of the pelvis, turns upon itself, and passes to the left of the median line, to terminate in the rectum. The line of attachment of the mesosigmoid (*pelvic mesocolon*) corresponds to that of the flexure as far as its place of entrance into the pelvic cavity; from here on to its termination it corresponds to an oblique line extending from the point on the brim of the true pelvis, over which the sigmoid passes, to one opposite the third segment of the sacrum, or to a point about six centimeters (two and a half inches) below the promontory. The portion of the sigmoid flexure (*pelvic colon*) which lies in the pelvis is completely covered by peritoneum and has an extensive mesentery.

Volvulus, one of the varieties of acute internal intestinal obstruction, affects the sigmoid flexure (*iliac and pelvic colon*) more commonly than any other portion of the intestinal tract.

Gross difference between the large and the small intestine.—The peculiarities which distinguish the large intestine are: the presence of the three flat bands of longitudinal muscle fibers, its lesser degree of mobility, its greater size, and the presence of the sacculations, the appendices epiploicæ, and the scybalous masses usually found in it. The peculiarities of the small intestine are: its shorter diameter, its mesentery, the transverse ridges produced by the valvulæ conniventes (plicæ *circulares*), which can be felt by rolling the small intestine between the fingers, and the absence of the characteristics of the large intestine.

Accessibility of the colon to pressure.—The colon is accessible to pressure from the cecum to the sigmoid flexure (*pelvic colon*), except at the hepatic (*right colic*) and splenic (*left colic*) flexures, which are deeply located.

The **capacity of the large intestine in the adult,** excluding that of the rectum, is about four or five liters (four or five quarts) of water; the rectum, when distended, is capable of holding from about one to one and a half liters (one to one and a half quarts). In an obscure case, in order to differentiate between obstruction of the large and the small intestine, the capacity of the large intestine should be ascertained.

The **mesosigmoid** (**pelvic mesocolon**) is the long fold of peritoneum connecting the pelvic portion of the sigmoid flexure (*iliac and pelvic colon*) to the posterior wall of the pelvis. In the left iliac fossa the sigmoid flexure (*iliac colon*) lies against the posterior wall, as a rule, having no mesentery. The peritoneum surrounds the sigmoid flexure (*pelvic colon*) completely, and consists of two layers and an intervening process of extraperitoneal connective tissue which transmits the vessels and nerves supplying this portion of the bowel.

The Kidneys.—Although the kidneys cannot be studied at this stage of the dissection, their position should be noted, and their relations to the other organs observed. They are found in the hypochondriac and lumbar regions, and extend slightly into the epigastric and umbilical regions. The right kidney occupies a somewhat lower position than the left, because the liver lies above it. It will be seen that in front the left kidney is in relation with the stomach, the pancreas, the spleen, and the descending colon, and the right kidney with the liver, the ascending colon, and the duodenum. As the kidneys are situated retroperitoneally and are surrounded by more or less extraperitoneal fat, these organs do not come in direct contact with the kidney or its capsule, although the superimposed weight of the liver and the spleen is sufficient to make impressions on the surfaces of those viscera.

PLATE CCCCX.

STRUCTURES IN GREATER OMENTUM AND LESSER OMENTUM.

Dissection.—Before removing any of the viscera, certain vessels should be dissected as far as possible, because removal of the organs necessitates division of the vessels which supply them. In exposing these structures, they should be dissected in the following order: (1) those occupying the gastro-hepatic omentum; (2) those along the greater curvature of the stomach and between the descending layers of the greater omentum; (3) those between the layers of the gastro-splenic omentum (*gastro-splenic ligament*), (4) those behind the peritoneum above the transverse mesocolon; (5) those between the layers of the mesentery; (6) those behind the parietal peritoneum on each side of the root of the mesentery, and, (7) those running between the layers of the mesosigmoid (*pelvic mesocolon*) (Plate CCCCX).

The structures between the layers of the gastro-hepatic and the hepato-duodenal omentum are exposed by removing portions of the anterior layer of that omentum. Along its right or free border are the hepatic, the cystic, and the common bile ducts, the hepatic artery, and the portal vein. The common bile duct lies to the right, the artery to the left, and the vein, behind and between the artery and the duct. These structures, including lymph vessels and sympathetic nerve-fibers, are surrounded by a sheath of loose connective tissue, which is a process of extraperitoneal connective tissue, and is part of **Glisson's capsule** (**fibrous capsule**) which is the fibrous investiture of the liver. Along the gastric border of the lesser omentum and between its two layers are the pyloric vessels and the terminal part of the coronary (*left gastric*) vessels.

The **common bile duct** (**bile duct**) is usually about seven to nine centimeters (three to four inches) long, but varies with the length of the hepatic and cystic ducts. Its normal diameter is about six millimeters but it may be dilated as the result of ductal obstruction. It is formed in the lesser omentum, by the union of the hepatic and cystic ducts, either just inside or outside of the porta hepatis. It runs first between the layers of the lesser omentum and in front and to the right of the portal vein, along the right border of that omentum, lying to the right of the hepatic artery. In the second part of its course it passes behind the first portion of the duodenum lying in front of the portal vein and to the right of the gastro-duodenal artery. Thence it passes along the left side of the second portion of the duodenum and behind the head of the pancreas, in front of the inferior vena cava, and finally turns slightly to the right, descending between the second portion of the duodenum and the head of the pancreas. As it passes downward it may be completely enclosed in pancreatic tissue. This is seen in about two-thirds of the cases examined in the dissecting room. It is joined by the pancreatic duct, and together they pierce obliquely the wall of the left side of the lower part of the second portion of the duodenum, at a point about ten centi-

meters (four inches) from the pylorus. The duct runs for about two centimeters (three-quarters of an inch) obliquely in the wall to empty into the descending duodenum. In order to obtain a good view of the opening, it is necessary to open the anterior duodenal wall, when the orifices of these ducts will be seen as a slight projection of the mucous membrane, known as the **papilla of Vater** (**papilla duodeni**) guarded on its superior surface by a further fold or hood of mucus membrane, while from its inferior surface a slight fold runs vertically downward for one centimeter (one-half inch) which is known as the frenum. The papilla contains a fusiform dilatation, the ampulla of Vater (*ampulla of bile duct*), into which the common duct and the pancreatic duct usually open by a common orifice. The sphincter at the papilla is known as the muscle of Oddi. The presence of the muscle of Oddi is questionable, the contractions of the papilla of Vater being more probably due to the musculature of the wall of the duodenum. It is into this dilatation, the ampulla of Vater (*ampulla of bile duct*), that a gall-stone is apt to lodge since the orifice of communication with the bowel is small and angular. Carcinoma affecting the papilla will give much the same symptoms as carcinoma of the head of the pancreas or calculous obstruction of the common duct, except that in the last-named the pain and jaundice are more likely to be intermittent. The hepatic and the pancreatic ducts may each, however, empty separately into the duodenum. The common bile duct is loosely connected with the surrounding parts by connective tissue, and with care may be separated from the portal vein and the hepatic artery; if great gentleness is not observed, either the portal vein or the vena cava will be torn.

Surgery of the common bile duct.—The relation which the common bile duct bears to the gall-bladder and the head of the pancreas, makes it readily seen how obstructive jaundice may result from occlusion due to stone or to carcinomatous or other involvement of this part of the pancreas. By dividing the posterior parietal peritoneum from the foramen of Winslow (*epiploic foramen*) downward along the right side of the second portion of the duodenum, and pulling the descending portion of the duodenum toward the median line, the retroduodenal portion of the common bile duct may easily be exposed and incised. The third portion of the duct is best explored by opening the second portion of the duodenum and incising the duct in the posterior inner wall of the bowel after finding the papilla of Vater (*papilla of bile duct*). A penetrating wound of the abdomen through the back, not piercing the peritoneal cavity, may open the retroperitoneal portion of the common bile duct and result in extraperitoneal extravasation of bile. Ulcerative perforation of the bile duct by gall-stone or rupture may take place either extraperitoneally or intraperitoneally, more often, however, the latter.

The common duct may also be constricted by stricture following ulceration, by metastatic invasion of the gastro-hepatic omentum, chronic pancreatitis, or aneurysm of branches of the celiac axis (*celiac artery*). Reconstruction of the common duct is sometimes necessary following the operation of cholecystectomy where injury to the common duct results in an external biliary fistula. The continuity of the duct may be restored by direct suture or a cannula may be inserted in the upper and lower ends of the divided ducts or the duct may be reconstructed with fascia or the upper end of the duct may be implanted either in the mobilized duodenum or the stomach.

The **hepatic duct** is considerably larger than the cystic, though not so large as the common bile duct. It is formed by the union of two large branches in the transverse fissure (*porta hepatis*) of the liver, runs obliquely downward and medialward between the layers of the lesser omentum for a distance of about two to four centimeters (three-fourths of an inch to one and a half inches), and is joined by the cystic duct. It is in intimate relation with the hepatic artery, which runs along its left side, and with the portal vein, which lies behind and to the left side of it. Lying behind or crossing in front of the duct is the cystic artery, a branch of the hepatic artery, a point important to bear in mind when making an incision into the duct.

The **cystic duct,** which is practically the elongated neck of the gall-bladder, varies in length from two to four centimeters (one to one and a half inches). In a normal condition of the duct it is impossible to carry the smallest probe through it, owing to its double curved course and the peculiar arrangement of its mucous lining in the valve of Heister (*spiral valve*). The terminal portion of the cystic duct, where it joins the hepatic duct to form the common bile duct, lies in front of the portal vein, with loose areolar tissue intervening. The two important points to remember in incising the cystic duct, as in the extraction of a stone, are its relation with the cystic artery and with the portal vein, the artery lying above and behind the duct, and the portal vein behind it, at the junction of the cystic and hepatic ducts. There are numerous anomalies of the cystic duct which the surgeon must keep in mind. It may be longer or shorter than normal; it may parallel the common duct before emptying into it or it may be so short that the neck of the gall-bladder fits on the common duct.

The **hepatic artery,** the origin of which cannot be seen until the posterior parietal peritoneum has been removed, is one of the three branches of the celiac axis (*celiac artery*). In the adult it is intermediate in size between that of the coronary (*left gastric*) and the splenic arteries, but in the fetus it is the largest of the three branches. It arises from the right side of the celiac axis (*celiac artery*), passes to the right, and runs forward along the upper border of the head of the

pancreas, behind the ascending layer of the posterior parietal peritoneum, to the upper border of the pyloric end of the stomach or of the first portion of the duodenum. Thence it runs upward between the two layers of the gastro-hepatic omentum to reach the transverse fissure (*porta hepatis*) of the liver; here it divides into a right and a left branch, for the supply of the two segments of that organ which are separated by the longitudinal (*left sagittal*) fissure. In its course it first lies below the foramen of Winslow (*epiploic foramen*) and then anterior to it. The hepatic plexus of sympathetic nerves accompanies this artery.

The **branches of the hepatic artery** are the pyloric (*right gastric*), gastro-duodenal, and the right and left hepatic arteries.

The **pyloric (right gastric) artery** arises from the hepatic artery at a point a short distance above its entrance into the lesser omentum. It descends to the upper border of the pylorus, turns to the left, and runs along the lesser curvature of the stomach, and anastomoses with the terminal part of the coronary (*left gastric*) artery. It gives branches to both surfaces of the stomach.

The **pyloric (right gastric) vein** arises from small veins along the lesser curvature of the stomach, runs upward and toward the right, and empties into the lower part of the portal vein. It should not be confused with the congerie of veins which marks the pyloric sphincter.

The **gastro-duodenal artery** arises from the hepatic artery between the layers of the gastro-hepatic omentum, and descends behind the first portion of the duodenum to its lower border, where it divides into two terminal branches, the right gastro-epiploic and the superior pancreatico-duodenal arteries. The greater portion of the gastro-duodenal artery, as well as the commencement of the superior pancreatico-duodenal branch, cannot be satisfactorily seen until the first and second portions of the duodenum and the head of the pancreas have been displaced. There is no vein which corresponds to this artery. The artery may lie anterior to the distal portion of the common bile duct and may be injured during operations on that structure.

In operations upon the stomach, on account of the distribution of the vessels, the walls, and not the curvatures, are selected for the point of incision.

The **superior pancreatico-duodenal artery** takes a curved course downward and to the right around the margin of the head of the pancreas, between it and the duodenum, to both of which it supplies branches. It terminates by anastomosing with the inferior pancreatico-duodenal, which is a branch of the superior mesenteric artery.

The **pancreatico-duodenal vein,** drains the area supplied by the pancreatico-duodenal arteries, and empties into the superior mesenteric vein.

The **cystic artery** usually arises from the division of the hepatic artery going to the right lobe of the liver, and runs to the gall-bladder, behind and above the cystic duct, and behind or in front of the hepatic duct. It divides into two branches, one of which ramifies over the free surface beneath the peritoneum, the other over the attached surface, which is in contact with the liver. This artery is sometimes quite large, and is of importance in the surgery of the biliary tract. It may give rise to fatal hemorrhage. During the operation of cholecystectomy, it is preferable to ligate it separately from the cystic duct. The blind application of hemostatic forceps in order to control hemorrhage after cholecystectomy is one of the most frequent causes of traumatic stricture of the common bile duct.

The **cystic vein** accompanies the cystic artery, and usually empties into the right branch of the portal vein.

The **coronary** (**left gastric**) **artery** is the smallest of the three branches of the celiac axis (*celiac artery*). It runs toward the left and slightly upward on the left crus of the diaphragm, behind the lesser peritoneal cavity and the posterior parietal peritoneum, until it approaches the lesser curvature of the stomach, just below the termination of the esophagus. Here it turns forward between the two layers of the gastro-phrenic ligament, and gives off two or three esophageal branches which ascend through the esophageal hiatus, and a small hepatic branch which enters the left lobe of the liver. In the remainder of its course it runs downward toward the right, between the two layers of the lesser omentum and along the lesser curvature of the stomach, giving branches to both surfaces. It gives off an hepatic branch to the left lobe of the liver, esophageal branches to the lower portion of the esophagus, and gastric branches to the anterior and posterior walls of the stomach, and finally anastomoses with the pyloric (*right gastric*) artery.

The **coronary** (**left gastric**) **vein** follows the course of the gastric artery, except that it runs in the opposite direction. It empties into the portal vein.

The **portal vein** (**vena portæ**) is formed by the union of the superior mesenteric and splenic veins, behind the head of the pancreas and in front of the inferior vena cava. It receives blood from the spleen, pancreas, and the abdominal part of the alimentary canal, except part of the blood from the anal canal and the lower end of the rectum. The larger veins forming the portal vein have no valves, but the smaller tributaries have. It is from seven to ten centimeters (three to four inches) in length, passes upward and to the right, behind the first portion of the duodenum, and then between the layers of the lesser omentum. It is surrounded by branches of the hepatic plexus of the sympathetic nerves, lymph vessels and glands, and a prolongation, the capsule of Glisson (*fibrous capsule*). It lies behind the common bile and hepatic ducts and the hepatic artery, the

ducts being to the right, the artery to the left, and the vein behind and between the artery and the ducts. Like the hepatic artery, it divides at the transverse fissure (*porta hepatis*) of the liver into a right and a left branch, which enter the respective lobes at that fissure. The branch passing to the right lobe of the liver is almost a direct continuation of the portal vein, while the branch passing to the left lobe diverges at a right angle from the main stem. Owing to the more direct course of the right branch, infectious material carried from the stomach or intestines to the liver by the portal vein is more likely to enter the right branch and lead to involvement of the right lobe. A slight dilatation immediately below the point where it divides into its two branches is called the sinus of the portal vein. It receives the coronary (*left gastric*), the pyloric (*right gastric*), and the cystic veins. The veins of the portal system are the portal, gastric, splenic, and superior and inferior mesenteric veins.

The radicles of the portal vein anastomose with the systemic veins in numerous places. Some of these anastomoses are: radicles of the superior hemorrhoidal vein anastomose with branches of the middle and inferior hemorrhoidal veins, these last being tributaries of the internal iliac (*hypogastric*) vein; the gastric tributaries of the portal vein anastomose with the lower esophageal veins, which empty into the azygos vein. In the suspensory ligament of the liver are veins which connect the portal system with the veins of the diaphragm; along the round ligament of the liver there are one or two veins which effect an anastomosis between the portal system and the veins of the abdominal wall. In case of obstruction to the portal vein, as in cirrhosis of the liver, these anastomosing channels may become enlarged forming the characteristic **caput Medusa,** to assist in establishing collateral circulation. It is appropriate in this connection, to remind the reader of the enlargement of the spleen met with in cirrhosis of the liver, due to the constant venous congestion of that organ from the interference with the portal circulation and consequent damming back of the blood in the splenic vein. In order to relieve the portal circulation of the splenic blood splenectomy has been advised in hepatic or biliary cirrhosis.

The Vessels between the Descending Layers of the Gastro-colic, or Greater Omentum.—These vessels, the right and the left gastro-epiploic, with their descending branches, are exposed by removing the anterior of the two layers of the greater omentum along the greater curvature of the stomach.

The **right gastro-epiploic artery** arises from the gastro-duodenal artery, and runs along the greater curvature of the stomach, between the descending layers of the greater omentum. It sends branches to both surfaces of the stomach and the greater omentum, and anastomoses with the left gastro-epiploic artery.

PLATE CCCCXI.

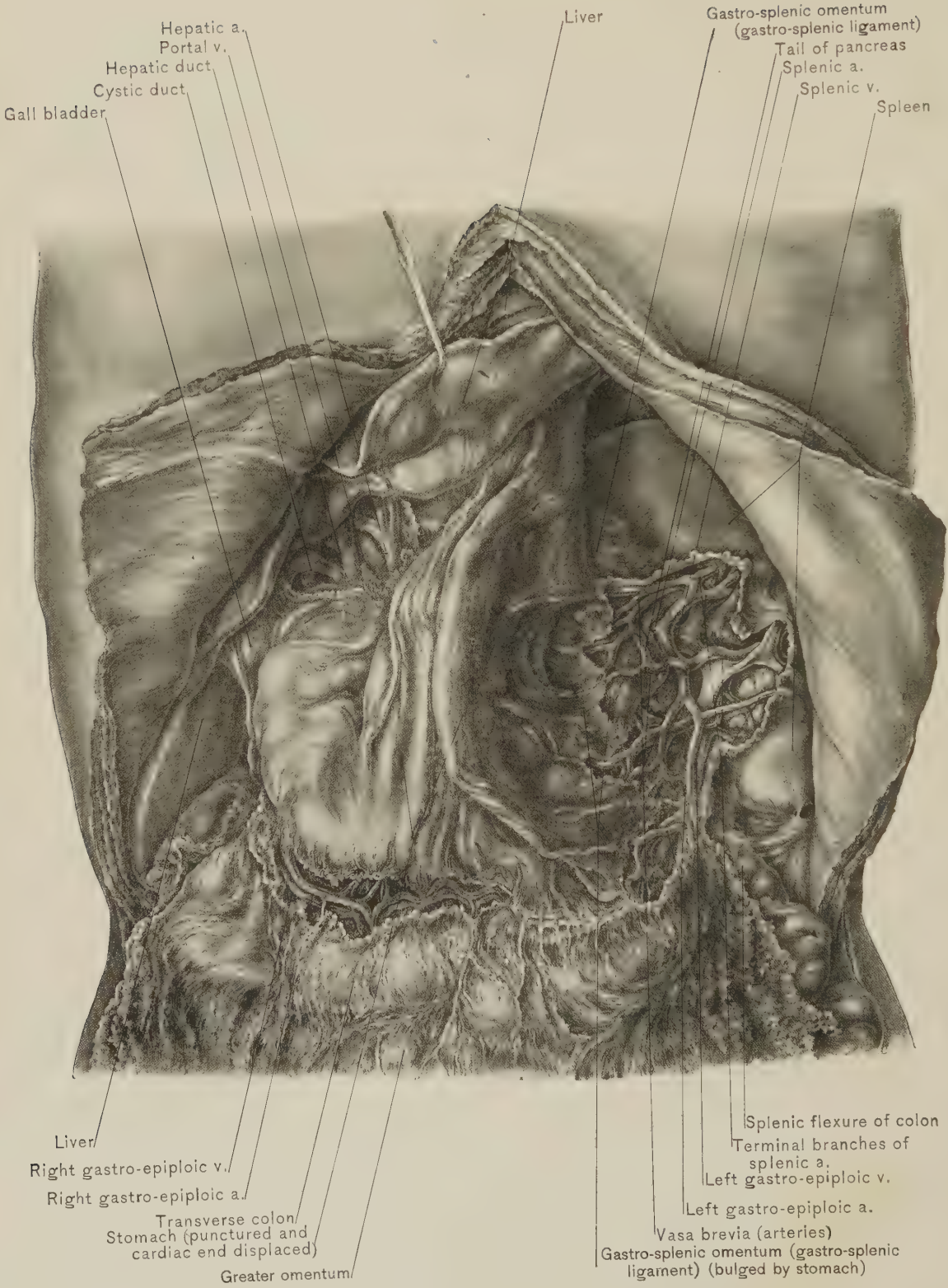

VASA BREVIA. STRUCTURES IN THE GASTRO-SPLENIC OMENTUM (GASTRO-SPLENIC LIGAMENT).

PLATE CCCCXII.

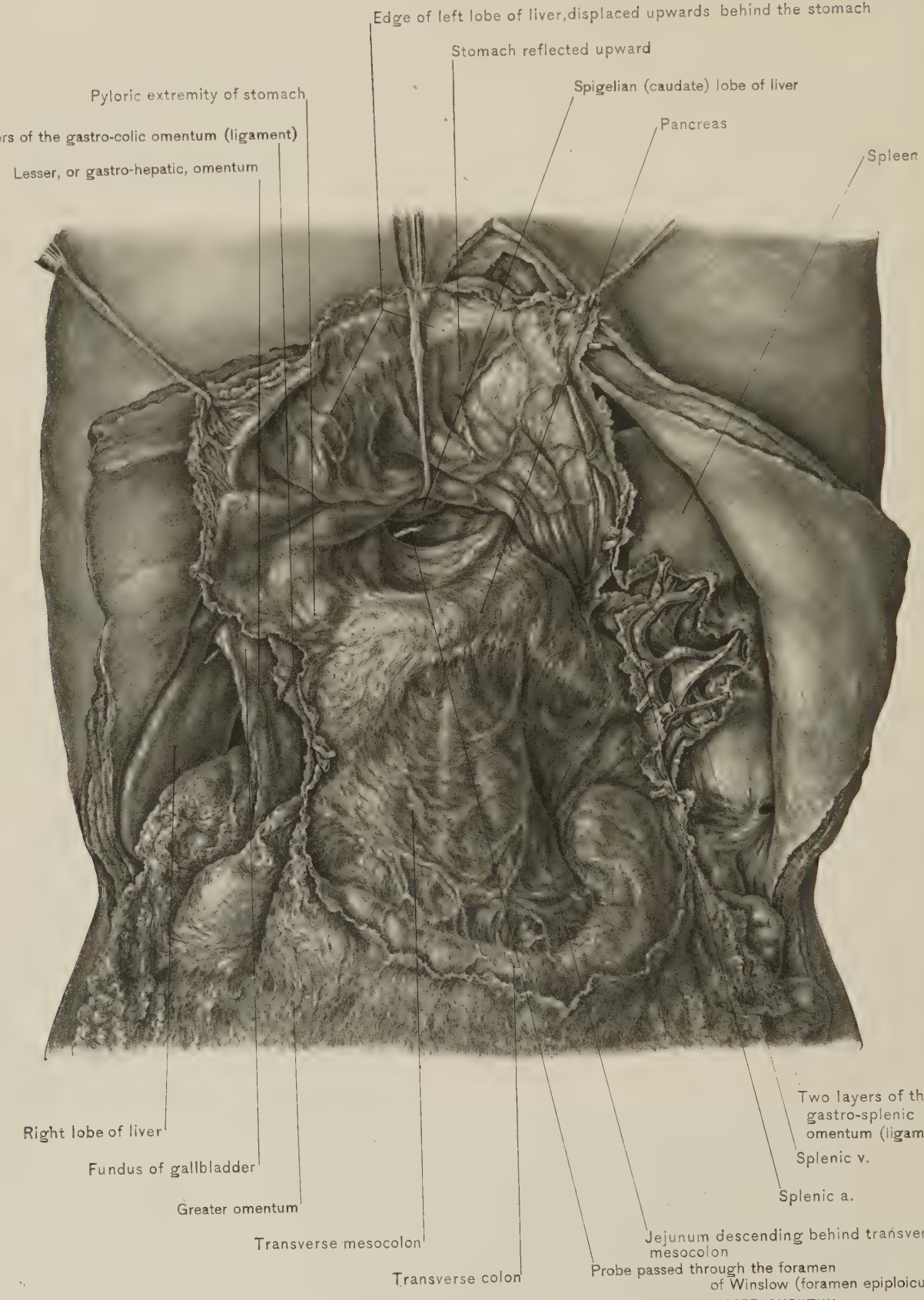
Edge of left lobe of liver, displaced upwards behind the stomach
Stomach reflected upward
Spigelian (caudate) lobe of liver
Pancreas
Spleen
Pyloric extremity of stomach
Layers of the gastro-colic omentum (ligament)
Lesser, or gastro-hepatic, omentum
Right lobe of liver
Fundus of gallbladder
Greater omentum
Transverse mesocolon
Transverse colon
Two layers of the gastro-splenic omentum (ligament)
Splenic v.
Splenic a.
Jejunum descending behind transverse mesocolon
Probe passed through the foramen of Winslow (foramen epiploicum)

STRUCTURES BEHIND THE POSTERIOR PARIETAL LAYER OF PERITONEUM. THE LESSER OMENTUM.

PLATE CCCCXIII.

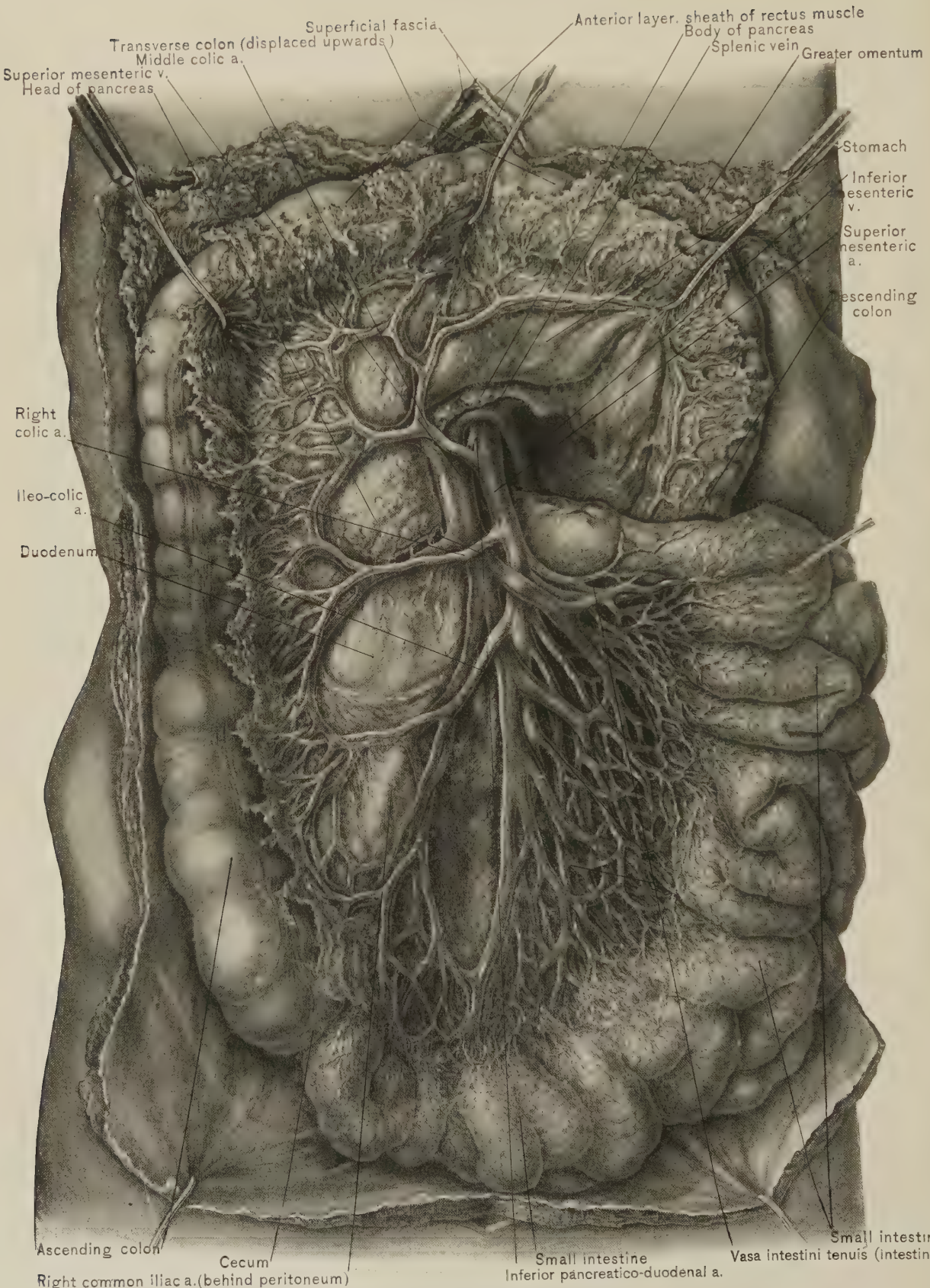

SUPERIOR MESENTERIC VESSELS.

The **left gastro-epiploic artery** arises from the splenic artery or one of its terminal branches, behind the cardiac end of the stomach, descends between the two layers of the gastro-splenic omentum, and finally passes downward toward the right, along the greater curvature of the stomach, between the two anterior layers of the greater omentum, anastomosing with the right gastro-epiploic artery.

The **gastro-epiploic veins** accompany the gastro-epiploic arteries. The *right gastro-epiploic vein* empties into the superior mesenteric vein, near its junction with the splenic vein. The *left gastro-epiploic vein* empties into the commencement of the splenic vein or into one of its branches which emerge from the spleen.

The **structures in the gastro-splenic omentum** (**gastro-splenic ligament**) (Plate CCCCXI) are the vasa brevia, the origin of the left gastro-epiploic artery, the venæ comites of these arteries, lymph vessels, and sympathetic nerves.

The **vasa brevia** are small arteries which arise from the terminal part of the splenic artery or its terminal branches, and pass between the layers of the gastro-splenic omentum, to reach the cardiac end of the stomach. It is through these branches that hematemesis results in splenic disease.

Dissection.—At this stage of the dissection the greater omentum and gastro-splenic omentum (gastro-splenic ligament) should be divided along the greater curvature of the stomach, and the stomach and lesser omentum should be displaced forward and upward, to obtain a better conception of the location and extent of the lesser peritoneal cavity.

The **structures behind the ascending layer of the posterior parietal peritoneum and behind the interval formed by removal of the lesser omentum** (Plate CCCCXII) should next be exposed by removing the ascending portion of the posterior parietal peritoneum; and their relations observed before they are disturbed. These structures are: part of the pancreas, the celiac axis (*celiac artery*), the splenic artery, the origins of the hepatic, gastric, or coronary (*left gastric*) and phrenic arteries, the solar (*celiac*) plexus of nerves, the splenic vein, the terminal parts of the superior and inferior mesenteric veins, and part of the aorta and inferior vena cava. Description of these structures is given on p. 508.

The **structures between the layers of the mesentery** are: the superior mesenteric artery and vein, the vasa intestini tenuis (*intestinal arteries and veins*), lymph glands and vessels, and parasympathetic and sympathetic nerve-fibers (Plate CCCCXIII).

Dissection.—In order to expose the vessels of the mesentery the greater omentum and transverse colon should be displaced upward, and the jejunum and ileum spread out on the left side of the body, so as to allow a full view of the anterior, or right, surface of the mesentery. The superior mesenteric artery and vein, their branches, and the lymph glands may be seen through the anterior,

or right, layer of the mesentery, and the posterior parietal peritoneum, between the root of the mesentery and the ascending colon. The peritoneum should now be removed from the right side of the mesentery, from the posterior abdominal wall as far as the ascending colon, and from the under surface of the transverse mesocolon. This part of the dissection can be performed with the fingers and the handle of the scalpel. The vessels should next be traced out of the extraperitoneal connective tissue which envelops them. In doing this the nerves of the superior mesenteric plexus should be observed.

The **superior mesenteric artery** is seen emerging between the lower border of the pancreas and the upper border of the third, or transverse, portion of the duodenum, and arises from the front of the aorta, a short distance below the celiac axis (*celiac artery*). Its origin lies behind the pancreas and the splenic vein, and will be exposed in the dissection of the duodenum and the pancreas. After passing between the pancreas and the duodenum, it crosses over the transverse portion of the duodenum, runs beneath the descending layer of the peritoneum for a short distance, and traverses the extraperitoneal connective tissue of the mesentery near the root of the latter. In its course through the mesentery, it describes a curve, the convexity of which is directed to the left. It ends in the right iliac fossa, where it forms an anastomosis with its ileo-colic branch.

The superior mesenteric artery supplies the third and fourth portions of the duodenum, the jejunum, ileum, vermiform appendix, cecum, ascending colon, and the major portion of the transverse colon. It is surrounded by the superior mesenteric plexus of sympathetic nerves.

Acute gastro-mesenteric ileus is, in some cases, supposed to be due to an obstruction of the duodenum, as a result of a descent of the mesentery pulling the superior mesenteric vessels across the duodenum.

The **superior mesenteric vein** accompanies the superior mesenteric artery, and its terminal portion, like the commencement of the artery, crosses the transverse portion of the duodenum and passes behind the pancreas. The vein commences in tributaries which correspond to the branches of the artery. It lies to the right of the artery, and at its termination joins the splenic vein, to form the portal vein.

The **branches of the superior mesenteric artery** are: the inferior pancreatico-duodenal, the middle colic, the right colic, the ileo-colic, and the vasa intestini tenuis (*intestinal arteries*).

The **inferior pancreatico-duodenal artery** runs toward the right, along the upper border of the transverse portion of the duodenum, in the groove between that viscus and the pancreas, to anastomose with the superior pancreatico-duodenal artery.

The colic branches.—The ileo-colic and the right and middle colic arteries arise from the concave side of the superior mesenteric artery and supply the cecum, ascending colon, hepatic (*right colic*) flexure and the transverse colon. The ileo-colic occupies a greater portion of the mesentery than the other two colic branches.

The **middle colic artery,** which often arises by a common trunk with the **right colic artery,** passes between the layers of the transverse mesocolon, and divides into a left and a right branch. The left branch anastomoses with the ascending branch of the left colic artery, and the right, with the ascending branch of the right colic artery. It is through the arterial arcade formed by the left branch and the branch from the left colic artery that an opening is made in the transverse mesocolon for a posterior gastro-enterostomy. Considerable care must be exercised so as not to injure the middle colic or its branches. If this accident should occur, gangrene of a portion of the transverse colon may result.

The **right colic artery** passes behind the posterior parietal peritoneum, which forms the inner layer of the ascending mesocolon; near the ascending colon, it divides into a descending and an ascending branch. The descending branch anastomoses with the colic branch of the ileo-colic, and the ascending branch with the right branch of the middle colic artery.

The **ileo-colic artery** descends to the right iliac fossa, behind the peritoneum, to a point opposite the cecum, where it divides into an ileac (descending) and a colic (ascending) branch. The *ileac branch* runs chiefly in the mesentery, and anastomoses with the termination of the superior mesenteric artery. The *colic branch* runs behind the peritoneum, which forms the medial layer of the ascending mesocolon, and anastomoses with the descending branch of the right colic artery. By the anastomosis of the ileac and colic branches with the respective vessels upon each side two arches are formed. These arches in turn give off branches which form a second arch, from which branches are given off to the terminal part of the ileum, the cecum, the vermiform appendix, and the ascending colon. The branches supplying the terminal part of the ileum, the cecum, and the vermiform appendix are derived from the secondary loop formed by the anastomoses of the ileac branch of the ileo-colic artery with the terminal part of the superior mesenteric artery.

The **appendicular artery** (**artery of vermiform process**) is the branch of the ileo-colic artery which supplies the vermiform appendix and reaches that organ by way of the meso-appendix.

The **appendicular veins** (**veins of vermiform process**), as well as the lymph vessels of the appendix, are of special importance in connection with the study of the pathology of appendicitis, demonstrating the course which infection may

take through channels other than the peritoneum. Septic material taken up by the appendicular vein may reach the portal vein and produce inflammation and thrombosis of that vessel with a resulting pylephlebitis and liver abcesses.

The **vasa intestini tenuis** (**intestinal arteries**) are the only branches of the superior mesenteric artery confined entirely to the mesentery. They arise from the convex side of the artery, vary in number from twelve to sixteen, and supply the jejunum, ileum, mesentery, and the mesenteric glands. Each of the vasa intestini tenuis (*intestinal arteries*) divides into two branches, which anastomose with the corresponding adjacent branch of the nearest artery; each of these branches again divides and forms another anastomosis, thus making from three to five tiers of arterial arches. From the last set of arches the branches which supply the bowel are derived. These branches pass transversely around the intestine. The circular arrangement of the vessels in the coats of the small intestine aid in distinguishing the intestine from the sac of a hernia.

Dissection.—Before replacing the greater omentum and the transverse colon, the small intestine and the mesentery should be drawn over to the right side of the abdomen. This will expose the posterior parietal peritoneum, which extends from the root of the mesentery to the descending colon and the mesosigmoid (*pelvic mesocolon*). To the left of the aorta the inferior mesenteric artery may be seen through the peritoneum, which should now be removed, and the vessels be traced through their supporting extraperitoneal connective tissue.

The **inferior mesenteric artery** (Plate CCCCXIV), which is smaller than the superior mesenteric artery, arises from the front of the aorta, from three to five centimeters (one to two inches) above its bifurcation, and about the same distance below the superior mesenteric artery. It passes obliquely downward, describing a slight curve, the convexity of which is directed to the left, and, after crossing the left psoas muscle and the common iliac artery, it passes into the pelvis between the layers of the mesosigmoid (*pelvic mesocolon*), and terminates as the superior hemorrhoidal artery. It supplies the descending colon, the sigmoid flexure (*iliac and pelvic colon*), and the upper part of the rectum. The artery is accompanied by the inferior mesenteric vein, which lies to the left of the artery, and is surrounded by the inferior mesenteric plexus of sympathetic nerves.

The **inferior mesenteric vein** begins at the rectum, in the superior and middle hemorrhoidal veins, and passes out of the pelvis between the layers of the mesosigmoid (*pelvic mesocolon*). It soon leaves the inferior mesenteric artery, and runs upward on the left side of the aorta, over the psoas muscle, and behind the peritoneum, in the extraperitoneal connective tissue. It finally passes under the transverse portion of the duodenum and the pancreas, to empty into the splenic vein. It is therefore considerably longer than the corresponding

PLATE CCCCXIV.

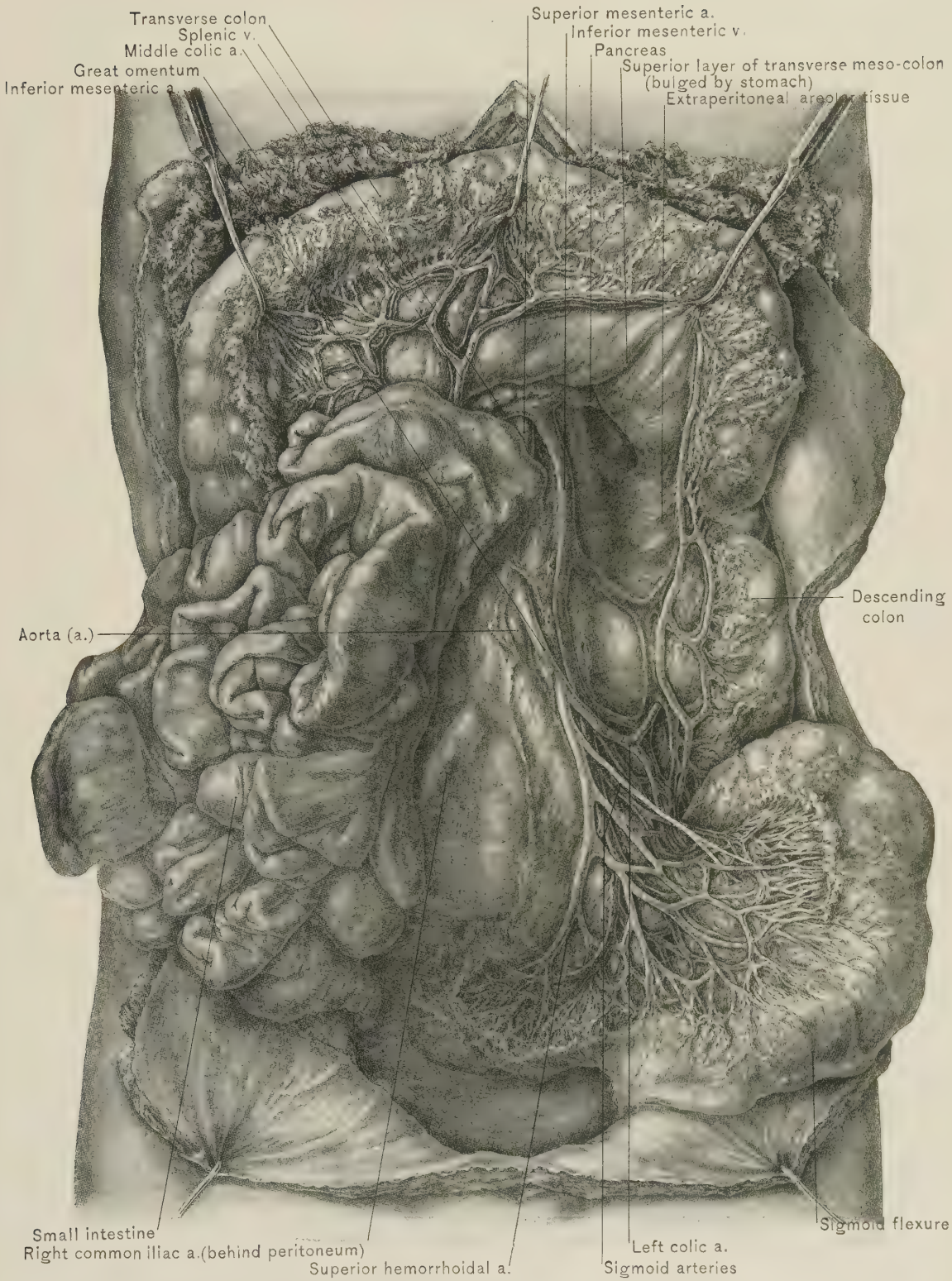

INFERIOR MESENTERIC VESSELS.

artery. The anastomosis of the middle and inferior hemorrhoidal veins is one of the sites of a connection between the portal and systemic circulations.

The **branches of the inferior mesenteric artery** are: the left colic, the sigmoid, and the superior hemorrhoidal arteries.

The **left colic artery** is the first branch of the inferior mesenteric artery, and passes transversely lateralward behind the peritoneum and in front of the lower part of the left kidney to a point near the descending colon, where it divides into an ascending and a descending branch. The *ascending branch* passes upward along the medial side of the descending colon, enters the transverse mesocolon, and anastomoses with the left branch of the middle colic artery. The *descending branch* enters the mesosigmoid (*pelvic mesocolon*), and anastomoses with the ascending branch of the sigmoid artery.

The **sigmoid arteries,** one to three in number, pass obliquely downward and to the left over the psoas magnus muscle, enter the mesosigmoid (*pelvic mesocolon*), and divide into ascending and descending branches which form arterial arches with the adjacent arteries. The upper and lower of these branches anastomose with the descending branch of the left colic and with the superior hemorrhoidal artery respectively.

The **superior hemorrhoidal artery,** the continuation of the inferior mesenteric artery, passes downward into the pelvis between the layers of the mesosigmoid, (*pelvic mesocolon*), and, reaching the terminal part of the sigmoid flexure (*pelvic colon*), divides into two branches which pass to the sides of this part of the bowel and the upper part of the rectum. It anastomoses with the sigmoid and the middle and inferior hemorrhoidal arteries.

Dissection.—Remove the entire portion of the intestine between the duodenum and the sigmoid flexure (*iliac and pelvic colon*), by severing between ligatures the upper end of the jejunum and the lower end of the descending colon and dividing the vessels, mesentery, and mesocolon at their attachment to the intestine. Before proceeding further, the part of the intestine which has been removed should be examined.

The **wall of the small intestine** is made up of four coats: serous, muscular, submucous, and mucous.

The **serous coat** is formed by the visceral portion of the peritoneum, and has been fully described under the dissection of that membrane (at p. 336). It will be remembered that certain parts of the duodenum are devoid of this covering, and that the remainder of the small intestine is entirely surrounded by it, with the exception of the line of attachment of the mesentery, where there is a slight interval between the two layers of peritoneum as they diverge to pass around the gut. After an end-to-end anastomosis union does not occur so quickly at this line as

elsewhere, owing to the absence of peritoneum in this location, so that leakage from the bowel into the peritoneal cavity is most likely to occur at the attachment of the mesentery.

The **muscular coat** is composed of two layers, an external, or longitudinal, and an internal, or circular, layer. Both of these layers are about uniformly disposed around the bowel. The circular layer is somewhat thicker than the longitudinal layer, therefore longitudinal wounds of the gut gape more widely than transverse ones.

The **submucous coat** connects the muscular with the mucous coat. It is composed of loose areolar tissue.

The **mucous coat** of the small intestine is highly vascular and quite thick at the upper part of the bowel, becoming thinner below. It may be divided into three layers. The first, often described with the submucous layer, consists of unstriped muscle fibers, known as the *muscularis mucosæ*. It lies between the submucous coat and the second layer of the mucous coat. The second layer consists of retiform connective tissue, in which the nerves and vessels ramify, and in which are found numerous lymph corpuscles. The third layer is made up of a coat of basement membrane which supports a layer of columnar epithelial cells. For a thorough study of the mucous membrane, the gut should be incised longitudinally along the attachment of the mesentery. The mucous membrane will then be seen to form transverse ridges or folds, varying in size and known as the **valvulæ conniventes** (**plicæ circulares**) (Plate CCCCXV). They differ from folds of mucous membrane found in the stomach in being transverse instead of longitudinal, and in being permanent, while those of the stomach disappear when the organ is distended. They are absent in the first part of the duodenum, most numerous in the upper half of the jejunum, and gradually disappear in the ileum. Scattered over the entire surface of the small intestine are minute projections of the mucous membrane, or *villi*, which give the surface a velvety appearance. They are most numerous in the duodenum and jejunum, becoming fewer and smaller in the ileum. These villi are composed of one or two lacteals, a plexus of blood-vessels, nerve-fibers, unstriped muscle fibers, and connective tissue, all surrounded by basement membrane and epithelial cells. For a minute description of them the student is referred to works upon histology.

The **glands** found in the small intestine are: Brunner's (*duodenal*) glands, the glands, or crypts, of Lieberkühn (*intestinal glands*), the solitary glands, and Peyer's patches (*aggregated lymph nodules*).

Brunner's glands (**duodenal glands**) are small compound racemose glands found in the duodenum. Beginning at the pylorus, where they are most numerous, they gradually decrease in number, being sparse beyond the bile ducts

PLATE CCCCXV.

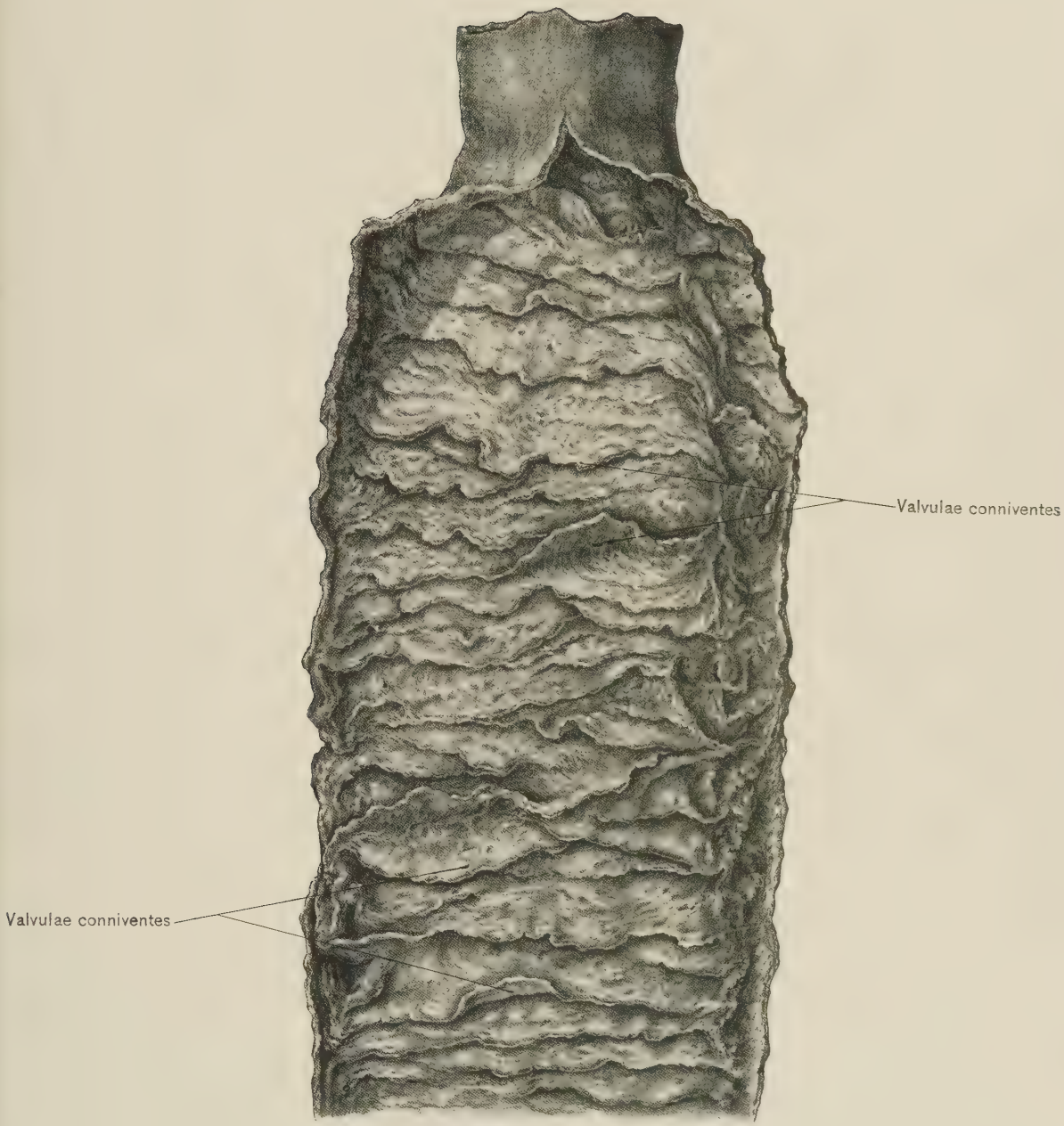

INTERNAL SURFACE OF SMALL INTESTINE SHOWING VALVULÆ CONNIVENTES.

PLATE CCCCXVI

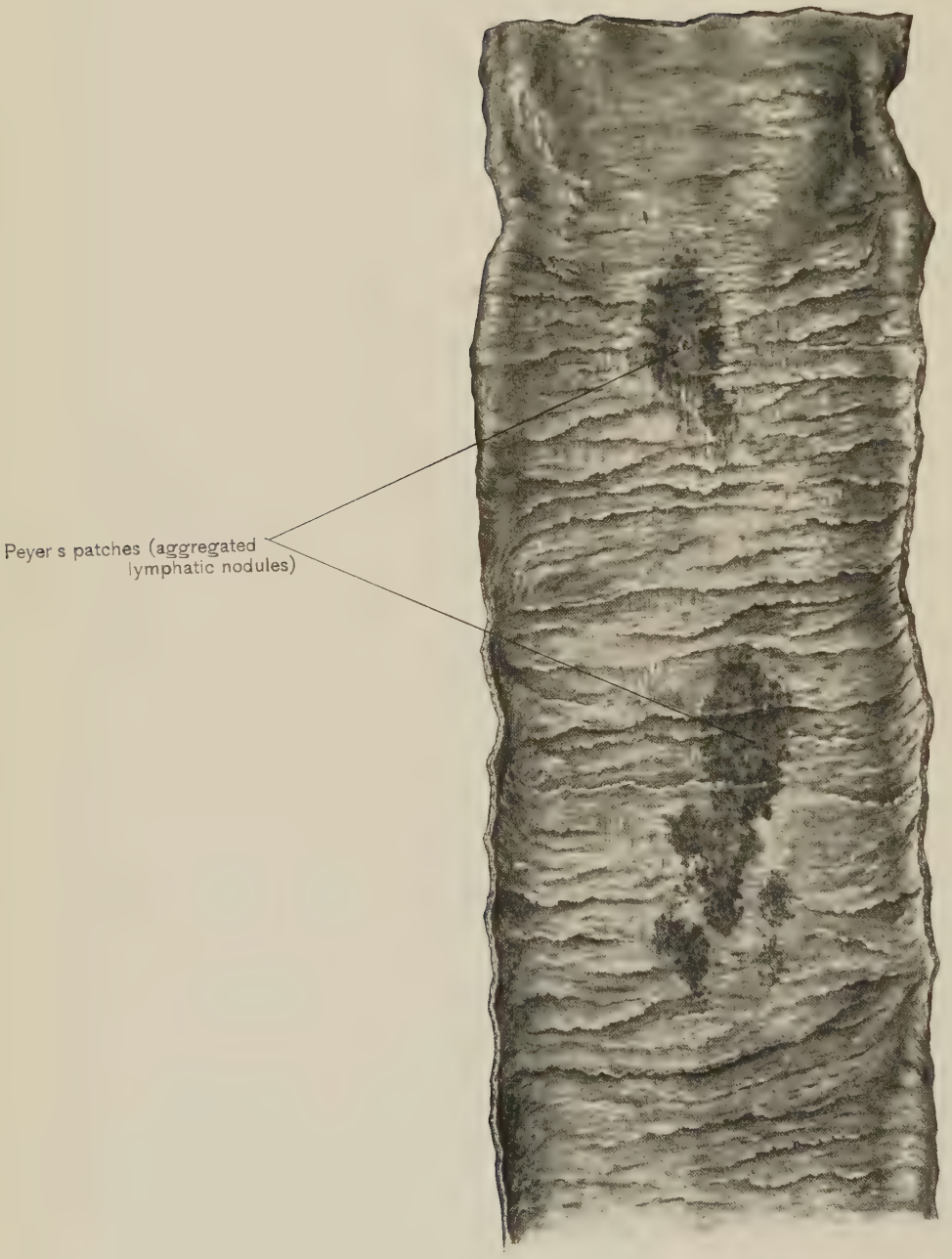

INTERNAL SURFACE OF ILEUM SHOWING PEYER'S PATCHES (AGGREGATED LYMPHATIC NODULES).

and disappearing completely near the duodeno-jejunal junction. They are embedded in the submucous layer. Their ducts open on the mucous membrane and discharge a serous secretion. Abscess of these glands may produce a perforating ulcer of the duodenum.

The **crypts of Lieberkühn** (**intestinal glands**) are simple follicular, or tubular, glands scattered throughout the mucous membrane of the small and the large intestine. They secrete mucus.

The **solitary glands** consist of small, whitish nodules of lymph tissue, scattered through the mucous membrane of both the small and the large intestine, being particularly numerous in the small bowel, the vermiform appendix and the cecum.

Peyer's patches (**aggregated lymph nodules**) (Plate CCCCXVI) are collections of lymphoid tissue measuring from one to seven centimeters (one-half to three inches) in length, and from one to two and a half centimeters (one-half to one inch) in width. They are situated in the part of the wall of the bowel furthest from the attachment of the mesentery in the mucous membrane, with their long diameter directed longitudinally. They are largest and most numerous in the lower part of the ileum, and are seldom found as high as the jejunum. Neither Peyer's patches (*aggregated lymph nodules*) nor the solitary glands are secretory in function as they are composed entirely of lymph tissue. Being best developed in young persons, they atrophy as age advances, so that their location in old persons is merely marked by a discolored patch. These glands show the most conspicuous lesion in typhoid fever, in which they undergo congestion, necrosis, ulceration, and repair, by formation of scar tissue. The ulcer formed may perforate the bowel and allow escape of feces, thus producing peritonitis. Separation of the necrotic tissues may give rise to serious hemorrhage.

Blood Supply.—The blood supply of the small intestine is derived from the superior mesenteric artery and from the superior pancreatico-duodenal, a branch of the hepatic artery. As seen in the dissection of the mesentery, the superior mesenteric artery runs between the layers of that structure and gives off the vasa intestini tenuis (*intestinal arteries*), which dividing and subdividing form numerous arches, which finally furnish branches that encircle the gut. One branch, the inferior pancreatico-duodenal, anastomoses with the superior pancreatico-duodenal artery, and forms a plexus in the concavity of the curve of the duodenum. This part of the intestine is supplied with blood by this arterial loop. The veins of the small intestine begin in small branches which empty into the superior mesenteric vein.

Nerve Supply.—The nerve supply of the small intestine is derived from the superior mesenteric plexus, the latter being continuous with the lower portion of

the solar (*celiac*) plexus. The branches of this plexus follow the branches of the superior mesenteric artery. These sympathetic nerves from two plexuses in the wall of the bowel. One of these is situated between the circular and longitudinal muscle layers, and is known as Auerbach's (*myenteric*) plexus; the other is the submucous coat, and is known as Meissner's (*submucous*) plexus. These plexuses contain ganglia, and control the muscular tissues of the bowel. In acute peritonitis, typhoid fever, and in certain other conditions, these plexuses become more or less paralyzed. This allows muscular relaxation and gaseous distention of the intestines (tympanites).

There are many differences between the jejunum and the ileum, although the dividing-line between these two portions of the bowel is not distinct or well defined. Thus:

1. The lumen of the jejunum is six millimeters (one-quarter inch) wider.
2. The wall of the jejunum is thicker.
3. The vascularity of the jejunum is greater, therefore it is redder.
4. The villi of the jejunum are more numerous.
5. Peyer's patches (*aggregated lymph nodules*) are present in the ileum, having their greatest development at its lower end, from which they gradually grow smaller and less frequent as the jejunum is reached, in which portion of the bowel they are rounded and infrequent.
6. At postmortem the jejunum is generally found empty, hence the name "empty gut"; the ileum frequently contains feces.
7. Occasionally, the remains of the vitello-intestinal duct, or Meckel's diverticulum (*diverticulum ilei*), are found near the lower end of the ileum.
8. The jejunum lies in the umbilical and left iliac regions and in the pelvis, while the ileum is more generally found in the right iliac and the hypogastric regions and in the pelvis.
9. The jejunum forms about two-fifths, and the ileum about three-fifths of the length of the small gut.
10. The jejunum contains larger and more numerous valvulæ conniventes (*plica circulares*).
11. The fat in the mesentery is not so abundant near the intestine in its upper part as it is lower down and the vessels close to the bowel are more readily seen.

Other things being equal, injuries or herniæ of the jejunum are more serious than of the ileum. Also all high obstructions are more serious than the lower ones. The higher the obstruction, the earlier the onset of toxemia. This difference in physiological importance explains the greater fatality of umbilical herniæ, which usually involve the jejunum, as compared with inguinal and femoral herniæ, in which the ileum is usually involved.

The **intestinal lymphatics** and their associated glands lie between the two layers of the mesentery, hence the designation, mesenteric glands. They vary in size from that of a pea to that of a small almond, and in number from one hundred to one hundred and fifty, and occupy the interspaces between the inosculations of the branches of the superior mesenteric artery. They are largest and most abundant at both ends of the small intestine, near the duodenum and near the ileo-colic junction, while in the colon they are fewer, the transverse portion having the smallest number.

The **lymph vessels of the small intestine** begin in closed extremities in the villi of the intestinal mucous membrane, where they absorb the products of digestion and carry them, emulsified and milk-like, to the mesenteric glands. Although usually as imperceptible as lymphatics elsewhere, they are readily distinguished after a meal as milk-white threads in the mesentery; for this reason they are named the *lacteals*. These vessels, after passing through several successive series of mesenteric glands, each time becoming less numerous but larger, enter the *receptaculum chyli*, which is situated in front of the body of the second lumbar vertebra.

Injuries of the small intestine.—Of all the viscera, the small intestine is most exposed to injury. At the same time it must be borne in mind that, owing to its mobility and the ease with which its coils glide over one another, it is enabled to escape the effects of pressure, and thus is better adapted to meet such injuries as contusions of the abdominal wall.

Gross found that a longitudinal incision in the small intestine about five millimeters in length was immediately reduced to a wound about three millimeters in length by muscular contraction, and that in addition to this contraction the eversion of the mucous membrane entirely sealed the opening. A longitudinal wound of the small intestine will gape more than a transverse wound, owing to the circular fibers possessing more power than the longitudinal fibers. The muscular coat of the jejunum is better developed than that of the ileum; therefore, wounds of the former gape more than of the latter. The longitudinal muscle fibers being thicker along the free border of the gut than at the attachment of the mesentery, transverse wounds gape most when inflicted at the free border. The bowel seems to withdraw from the point of a needle introduced through the abdominal wall, so that peritonitis after the injection of saline, blood, or air is most unusual.

The **wall of the large intestine,** like that of the small intestine, is composed of four coats: serous, muscular, submucous, and mucous.

The **serous coat** is derived from the peritoneum, and has been fully described with the peritoneum (at p. 336). It differs from the serous coat of the small intes-

tine in forming small projections, or pouches, filled with fat, the *appendices epiploicæ*.

The **muscular coat** is composed of two layers, a longitudinal and a circular, the former being external. The longitudinal layers are arranged in three bands, and are so marked as to be plainly visible through the serous coat. Only a few longitudinal fibers are found between the bands, except in the appendix and the rectum, where they are uniformly distributed around the bowel. These longitudinal bands are shorter than the other structures of the large intestine, and, therefore, pucker it into saccules. The circular layers form a very thin layer over the cecum and the colon, where they are most abundant between the sacculi. In the lower part of the rectum they are most numerous and form a thick layer which constitutes the **internal anal sphincter.**

The **submucous coat** consists of areolar tissue connecting the muscular and mucous coats.

The **mucous membrane** is smooth and destitute of villi and valvulæ conniventes (*plicæ circulares*), but it contains the orifices of numerous large intestinal glands. As in the small intestine, it may be divided into three layers. The external layer consists of muscle fibers, the muscularis mucosæ; the second layer is made up of retiform connective tissue in which the vessels ramify; the third layer is composed of a basement membrane and columnar epithelium.

The **glands of the large intestine** are the crypts of Lieberkühn (*intestinal glands*) and the solitary glands.

The *crypts of Lieberkühn* (*intestinal glands*) are similar in structure to those in the small bowel, except that they are larger and more numerous.

The *solitary glands*, or lymph follicles, are also like those of the small intestine, but are not so numerous. They are most abundant in the vermiform appendix and the cecum.

The **structure of the appendix** although resembling that of the large intestine, has some distinguishing features. The **mucous membrane lining the appendix** is composed of a delicate retiform connective tissue containing numerous lymphoid cells within its meshes, and has a plentiful supply of solitary glands and glands of Lieberkühn (*intestinal glands*), the latter varying much in size and number, often being entirely wanting. The retiform connective tissue is lined with a basement membrane on which are found columnar epithelial cells covered with clusters of various micro-organisms. Between the mucous and submucous coats a thin layer of circular muscle fibers may be distinguished, forming the muscularis mucosæ.

The **submucosa** is formed of areolar tissue, is much denser than the mucous coat, and contains numerous large lymph nodules which, fusing to form masses,

may almost reach the free surface of the mucosa. Numerous small arteries and veins supplying the mucous membrane are present in the submucosa, which generally contains also a small quantity of fat.

From within the cecum may be seen a prominence of the mucous membrane partially or completely surrounding the orifice of the appendix, due to an increase of the lymphoid tissue. This, in certain circumstances, may act as a valve, and thus favor occlusion of the orifice. Hypertrophy of the lymphoid tissue in the wall of the appendix frequently occurs in typhoid fever, and may lead to obstruction of the lumen of the organ and stagnation of its fecal contents.

The **muscular coat** consists of two layers. The inner one is a thick layer of circular fibers (about one millimeter) at times constituting fully one-third the entire thickness of the appendiceal wall. The outer layer is composed of longitudinal fibers. It is only about one-half as thick as the inner layer, and the muscle fibers are more irregular, sometimes being bunched at certain points as in the outer layer of the muscular coat of the cecum.

Probably one of the strongest evidences of the existence of the longitudinal muscle fibers is demonstrated after the removal of the vermiform appendix, when by the contraction of the fibers, the organ rapidly shrinks, sometimes to one-third of its original length. The circular fibers possess the same power, for when the appendix has been incised to expose its canal, there immediately follows a contraction of the circular fibers, thus bringing the mucous lining into view.

The **peritoneal coat,** or serous covering, of the appendix is similar to the peritoneum in general. Its extent in regard to the appendix has been described (at p. 364).

The vascular supply of the viscera in the right iliac fossa is derived from loops formed by the anastomoses of the right colic and the ileo-colic arteries, branches of the superior mesenteric artery. From these loops secondary loops are given off, from which are derived the arteries that supply the appendix and the ileo-cecal region. The branch to the appendix, the appendicular artery, passes along the free edge of the meso-appendix, when that structure is present. In the absence of the meso-appendix, the artery usually passes beneath the peritoneal coat of the appendix. In exceptional cases the artery may pass directly to the tip of the appendix, in which case its branches are not given off until it has entered the submucosa. In the female, there is sometimes an additional supply of blood brought to the appendix through the folds of the appendiculo-ovarian ligament.

The **lymphatics of the appendix** are grouped into an anterior and a posterior set. The anterior ones are in the fold between the colon and cecum. The posterior empty into small nodes beneath the peritoneum on the back of the

cecum. The lymphatics may empty into those of the ovary by passing along the appendiculo-ovarian ligament, in this way forming a lymphatic communication between the appendix and the right ovary; they may communicate with nodes in the mesentery, and with retroperitoneal nodes on the lateral aspect of the ascending colon.

The **nerves of the appendix** are derived from the superior mesenteric plexus of the sympathetic, the branches of this plexus which accompany the ileo-colic artery sending filaments to the appendix. These sympathetic fibers make a central connection with the somatic sensory nerves supplying the abdominal wall in the region of the umbilicus. This accounts for the initial reference of pain in acute appendicitis.

Blood Supply.—The blood supply of the large intestine is derived from branches of the superior and inferior mesenteric, internal iliac (*hypogastric*), and internal pudendal arteries. The branches which supply the rectum are the superior hemorrhoidal branch of the inferior mesenteric artery, the middle hemorrhoidal branch of the internal iliac artery, and the inferior hemorrhoidal branch of the internal pudendal artery. The vessels assume a longitudinal direction toward the lower end of the rectum, and communicate very freely near the anus.

Nerve Supply.—The nerves and lymphatics of the large intestine are similar in manner of distribution to those of the small intestine.

The **ileo-cecal,** or **ileo-colic, valve** (Plates CCCCXVII; CCCCXVIII; CCCCXIX) guards the orifice of communication between the ileum and colon and prevents regurgitation from the colon to the ileum. It consists of two transverse folds of mucous membrane, underlying which are submucous tissue and unstriated circular muscle fibers. The upper of the two folds is the smaller and is more horizontal in position; the lower fold, the larger, is more vertical. To expose the valve an oval piece upon each side of it should be removed from both the ileum and the cecum.

Intussusception.—The ileo-cecal region is probably the most frequent seat of that form of acute, mechanical, internal intestinal obstruction known as intussusception, or invagination. There are two kinds of such invagination: the ileo-cecal and the ileo-colic. In the ileo-cecal, the more common form, the ileum, the cecum, and the ileo-cecal valve are prolapsed into the colon, the ileo-cecal valve forming the summit of the protrusion. In the ileo-colic variety the ileum alone is prolapsed into the large intestine through the ileo-cecal valve.

Surgical Anatomy of the Appendix.—The position, structure, and peritoneal relations of the appendix have been discussed at p. 364. Its mesentery is a fold made by the passage of the appendicular artery. It has a free border which is shorter than the border applied to the appendix and often does not extend to the

PLATE CCCCXVII.

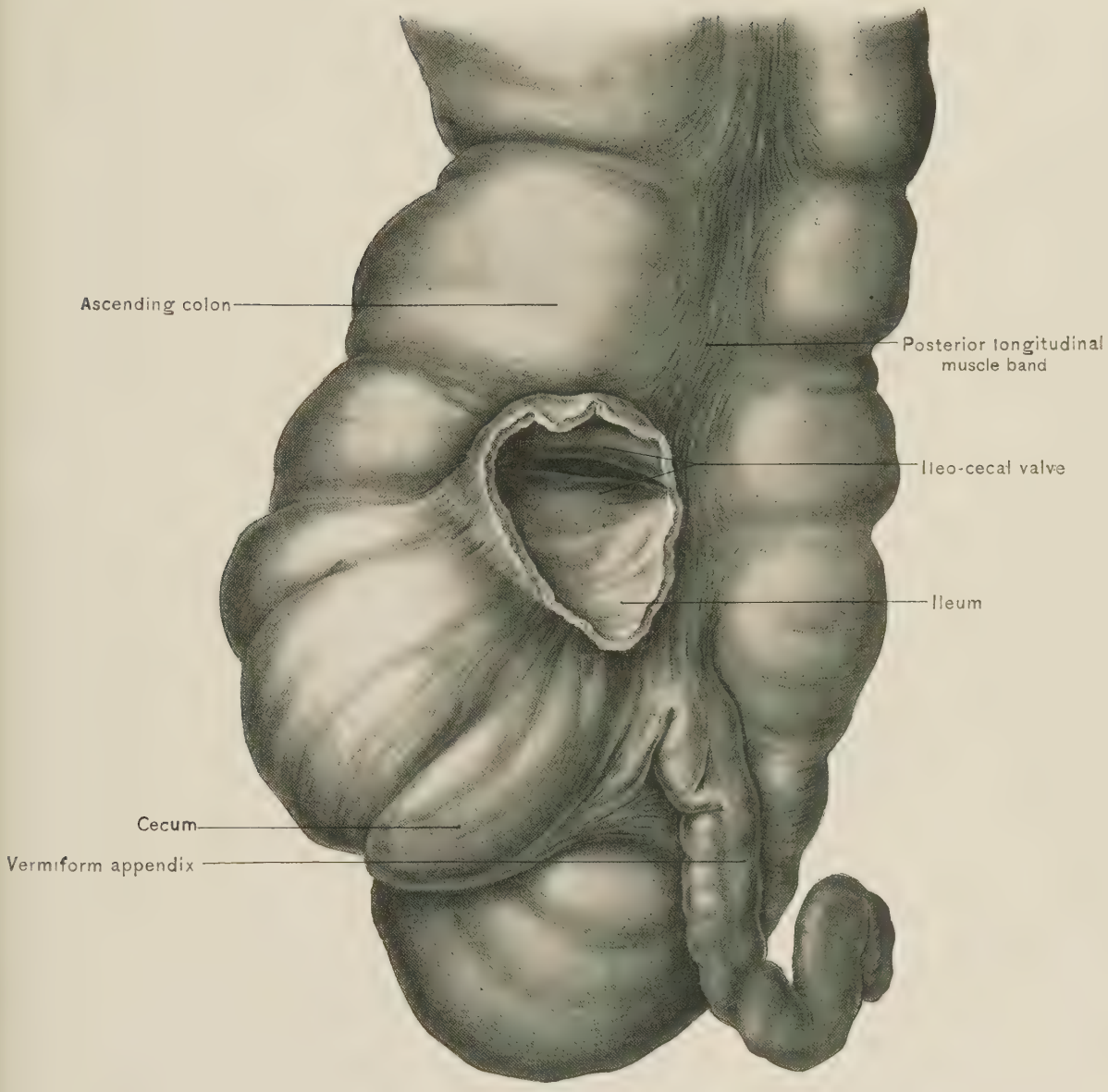

ILEO-CECAL VALVE—EXTERNAL VIEW.

PLATE CCCCXVIII.

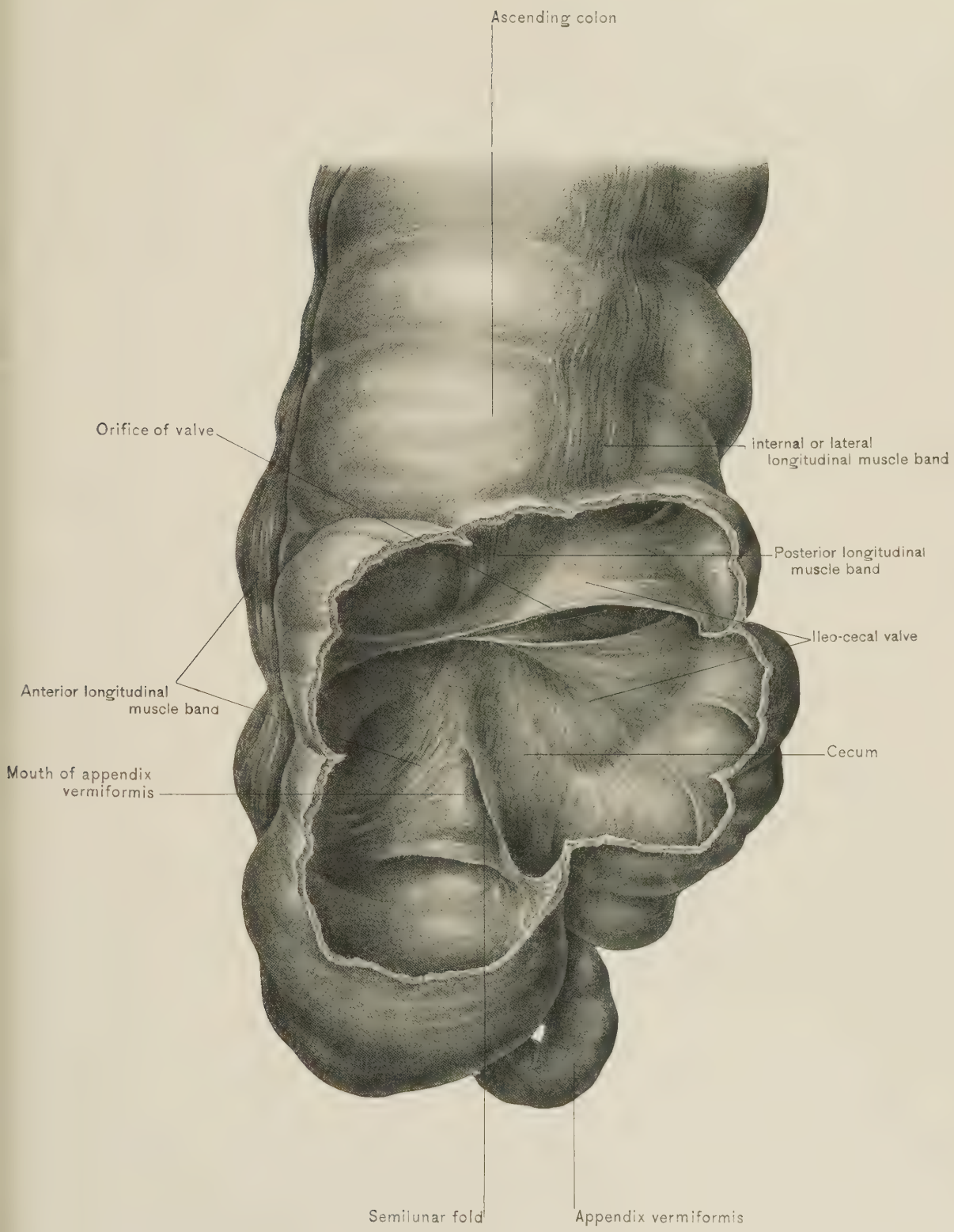

ILEO-CECAL VALVE—INTERNAL VIEW.

PLATE CCCCXIX.

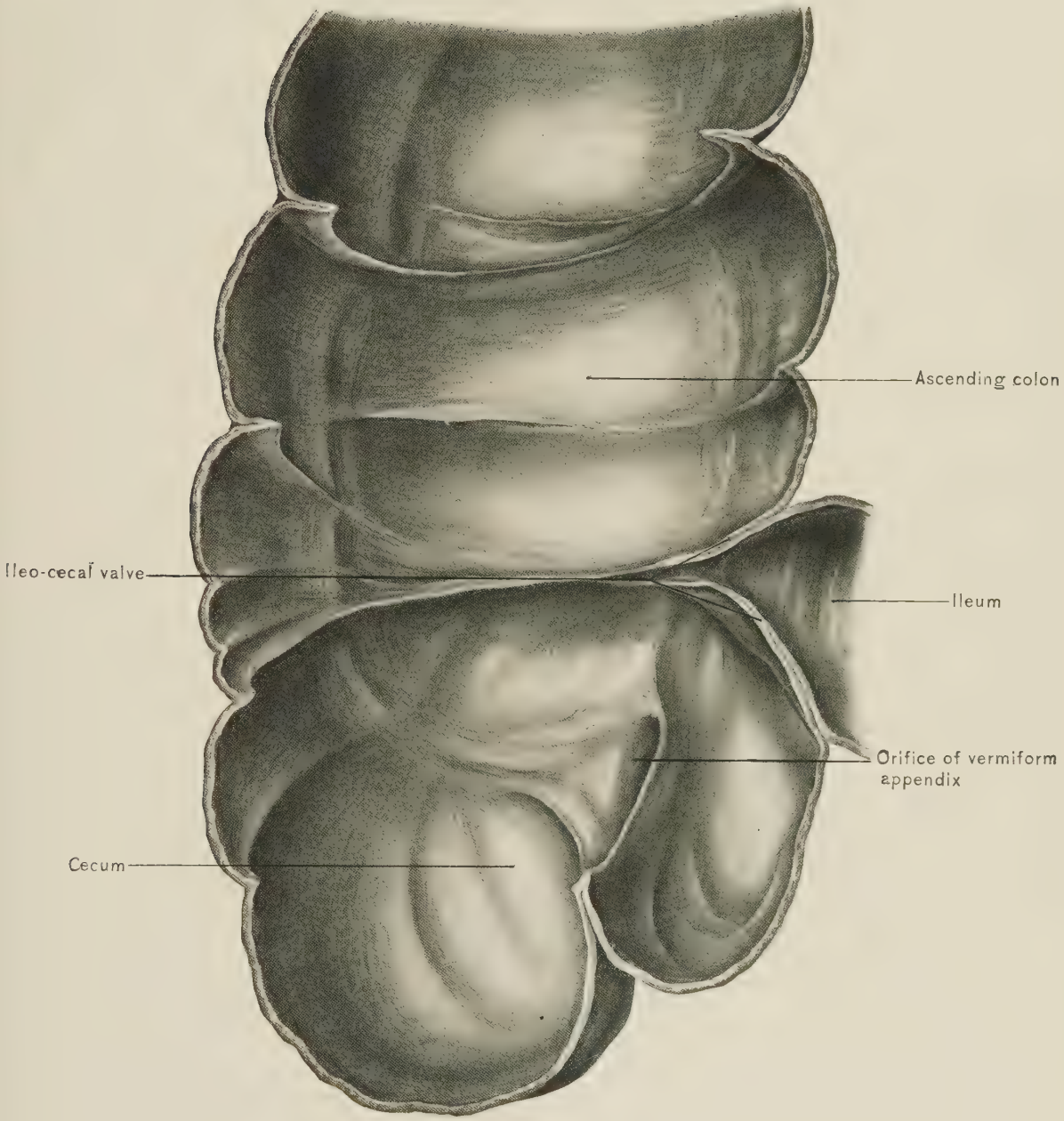

SECTION THROUGH ILEO-CECAL VALVE.

tip of the organ. Because of the formation of the meso, the appendix is frequently coiled. This therefore is normal and need not be taken as gross evidence of previous disease. The ileo-cecal fold runs from that part of the ileum most remote from its mesenteric attachment and is united with the mesentery of the appendix. It carries no blood vessels, and is regarded by Treves as the true meso-appendix. The larger the size of the cecum, the smaller the mesentery of the appendix. An appendix with an ample mesentery is less apt to have its blood supply interfered with and is less often the seat of disease. The abundance of lymphoid tissue in the appendix favors rapid swelling which results in appendicular obstruction. Thus there are a number of anatomic facts which are predisposing causes of appendicular inflammation: the rudimentary character of the organ; the shortness of its mesentery; its imperfect drainage, the dependence for blood supply on a single terminal vessel, and the excessive lymphoid tissue.

Surgical removal of the appendix is performed either during an attack of appendicitis or in the interval between attacks. If done within a short time after the onset of the attack, or in the interval between exacerbations of the disease, the operation is comparatively safe and simple, but after the occurrence of gangrene of the organ or abscess formation, the mortality following the operation is high.

Incision and Operation.—One of several abdominal *incisions* may be used each of which has certain advantages. In the interval cases or in those patients suffering from chronic appendicitis, an incision through the right rectus or the right semilunar line allows for careful exploration of the abdomen. After dividing the skin and superficial fascia the anterior sheath of the rectus muscle is exposed. This consists of two layers, the aponeurosis of the external oblique muscle and the anterior layer of the aponeurosis of the internal oblique. Dividing these will expose the fibers of the rectus muscle. They should be separated with the handle of the scalpel and the posterior sheath of the rectus, the transversalis fascia, and the preperitoneal fat exposed. If the deep (*inferior*) epigastric vessels come into view they may be either pushed aside or seized between two pairs of hemostats and tied. Nerves should be displaced either upward or downward. Each layer of the abdominal wall should be divided to the same extent. As the structures beneath the rectus muscles are exposed, they should be caught in hemostatic forceps and cautiously cut, not with the point of the scalpel but with the belly of the instrument. Traction is then made upon the two pairs of hemostats so as to raise the tissue away from the underlying omentum and intestine and the peritoneum opened, care being taken to cut only during the process of expiration, since during inspiration the intestines are forced against the parietal peritoneum. When the peritoneal cavity has been

opened the peritoneal wound can be enlarged with blunt-pointed scissors, the index finger of either hand being used as a guide. I prefer to make the incision, especially in the acute case, over the lateral part of the rectus muscle and carry it through that muscle, so that the resulting scar will be thicker and stronger, thus reducing the probability of a ventral hernia through the cicatrix.

In acute appendicitis, with or without abscess formation, I prefer the McBurney incision. In this incision, the abdominal cavity is opened by a series of incisions. The first incision is semilunar in shape, and is made midway between the anterior superior spine of the ilium and the right semilunar line, and carried downward and slightly medialward. It passes through skin, superficial fascia, and deep fascia. The fibers of the aponeurosis of the external oblique muscle are separated but not cut. The second incision passes through the superficial layer of interabdominal fascia; the fibers of the internal oblique muscle are separated, the deep interabdominal fascia is divided, and the fibers of the transversalis muscle are separated. The third incision is parallel with the first, and divides the transversalis fascia, preperitoneal fat, and peritoneum. In closing the wound, each incision is closed separately. This operation is feasible when a small opening is sufficient. It can be demonstrated on the cadaver that the cecum is never directly exposed after a right rectus incision. Such an incision exposes the ileum. Anatomically, the muscle-splitting incision of McBurney is ideal for the direct exposure of the cecum. In cases of suppurative appendicitis the right rectus incision necessitates drawing a suppurative focus across a portion of the bowel which may as yet not have become infected. After a large experience with both incisions in acute cases, I must state that I believe the right rectus incision an impediment to the patient's recovery. Hernia after drainage through a right rectus incision is more frequent than when drainage is instituted through a muscle-splitting incision.

The cecum is recognized by one or more of its longitudinal muscle bands, all of which lead to the base of the appendix when traced to the tip of the cecum. It is my practice to deliver the cecum, when this can be done, and thus save time in searching for the appendix. As soon as the root of the appendix is located, the organ is traced to its tip and is then brought into the wound. The greater part of the cecum is now returned to the abdomen, and a gauze is introduced to retain it.

Whether or not the appendix can be delivered or brought up into the wound, will depend upon the number of adhesions, the width of the meso-appendix, etc. It is not possible in all cases to deliver the entire cecum or part of it immediately upon opening the abdomen. This may be due to a short mesocecum or to the absence of a peritoneal covering on the posterior surface of the cecum, or adhe-

sions may tie it down, or the greater omentum may cover it and be adherent to its lateral wall or to the lateral and anterior walls of the abdomen. The mesoappendix is then ligated, and the appendix removed by one of the now well-recognized surgical procedures.

In acute appendicitis with abscess, the site of the incision should be governed by the position of the swelling. If the latter is more pronounced upon the lateral than upon the medial side of the semilunar line, and comparatively low down, I take it that the appendix holds one of the right or lateralward positions, and will, therefore, be more accessible through an incision carried obliquely through the anterior part of the flank, parallel with, and above the lateral third of Poupart's (*inguinal*) ligament. This incision gives an extraperitoneal approach.

When the appendix is removed for chronic, or recurrent, appendicitis the organ is frequently found to be encapsulated by a mass of inflammatory exudate. In these circumstances the appendix can usually be found by burrowing through the exudate at the point where it is most abundant. The method of searching for the appendix in such circumstances is similar to that used in searching for the urethra when attempting a perineal section for traumatic stricture, in which, as often happens, the perineum is virtually a mass of inflammatory exudate. In these circumstances I have always been able to find the urethra by dissecting through the exudate where it is most abundant, and where organization was furthest advanced. From what has been said about the different positions of the appendix, it can readily be seen, how the surgeon who is not thoroughly familiar with the topographic anatomy of the organ may be easily and greatly embarrassed, if not entirely foiled, in his attempt at its removal.

When done for chronic or recurrent appendicitis, appendicectomy is simple and safe and the operation is ordinarily not difficult. The most favorable time for operation in recurrent appendicitis is in the interval between attacks.

Colostomy, the establishment of an artificial anus by opening the colon, is most commonly performed upon the proximal portion of the sigmoid flexure (*iliac colon*), because the conditions requiring the operation are most frequently the result of obstruction in either the sigmoid flexure (*iliac and pelvic colon*) or the rectum, and because the sigmoid (*iliac and pelvic colon*) is freely movable and situated nearest the anus.

When the sigmoid flexure (*iliac colon*) is selected as the portion of the colon to be opened, the operation is called iliac, and not inguinal, colostomy. The sigmoid flexure (*iliac colon*) is reached through the anterior abdominal wall, and is exposed through an oblique incision six to seven centimeters (two and a half to three inches) in length which is similar to the McBurney, or muscle-splitting, incision for appendicectomy. A colostomy through this incision has one great

disadvantage in that the colostomy bag may not fit properly due to its impinging on the bony prominences of the pelvis. For this reason I prefer to bring the bowel through the left rectus muscle. Furthermore this incision permits of abdominal exploration at the same time. The center of the incision should correspond to its point of intersection with a line drawn from the anterior superior spine of the ilium to the umbilicus, and should be carried through the abdominal wall four centimeters (one and a half inches) to the medial side of the anterior superior spine of the ilium. Where exploration is not desired, the muscle-splitting incision on the left side gives sufficient exposure for bringing the sigmoid into the wound. There is no doubt but that in the anterior colostomy the patient can take much better care of himself and is much more comfortable than in the posterior colostomy. In the radical operation for carcinoma of the recto-sigmoid or of the upper rectum, the colostomy should be done as high in the sigmoid as possible so that sufficient room is left for the radical removal of the lesion. There is no doubt in my mind but that the two-stage operation, that is, colostomy as a preliminary to the more radical operation, reduces mortality and is in the best interest of the patient. The surgeon must be careful, however, in bringing the sigmoid up into the wound, to be sure that he is not pulling too much on the meso-sigmoid. If this is torn considerable hemorrhage may result. If it is necessary to mobilize the meso-sigmoid, I do this from the lateral side.

Should the descending colon be selected, the operation is performed by carrying an oblique incision through the loin (costo-iliac space), observing the oblique crease above the crest of the ilium; this is constant in all individuals, and is well marked in corpulent persons. The line of the descending colon is drawn directly upward from a point twelve millimeters (half an inch) behind the center of the iliac crest. The following structures are divided: the skin, the superficial and deep fasciæ, the posterior fibers of the external oblique muscle, the anterior fibers of the latissimus dorsi muscle, the posterior fibers of the internal oblique and transversalis muscles, and the lumbar and transversalis fasciæ.

Right lumbar colostomy is performed only when the obstruction is too high to be relieved by either a left lumbar or a left iliac colostomy. It is not a satisfactory operation and I believe cecostomy to be the preferable procedure. The cecum is exposed by the muscle splitting ihcision of McBurney.

In the adult, the mesosigmoid (*pelvic mesocolon*), the reflection of peritoneum attaching the sigmoid flexure (*iliac and pelvic colon*) to the posterior wall of the abdominal and pelvic cavities, is longer than either of the mesocolons, and thus allows the sigmoid flexure (*iliac and pelvic colon*) to be drawn some distance from its normal site. In very young children, the sigmoid flexure (*iliac and pelvic colon*) and the mesosigmoid (*pelvic mesocolon*) are relatively much longer than in

PLATE CCCCXX.

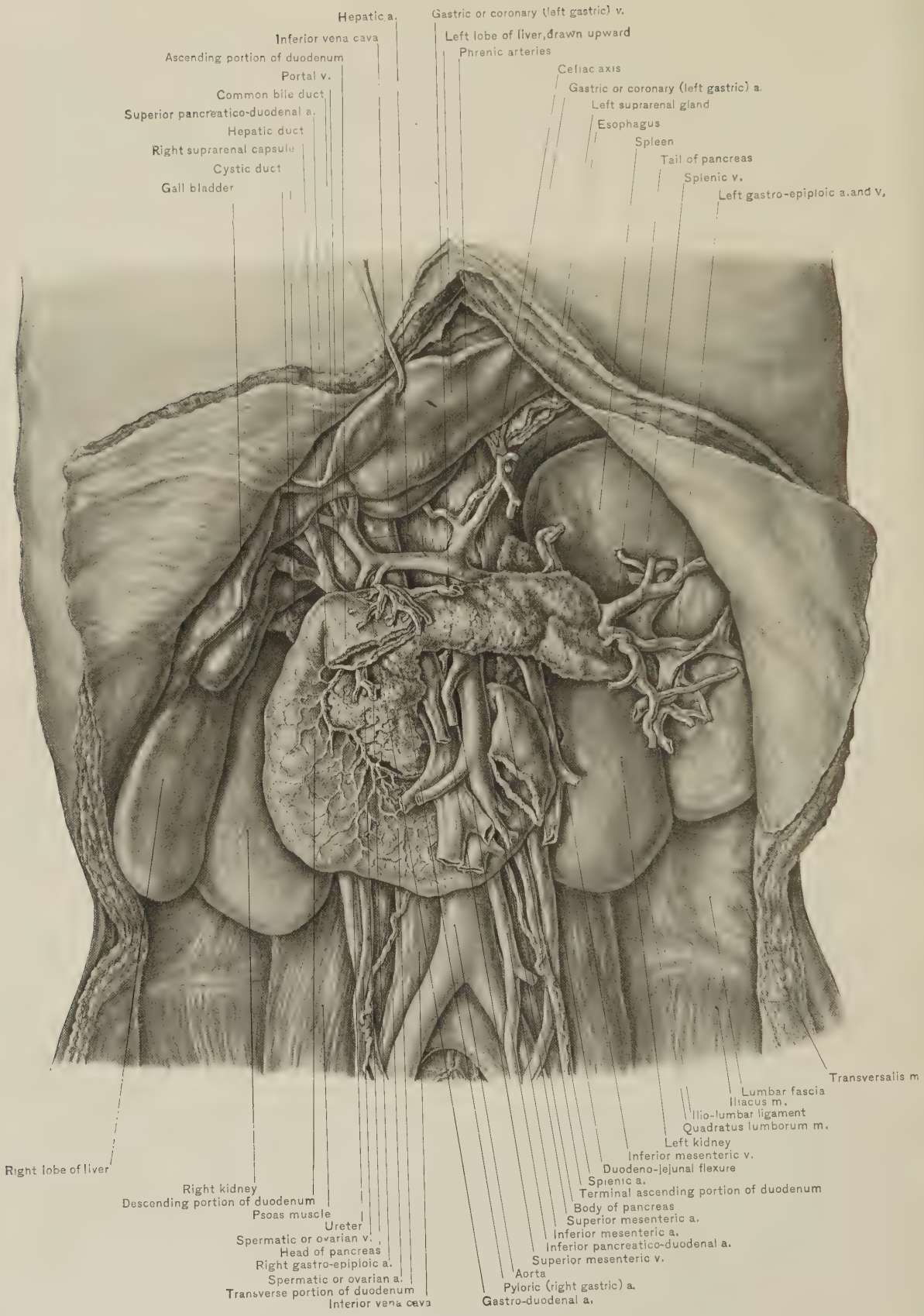

DUODENUM AND PANCREAS.

the adult, and in a small percentage of cases the former will occupy the right iliac fossa; for this reason a right, rather than a left iliac colostomy, has been recommended in infants born with imperforate anus and in whom the rectum cannot be found through an incision made in the perineum. This is no argument, however, against the left iliac operation, for even if the flexure does occupy the right iliac fossa, it can readily be found through the incision made in the left rectus muscle. The only anatomic reason for giving iliac colostomy the preference over lumbar colostomy is that in a certain percentage of cases the descending mesocolon is so long as to make it impossible to reach the colon through the the incision in the loin. An exploratory laparotomy is impossible through the lumbar approach. Anatomically the chief advantage of the lumbar over the iliac operation is that the absence of peritoneum on the posterior aspect of the colon overcomes the necessity of opening the peritoneal cavity.

Dissection.—At this point the topography of the duodenum, the pancreas, and the vessels in relation with the same are best studied. A blow-pipe should be introduced into the divided end of the jejunum. Before inflating the duodenum and stomach, however, the stomach should be lifted up, but not high enough to disturb the commencement of the duodenum, so that the direction taken by the duodenum can be observed. The distended stomach should be displaced upward, and the posterior parietal peritoneum dissected up from where it has been divided in cutting through the transverse mesocolon. The duodenum and pancreas will now be seen throughout their extent, and the superior and inferior pancreatico-duodenal arteries will be found in the groove between the duodenum and the head of the pancreas.

The **duodenum** (Plate CCCCXX) is the first, the shortest, and the widest portion of the small intestine. Its length, which is twenty-five to thirty centimeters (ten to twelve inches) is less variable than that of the jejunum and ileum. It commences at the pyloric sphincter, and ends in the jejunum to the left of the body of the second lumbar vertebra.

It consists of four portions: first ascending, descending, transverse, and terminal ascending portion.

The **first,** or **first ascending, portion** is nearly horizontal or transverse, and is about five centimeters (two inches) long. Like the stomach, this portion is comparatively movable, more so than any of the other portions of the duodenum. It passes upward, lateralward, and posteriorly from the pyloric end of the stomach to the neck of the gall-bladder. Like the stomach, it is completely surrounded by peritoneum, which, in turning to the right, again forms the free border of the gastro-hepatic omentum just above it. Situated above it are the foramen of Winslow (*foramen epiploicum*) and the lesser omentum; below, is the head of the

pancreas; in front of it are the liver and the neck of the gall-bladder, and behind it are the common bile duct, the hepatic artery, the portal vein, and the gastro-duodenal artery. Owing to the relation which this portion holds to the gall-bladder, its anterior surface is frequently found stained with bile after death.

The **second, or descending, portion** is about seven centimeters (three inches) in length, and extends from the neck of the gall-bladder to the level of the third lumbar vertebra. Its anterior surface is covered with peritoneum—the ascending layer of the transverse mesocolon—except where the transverse colon passes in front of it, and is firmly fixed to the head of the pancreas by connective tissue and peritoneum. In front of it is the commencement of the transverse colon; behind it are the common bile duct, the medial border of the right kidney, the renal vessels, and the inferior vena cava; on its medial, or left, side are the common bile and the pancreatic ducts, both of which open into it, the superior and inferior pancreatico-duodenal arteries, and the head of the pancreas. After obliquely traversing the wall of the bowel, the pancreatic and the common bile ducts open into the postero-internal aspect of the lower part of this segment of the duodenum, on the summit of a papilla.

The **third, or transverse, portion,** the longest and narrowest part of the duodenum, is about twelve centimeters (five inches) in length; it passes obliquely upward and toward the left side, across the vertebral column, at the third lumbar vertebra, to the left of the second lumbar vertebra, where it terminates. A line drawn from a point seven centimeters (three inches) to the right of the umbilicus, to a point five centimeters (two inches) to the left and above it, will nearly indicate its position. Its anterior surface, except where the superior mesenteric artery and vein cross it, is covered by peritoneum, the descending layer of the transverse mesocolon. In front of it are the superior mesenteric artery and vein, the jejunum, and the lower layer of the transverse mesocolon; behind it are the crura of the diaphragm, the inferior vena cava, and the abdominal aorta; above it are the superior mesenteric artery and vein, the pancreas, and the inferior pancreatico-duodenal artery; below it are parts of the mesentery and posterior parietal peritoneum.

The **fourth, or terminal ascending, portion** is the shortest portion, being about two and a half centimeters (one inch) in length. It commences immediately to the left of the second lumbar vertebra, passes upward on the surface of the left psoas muscle, and terminates at the point where the mesentery begins, namely, at the origin of the jejunum. It is covered by peritoneum on the anterior surface and partly on the sides, and is firmly fixed to the left crus of the diaphragm and the connective tissue around the celiac axis (*celiac artery*) by a band of fibrous tissue which contains some muscle tissue as well, and is called the *musculus*

suspensorius duodeni (ligament of Treitz), or suspensory ligament of the duodenum and mesentery. The junction of the terminal portion of the duodenum with the jejunum constitutes the *duodeno-jejunal flexure*, below and to the left of which is the duodeno-jejunal fossa. This has been described with the peritoneum.

Surgery of the duodenum.—Being destitute of peritoneum posteriorly, the duodenum beyond the first portion may be wounded from behind without opening the peritoneal cavity. The relations which the duodenum bears to the liver, gall-bladder, common bile duct, kidney, colon, pancreas, aorta, and vertebral column must be borne in mind in order to explain the origin of certain complications, as well as sequelæ of disease of any of these organs. From the relation the gall-bladder bears with the duodenum it may be understood how, by ulcerative perforation, a communication may be established between them, thus making a spontaneous cholecysto-duodenostomy, by way of which gall-stones too large to pass through the cystic and common bile ducts may reach the duodenum. It is due to this relation, together with the fact that the first portion of the duodenum is quite freely movable, that the operation of cholecysto-duodenostomy provides a means of relieving obstruction of the common bile duct due to a growth involving the head of the pancreas or the duodenum at the site of the papilla of Vater (*duodenal papilla*), in cases where neither of them can be removed.

Adhesions from cholecystic disease may so deform the duodenum as to cause a partial obstruction. Ulcer of the duodenum also is a very frequent surgical lesion. The majority of these ulcers are within five centimeters (two inches) of the pylorus, and are most frequently on the anterior wall. The peritoneum on the right side of the first portion of the duodenum looks into the general peritoneal cavity while that of the left side looks into the lesser cavity. This should be remembered when operating for perforated duodenal ulcer. In exposing the duodenum it is well to remember that the gall-bladder when distended lies in front of the duodenum; that by elevating and drawing forward the transverse colon, which lies in front of and below the horizontal portion of the duodenum, the first portion is better exposed and that by pushing the stomach and pylorus to the left and elevating the liver, better access to the duodenum is obtained.

In operations for duodenal ulcer any procedure which removes the ulcer gives the best chance for permanent cure. In the hands of the general surgeon, however, posterior gastro-enterostomy will give a better percentage of relief from symptoms and at the same time a lower mortality than one of the more radical operations. When the ulcer is excised care should be taken carefully to close the duodenum so that leakage will not occur. The more radical operations, each of which has its place in selected cases, are the Polyá operation, the Finney pyloroplasty and a type of resection suggested by Finsterer. In those cases in which

pylorectomy or subtotal gastrectomy is a part of the procedure care must be taken not to injure the gastro-duodenal artery and the common bile duct.

Duodenotomy may be necessary in cases of impacted stone in the ampulla of Vater (*ampulla of bile duct*). The second portion of the duodenum may be mobilized by dividing the peritoneum along its posterolateral aspect.

The **pancreas** (Plates CCCCXX; CCCCXXI; CCCCXXII) is a long, slender organ extending from the second portion of the duodenum through the epigastric region, to the hilum of the spleen, in the left hypochondriac region. It measures from fifteen to twenty centimeters (six to eight inches) in length, from two and a half to four centimeters (one to one and a half inches) in breadth, and from one to two and a half centimeters (one-half to one inch) in thickness, and weighs, on an average, about eighty-five grams (three ounces). It is composed of three portions: a head, a body, and a tail. The head is the largest portion, and is embraced in the concavity of the curve formed by the first, second, and third portions of the duodenum; the body crosses the bodies of the first and second lumbar vertebræ, and in front of the great vessels, and has an anterior, a posterior, and an inferior surface; the tail is in contact with the anterior margin of the hilum of the spleen.

It is a compound racemose gland which resembles the salivary glands in structure, although it is looser and softer in texture. It is surrounded by a layer of areolar tissue which binds the different lobules of the gland together by dipping down between them. It secretes a digestive fluid—the pancreatic juice—which is carried to the duodenum by the **duct of the pancreas or duct of Wirsung.** This duct runs almost the whole length of the gland within its substance, and along its course receives numerous tributaries which join the main duct at right angles. These tributaries subdivide, the terminal divisions ending in a number of acini which form the separate lobules. The duct empties into the second portion of the duodenum, generally in common with the common bile duct. It may become occluded by a calculus and thus give rise to symptoms simulating biliary colic.

The **accessory pancreatic duct,** or **duct of Santorini,** is a small duct which opens into the duodenum, either independently of the pancreatic duct at a point about three centimeters (one and a quarter inches) above and in front of the latter, or empties into the duct of Wirsung (*pancreatic duct*) as it turns downward, thus reaching the duodenum.

Relations.—In front of the pancreas are the ascending layer of the posterior parietal peritoneum and the stomach. Behind it are the crura of the diaphragm, the inferior vena cava, the aorta, the splenic artery and splenic vein, the origin of the superior mesenteric artery, the terminations of the superior and inferior mesenteric veins, the commencement of the portal vein, the left renal vein, the

PLATE CCCCXXI.

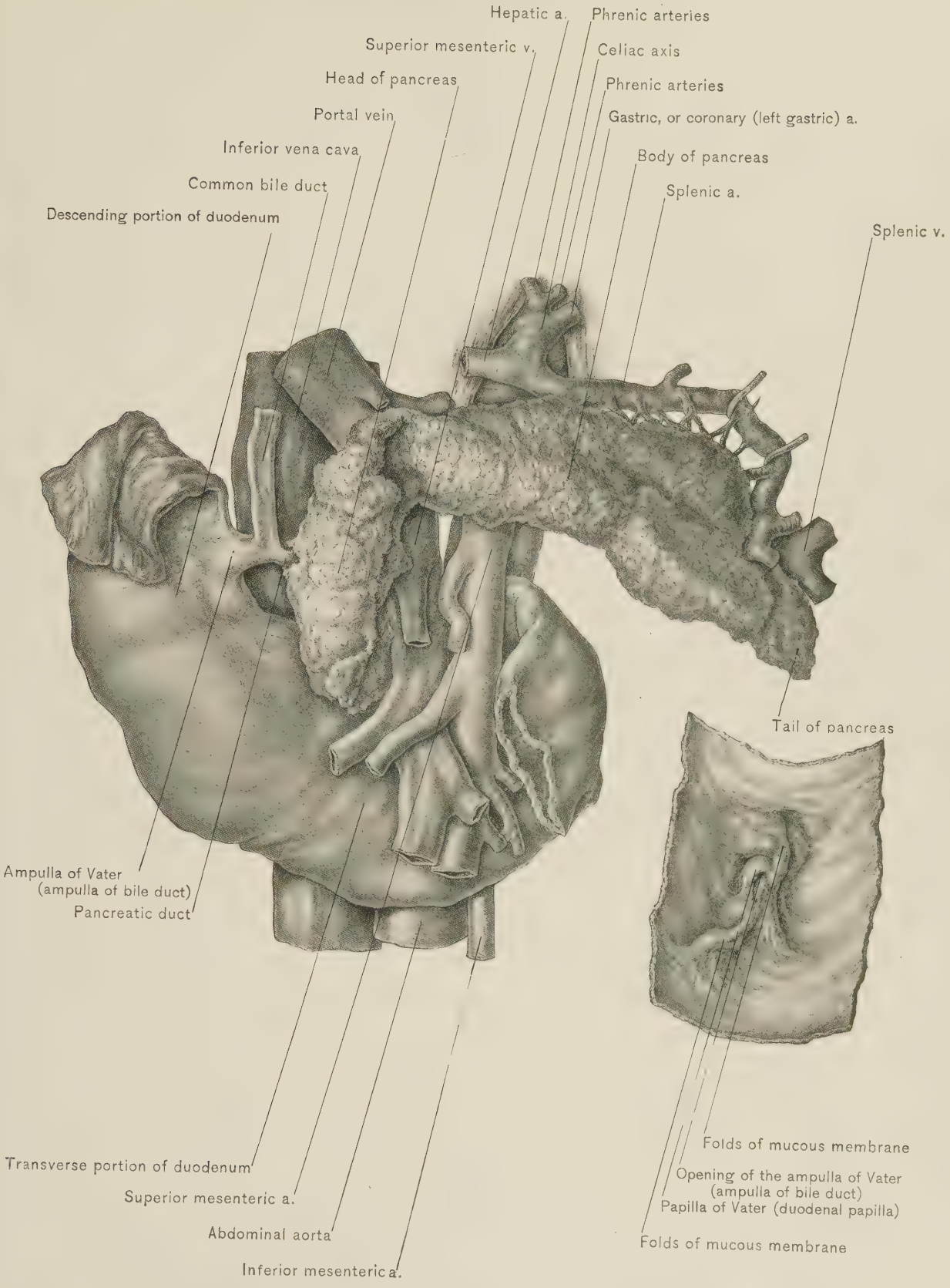

PANCREATIC AND COMMON BILE-DUCTS.

PLATE CCCCXXII.

PANCREAS AND DUODENUM, WITH PANCREATIC AND COMMON BILE DUCTS.

left kidney and suprarenal gland. Above it are the celiac axis (*celiac artery*) and the hepatic and the splenic artery. The lower surface is narrow and is in contact with the transverse portion of the duodenum, the duodeno-jejunal flexure, the transverse colon, and the transverse mesocolon.

Blood Supply.—The blood supply of the pancreas is derived from the pancreatic branches of the splenic and hepatic arteries, and from the superior and inferior pancreatico-duodenal arteries. The veins of the pancreas empty into the splenic and superior mesenteric veins.

Nerve Supply.—The nerve supply of the pancreas is derived from the solar (*celiac*) plexus. These nerves accompany the arteries.

Surgery of the pancreas.—Occasionally, an accessory pancreas is found in various locations within the abdomen which may be mistaken for a new growth. An important anomaly is one in which the pancreas surrounds the second portion of the duodenum and gives rise to a high obstruction. The situation of the pancreas, the partial protection it receives from the costal arch, and the depth at which it lies render it unlikely to injury from trauma. The close relationship of the lymphatics of the gall-bladder, liver and pancreas explains the frequent association of cholelithiasis and pancreatitis. Armstrong believes that occlusion of the duodenal orifice of the common duct permits the entrance or retrojection of bile into the duct of Wirsung (*pancreatic duct*) and thus causes acute inflammation of the pancreas. I do not find this to be a frequent cause of the lesion, since it is well known that human bile is almost innocuous. A calculous occluding the ampulla of Vater (*ampulla of bile duct*) does not of necessity cause complete obstruction of the pancreatic secretion, since in fifty per cent of cases the duct of Santorini (*accessory pancreatic duct*) communicates with the main duct within the gland and opens into the duodenum by a separate orifice. From the relation which the pancreas holds with the stomach it can be understood why it is so often involved in carcinoma of the posterior wall of the stomach. At times, also, it is the site of primary carcinoma which, if it involves the head of the organ, may cause occlusion of the common bile duct and consequent jaundice. If the tumor affects that part of the organ in relation with the aorta or in immediate proximity thereto, it may simulate aortic aneurysm by causing a swelling over which pulsation transmitted to it by the aorta is detected. When a pancreatic cyst assumes a large size it may be mistaken for an ovarian cyst. The pancreas is most readily reached by displacing the greater omentum, the transverse colon, and the transverse mesocolon upward and dividing the lower layer of the transverse mesocolon. It can also be exposed through the gastro-hepatic and gastro-colic omenta and from behind. The pancreas rarely forms part of a diaphragmatic hernia and more rarely a part of an umbilical hernia.

The **splenic artery,** the largest branch of the celiac axis, (*celiac artery*) runs tortuously along the upper border of the pancreas, and reaches the hilum of the spleen by passing between the layers of the lieno-renal ligament.

The **branches of the splenic artery** are the pancreatic, vasa brevia, left gastro-epiploic, and terminal branches.

The **pancreatic branches** are *small* branches that arise from the splenic artery in its course above and beneath the pancreas. They enter and supply the pancreatic tissues. A large branch given off near the tail of the pancreas, runs from left to right, and accompanies the pancreatic duct.

The **vasa brevia** (**short gastric arteries**) arise from the terminal part of the splenic artery or its terminal branches, pass to the cardiac end of the stomach, between the layers of the gastro-splenic omentum, and anastomose with branches of the coronary (*left gastric*) and the left gastro-epiploic artery.

The **left gastro-epiploic artery,** the largest branch of the splenic, runs from left to right along the greater curvature of the stomach, between the descending layers of the greater omentum, where it anastomoses with the right gastro-epiploic artery.

Dissection.—The pancreas and the splenic artery should be displaced downward and forward in order to expose the splenic vein.

The **splenic vein** is a large vein which runs behind the pancreas and below the splenic artery, to join the superior mesenteric vein, with which it forms the portal vein. Unlike the splenic artery, the vein pursues a direct course. It receives the inferior mesenteric vein and branches corresponding to those of the splenic artery.

Dissection.—Displace the pancreas anteriorly and upward, and expose the commencement of the superior mesenteric artery, the terminations of the superior and inferior mesenteric veins, and the beginning of the portal vein.

The **superior mesenteric artery** arises from the front of the aorta, a short distance below the celiac axis (*celiac artery*) and behind the pancreas, opposite the first lumbar vertebra. Sometimes it arises as a common trunk with the celiac axis (*celiac artery*). It runs downward behind the pancreas and the splenic vein, and then forward between the lower surface of the pancreas and the third portion of the duodenum, to enter the mesentery where it takes a curved course with its convexity to the left and ends in the right iliac fossa by anastomosing with its own ileo-colic branch. The vein is on its right side.

The **inferior pancreatico-duodenal artery** arises from the superior mesenteric artery, behind the lower margin of the pancreas. It takes a curved course around the head of the pancreas, between it and the duodenum, and supplies branches to both. It terminates by anastomosing with the superior pancreatico-duodenal artery.

PLATE CCCCXXIII.

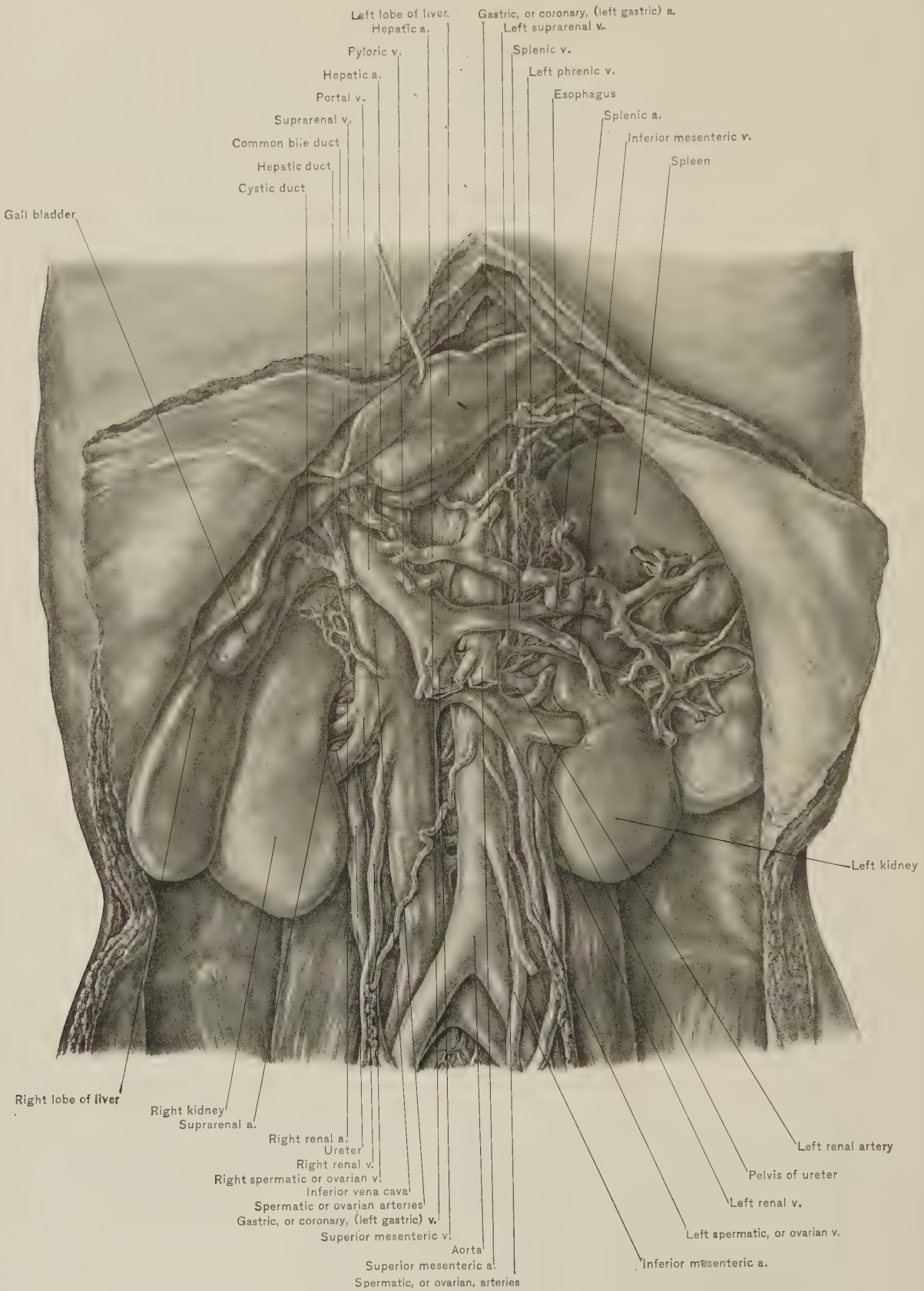

PORTAL VEIN, SUPERIOR AND INFERIOR MESENTERIC VEINS, AND SPLENIC VESSELS.

The **superior mesenteric vein** (Plate CCCCXXIII), the accompanying vessel of the superior mesenteric artery, runs a short distance in front and to the right of this artery. Like the latter it passes between the third portion of the duodenum and the lower surface of the pancreas, then behind the pancreas, at the upper border of which it joins the splenic vein in front of the inferior vena cava, to form the portal vein.

The **inferior mesenteric vein,** the accompanying vessel of the inferior mesenteric artery, runs upward beneath the posterior parietal peritoneum, as already described. It passes along the left side of the third portion of the duodenum, and then behind the pancreas, to join the splenic vein to the left of the union of the latter vein with the superior mesenteric vein.

Dissection.—The liver should now be removed, so that it can be more fully studied. First, the round ligament and suspensory (*falciform*) ligament are to be divided, and, after drawing the liver downward, the lateral (*triangular*) ligaments of the organ should be severed, and then the upper, or anterior, layer of the coronary ligament. Next that portion of the posterior surface which is connected to the diaphragm by areolar tissue should be separated from its attachment. The liver being now displaced further downward, the inferior vena cava will be seen emerging from the posterior surface of the liver, on its way to pierce the central tendon of the diaphragm, just below which the inferior vena cava should be severed. Then the remaining or inferior layer of the coronary ligament should be divided, and the inferior vena cava at the level of the under surface of the liver severed. After severing the structures which traverse the transverse fissure (*porta hepatis*) of the liver, and separating the gall-bladder from the right lobe, the liver may be lifted out of the abdominal cavity.

The **liver,** the largest gland in the body, weighs from about fourteen hundred and fifty to seventeen hundred and fifty grams (three to three and three-quarters pounds). It is of firm consistency and of a reddish-brown color. Its main bulk lies in the right hypochondriac region, although it extends through the epigastric, and sometimes into the left hypochrondriac, region. It occupies the entire anteroposterior diameter of the right upper abdominal cavity. In the child the liver is proportionately much larger than in the adult. It fits closely into the concavity of the diaphragm above, its superior and posterior surfaces being in contact with that muscle. It lies mostly under shelter of the ribs, but is exposed in the epigastric (*subcostal*) angle and at times along the right costal margin.

The plasticity of the liver is so great that its shape changes considerably after it has been removed from the body and laid on a flat surface. On the surface of a liver which has been hardened *in situ*, the various depressions for the different organs which abut against it are plainly seen, and the fissures and lobes are more

distinct in their outlines. The liver has five surfaces, one border, two extremities, four lobes, five fissures, five ligaments, and five sets of vessels.

The **surfaces of the liver** (Plates CCCCXXIV and CCCCXXV) are the superior, the inferior, the posterior, the anterior and the right lateral.

The **superior surface** and **anterior surface** can be considered as one. It lies against the dome of the diaphragm, to which and to the anterior abdominal wall it is attached by the suspensory (*falciform*) ligament. It is convex and smooth, and is entirely covered by peritoneum. The suspensory (*falciform*) ligament is attached along its anteroposterior diameter, dividing the surface into two divisions which represent the superior surface of the right and the left lobe. The area opposite the heart is concave, that opposite the lungs convex.

The **inferior, or visceral, surface** is very irregular, being subdivided by fissures and vessels, and it, too, is entirely covered with peritoneum except where the gall-bladder lies in contact with this surface and at the transverse fissure (*porta hepatis*). A longitudinal sulcus (*left sagittal fissure*) divides it into a right and a left lobe.

The **posterior surface,** triangular in shape, is irregularly concave from side to side, the concavity being due to pressure against the vertebral column. Slightly to the right of the concavity will be found the inferior vena cava embedded in the liver. To the right of the inferior vena cava this surface of the liver is rough, being the non-peritoneal area of the liver, and is connected with the diaphragm by the connective tissue situated between the two layers of the coronary ligament. The part of this surface represented by the right lobe is broad, while that corresponding to the left lobe is narrow. The right extremity is thick and rounded, while the left is thin and flattened.

The right lateral surface is quadrilateral in shape and roughly convex. It lies against the diaphragm opposite the seventh to the eleventh ribs in the mid-axillary line and against the transversus abdominis muscle for one centimeter (half an inch) below the ribs.

The **fissures of the liver** are arranged in the form of the letter H, and so placed that they divide the liver into its various lobes. They are: the longitudinal fissure (*left sagittal fissure*), which is subdivided into the umbilical fissure, and the fissure for the ductus venosus; the transverse fissure (*porta hepatis*); the fissure for the gall-bladder, and the fissure for the inferior vena cava. They are found on the inferior and the posterior surfaces.

The **longitudinal** (**left sagittal**) **fissure** extends from the notch in the anterior border of the liver to the posterior surface, separating the right and left lobes. It is joined at right angles by the transverse fissure (*porta hepatis*), which divides it into two unequal parts; the anterior of these is the deeper of the two.

PLATE CCCCXXIV.

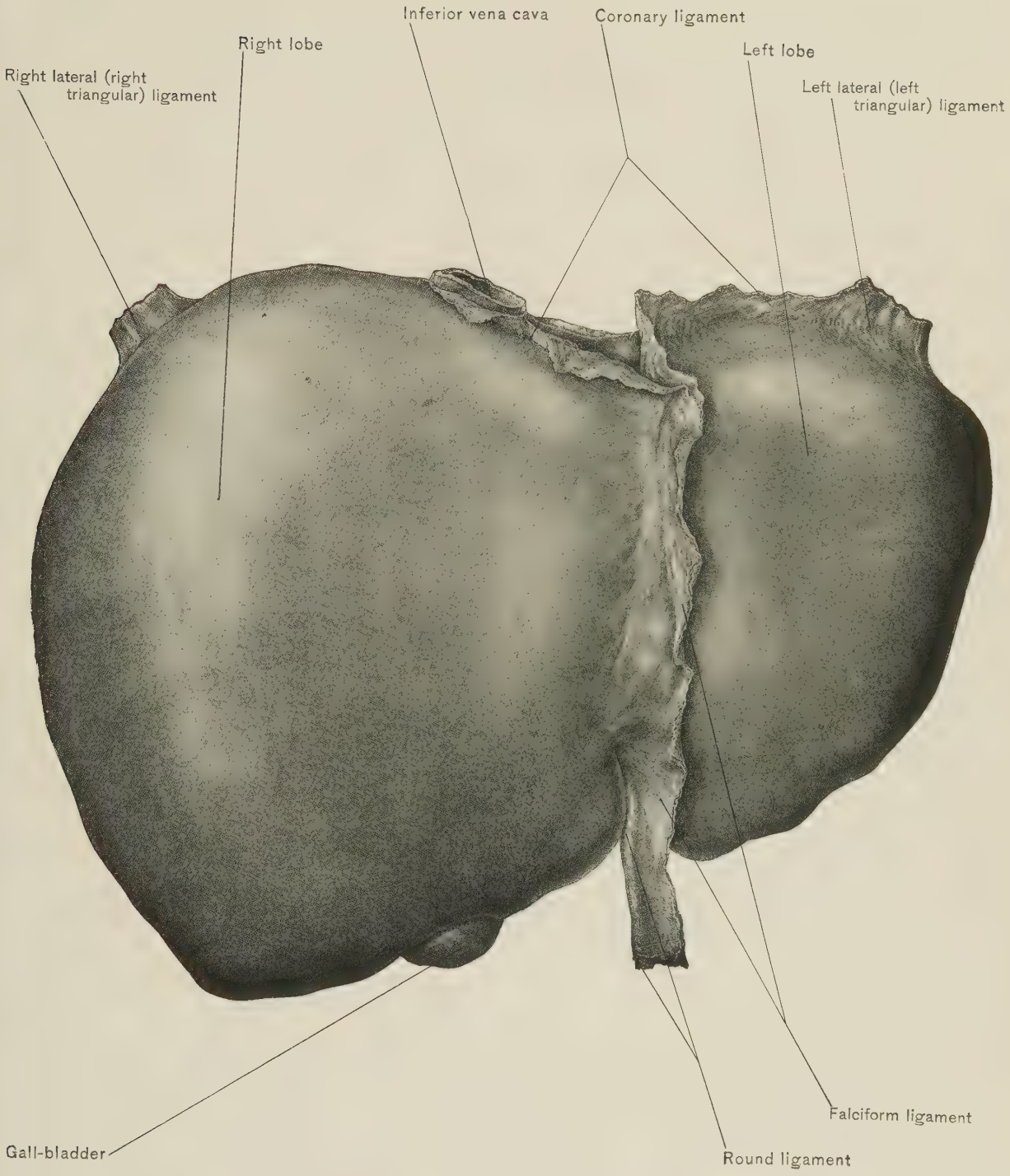

SUPERIOR SURFACE OF LIVER.

PLATE CCCCXXV.

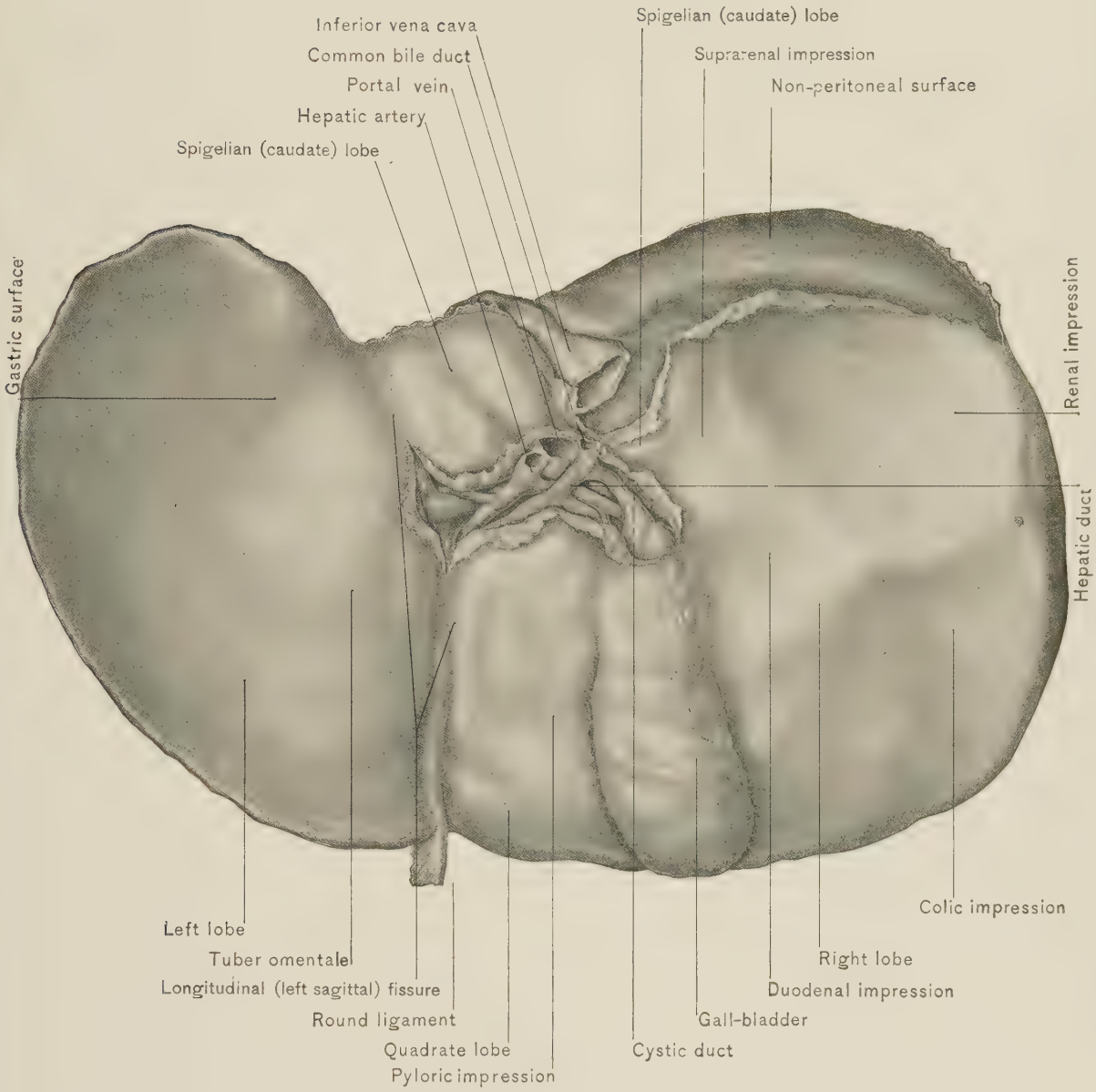

INFERIOR SURFACE OF LIVER.

It lodges the umbilical vein in the fetus, and its remains, the round ligament in the adult; it is therefore called the **umbilical fissure.** It is sometimes bridged over by a piece of the hepatic substance, the *pons hepatis.* The posterior portion of the longitudinal (*left sagittal*) fissure, known as the **fissure of the ductus venosus,** lodges the ductus venosus in the fetus, and in the adult a small, fibrous cord, ligamentum venosum, the remains of this vessel.

The **transverse fissure** (**porta hepatis**) is a deep depression about five centimeters (two inches) in length; it extends transversely to the right from the longitudinal (*left sagittal*) fissure, and is situated about midway between the anterior border and the posterior surface of the liver. It connects the upper ends of the fissure for the round ligament and the fossa for the gall-bladder. It is the hilum of the organ for the passage of the hepatic artery and nerves, the hepatic ducts, the portal vein, and the lymphatics. The lesser omentum is attached to its margins. Just below the fissure the vessels hold a definite arrangement, the common duct lying to the right of the artery, with the portal vein between and behind them.

The **fissure, or fossa, of the gall-bladder** is a shallow depression found on the inferior surface of the right lobe. It extends from the anterior margin to near the right extremity of the transverse fissure (*porta hepatis*). It lies parallel with the longitudinal (*left sagittal*) fissure.

The **fissure for the inferior vena cava** is found to the right of the Spigelian (*caudate*) lobe, this part of the liver separating it from the longitudinal (*left sagittal*) fissure. It is very short and deep, and is sometimes bridged over by liver substance, when it forms a complete canal. Its course is oblique.

The **lobes of the liver** are the right, the left, the quadrate, and the Spigelian (*caudate*). The number of lobes may be increased or diminished according to the number of fissures present. An entirely separate and distinct "accessory liver," composed of true liver substance, is sometimes found hanging from the left lobe.

The **right lobe** forms the main bulk of the organ, comprising fully four-fifths of the entire mass. It is separated from the left lobe, above, by the line of attachment of the suspensory (*falciform*) ligament; below, by the longitudinal (*left sagittal*) fissure; and in front, by a deep notch. The under surface has a fossa for the gall-bladder and two shallow impressions. The anterior, or *colic, impression* rests upon the hepatic (*right colon*) flexure of the colon, and the posterior, or *renal, impression* upon the right kidney. To the left side of the lower part of the renal impression is the impression for the upper end of the second part of the duodenum, and the suprarenal gland may likewise cause a slight impression. This surface also presents the two smaller lobes—the Spigelian (*caudate*), the quadrate, and the caudate process.

The **left lobe** is smaller than the right in all of its diameters, and is more nearly flat. It is found in the epigastric region, and rarely extends more than six centimeters (two and a half inches) beyond the left margin of the sternum, although it may extend into the left hypochondriac region. It overlaps and almost completely covers the stomach when that organ is not distended. The posterior surface of this lobe is notched for the esophagus. To the left of this notch, on the inferior surface, is the shallow *gastric impression* for the stomach. Between this depression and the longitudinal (*left sagittal*) fissure is found a slight elevation, the *omental tuberosity* (*tuber omentale*), which lies against the lesser omentum and the lesser curvature of the stomach.

The **Spigelian** (**caudate**) **lobe** extends from the transverse fissure (*porta hepatis*) to the posterior surface of the liver, and between the fissures for the inferior vena cava and the ductus venosus. It is found in the concavity of the posterior surface of the liver, being separated from the spinal column by the diaphragm and the aorta. It is connected with the under surface of the right lobe of the liver by the caudate process.

The **quadrate lobe** is found on the inferior surface of the right lobe, between the umbilical fissure and the fissure for the gall-bladder, and extends from the anterior border of the liver to the transverse fissure (*porta hepatis*). It is in relation with the pyloric end of the stomach and the first part of the duodenum.

The **caudate process** is a narrow eminence which extends obliquely forward and to the right from the base of the Spigelian (*caudate*) lobe to the inferior surface of the right lobe. It separates the fissure for the inferior vena cava from the right end of the transverse fissure (*porta hepatis*).

The **five sets of vessels of the liver** are: the hepatic artery, the portal vein, the hepatic duct, the lymph vessels, and the hepatic veins. The first three lie together at the transverse fissure (*porta hepatis*), the vein being behind the other two, and the duct to the right of the artery. They are covered by the capsule of Glisson (*fibrous capsule*), and are accompanied by nerves and lymphatics.

The **hepatic veins** are venous channels within the liver which do not extend beyond its substance. They empty directly into the inferior vena cava at the point where it is apposed to the liver, and the inferior vena cava is firmly attached to the liver by these hepatic veins and by fibrous tissue.

The **lymphatics of the liver** constitute a superficial and a deep set.

The **superficial lymphatics** are found in the subperitoneal connective tissue covering the entire organ, and consist of several groups: (1) three or four branches pass forward upon the convex surface of the liver and into the suspensory (*falciform*) ligament, where they unite into a single trunk which enters the

chest through the small diaphragmatic opening at the side of the xiphoid cartilage, to join the anterior mediastinal glands, eventually emptying into the right lymphatic duct. (2) A similar group turns downward over the anterior border of the liver to its under surface, runs along the longitudinal (*left sagittal*) fissure to the transverse (*porta hepatis*) fissure, and thence to the glands of the gastro-hepatic omentum. (3) Some lymphatics pass over the superior surface of the liver to its right lateral (*right triangular*) ligament, where they either pierce the diaphragm and cross to the left and enter the anterior mediastinal glands, or pass to the left over the right crus of the diaphragm to enter the lower end of the thoracic duct. (4) Other lymphatics pass toward the left, along the superior surface of the left lobe, to the left lateral (*left triangular*) ligament, where they perforate the diaphragm and pass forward to the anterior mediastinal glands. (5) The lymphatics from the right of the gall-bladder on the under surface empty into the lumbar glands. (6) The lymphatics surrounding the gall-bladder form a plexus and pass to the glands of the gastro-hepatic omentum. (7) The glands from the under surface of the liver upon the left of the gall-bladder pass to the esophageal glands and to the glands along the lesser curvature of the stomach. (8) It has been definitely shown that certain of the lymphatics from the gall-bladder pass into the liver to meet the deep hepatic lymphatics, while still others inosculate with the lymphatics around the head of the pancreas.

The **deep lymphatics** accompany the portal and hepatic veins through the liver. The portal lymphatics enter the glands of the lesser omentum; those which follow the hepatic veins pass through the canal opening in the diphragm and enter the thoracic duct.

Blood Supply.—The blood supply of the liver is derived from the hepatic artery and the hepatic branch of the gastric artery.

Nerve Supply.—The nerve supply of the liver is derived from the hepatic plexus of the thoracico-lumbar outflow of the sympathetic nerves, and from the left vagus. They accompany the ramifications of the hepatic artery after entering the liver at the transverse fissure (*porta hepatis*) through the liver substance to the interlobular spaces, and send branch plexuses along the pyloric (*right gastric*) and gastro-epiploic arteries. A *cystic branch* for the gall-bladder is also derived from the hepatic plexus.

The fact that the right phrenic nerve sends branches to the capsule of the liver is of interest in connection with the "shoulder-tip pains" of certain hepatic affections. The phrenic nerve is derived mainly from the fourth cervical nerve, which also sends a branch—the supra-acrominal (*posterior supraclavicular*)—to the integument at the summit of the shoulder. A portion of the phrenic comes from the fifth cervical and this segment also gives rise to the suprascapular nerve.

It is through a central reflex action that pain in biliary tract disease is referred to the distribution of the supra-acromial (*posterior supraclavicular*) and supra-scapular nerves.

Structure of the liver.—The structural arrangement of the liver is comparable to clusters of grapes so closely packed together that the mutual pressure would give the fruit a polyhedral form, and so that a section would show the grapes polygonal and edge to edge. Each grape represents a liver lobule through the center of which passes a vein called the *central*, or *intralobular*, vein. The stems which support the grapes represent the sublobular veins into which the central veins empty, while the larger stalks formed by the union of many branches represent the hepatic veins which eventually enter the inferior vena cava. The interspaces between the compressed polygonal grapes correspond to the interlobular spaces of the liver, in which are found the branches of the hepatic duct and of the afferent vessels—the portal vein and the hepatic artery. The hepatic artery and portal vein form a network about each lobule, from which small vessels penetrate the lobule, those from the artery for nourishment, and those from the portal vein to bring work, all of which is done in the short transit of blood from the periphery, to the center of the lobule. This arrangement of the liver is simple, readily understood, and when once mastered is the key to a number of important pathologic facts which it is otherwise difficult to remember.

The **gall-bladder** (Plate CCCCXXV) is a conical or pear-shaped viscus about ten centimeters (four inches) long and about four centimeters (one and a half inches) wide at its widest part, and its capacity is about forty cubic centimeters (one and a quarter ounces). It is lodged in a special fossa on the under surface of the right lobe of the liver, extending from near the right extremity of the transverse fissure (*porta hepatis*) to the anterior border of the organ. To facilitate description it is divided into a fundus, a body, and a neck. The **fundus** projects slightly beyond the anterior margin of the liver, between the right and the quadrate lobe, and just below the chondral margin, opposite the ninth costal cartilage, or at the intersection of the costal margin and the lateral border of the right rectus muscle. The **body and the neck** are directed backward, upward, and to the left. The neck presents a curve like the letter **S,** and narrows to a point ending in the cystic duct. Oftentimes, as the result of pathology, there is a dilatation between the body and the neck of the gall-bladder. This is known as the pelvis or infundibulum, and is frequently found adherent to the right free border of the gastro-hepatic omentum. The gall-bladder is a fibro-muscular sac lined with mucous membrane and covered with peritoneum, which passes from its sides upon the adjoining surface of the liver; the gall-bladder, however, is sometimes, wholly invested by peritoneum, which

may form a sort of mesentery for it. The mucous membrane of the neck and of the cystic duct is arranged in a spiral fold, the valve of Heister (*spiral valve*), which prevents sudden expulsion of its contents. The gall-bladder is very tough—so much so, in fact, that if taken out of a fresh body, inflated, and then permitted to dry, a man of average weight may stand upon it without rupturing its walls.

Relations.—Above the gall-bladder is the under surface of the liver; below it are the first portion of the duodenum, the hepatic (*right colic*) flexure of the colon, and, at times, the pyloric end of the stomach. The fundus abuts against the anterior abdominal wall just below the ninth costal cartilage.

Structure of the gall-bladder.—The walls of the gall-bladder are composed of a serous, a fibro-muscular, and a mucous coat.

The **serous coat** is derived from the peritoneum. As was observed in the dissection of that membrane, the peritoneum completely surrounds the fundus of the gall-bladder, but is found only on the lateral and under surfaces of the body and neck.

The **fibro-muscular coat** is composed of a strong layer of fibrous tissue, the fibers interlacing in all directions to form a network. The smooth muscle fibers intermingle with the fibrous tissue. They run principally in a longitudinal direction, although some are placed transversely.

The **mucous coat** is yellowish-brown in color, and comprises a mesh-work, formed by the membrane being thrown into numerous rugæ. By an inward projection of the mucous layer opposite the neck of the gall-bladder oblique ridges or folds are formed so as to constitute the valve of Heister (*spiral valve*).

The **common duct of the liver,** the **ductus choledochus** (Plates CCCCXXI and CCCCXXII), is formed by the junction of the cystic and hepatic ducts, about one centimeter (half an inch) above the upper margin of the first portion of the duodenum. The **cystic duct** leaves the neck of the gall-bladder and passes obliquely downward for about four centimeters (an inch and a half), to join the hepatic duct. The **hepatic duct** is formed by two ducts of about equal size which leave the liver through the transverse fissure (*porta hepatis*). Both the hepatic and the cystic ducts traverse the gastro-hepatic omentum (*gastro-hepatic ligament*). The common bile duct descends between the layers of the lesser omentum on the right side of the hepatic artery, runs behind the first part of the duodenum, and passes along the posteromedial aspect of the second portion of the duodenum, where it lies embedded in the sulcus between that portion of the duodenum and the head of the pancreas. It is joined by the pancreatic duct, and then passes obliquely through the duodenal wall, and opens into the duodenum on the summit

of an elevation on the medial aspect of the gut, the papilla of Vater (*duodenal papilla*), about ten centimeters (four inches) from the pylorus. The intestinal orifice is somewhat constricted; just above the orifice of the duct it presents a dilatation, the *ampulla of Vater* (*ampulla of bile duct*), in which biliary calculi passing down the duct may lodge.

Structure.—The walls of the bile ducts are composed of two layers—an external, or fibrous, coat and an internal, or mucous, coat. The external layer is made up of fibro-areolar tissue with a few muscle fibers arranged in a circular direction. The mucous coat is continuous with the mucous coat of the gall-bladder and that of the two ducts forming the hepatic duct, and also with the mucous membrane of the duodenum. There are many mucous glands found in the mucous membrane.

Operations.—Surgical treatment is indicated in gall-stone disease usually as soon as a diagnosis is made. What I have for many years said about early operation for appendicitis applies as well to cholelithiasis. It is safer to operate while the stones are still in the gall-bladder than after they are in the common duct.

Many incisions have been advocated but I have found that the most useful one for the greater number of cases is the vertical right rectus incision. It is better to make this between the lateral third and medial two-thirds of the muscle. The incision should be long enough for adequate exposure of the gall-bladder and its ducts. Bevan supplements this incision by cutting loose the medial half of the rectus from its costal attachment. He also, if necessary, cuts the lateral half below, thus securing a wide exposure. The Kocher incision which runs parallel with the rib margin is used by many surgeons. It causes a larger percentage of herniæ and has no advantages from the standpoint of exposure. Where the common duct is to be explored I make an incision of sufficient length to deliver the medial half of the right lobe of the liver, and by rotating the edge of the liver bring the common duct almost to the surface of the body.

Cholecystostomy.—In my opinion there are only two indications for cholecystostomy. The first is for the removal of calculi when this is done by the inexperienced operator. I do not believe that there is such an operation as "ideal cholecystostomy." The second indication is in acute suppurative disease of the gall-bladder where the friable, edematous tissues do not lend themselves as readily to cholecystectomy, where hemorrhage is greater and a prolonged operation may turn the tide against a successful culmination of the case. A small right rectus incision is used in these cases. The distended gall-bladder is exposed and incised. The bile is aspirated and the calculi are removed. The tube is fixed in the gall-bladder by a double purse string suture. I never suture the gall-bladder to the parietal peritoneum.

Cholecystectomy.—After opening the peritoneal cavity I rotate the right lobe of the liver to the right, and at the same time pull it downward, lateralward, and upward. This brings the under surface of the liver forward so that one can see the right free border of the gastro-hepatic omentum and properly examine the junction of the cystic and common ducts. If the surgeon makes it a practice never to perform cholecystectomy until he has visualized this junction ductal anomalies will cause little concern and common duct injuries will become much more infrequent. The infundibulum of the gall-bladder may be adjacent and adherent to the common duct so that the cystic duct is not visible. In that case, separate the adhesions and visualize the cystic duct. The right hepatic duct may empty into the cystic duct. If this is found, divide the cystic duct distal to this point. Whatever anomaly exists be sure that it is seen before the removal of the gall-bladder is begun. I then pass a Kelly hemostat or a Shallcross forceps between the liver and the duct as close to the common duct as is possible. In this way the cystic artery and duct can be clamped together. A second clamp is applied just distal to the first one and the cystic duct and artery are severed. The gall-bladder is then stripped from its bed for a short distance. Before removing it entirely the duct and artery are ligated. Thus the gall-bladder acts as a tractor to keep the clamped cystic duct and artery well forward. After ligation of these structures the gall-bladder is removed and the parietal wound closed in the usual manner. If the common duct is to be explored I do this first using the gall-bladder as a tractor. This throws the common duct forward. In those cases necessitating its exposure and incision, it is usually distended and readily recognized.

Choledochostomy is best done below the entrance of the cystic duct but may be done anywhere if the stone is impacted. It is best to aspirate the common duct, before making the incision, with a fine hypodermic needle so as to be sure one is not opening the portal vein which normally lies between and behind the common duct and the hepatic artery. A small plexus of veins which surrounds the duct may give rise to some oozing after the incision. Occasionally the gastro-duodenal artery will lie anterior to the suprapancreatic portion of the common duct. If the duct is carefully exposed previous to incision this will be recognized. When a stone is impacted in the retropancreatic or retroduodenal portion of the duct the duodenum must be mobilized and turned downward in order to expose the site of impaction. The incision is made along the upper margin of the duodenum and the bowel is turned downwards. The upper margin is nearly avascular as far as any blood supply to the duodenum is concerned so that little bleeding is encountered.

Cholecystenterostomy is an operation which establishes a communication between the gall-bladder and the intestine when the common bile duct is obstructed by extrahepatic bile-duct obstruction or by a carcinoma of the papilla of Vater (*duodenal papilla*). **Cholecystagastrostomy** is adopted by some surgeons as the operation of choice, but I am still convinced that **cholecystoduodenostomy** is the operation of choice. The incision can be made through the right semilunar line, on a level with the tenth costal cartilage or through the right rectus muscle. It divides the skin, superficial fascia, aponeuroses of the external oblique, internal oblique, and transversalis muscles, transversalis fascia, preperitoneal fat, and peritoneum. The incision is preferably made through the right rectus muscle. The gall-bladder is then found and if possible is drawn into the wound and any stones found removed. The duodenum should next be brought into the wound. The duodenum and gall-bladder should then be approximated and held in apposition by four rows of sutures, two anterior and two posterior. The anastomosis is not unlike that of a posterior gastro-enterostomy. The gall-bladder and duodenum should be carefully aspirated when they are opened to prevent soiling. The first row is a continuous Lembert suture which unites the serous coats of the duodenum and the gall-bladder posteriorly. The second row is then introduced from within and secures the cut edges of the mucous membranes, after which the continuous Lembert suture is completed. The parietal wound is then closed in the usual manner.

Dissection.—The lower end of the esophagus, the phreno-splenic ligament, and any remaining portions of the peritoneum which are attached to the stomach, spleen, duodenum, or pancreas should be divided and these organs removed from the abdominal cavity. This will permit a thorough study of the structure of these organs.

Structure of the Stomach.—The stomach has already been described on page 387. The walls of the stomach are made up of four coats: serous, muscular, submucous, and mucous.

The **serous, or peritoneal, coat of the stomach** has been studied with the peritoneum. It will be remembered that the peritoneum entirely surrounds the stomach, with the exception of the curvatures, where there is a linear interval between the two layers of the omenta.

The **muscular coat of the stomach** is exposed by removing the serous coat. It consists of unstriped muscle fibers arranged in three layers: longitudinal, circular, and oblique.

The *longitudinal fibers* are placed externally and are continuous with the longitudinal fibers of the esophagus and the duodenum. They are thinly and irregularly distributed over the whole extent of the stomach, but are more

PLATE CCCCXXVI.

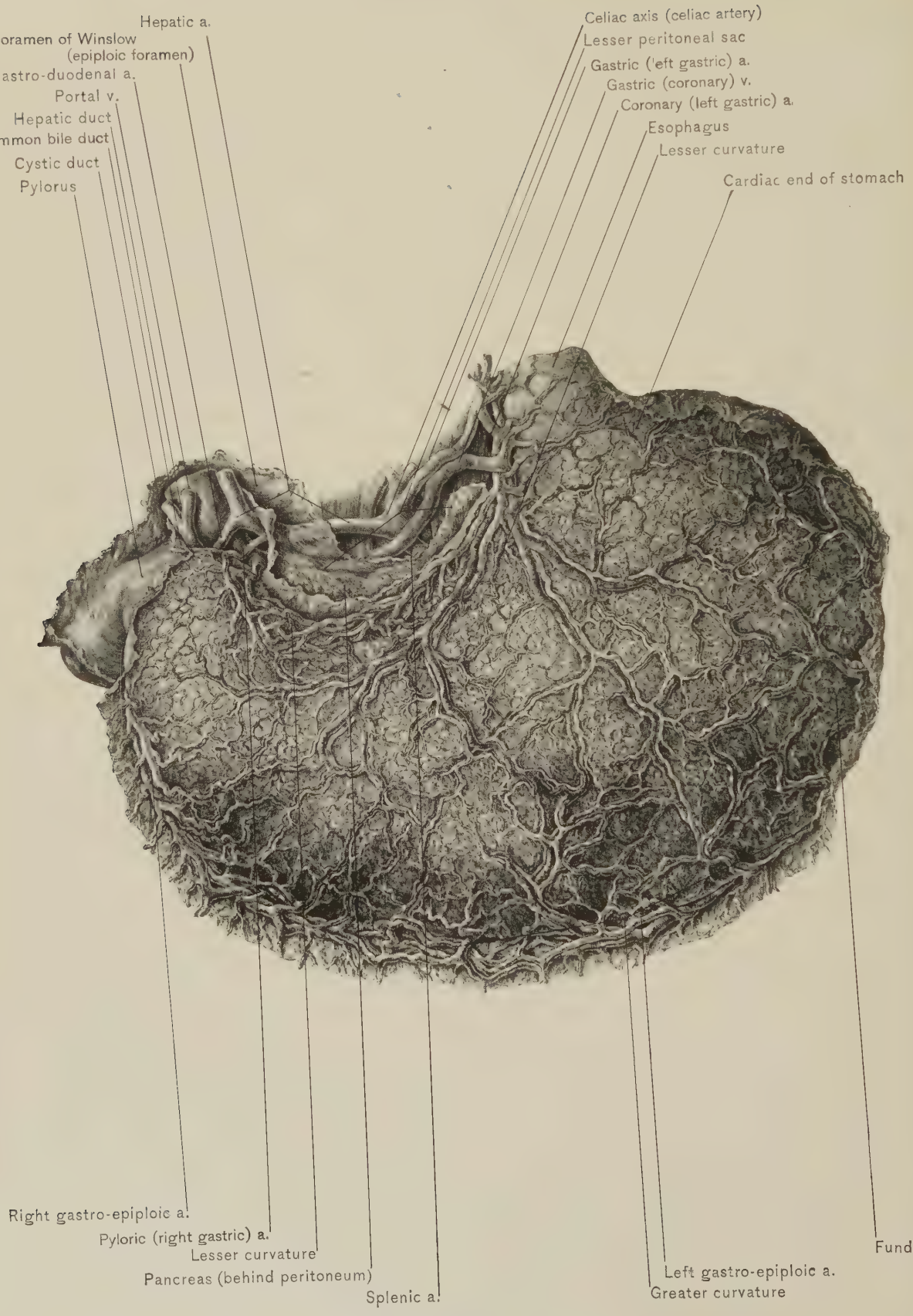

THE STOMACH AND ITS ARTERIES.

abundant along the curvatures and especially along the lesser curvature. They become more numerous near the pyloric end, where they are more evenly distributed and are continuous with the longitudinal muscle fibers of the duodenum.

The *circular fibers* lie immediately beneath the longitudinal set, comprising the middle set of fibers and consisting of V-shaped loops, open toward the fundus and circular near the pylorus. They are distributed over the whole extent of the organ and are continuous with the circular fibers of the esophagus. At the pyloric end of the stomach they are very abundant, and here form a sphincter which, with the mucous membrane covering its surface, is known as the *pyloric sphincter.*

The *oblique, or internal, fibers* are continuous with the circular fibers of the esophagus. They are found principally near the cardiac end of the stomach, where they pass to the left of the esophagus and run obliquely from right to left and from left to right, and finally unite with the circular fibers of the stomach.

The **submucous coat of the stomach,** sometimes called the areolar, or vascular, coat, is composed of loose areolar tissue. It connects the muscular with the mucous coat, and transmits the blood-vessels which run freely through this coat before supplying the mucous layer. It contains the nerve plexus of Meissner (*submucous plexus*).

The **mucous coat of the stomach** is quite thick, and presents a smooth, soft internal surface. In a healthy condition it is of a pinkish hue, which is much brighter in the infant. When the stomach is empty and collapsed, the mucous membrane is thrown up into numerous longitudinal folds, or rugæ. These are more numerous along the greater curvature. The *muscularis mucosæ*, a thin layer of muscle fibers, is placed in the deeper part of the membrane.

Under the microscope the internal surface of the mucous membrane is seen to be made up of numerous little hexagonal pits or depressions, which give it a honeycombed appearance. At the bottom of the pits are the minute orifices of the ducts of the *gastric glands.* A section perpendicular to the surface of the membrane shows the glands arranged in parallel lines at a right angle to the surface of the membrane. They terminate above the areolar layer in blind, sacculated ends. These glands secrete the gastric juice. For a description of these glands the student is referred to works on histology.

Blood Supply (Plate CCCCXXVI).—The blood supply of the stomach is derived from the gastric, or coronary (*left gastric*), pyloric (*right gastric*), right and left gastro-epiploic arteries, and the vasa brevia (*short gastric arteries*) from the splenic artery. These vessels supply the muscular coat and then ramify in the

submucous layer, where they break up into small vessels for final distribution to the mucous coat. The **veins** which correspond to the pyloric (*right gastric*) and gastric (*left gastric*) arteries terminate in the portal vein; those corresponding to the vasa brevia (*short gastric arteries*) and the left gastro-epiploic arteries end in the splenic vein; and the right gastro-epiploic vein empties into the superior mesenteric vein.

The **lymphatics of the stomach** follow the blood-vessels of the organ. Some of them follow the vessels along the curvatures between the layers of the omenta, and others pass from the cardiac end with the vasa brevia (*short gastric arteries*). They arise in the subserous and submucous coats, and are divided into three sets, which accompany corresponding blood-vessels. One set passes along the lesser curvature with the coronary (*left gastric*) vessels, collecting from both walls, and turns downward to enter the celiac glands. Another set runs along the greater curvature with the right gastro-epiploic vessels, also receiving from both walls; these are joined by lymphatics from the duodenum and also end in the celiac glands. A third set passes from the cardiac end with the vasa brevia (*short gastric arteries*), to join the splenic lymphatics.

Surgical anatomy of the stomach.—The portion of the stomach most accessible for operative interference is represented by a triangle bounded on the right side by the anterior margin of the liver, on the left by the cartilages of the eighth and ninth ribs, and below by a horizontal line passing between the tips of the tenth costal cartilages. The horizontal line corresponds with the lower portion of the stomach when not much distended. To expose the stomach, one of four incisions may be used: parallel with, and about two fingerbreadths from the free border of the left costal cartilages; through the linea alba; through the left semilunar line, or through the left rectus muscle. Although this is anatomically correct, the stomach is usually exposed through a right rectus or a medial line incision. Since the *esophageal orifice* lies ten centimeters (four inches) behind the seventh costal cartilage and about two and a half centimeters (one inch) from the median plane, this area is inaccessible in most cases for surgical intervention. This is also true of the fundus which rises to the level of the fifth rib in the midclavicular line. It is separated from the pericardium and the heart by the diaphragm. The pylorus lies against the neck of the pancreas, opposite the first lumbar vertebra. It is about one centimeter (one-half inch) to the right of the median plane in the *transpyloric plane*. The pylorus is readily recognized since its muscular coat is considerably thicker than that of the body of the stomach. The *pyloric sphincter* is marked by its thick circular muscle bundle and by a collection of veins which crosses its anterior surface beneath the peritoneum, at its junction with the duodenum.

Gastrostomy is the operation performed to establish an artificial opening in the stomach through the abdominal wall through which the patient may be supplied with nourishment.

The incision should be made through the medial side of the left rectus muscle. The middle of the incision should be about on a level with the lower border of the liver. The skin, superficial fascia, deep fascia, anterior sheath and fibers of the rectus muscle are divided. The posterior sheath of the rectus muscle, preperitoneal fat, and peritoneum are also divided. When the wound is retracted the liver will generally present, and, immediately under this organ, the stomach will be found. The liver can readily be recognized by its firmness, color, and relation to the surrounding organs. The stomach is drawn into the wound. The operation of opening of the stomach is a painless one, requiring no anesthetic so that the entire operation can easily be performed under local anesthesia. In opening the stomach care must be taken to carry the incision entirely through the wall of the organ, as there is a likelihood that the mucosa may be pushed before the knife. The operation can be concluded as suggested by Stamm, Witzel, or a number of other surgeons. I prefer the Witzel technic.

In the operation devised by Witzel a rubber catheter or tube is introduced into a small opening in the anterior wall of the stomach, and from five to six centimeters (two to two and a half inches) of the projecting portion of the catheter buried by folding over it two plaits of the stomach wall. The stomach, after being replaced, is then sutured to the parietal peritoneum, and the abdominal wound closed except at the site of the catheter.

Gastrotomy.—In performing gastrotomy, the steps in the operation are the same as those for gastrostomy. A similar incision is made, and the same structures are divided. The stomach should be drawn into the wound, and as large an opening made into it as is necessary to accomplish the purpose for which the operation is performed. If the lesion sought is on the posterior gastric wall the left hand should be introduced behind the stomach and this wall pushed through the opening in the anterior gastric wall.

In closing the gastric wound, the mucous membrane should first be approximated and held together by a continuous suture. The remaining layers of the stomach should then be closed with Lembert sutures. In making this suture, the needle is introduced through the serous and muscular layers into the submucosa but not through the mucous layer. After passing through the serous and muscular layers into the submucosa, the point of the needle is directed toward the surface and passes through the muscular and serous coats. It is then passed in the same manner through the serous and muscular coats on the other side of the wound, and the edges of the wound are approximated. This will bring two serous

surfaces in contact, while the free edges of the wound, with the sutured mucous membrane, are in contact. The abdominal wound should then be closed in the usual manner.

Pyloroplasty.—(Plate CCCCXXVII) This operation is usually performed for the hypertrophic stenosis of infants and occasionally for pyloric obstruction in the adult. The incision is similar to that made in gastrostomy, except that it should be on the right side instead of the left. It may be made through the linea alba, the right semilunar line or the right rectus muscle. The peritoneum having been divided, the pylorus is sought and drawn into the wound as far as possible. This is not always easy on account of the bulk of the stomach, and because the duodenum is held in place by the peritoneum. The incision should be made into the tumor found at the pylorus, in the long axis of the stomach, extending into the stomach and into the duodenum; it should be about four centimeters (an inch and a half) in length. Great care must be taken not to open the duodenal or gastric mucosa. The duodenal wall is thin in comparison with that of the stomach so that the greater danger is on the duodenal side of the pyloric sphincter. As soon as the mucosa pouts into the wound the incision should stop. The tumor is then grasped between the thumbs and index fingers and "cracked", much as one divides an apple.

The wound in the abdominal parietes should be closed in the usual manner.

Pylorectomy.—The incision should be made through the right rectus muscle over the mass in the pylorus for the removal of which the operation is performed. After the mass has been explored and, if possible, all adhesions separated, it should then be drawn into the wound as far as possible and the portions of the greater and lesser omenta attached to the pyloric end of the stomach should be cut between two sets of ligatures. These omenta should be divided far enough beyond the malignant growth to allow the knife or cautery to pass through healthy tissue. The amount of stomach to be removed will vary with the type and extent of the lesion for which the operation is being performed. In the operations for pyloric cancer it is best to do a *partial* or *subtotal gastrectomy*. The procedure and anatomic considerations are the same whether the incision is through the pyloric antrum or through the body of the stomach. In operations for cancer as wide an excision of the omenta as possible should be done. The next step in the operation consists of applying the clamps on the stomach in an oblique direction. The stomach may then be divided between the clamps by the cautery. It does not make any material difference whether the clamps are applied first to the duodenum and this structure severed or to the stomach as above described. In the one instance the portion to be removed is turned downwards and in the other it is turned upwards. It is perhaps safer to work from the stom-

PLATE CCCCXXVII.

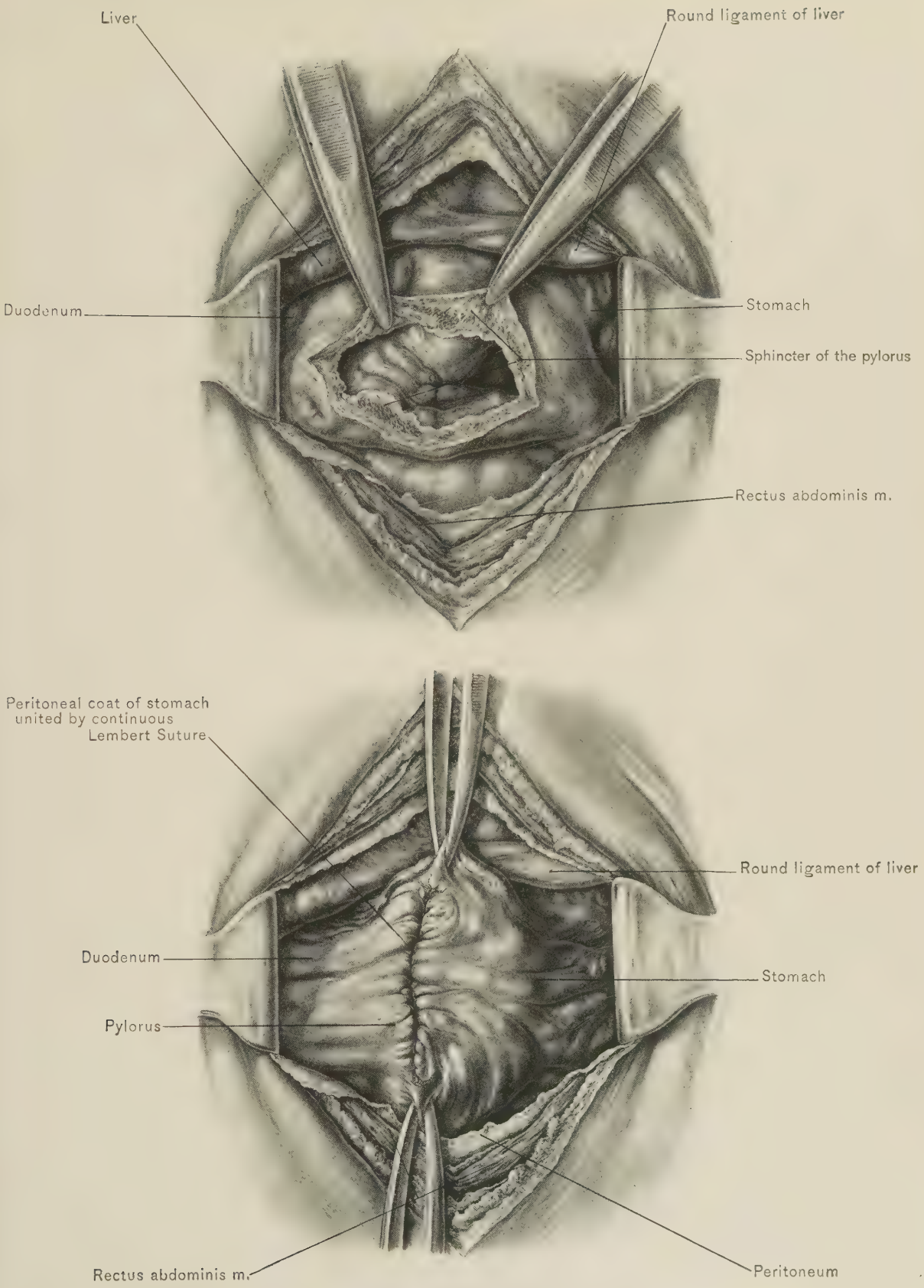

INCISION AND SUTURED WOUND IN PYLOROPLASTY.

ach toward the duodenum so that minimal trauma to the pancreas and the retro-duodenal vessels will result. It must be remembered that the superior pancreato-duodenal and right gastro-epiploic arteries are posterior to the duodenum and give rise to troublesome hemorrhage when injured.

It will be remembered that the common bile duct and the pancreatic duct enter the duodenum about ten centimeters (four inches) beyond the pylorus. Care must be exercised in the manipulation so as not to disturb these structures. The vessels divided during the resection will include the pyloric (*right gastric*), the right gastroepiploic, and often the gastro-duodenal arteries and some of their branches, together with their accompanying veins. The method by which the operation is to be concluded is a matter of choice. The Billroth II method in which the stomach is closed and a posterior gastro-enterostomy performed is a safe and sane procedure. The modern modification of the Billroth I has also many advocates. The Polyá method whereby the jejunum is brought to the open end of the stomach and a gastro-jejunostomy is performed either by the anterior or posterior method gives excellent results. Since this book is primarily a surgical anatomy I do not feel that the addition of the many methods is advisable or desirable. As far as possible the anatomic features have been discussed in the foregoing pages.

Gastro-enterostomy.—The abdominal walls should be incised in the same manner as described under pylorectomy. The same structures will be divided. The greater omentum should then be pushed to the left, and a loop of the jejunum, as near to the duodenal-jejunal flexure as practicable, should be brought into the wound. Then lift the transverse colon out of the wound by pulling upwards and to the right. This exposes the upper jejunum. The duodenal-jejunal flexure lies about four to five centimeters (one and a half to two inches) above the umbilicus and to the left of the vertebral column. Pick up a loop of jejunum about seven and a half centimeters (three inches) from the flexure and mark it. An opening is then made in the transverse mesocolon to the left of the middle colic artery and inferior to its left branch which curves toward the splenic flexure to meet branches of the left colic artery. Care must be taken not to injure the middle colic artery. After the opening is made the stomach is pushed from above so as to prolapse through it, and the clamps are applied. To avoid kinking, the anastomosis should be made as closely as possible along the natural line of relationship between the stomach and jejunum, that is, from above downwards and to the left along the posterior gastric wall. It is important to use a short loop of jejunum, so that a sagging loop of bowel above the anastomosis does not result. Such a sag will cause angulation of the anastomosis and "vicious circle." An incision should be made into the walls of each, the serous

and muscular layers being divided, and the submucous and mucous layers being allowed to remain intact for the present. The posterior part of the incised portions should then be approximated by a Lembert suture. The submucous and mucous layers may be divided with a pair of scissors, and the anastomosis completed with Czerny or Connell sutures. The anastomosis should then be reinforced by a row of Lembert sutures, these sutures also approximating the gut and the stomach for about three to five centimeters (one to two inches) beyond the anastomosis, in order to prevent angulation of the gut. The stomach is then fixed to the rent in the mesocolon by interrupted sutures.

Severe bleeding from branches of the coronary (*left gastric*), pyloric (*right gastric*), right gastro-epiploic, and left gastro-epiploic arteries may occur from the incised stomach.

The **kidneys** (Plate CCCCLXXVIII) lie on the upper part of the posterior abdominal wall of the abdomen behind the peritoneum. They are enveloped and supported by a layer of connective tissue which is derived from the parietal portion of extraperitoneal areolar tissue. This connective tissue, known as the *renal fascia*, encloses the kidney and the suprarenal gland. In some cases the fat (*perinephric fat*) in this enveloping membrane is very abundant; in others the fat is so scanty in quantity that the connective tissue forms a thin, translucent covering which might readily be mistaken for peritoneum or transversalis fascia. It is through lessened intra-abdominal pressure, from poorly developed anterior abdominal muscles, and the laxity of this fat-bearing connective tissue that the kidney is sometimes allowed to move from its normal position; it is then called a movable, floating, or wandering kidney. As this fat is poorly supplied with blood, it is frequently affected by abscess. This is a perinephric abscess, which follows injuries, disease of the kidney, of the spine, of the vermiform appendix, or of some adjacent structure. The pus may follow the extraperitoneal fat downward to the iliac fossa and the pelvis, or it may empty into the large bowel or the bladder, and may ulcerate through the lumbar fascia and appear at Grynfelt's and Lesshaft's (*lumbar*) triangle.

The kidney is reddish-brown in color. It is shaped very much like a lima bean and is normally smooth on its surface. Each kidney is about eleven and a half centimeters (four and a half inches) long, six centimeters (two and a half inches) broad and about three and a half centimeters (one and a half inches) thick. The average weight is about one hundred and thirty grams (four and a half ounces). The kidney of the new-born infant and the child is relatively much larger than that of the adult.

Position.—The right kidney is situated from one to two centimeters lower than the left one on account of the size of the liver on the right side. Conse-

PLATE CCCCXXVIII.

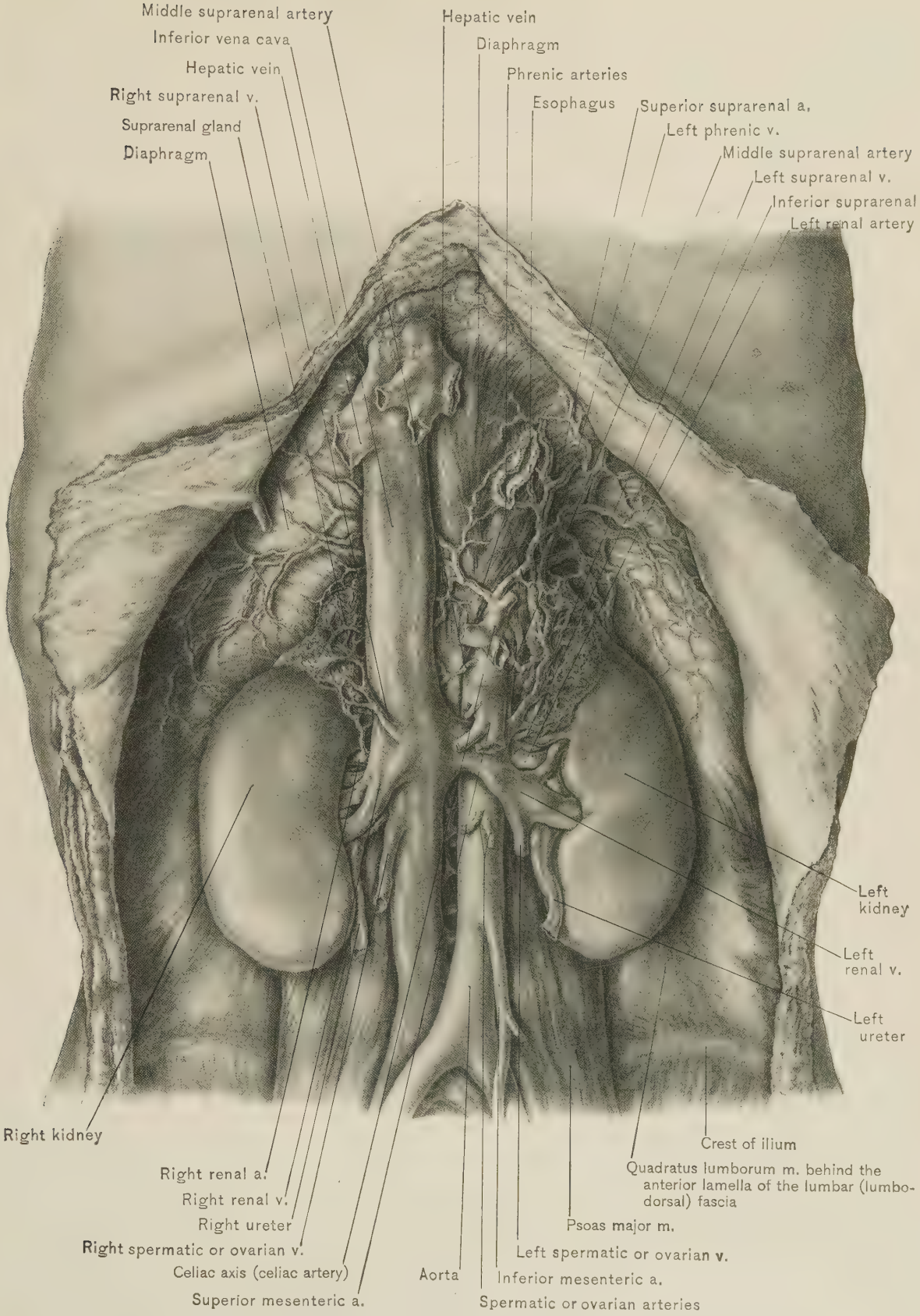

ABDOMINAL AORTA, INFERIOR VENA CAVA, KIDNEYS, AND URETERS IN SITU.

PLATE CCCCXXIX.

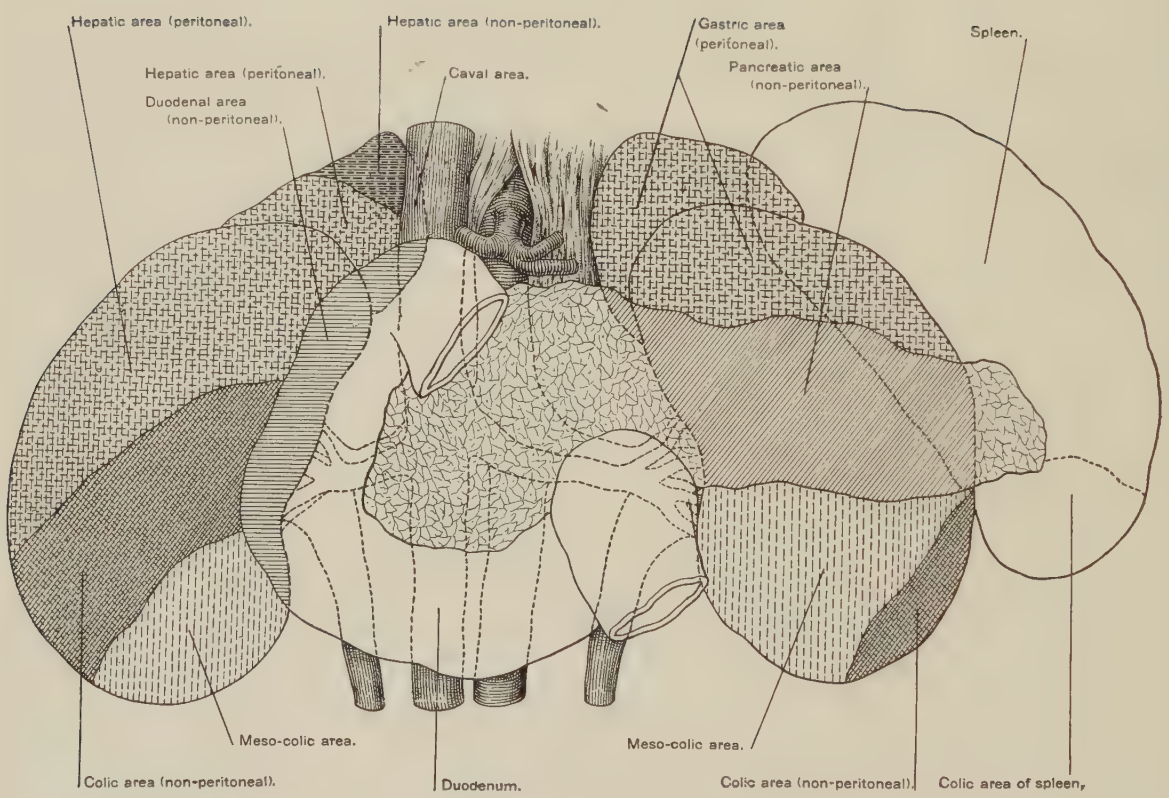

DIAGRAM OF KIDNEY, RENAL VESSELS, AND URETER.

quently the left kidney extends as high as the upper border of the eleventh rib, while the right reaches only to the level of the lower border of that rib or at times only to the upper border of the last rib. The kidneys are situated one on each side of the great vessels and the spinal column, opposite the bodies of the last thoracic and upper two or three lumbar vertebræ. On the surface their vertical limits are marked by the upper borders of the tips of the spines of the last thoracic and third lumbar vertebræ, and they extend laterally about nine to ten centimeters (three and one-half to four inches) from the spinous processes of these vertebræ. The upper end is nearer the median plane than the lower end. The subcostal plane passes through the lower end of the right kidney and just misses the left. The hilum of the right kidney is five centimeters (two inches), and the lateral border ten centimeters (four inches) from the median plane, while the hilum and the lateral border of the left kidney are slightly closer to the median plane. The transpyloric plane passes through both kidneys above the middle of the hilum.

As the kidneys are at the side of the lumbar spine, which is freely movable, it is possible for these organs to be squeezed between the ribs and the ilium during extreme forcible flexion of this portion of the vertebral column. This may produce hematuria.

In some instances the kidney can be palpated at the lateral border of the erector spinæ muscle, just below the last rib.

Dissection.—The kidneys should now be removed from the abdominal cavity by severing the renal and suprarenal vessels, the ureter, and the attachments of the connective-tissue membrane which holds the organ in place. This enveloping tissue should then be removed from the kidney, care being taken to leave the suprarenal gland upon the kidney.

The shape of the kidney is so well known and is so characteristic that the term "kidney shape" is commonly used in descriptive language (Cunningham).

It is surrounded by a dense fibrous covering, the **capsule.** In the healthy organ this capsule can easily be stripped from the glandular substance of the kidney, but in some pathologic conditions the capsule becomes so adherent that it is impossible to remove it without tearing away some of the glandular tissue. The capsule enters the hilum and lines the sinus of the kidney; here it is continuous with the sheaths of the renal vessels and with the external coat of the ureter.

Each kidney has an anterior and a posterior surface, an upper and a lower end, or pole, and a lateral and a medial margin.

The **anterior surface** (Plate CCCCXXIX) is directed forward and lateralward. This surface of the right kidney is related, from above downward, with the renal impression of the liver, the colon, and the peritoneum; along its medial margin it

is overlapped by the descending duodenum. The hepatic area of this surface is covered by peritoneum, but the colic and duodenal areas are non-peritoneal. In front of the left kidney are, in the same order, the stomach, the splenic vessels, the tail of the pancreas, the peritoneum, and the colon.

The **posterior surface** is directed backward and medialward toward the spinal column. The upper third of this surface rests against the diaphragm, the lower two-thirds against the fascia covering the psoas major muscle and upon the anterior lamella of the lumbar fascia, which covers the quadratus lumborum muscle. The anterior branch of the last thoracic, the ilio-hypogastric, and the ilio-inguinal nerve, pass lateralward behind the lower half of the kidney.

The **ends, or poles,** are rounded; the upper pole is thicker and broader than the lower one, and is surmounted by the suprarenal gland.

The **lateral margin** is convex from above downward and free. In the left kidney the upper portion of this margin is in contact with the renal or medial surface of the spleen, while in the right kidney it is in relation with the right lobe of the liver. The **medial margin** is concave and attached to the nerves and vessels of the kidney. These structures enter this margin through a fissure, or slit, called the **hilum,** which opens into a chamber called the **sinus of the kidney.** (Plate CCCCXXX.) The vessels which pass through the hilum and lie in the sinus are, from before backward: branches of the renal vein, branches of the renal artery, other branches of the renal vein, and the ureter. The upper part of the medial margin of the right kidney is quite near the inferior vena cava, but the lower portion of this margin is some distance from it. The medial margin of the left kidney is two to three centimeters (three-quarters to one and one-fourth inches) distant from the aorta.

The right and the left kidney may readily be distinguished by the relation of the vessels at the hilum, the ureter being behind the other vessels and bent downward; the upper pole of the kidney is larger than its lower pole.

Structure of the Kidney (Plate CCCCXXXI).—If the kidney is divided longitudinally through its convex margin to the hilum, it is found to consist of two parts, distinctly visible to the naked eye: an outer cortical layer and an internal medullary layer.

The **outer layer,** or **cortex,** forms the surface of the kidney. It is about six millimeters (one-fourth of an inch) in thickness, and sends processes inward between the Malpighian (*renal*) pyramids of the medulla. These processes are called the **columns of Bertini,** and carry the blood-vessels from the sinus of the kidney to the line between the cortex and the medulla. The cortex contains the more important secreting structures of the organ, while the medulla is composed of conducting tubules. In the cortex are found the **Malpighian bodies** (**renal**

PLATE CCCCXXX.

TYPES OF SINUSES OF KIDNEY.

PLATE CCCCXXXI.

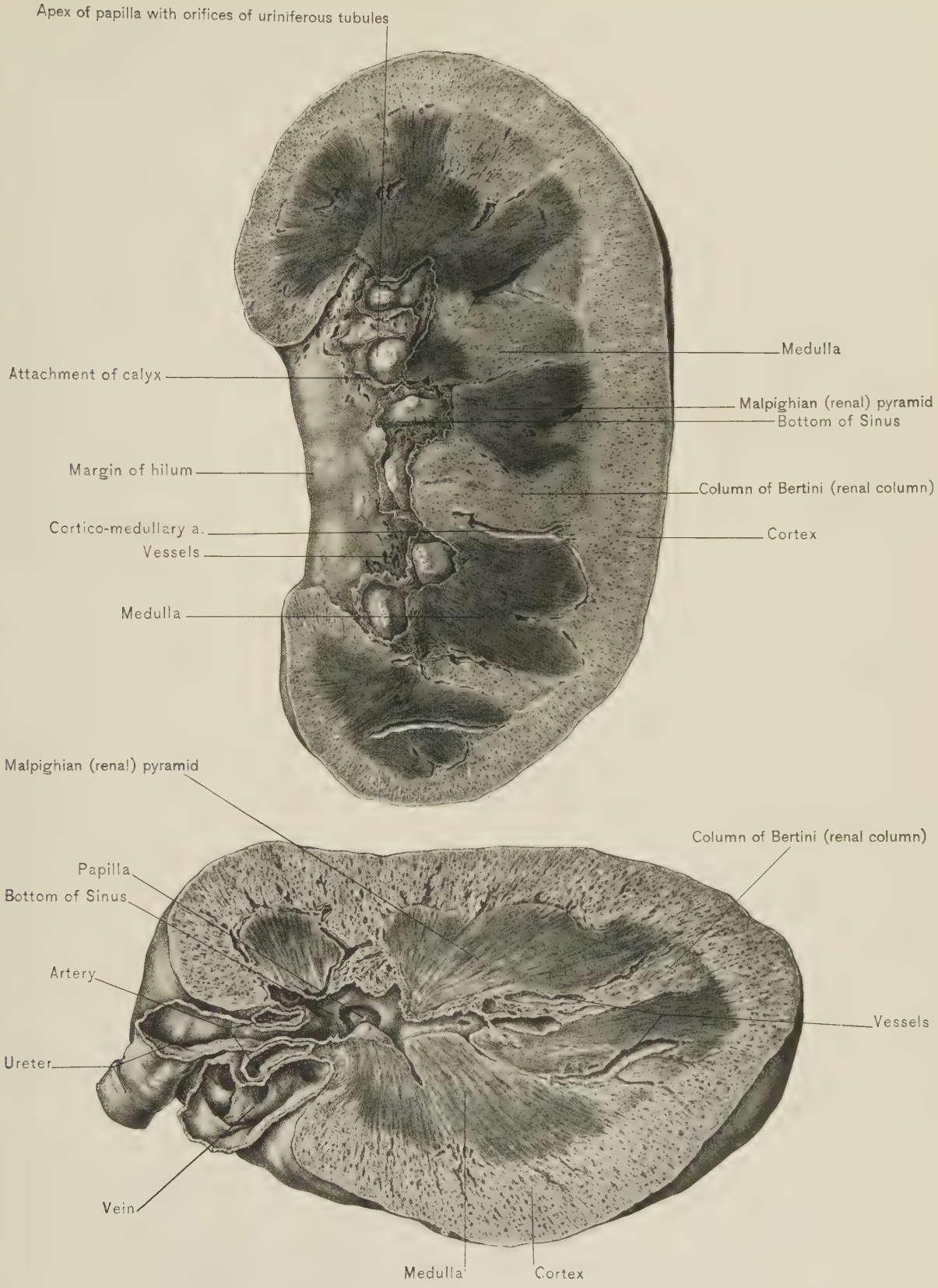

SECTIONS OF KIDNEY.

PLATE CCCCXXXII.

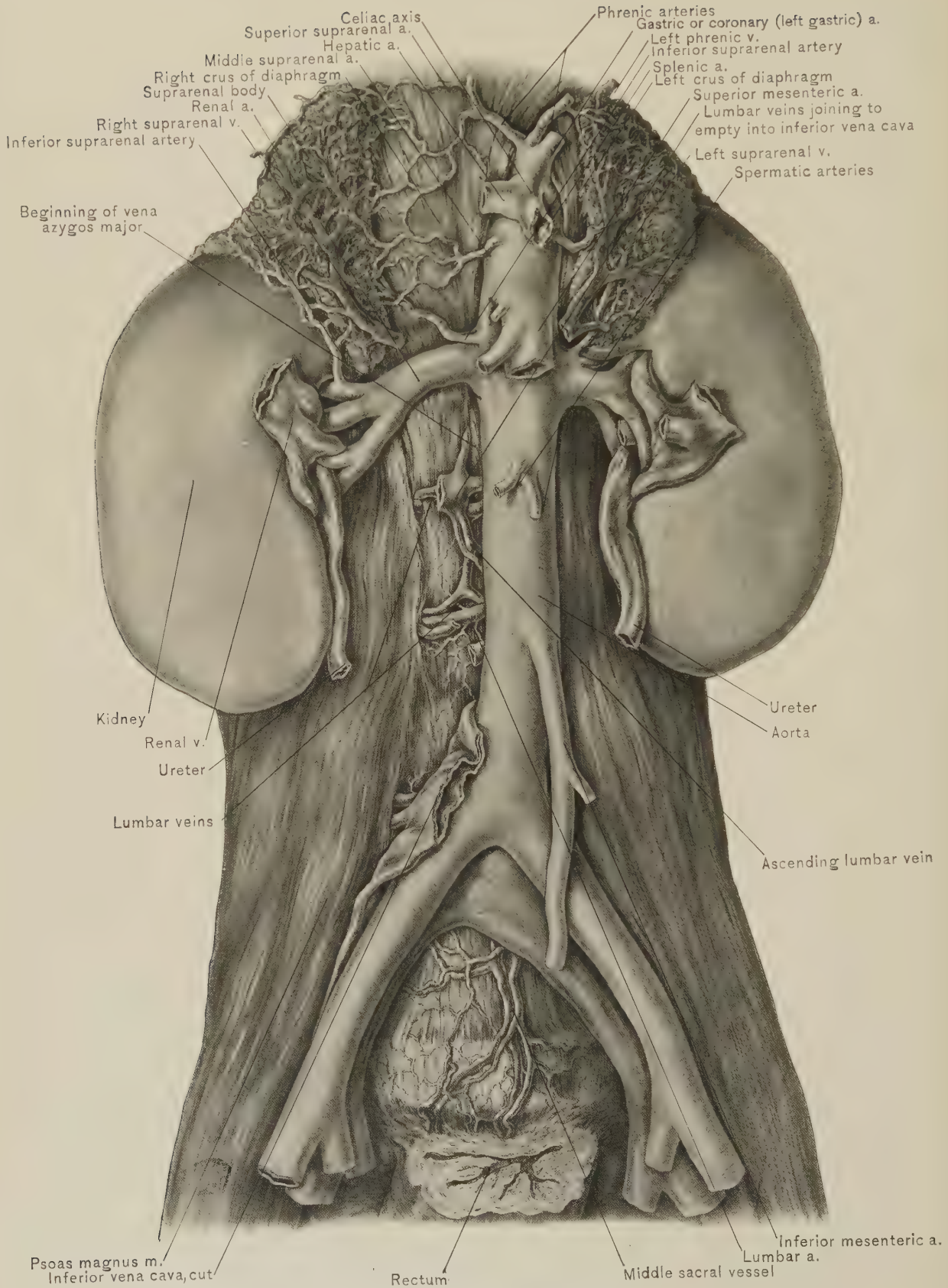

KIDNEY, RENAL VESSELS, AND URETERS.

corpuscles); these are composed of a tuft of vessels, surrounded by the **capsule of Bowman** (**capsula glomeruli**), which is the sac-like commencement of the uriniferous tubules.

The **pyramidal,** or **medullary, substance,** denser in structure than the cortex, is formed by the converging straight conducting tubes which carry the urine from the cortical substance to the central cavity or sinus of the organ. The pyramids are finely striated. The apices of the **medullary** (**renal**) **pyramids,** or **Malpighian pyramids,** project into the sinus of the kidney as small mammillary eminences called the **renal papillæ.** These are embraced by a process of the ureter called the **calyx,** and are marked by numerous small openings of the uriniferous tubules, the **foramina papillariæ,** from which urine is readily expressed by slight compression. There are generally about a dozen papillæ, but they may vary in number from eight to twenty.

Blood Supply.—The blood supply of the kidney is derived from the renal artery, which divides into four or five branches that enter the hilum and then subdivide for distribution to the substance of the organ. Sometimes one or more of these primary branches enter the kidney through its cortical substance, perforating the capsule. The artery is very large in proportion to the organ it supplies. The **renal veins** form arches at the bases of the medullary pyramids, whence they accompany the arteries to the sinus of the kidney, uniting external to the hilum to form the renal vein, which empties into the inferior vena cava.

Nerve Supply.—The nerve supply of the kidney is derived from the solar (*celiac*) and the aortic plexuses and lesser splanchnic nerves; branches accompany the arteries into the substance of the organ, some filaments also going to the spermatic plexus and the ureter.

The **lymphatics** consist of a superficial set, which ramifies over the surface of the organ, and a deep set, accompanying the blood-vessels in the interior of the kidney; they all terminate in the lumbar glands.

The **ureter** (Plate CCCCXXXII) is the excretory duct of the kidney. It is about twenty-five centimeters (ten inches) long. For twelve and a half centimeters (five inches) it is in the abdomen proper and for twelve and a half centimeters (five inches) it is in the pelvis. The upper, expanded, and funnel-shaped portion of the ureter begins in the renal sinus and is known as the pelvis. The **pelvis of the ureter** divides into the sinus of the kidney into three branches, *infundibula*, and these again subdivide into the *calices* which embrace the real papillæ. The ureter proper has the diameter of a goose quill. It bends downward and medialward from the apex of the pelvis, and continues in this direction, lying in the extraperitoneal fat. It rests upon the psoas major muscle as far as the brim of the pelvis, where it passes over the external iliac artery

near the bifurcation of the common iliac artery, and enters the pelvis to reach the base of the bladder. The right ureter lies close to the lateral side of the inferior vena cava, and is covered by the ileum as it enters the pelvis. The left ureter is covered by the sigmoid flexure (*iliac and pelvic colon*) at its lower abdominal portion. Both ureters are crossed obliquely in front by the spermatic vessels.

The ureters have three coats: fibrous, muscular, and mucous. The **fibrous coat** is continuous above with the true capsule of the kidney, and below with the wall of the bladder. The **muscular coat** is composed of an external, or circular, and an internal, or longitudinal, layer. In its lower portion there is an additional thin external longitudinal layer of muscle fibers. The **mucous membrane** presents longitudinal folds and is lined with transitional epithelium. The ureter may be greatly distended by a stone; rupture of the ureter causes urine to collect in the subperitoneal fat and leads to the formation of an abscess.

Blood Supply.—The blood supply of the ureters is derived from the renal, spermatic, internal iliac (*hypogastric*), and vesical arteries. The **veins** empty into corresponding trunks.

Nerve Supply.—The nerve supply of the ureters is derived from the renal, the spermatic, and the hypogastric plexuses of nerves.

The lymphatics end in the nearest glands in the abdomen and pelvis.

When a renal calculus passes down a ureter, it gives rise to pain in the course of the duct and in the testicle, referred by the spermatic and renal plexuses of nerves, and in the thigh through branches of the lumbar plexus. These plexuses have a central connection with the spinal cord. The nerves to the testicle come from the tenth thoracic segments, while those to the epididymis come from the eleventh and twelfth thoracic and the first lumbar segments.

Obstruction of a ureter dams the urine in the pelvis of the ureter and produces back pressure on the kidney, producing *hydronephrosis*, or distention of the kidney with urine. If an infection coexists pyonephrosis may result.

A **movable kidney** is one which is so loosely attached that it shifts its position back of the peritoneum. In some cases the fatty capsule is so large and so loosely connected with the kidney that the organ has room for movement within the capsule. In others the tissue surrounding the kidney is scant and is so loosely attached to the peritoneum and posterior abdominal wall that the whole mass is free to move. The extent of the movement in this instance is limited by the attachment of the vessels. A **floating kidney,** on the other hand, is one which has a complete peritoneal investment, with a mesentery or mesonephron sufficiently long to permit its free movement about the abdomen. A movable kidney often produces discomfort and may be very painful, sometimes being so distressing as to necessitate an operation for anchoring it in its normal position—*neph-*

rorrhaphy. In anchoring a floating kidney, it must be remembered that the vessels may be shortened on account of the congenital position of the kidney, and that much traction upon them, especially upon the vein, may interfere with the circulation and cause the kidney to undergo serious change. Movable kidney occurs more frequently in women, and more commonly upon the right side.

Before any operation is contemplated in these cases careful study is indicated. The movable or floating kidney may cause angulation of the hepatic (*right colic*) flexure of the colon or drag of the duodenum. In these cases operation is indicated. Frequently nephroptosis is only a part of a general abdominal visceroptosis and in these cases operation as a rule is not indicated.

Nephrectomy.—The kidney may be removed by an incision through the lumbar region, or by one through the linea semilunaris, or through the rectus muscle. In the lumbar operation the incision is made between the last rib and the crest of the ilium. There are numerous modifications of this incision. The tissues divided are the skin, the superficial and deep fasciæ, the anterior fibers of the latissimus dorsi muscle, the posterior part of the external and internal oblique and transversalis muscles, and the transversalis and lumbar (*lumbo-dorsal*) fasciæ. The anterior branch of the last thoracic nerve may be found lying in the wound anterior to the lumbar (*lumbo-dorsal*) fascia. This should be pushed aside and not cut, if it can be avoided. After dividing the lumbar fascia, the perirenal fat usually bulges into the wound. This should be torn and the lateral margin of the kidney sought for. If the perirenal fat is abundant, some of it should be ligated and removed, as its blood supply is so poor that it may subsequently cause trouble by breaking down. The kidney should be freed from its surrounding perirenal fat in order to reach the vessels and duct. The position of the structures at the hilus are vein, artery, ureter, from anterior to posterior and from above downward. The ureter should be isolated and tied separately and the vessels then ligated. The pedicle may then be severed with a pair of scissors, and the kidney removed. Care must be taken that too much traction is not made on the kidney, as there is danger of tearing the vessels, especially the vein. It must also be remembered that the vein on the right side is very short, and that there is danger of tying a part of the inferior vena cava in the ligature. By prolonging the incision downward, the ureter may be explored, and, if necessary, removed extraperitoneally.

The same exposure should be used for the removal of a stone from the renal pelvis or the upper portion of the ureter. In these cases it is important to bear in mind the relation of the ureter and pelvis to the renal vessels. Occasionally there is a vein posterior to the pelvis and this should be mobilized and retracted if present.

In the intra-abdominal operation the incision is made on a level with the umbilicus, in the line of the linea semilunaris, or, preferably, to the medial side of the linea semilunaris, the fibers of the rectus muscle being separated. The structures divided at the linea semilunaris are the skin and superficial fascia, the aponeuroses at the lateral edge of the rectus muscle, the transversalis fascia, preperitoneal fat, and peritoneum. To the medial side of the linea semilunaris the skin, superficial fascia, anterior wall of the rectus sheath, rectus muscle, posterior wall of the rectus sheath, transversalis fascia, perperitoneal fat, and peritoneum are divided. The intestine should then be held to one side, and the colon with its mesocolon be brought into view. The lateral layer of the mesocolon should then be incised. The tissue around the kidney should be broken through, the pedicle ligated as in the lumbar operation, and the kidney removed. It is advisable not to open the capsule of the kidney, as the danger of septic infection would be greatly increased if this were done. The incision is made through the lateral layer of the mesocolon because it contains but few vessels, whereas the large vessels to the colon pass behind the medial layer.

The kidney may also be removed through the linea alba, but this is not so safe a method as that of removing it through the linea semilunaris, because in the median line one is further away from the kidney, a greater expanse of peritoneum is exposed, and it is necessary to cut through the internal layer of the mesocolon to reach the kidney. Jacobson has reported a case in which he made an incision from the anterior superior spine of the ilium to the eighth rib, through the abdominal walls, and then stripped the peritoneum from the walls of the iliac fossa, reaching the kidney by going postperitoneally. A similar incision has recently been suggested by Lipshutz.

The other operations performed upon the kidney are nephrotomy and nephrolithotomy. These are done preferably through the loin incision, and are, therefore, extraperitoneal operations.

The **suprarenal glands,** or **capsules,** are ductless glands weighing from thirty to sixty grams (one to two drams), lying close upon the medial portion of the upper poles of the kidney. They are yellowish in color and are sometimes overlooked by the inexperienced or the careless surgeon who is apt to mistake them for parts of the adjacent extra peritoneal fat. The right gland is pyramidal and the left semilunar in shape. The right suprarenal gland is covered anteriorly by the posterior surface of the liver, peritoneum, and the duodenum, and the left by peritoneum, the stomach, the pancreas, and the splenic vessels. Behind, each rests upon its respective crus of the diaphragm, opposite the tenth intercostal space or eleventh rib. Medially they are in relation with the greater splanchnic nerve and the semilunar (*celiac*) ganglion, the right resting against

the inferior vena cava and the left against the aorta. The left suprarenal gland is in relation, laterally, with the renal surface of the spleen.

On section, the suprarenal gland is seen to consist of a yellow cortical and a dark-brown medullary substance, the latter sometimes being broken down and leaving a narrow cavity. The medulla of the suprarenal glands belongs to the chromaffin or chromaphil system. This system is developed in association with the sympathetic system and is closely connected with it, anatomically and physiologically.

Blood Supply.—The blood supply of the suprarenal glands is derived from the suprarenal arteries and from branches of the **inferior phrenic and renal arteries.** These branches subdivide into many minute vessels before entering the organ. Its **vein,** the **suprarenal,** is formed from the **medullary venous plexus** and branches from the cortical substance; the right vein enters the inferior vena cava, and the left, the renal vein. Its **lymphatics** enter the lumbar glands and partly the glands of the posterior mediastinum.

Nerve Supply.—The nerve supply of the suprarenal gland is very liberal, and is derived from branches of the solar (*celiac*) and renal plexuses and from the phrenic and vagus nerves. The vessels and nerves enter through a deep fissure called the hilum.

The **abdominal aorta** (Plate CCCCXXVIII) is the continuation of the thoracic aorta, and is about twelve centimeters (five inches) long. It begins at the aortic opening in the diaphragm, opposite the lower border of the body of the twelfth thoracic vertebra. It extends downward upon the left side of the front of the bodies of the lumbar vertebræ to the middle of the body of the fourth lumbar vertebra, opposite which it divides into the right and left common iliac arteries. This point is about two centimeters (three-fourths of an inch) below the level and to the left of the umbilicus, and is located in a line drawn between the highest points of the iliac crests just above and to the left of the umbilicus, and can readily be felt pulsating. It is easily compressed through thin abdominal walls where it rests upon the third lumbar vertebra, which is the most anterior portion of the lumbar curve of the spinal column. The aorta gives off large branches and thus tapers off rapidly as it descends.

Relations.—It is related, behind, with the four upper lumbar vertebræ and the intervertebral discs, from which it is separated by the anterior common (*anterior longitudinal*) ligament, the left lumbar veins, the lower end of the thoracic duct, the receptaculum chyli (*cisterna chyli*), and the origin of the left crus of the diaphragm. In front of it are the liver, the lesser omentum, the stomach, the posterior parietal peritoneum, the pancreas, the transverse duodenum, the celiac axis (*celiac artery*) and its branches, the solar (*celiac*) plexus,

the aortic plexus, the splenic vein, the left renal vein, and the mesentery. On its right side are: the right crus of the diaphragm, the vena azygos major (*vena azygos*), the thoracic duct, the right semilunar (*celiac*) ganglion, the right greater splanchnic nerve, and the inferior vena cava. On its left side are: the left greater splanchnic nerve, the left semilunar (*celiac*) ganglion, the left crus of the diaphragm, the psoas major muscle, the tail of the pancreas, and the left kidney.

The **branches of the abdominal aorta** are: the inferior phrenic arteries, the celiac axis (*celiac artery*), the superior mesenteric, the suprarenal, the renal, the spermatic or ovarian, the inferior mesenteric, the lumbar, and the middle sacral arteries. Its terminal branches are the right and left common iliac arteries.

The **phrenic arteries,** or **inferior phrenic arteries,** in contradistinction to the phrenic branches of the internal mammary artery are two slender vessels which arise very irregularly from the abdominal aorta, either above or below the celiac axis (*celiac artery*), or direct from the latter or its branches. Arising separately or by a common trunk, they pass upward and laterally and diverge over the crura of the diaphragm. The left passes behind the esophagus and forward along the left side of the esophageal opening, and the right over the back of the liver and the inferior vena cava and to the right side of the caval opening. Each divides into a medial and a lateral branch. The *medial branch* passes forward to supply the diaphragm and anastomoses with the phrenic artery of the opposite side and with the musculo-phrenic artery. The *lateral branch* runs to the side of the chest, where it anastomoses with the intercostal arteries. The medial branch of the right also supplies the inferior vena cava, the liver, and the right suprarenal gland, while that of the left also sends twigs to the left suprarenal gland and the spleen.

The **celiac axis,** or **celiac artery,** is a short, thick trunk which arises from the front of the first centimeter (half inch) of the abdominal aorta immediately below the aortic opening in the diaphragm. It runs forward across the lower border of the Spigelian (*caudate*) lobe of the liver, and the upper border of the pancreas. It is about two and one-half centimeters (one inch) in length, and divides into the left gastric, hepatic, and splenic arteries. It lies behind the lesser omentum and the ascending layer of the posterior parietal peritoneum. Upon its right side are the right semilunar (*celiac*) ganglion and the Spigelian (*caudate*) lobe, and upon its left side are the left semilunar (*celiac*) ganglion and the cardiac end of the stomach. Above it are the diaphragm, the median lumbo-costal arch (*median arcuate ligament*), and the origins of the inferior phrenic arteries. Below it is the pancreas. The lesser sac (*omental bursa*) separates it from the lesser omentum in front.

The **left gastric, or coronary, artery,** the smallest branch of the celiac axis (*celiac artery*), passes upward and to the left on the left crus behind the ascending

layer of the posterior parietal peritoneum, to the cardiac end of the lesser curvature of the stomach. Here it gives off: *esophageal branches* which pass upward through the hiatus esophagus to anastomose with esophageal branches from the thoracic aorta, a *hepatic branch* which passes upward and to the right between the layers of the lesser omentum to reach the liver, and *cardiac branches* to the cardiac end of the stomach, which join branches of the splenic artery. It then turns downward and to the left along the lesser curvature of the stomach between the layers of the lesser (*gastro-hepatic*) omentum, supplying gastric branches to both surfaces of the stomach. This portion of the vessel, often called the coronary artery, anastomoses with the pyloric branch (*right gastric*) of the hepatic artery on the lesser curvature of the stomach.

The **hepatic artery,** intermediate in size between the left gastric and splenic arteries, extends upward and to the right along and above the head of the pancreas, where it gives off *pancreatic branches* which supply the pancreas. It then passes between the two layers of the gastro-hepatic omentum to the first portion of the duodenum. In this omentum it gives off the small *pyloric branch* (*right gastric*) opposite the pylorus, to join the left gastric, the *gastro-duodenal branch*, which passes posterior to the duodenum and supplies the stomach, duodenum, and pancreas. It then passes upward in front of the foramen of Winslow (*foramen epiploicum*) between the layers of the lesser (*gastro-hepatic*) omentum, near its free border, to the left of the common duct and anterior to the portal vein to the transverse fissure (*porta hepatis*) where it divides into the right and left hepatic arteries. The right hepatic artery gives off the **cystic artery** just above the point where the cystic duct enters the common duct. As a rule this passes behind the common duct, but occasionally it passes anterior to it. The *gastro-duodenal* artery passes downward behind the first portion of the duodenum to the lower border of the stomach, where it gives off a few *inferior pyloric arteries*, and divided into the right gastro-epiploic and the superior pancreatico-duodenal.

The **right gastro-epiploic artery** passes from right to left along the greater curvature of the stomach, between the anterior layers of the greater omentum, sending branches to both walls of the stomach and to the greater omentum. It anastomoses with the left gastro-epiploic artery, a branch of the splenic.

The **superior pancreatico-duodenal artery** passes downward between the adjacent surfaces of the duodenum and the head of the pancreas to supply them, and to anastomose with the inferior pancreatico-duodenal branch of the superior mesenteric artery.

The **splenic artery** is the largest division of the celiac axis (*celiac artery*), and is remarkably tortuous. It passes from right to left behind the stomach, and the lesser cavity (*omental bursa*) of the peritoneum and along the upper margin of the

pancreas in company with and above the splenic vein, giving off descending small pancreatic branches*æ*, *pancreatic parvæ*, to the substance of this gland. The largest one of these, the *pancreatica magna*, near its left end, accompanies the pancreatic duct from left to right. It passes upon the left crus of the diaphragm, the suprarenal gland, and the left kidney, behind the omental bursa and stomach to the spleen, where it divides into five or more branches. Near its termination the splenic artery gives off the left gastro-epiploic artery.

The **left gastro-epiploic artery** first descends between the two layers of the gastro-splenic omentum, and then passes along the greater curvature of the stomach from left to right, between the two layers of the greater omentum, to join the right gastro-epiploic artery. On its way it distributes gastric and omental branches. Beyond the left gastro-epiploic artery, the splenic artery or its terminal branches give off about five or six short gastric branches, *vasa brevia*, which pass between the layers of the gastro-splenic omentum to the stomach to supply the cardiac end of that organ. It then breaks up into the several branches which enter the spleen at its hilum.

The **superior mesenteric artery** arises from the anterior surface of the abdominal aorta below the celiac axis (*celiac artery*). At first it lies behind the pancreas. It passes between the latter and the transverse portion of the duodenum; then downward across that part of the duodenum, and enters the mesentery. It finally runs between the two layers of the mesentery at its root, and terminates in the right iliac fossa by anastomosing with its own ileo-colic branch. From its convex side it gives off from twelve to fifteen *vasa intestini tenuis* (*intestinal arteries*), which supply the jejunum and ileum. From its concave side the first branch is the slender *inferior pancreatico-duodenal artery*, which passes between the pancreas and the transverse part of the duodenum, to anastomose with the superior pancreatico-duodenal artery. The other branches of the superior mesenteric artery arise from its concave side, and are the *middle colic*, *right colic*, and the *ileocolic*. These arteries are described at p. 427.

The **suprarenal arteries,** sometimes called the **middle suprarenal arteries** to distinguish them from the suprarenal branches of the phrenic and of the renal arteries, arise from the sides of the aorta at about the level of the superior mesenteric artery, and pass upward and lateralward to the suprarenal glands. The pancreas is anterior to both arteries, and the inferior vena cava is also in front of the right artery. The **superior suprarenal arteries** are branches of the phrenic arteries, and the **inferior suprarenal arteries** are derived from the renal arteries.

The **renal arteries** arise from the sides of the aorta at a right angle, below the superior mesenteric artery, opposite the upper border of the second lumbar vertebra. The right renal artery is longer that the left, because of the location

of the aorta to the left of the median line, and is lower than the left, because of the lower position of the right kidney. These vessels subdivide into several branches before entering the hilum of the kidney, the vein being in front of them and the ureter behind them. The right renal artery is crossed in front by the inferior vena cava. Supernumerary renal arteries, ofgentimes of considerable size are quite frequent, a fact which must be borne in mind in the operation of nephrectomy.

The **spermatic** (**internal spermatic**) or **ovarian arteries** are two long slender vessels which arise from the front of the aorta a short distance below the renals, and pass downward and slightly laterward obliquely across the psoas major muscle and the ureter to the external iliac artery. From this point in the *male*, the spermatic artery continues through the internal abdominal (*abdominal inguinal*) ring and the inguinal canal as a constituent of the spermatic cord for final distribution to the testicle. In the *female* the ovarian artery, which is the homologue of the spermatic artery, passes between the two layers of the broad ligament to supply the ovary. The terminal portion of this artery are more fully described with the pelvis. The right spermatic artery crosses the inferior vena cava obliquely, and the left runs beneath the sigmoid flexure (*iliac and pelvic colon*).

The **branches of the spermatic artery** are: the *ureteral*, running to the ureter; the *cremasteric*, small branches which supply the cremaster muscle; the *epididymal*, to the epididymis, and the *testicular*, or terminal, branches. The **branches of the ovarian artery** are the *ureteral*, the *Fallopian*, or *tubal*, the *uterine*, and the *ligamentous;* they are described with the pelvis.

The **inferior mesenteric artery** arises from the left side of the front of the aorta, posterior to the duodenum and about four centimeters (one and a half inches) above the bifurcation of the aorta. It is smaller than the superior mesenteric artery. It descends toward the left iliac fossa, posterior to the peritoneum, but in front of the aorta and sympathetic trunk giving off the left colic and the *sigmoid* arteries, after which it continues into the pelvis across the left common iliac artery to the lower end of the sigmoid flexure (*pelvic colon*) as the **superior hemorrhoidal artery,** which is described in the consideration of the pelvic viscera. Its vein is a little to the left of it.

The **lumbar arteries,** four on each side, are arranged like the intercostals. They pass lateralward from the posterior surface of the aorta almost at right angles, and then go backward and lateralward around the sides of the bodies of the respective vertebræ. They are covered by the psoas major muscle and the sympathetic trunk, from which they are separated by tendinous arches. They are also deep to the lumbar plexus. The upper two are covered by the crura of

the diaphragm, and those on the right side by the inferior vena cava also. Between the transverse processes of the vertebræ each lumbar artery divides into a dorsal and an abdominal branch. The *dorsal branch* gives off a spinal branch to the interior of the spinal canal, and continues backward to supply the muscles and skin of the lumbar region. It anastomoses with the posterior branches of the adjacent lumbar and intercostal arteries. The spinal branches of the dorsal branches enter the spinal canal upon the lumbar nerves, through the intervertebral foramina. Each divides into an upper and a lower branch, each division joining similar adjoining branches above and below, thus forming lateral arches upon the back of the bodies of the vertebræ. Twigs from these arches join the anterior spinal artery. All these supply the adjacent bone and contents of the spinal canal. The *abdominal branches* of the lumbar arteries run lateralward behind the quadratus lumborum muscle, and thence forward between the abdominal muscles to supply the abdominal wall; the lowest branch sometimes passes in front of the quadratus lumborum. These arteries anastomose in front with the epigastric and internal mammary arteries; above, with the intercostals and below, with the ilio-lumbar and the circumflex iliac arteries.

The **middle sacral artery** arises from the posterior surface of the aorta at its point of, or one centimeter (half an inch) above its bifurcation, and descends over the anterior aspect of the bodies of the last two lumbar vertebræ, over the sacral promontory, and down the middle of the sacrum to the base of the coccyx, where it inosculates with the lateral sacral arteries. It continues as a small twig down the coccyx to the coccygeal body (*glomus coccygeum*) which will be referred to again in the description of the pelvis.

Aneurysm of the abdominal aorta occurs most frequently in the region of the celiac axis (*celiac artery*), which seems to be the weakest part, for here also rupture is most likely to occur when forcibly injecting coloring material into the arterial system of the cadaver. Tumors of the pancreas and the stomach may be mistaken for aneurysm of the abdominal aorta. Aneurysm is often accompanied by backache which is sometimes mistaken for lumbago. By reflex sympathetic disturbance, it may cause nausea and vomiting. Its constant pressure sometimes causes gradual absorption of the bodies of the vertebræ, while pressure upon the spinal nerves may give rise to neuralgia in corresponding areas of nerve distribution. This is true of all intra-abdominal growths which cause pressure upon the somatic sensory nerves. It may compress various veins, arteries, or viscera, giving rise to a symptomatology which it is well for the student to figure out for himself. Thus, he may suppose the extension of the growth in a given direction, estimate its interference with other structures, and deduce the logical symptomatic results. As a general rule, symptoms referred to the back predominate in

PLATE CCCCXXXIII.

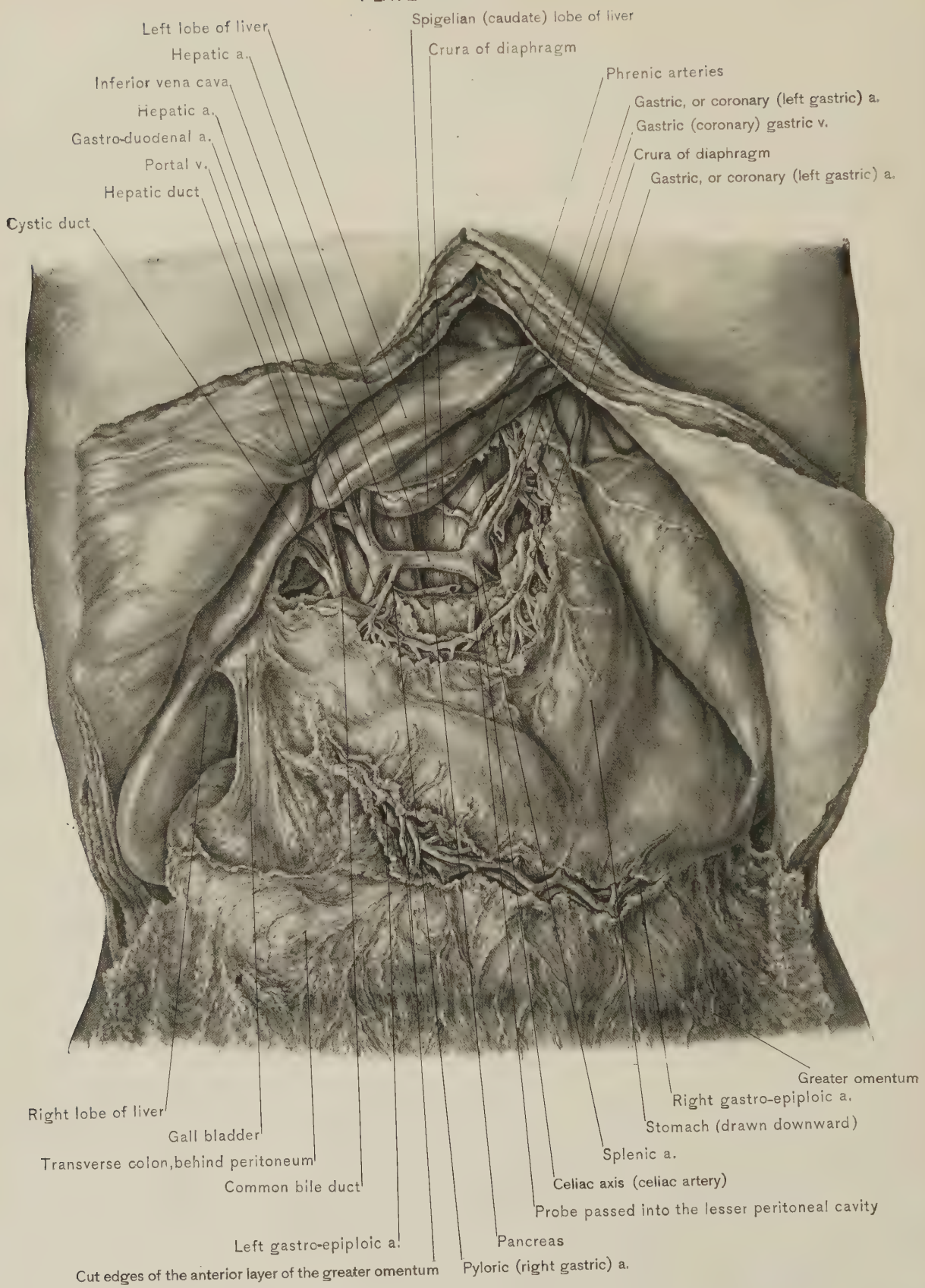

STOMACH, LIVER, PANCREAS, CELIAC AXIS (CELIAC ARTERY), HEPATIC, PYLORIC (RIGHT GASTRIC), AND GASTRIC, OR CORONARY (LEFT GASTRIC) ARTERIES, AND PORTAL VEIN.

aneurysms which begin at the back of the aorta, while in those which begin in the anterior wall of this vessel, visceral symptoms are prominent.

Ligation of the abdominal aorta is effected through the linea alba, by dividing both the anterior and the posterior parietal peritoneum, or may be done without entering the peritoneal cavity, as in ligation of the common iliac artery.

Compression of the aorta is more readily effected just above and to the left of the umbilicus, where it is nearest to the belly-wall, because the anterior lumbar curve of the spinal column is most prominent at that level. This is also a method of arresting severe hemorrhage from the pelvis and lower abdomen until other means can be adopted. The heel of the palm or the thenar and hypothenar eminences serve well for this purpose and are always available.

The **inferior, or ascending, vena cava** (Plate CCCCXXXIII) collects the blood from the lower extremities and the trunk below the diaphragm, except that from the alimentary tract, the pancreas, and the spleen, which passes through the liver by the portal vein and its tributaries. The hepatic vein which later collects this blood, however, also empties into the inferior vena cava. It is the largest venous trunk in the body, and is formed by the union of the two common iliac veins in front of the right side of the body of the fifth lumbar vertebra about two and a half centimeters (one inch) to the right of the median plane. In its ascent it lies upon the bodies of the lower three lumbar vertebræ, the right lumbar and renal arteries, and the right crus of the diaphragm, by which it is separated from the aorta. It passes through the caval opening in the central tendon of the diaphragm opposite the eighth thoracic vertebra, pierces the pericardium and immediately enters the right auricle of the heart. In its upward course it receives the lumbar, the right spermatic (*internal spermatic*) or ovarian, the renal, the right phrenic, the right suprarenal, and the hepatic veins. To the left of it lies the aorta, from which it is separated above by the right crus of the diaphragm. In front of it are the mesentery, the right spermatic artery, the transverse duodenum, the pancreas, the portal vein, the hepatic artery, and the liver, which partly encircles it.

The veins tributary to the inferior vena cava generally follow the same course as the corresponding arteries. Because of the position of the inferior vena cava to the right of the median line, the veins entering it from the left are longer than those from the right side; and as the aorta is on the left side of the median line, the arteries arising from the right side are longer than those from the left.

The inferior vena cava sometimes lies upon the left of the aorta, and crosses to the right above the level of the renal veins. In complete transposition of the viscera it lies upon the left side of the aorta throughout its course. Sometimes the inferior vena cava empties into the vena azygos major (*vena azygos*), which is

then necessarily enormously enlarged. The superior vena cava then receives the blood from the entire body, except the territory of the portal vein, the blood from which, after passing through the liver, goes directly to the right auricle by way of the hepatic veins. The anterior abdominal relations of the inferior vena cava are as follows: (1) the liver; (2) foramen of Winslow (*epiploic foramen*) with the free edge of the lesser omentum (*gastro-hepatic ligament*) containing the portal vein, the common bile duct and the hepatic artery; (3) the first portion of the duodenum, which is separated from the inferior vena cava by the portal vein, the common duct and the gastro-duodenal artery; (4) the head of the pancreas; (5) the right portion of the duodenum; (6) the posterior parietal peritoneum with the right colic and ileo-colic vessels; (7) the root of the mesentery with the superior mesenteric vessels, and (8) the right common iliac vessels.

The **lumbar veins,** four in number on each side, are found in company with the corresponding arteries. They receive blood through the dorsal tributaries from the muscles and the integument of the loins, through abdominal tributaries from the abdominal walls, and through spinal tributaries from the spinal plexuses of veins. In front of the transverse processes of the vertebræ the veins are joined by cross veins which form a continuous vessel, the *ascending lumbar vein,* which is connected by its upper extremity to the vena azygos major (*vena azygos*) on the right side, and to the vena azygos minor (*vena hemiazygos*) on the left side. The lumbar veins empty into the inferior vena cava, those of the left side passing behind the aorta.

The **two spermatic** (**internal spermatic**) or **ovarian veins** differ in their mode of termination; the right enters the inferior vena cava at an acute angle, and the left joins the left renal vein at almost a right angle. This is commonly held to account for the greater frequency of varicocele on the left side, because the blood from the spermatic (*internal spermatic*) artery enters at right angles to the renal blood current. Other reasons given for this occurrence are that, the left vein passing under the sigmoid flexure is subject to pressure by fecal accumulations in that portion of the bowel, and that the left testicle being situated lower than the right, the left spermatic (*internal spermatic*) vein is the longer, therefore the column of blood is heavier in this vein.

The **renal veins** are each formed at the hilum of the kidney by the union of three to six tributaries. They lie in front of the renal arteries, thus being an exception to the general rule that the veins of the abdomen lie behind or on the same plane as the arteries. They differ in length, the right being the shorter, a fact to be remembered in doing a right nephrectomy, for if too much traction is made upon the vein when applying the ligature, there is danger of tying off a part of the inferior vena cava or of tearing the vein from it. The left renal vein

PLATE CCCCXXXIV.

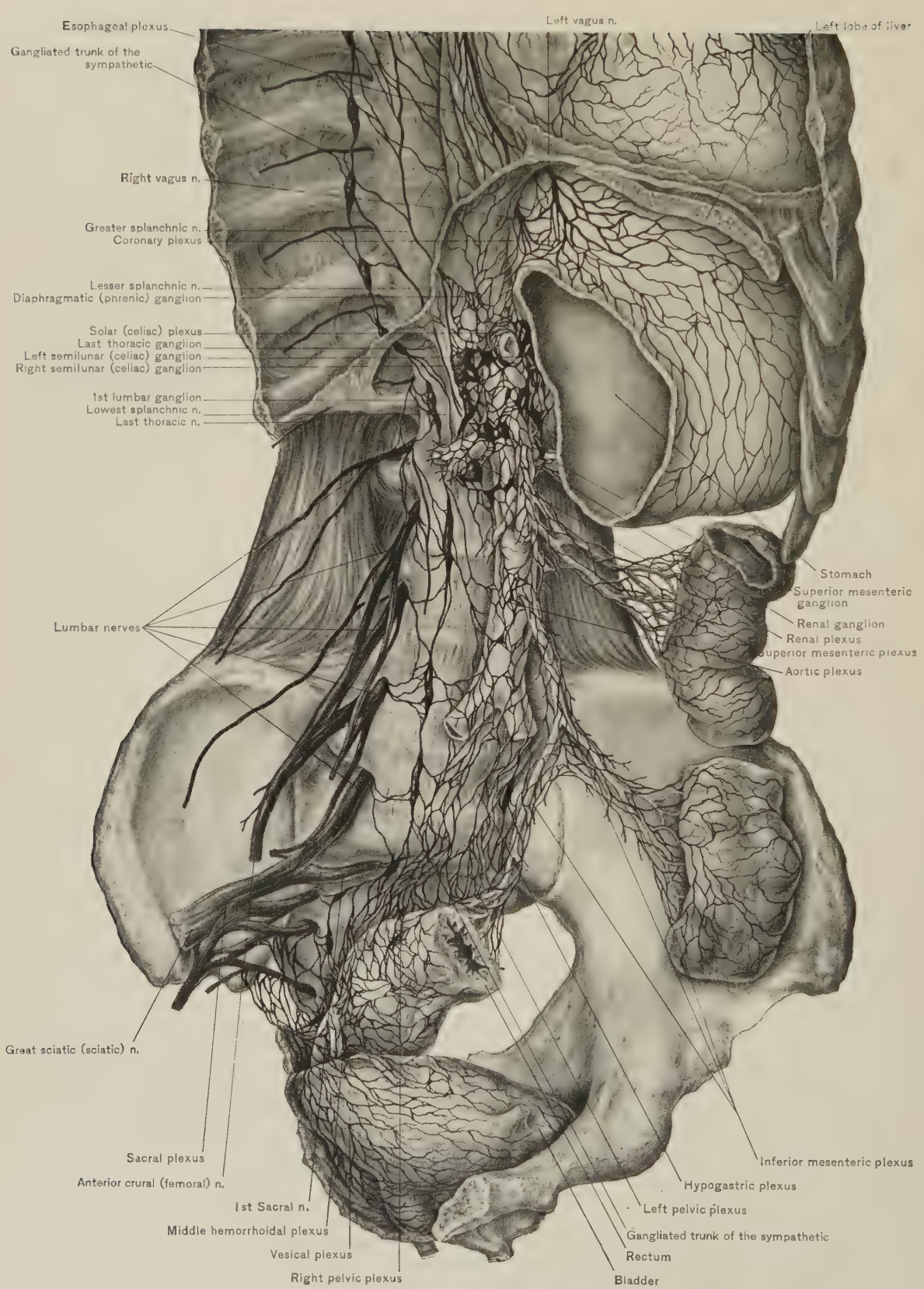

ABDOMINAL SYMPATHETIC NERVES.

PLATE CCCCXXXV.

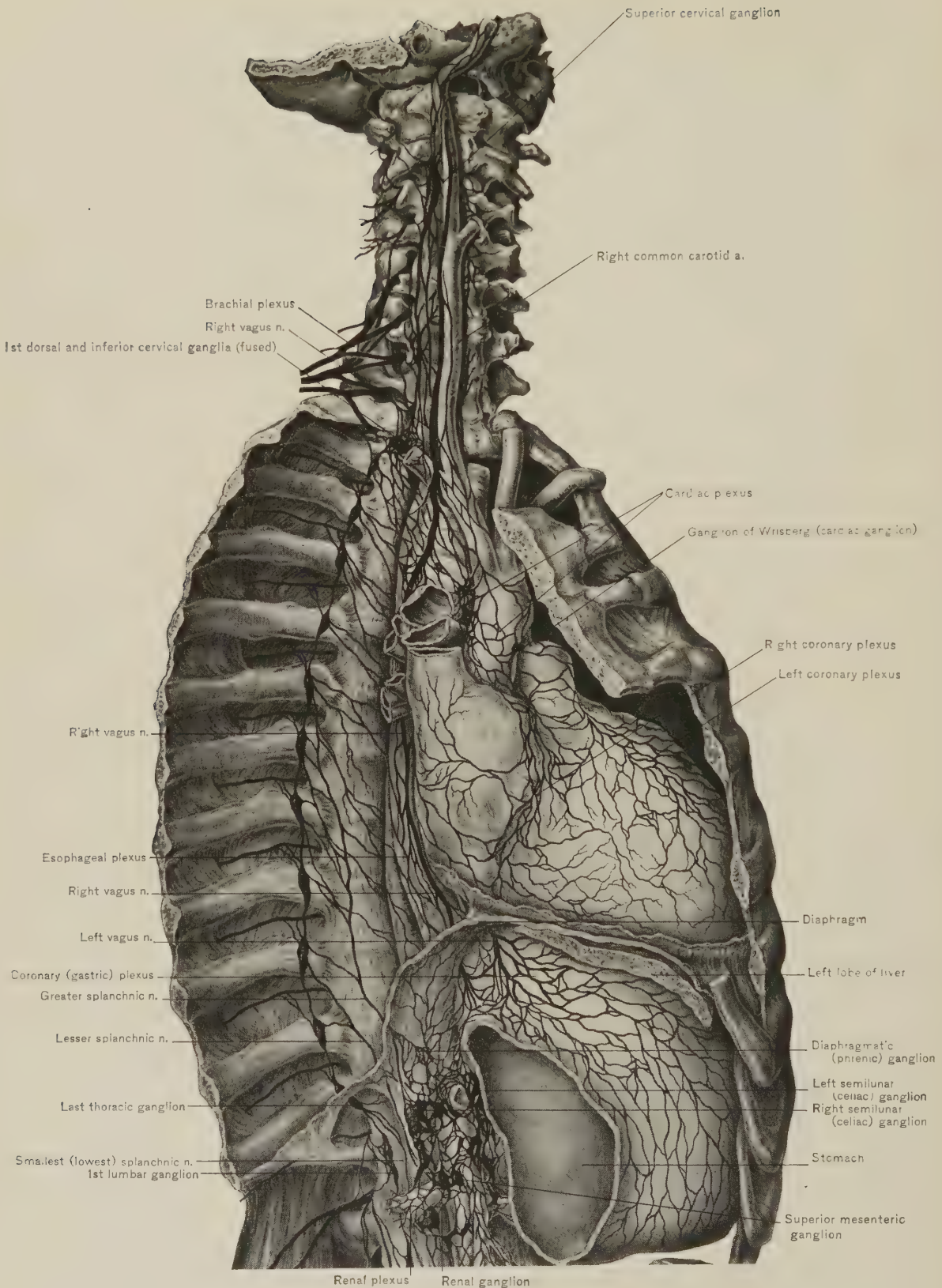

CERVICAL AND THORACIC SYMPATHETIC TRUNKS.

receives the left spermatic (*internal spermatic*) or ovarian, suprarenal, and phrenic veins.

The **suprarenal veins** differ in their terminations: the right joins the inferior vena cava, and the left empties into the left renal vein or the left phrenic vein.

The **phrenic veins** also differ: the right phrenic vein enters the inferior vena cava, and the left, the left renal vein.

The **hepatic veins** enter the inferior vena cava directly from the liver where it hugs this great venous trunk; so that these veins do not exist outside of the liver. The Spigelian (*caudate*) lobe ofttimes has a separate vein.

The **common iliac vein** is formed by the union of the external iliac and internal iliac (*hypogastric*) veins, opposite the sacro-iliac articulation at the inlet of the pelvis. The *right common iliac vein* is the shorter of the two, and holds a more nearly vertical course than the left. It lies behind, and then to the postero-lateral side of the right common iliac artery. The *left common iliac vein* runs a more oblique course. It lies on the medial side of the left common iliac artery, and then crosses beneath the right common iliac artery to join the right common iliac vein, in front of the right side of the body of the fifth lumbar vertebra, to form the inferior vena cava. It is crossed by the pelvic mesocolon and the superior hemorrhoidal vessels.

The **external iliac vein** is the continuation of the common femoral vein, which changes its name at the lower border of Poupart's (*inguinal*) ligament at the medial side of the termination of the external iliac artery. It passes upward along the brim of the pelvis, and joins the internal iliac (*hypogastric*) vein to form the common iliac vein opposite the sacro-iliac synchondrosis. On the right side, at first, the external iliac vein lies to the medial side of the artery but soon passes behind it; on the left side, it remains to the medial side of the artery throughout its entire course. The tributaries of the external iliac vein are the deep (*inferior*) epigastric and the deep circumflex iliac veins.

The **deep (inferior) epigastric vein** is a short vessel formed by the union of the venæ comites of the deep (*inferior*) epigastric artery. It empties into the external iliac vein a short distance above Poupart's (*inguinal*) ligament.

The **deep circumflex iliac vein** is formed by the union of the two veins which accompany the deep circumflex iliac artery. It crosses the external iliac artery just above Poupart's (*inguinal*) ligament, and joins the external iliac vein a little higher than the deep (*inferior*) epigastric vein.

The Abdominal Sympathetic (Plates CCCCXXXIV and CCCCXXXV).—The sympathetic system of trunks and ganglia enters the abdomen behind the internal arcuate ligaments (*medial lumbo-costal arches*) which span the psoas major muscles, or through the crura of the diaphragm, and passes downward

along the front of the bodies of the lumbar vertebræ. In the abdomen proper is the **lumbar portion of the gangliated trunk,** which usually contains four but sometimes more (up to eight) ganglia. The chains of ganglia enter the pelvis behind the common iliac arteries. A ganglion is found upon the body of each vertebra, and gives off lateral and medial branches. Some of the **medial branches** pass directly to the aortic plexus, and some pass along the common iliac and internal iliac (*hypogastric*) arteries to the hypogastric and pelvic plexuses. The **lateral branches,** or **gray rami communicantes,** run in pairs, accompany the lumbar arteries beneath the tendinous arches from which the psoas muscle arises, and join the anterior primary divisions of the lumbar nerves just lateral to the intervertebral foramina. (These rami communicantes in the lumbar portion of the sympathetic system are longer than elsewhere.)

The **solar,** or **epigastric** (**celiac**), **plexus** is a thick network of nerves and ganglia winding around the celiac axis (*celiac artery*) and the origin of the superior mesenteric artery. It rests upon the aorta and the crura of the diaphragm. It occupies the middle position, and is the largest in size of the **three prevertebral plexuses** of the sympathetic portion of the nervous system. These plexuses are: the **cardiac,** in the chest; the **solar** (**celiac**), in the abdomen, and the **hypogastric,** in the pelvis. The solar (*celiac*) plexus extends downward to the pancreas and laterally to the suprarenal glands. It receives the lesser splanchnics and branches of the vagi. It gives off branches which are distributed along all the branches of the abdominal aorta, around which they form networks or plexuses. These plexuses bear the same names as the vessels to which they are related.

The **semilunar** (**celiac**) **ganglia,** two in number, are parts of the solar (*celiac*) plexus, lying on each side of the plexus, and are formed by aggregations of smaller ganglia. They lie between the suprarenal glands, laterally, and on each side of the celiac axis (*celiac artery*) which they embrace in their concavities, and are united on their medial sides. The right is behind the inferior vena cava. After piercing the diaphragm the greater splanchnic nerves enter the convex sides of the ganglia.

The branches of the solar (*celiac*) plexus are, from above downward: the phrenic, the celiac, the gastric, the hepatic, the splenic, the suprarenal, the renal, the superior mesenteric, the aortic, the spermatic or ovarian, and the inferior mesenteric plexuses. They have been described in discussing the viscera to which they go, except in the following details:

The **phrenic,** or **diaphragmatic, plexuses** arise from the upper end of the semilunar (*celiac*) ganglia, the right being the larger. At the communication between the right phrenic plexus and the phrenic nerve there is a diaphragmatic ganglion (*phrenic ganglion*) which lies on the under surface of the diaphragm near the suprarenal gland.

The **suprarenal plexuses** are derived from the solar (*celiac*), the phrenic, and the renal plexuses. They are distributed to the medullary portions of the suprarenal glands.

Splanchnic Anaesthesia.—The method in most use today is that advocated by Kappis. It is applicable to operations on the stomach and gall-bladder. The injection is made by the posterior method. The patient is placed in a lateral position with the back arched, and the knees flexed and drawn up toward the chin. A pillow is placed under the loin to keep the spine straight. This assures a more accurate technic. The twelfth rib is located, a wheal is raised on its lower border seven centimeters (two and a half inches) from the midline of the spine. A long needle, ten to fifteen centimeters (four to six inches) in length, is used for the deep injection. The needle is inserted through the anesthetized skin, and contact is made with the twelfth rib. The needle is withdrawn slightly and is inclined toward the spine at an angle of from thirty to thirty-five degrees with the median sagittal plane. The needle strikes the lateral aspect of the first lumbar vertebra in front of the intervertebral foramen and within the substance of the psoas muscle. This point is posterior to the splanchnic nerves at approximately the level at which they join the semilunar (*celiac*) ganglion. The needle is then withdrawn and reinserted somewhat more obliquely lateralward, thus increasing the angle until the needle is tangent to the vertebra. When the needle no longer impinges on the bone but just grazes the body of the vertebra, the operator will feel it passing through a muscular mass and entering the paravertebral cellular space. At this point thirty to fifty cubic centimeters of one per cent novocain is injected. The procedure is then repeated on the opposite side.

The **renal plexus** is formed from the solar (*celiac*) plexus, the lateral parts of the semilunar (*celiac*) ganglia, the aortic plexus, and the lesser and smallest (*lowest*) splanchnic nerves. Each plexus consists of from fifteen to twenty nerves studded with ganglia. Branches from these plexuses enter the hilum of the kidneys, accompanying the arteries.

The **celiac plexus** is large and is a direct continuation of the solar (*celiac*) plexus. This is discussed under the celiac plexus in the new terminology. It surrounds the celiac axis (*celiac artery*), and divides into the *gastric*, *hepatic*, and *splenic plexuses*, which accompany the vessels of the same name and their branches to their ultimate destination.

The **superior mesenteric plexus** is derived from the lower part of the solar (*celiac*) plexus and a branch from the right vagus, accompanies the superior mesenteric artery, and contains a few ganglia, the superior mesenteric ganglia. Its subdivisions receive names corresponding to the branches of the artery.

The **aortic plexus** is, practically, the continuation of the solar (*celiac*) plexus on each side of the abdominal aorta, and is joined by branches from the upper three lumbar nerves. Each plexus is connected by transverse branches which cross in front of the aorta, and give origin to the spermatic or ovarian and inferior mesenteric plexuses, and terminates in branches to the hypogastric plexus.

The **spermatic plexus** is derived from the renal and aortic plexuses. Each plexus follows the spermatic artery to the internal abdominal (*abdominal inguinal*) ring, where it is joined by branches of the inferior hypogastric or pelvic plexuses. These last branches accompany the vas (*ductus*) deferens to the internal abdominal (*abdominal inguinal*) ring. The plexus then follows the artery to the testicle, or, in the female, follows the ovarian artery to the ovary and uterus.

The **inferior mesenteric plexus** arises from the left side of the aortic plexus, and accompanies the inferior mesenteric artery and its branches.

The Lumbar Nerves.—The lumbar nerves are five in number upon each side, and emerge at the intervertebral foramina. They are numbered from above downward, and divide into anterior and posterior branches.

The **posterior divisions** of the lumbar nerves have been described with the back.

The **anterior divisions** increase in size from above downward, and enter into the lumbar and sacral plexuses. They communicate with the lumbar sympathetic ganglia by long slender filaments, rami communicantes, and supply muscular branches to the psoas major and quadratus lumborum muscles.

The **lumbar plexus** (Plates CCCCXXXVI and CCCCXXXVII) is formed by the intercommunication of the anterior divisions of the upper four lumbar nerves and a communicating twig from the anterior division of the last thoracic nerve, the dorsi lumbar nerve. The lumbar and sacral plexuses are often discussed together as the *lumbo-sacral plexus*, but we are adhering to the anatomic subdivisions. It is placed in front of the transverse processes of the lumbar vertebræ, within the substance of the psoas major muscle. A branch from the fourth lumbar and the fifth lumbar nerves, form the lumbo-sacral trunk, which connects with the sacral plexus. The branches of the lumbar plexus are: the ilio-hypogastric and the ilio-inguinal nerves, which are derived from the first lumbar nerve or this nerve and a branch from the twelfth thoracic nerve; the genito-crural (*genito-femoral*) which is derived from the first and second lumbar nerves; the external (*lateral*) cutaneous nerve, from the second and third lumbar nerves; the obturator and the anterior crural (*femoral*) nerve, from the second, third, and fourth lumbar nerves, and the accessory obturator nerve (inconstant), from the third or third and fourth lumbar nerves.

PLATE CCCCXXXVI.

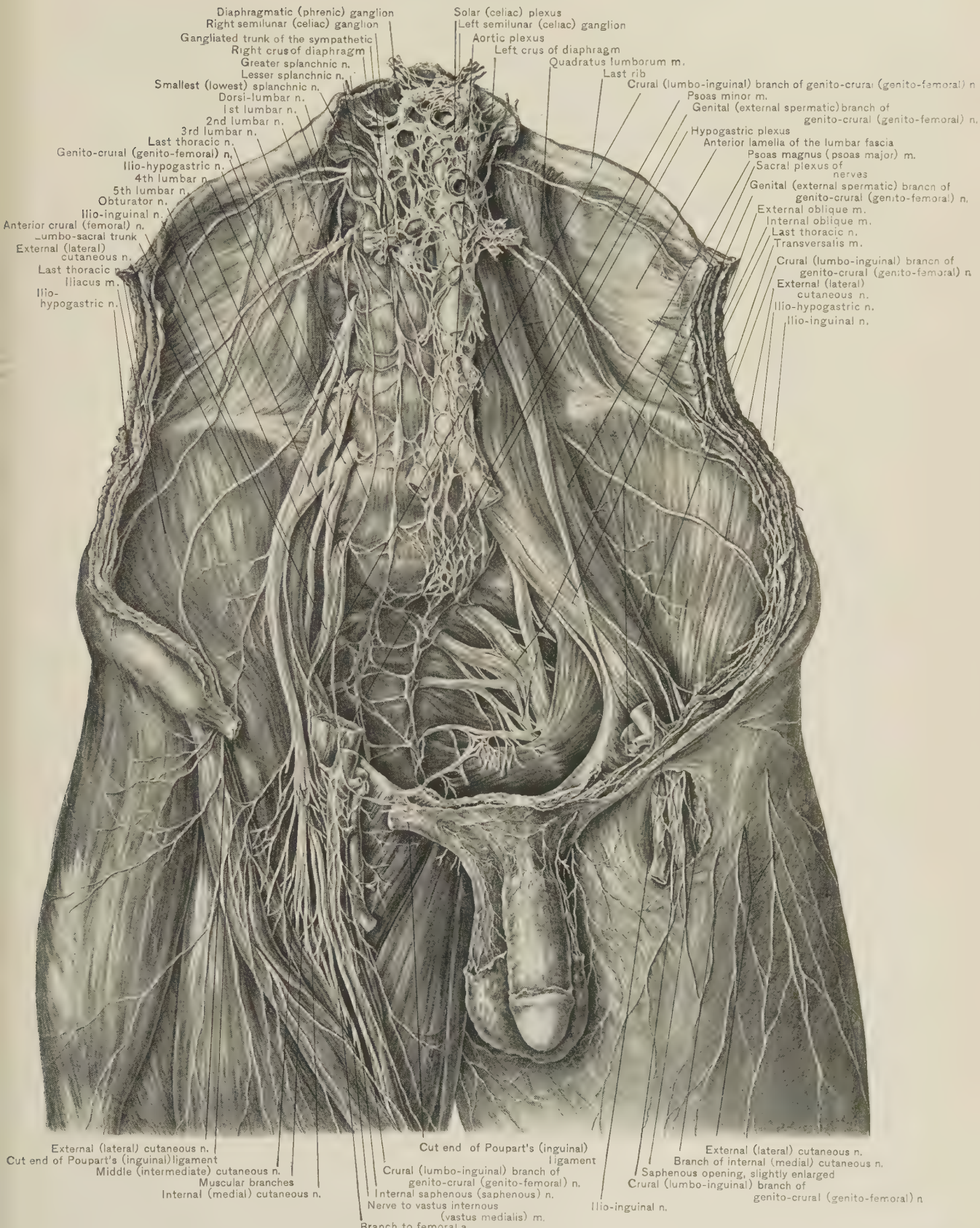

THE LUMBAR PLEXUS.

PLATE CCCCXXXVII.

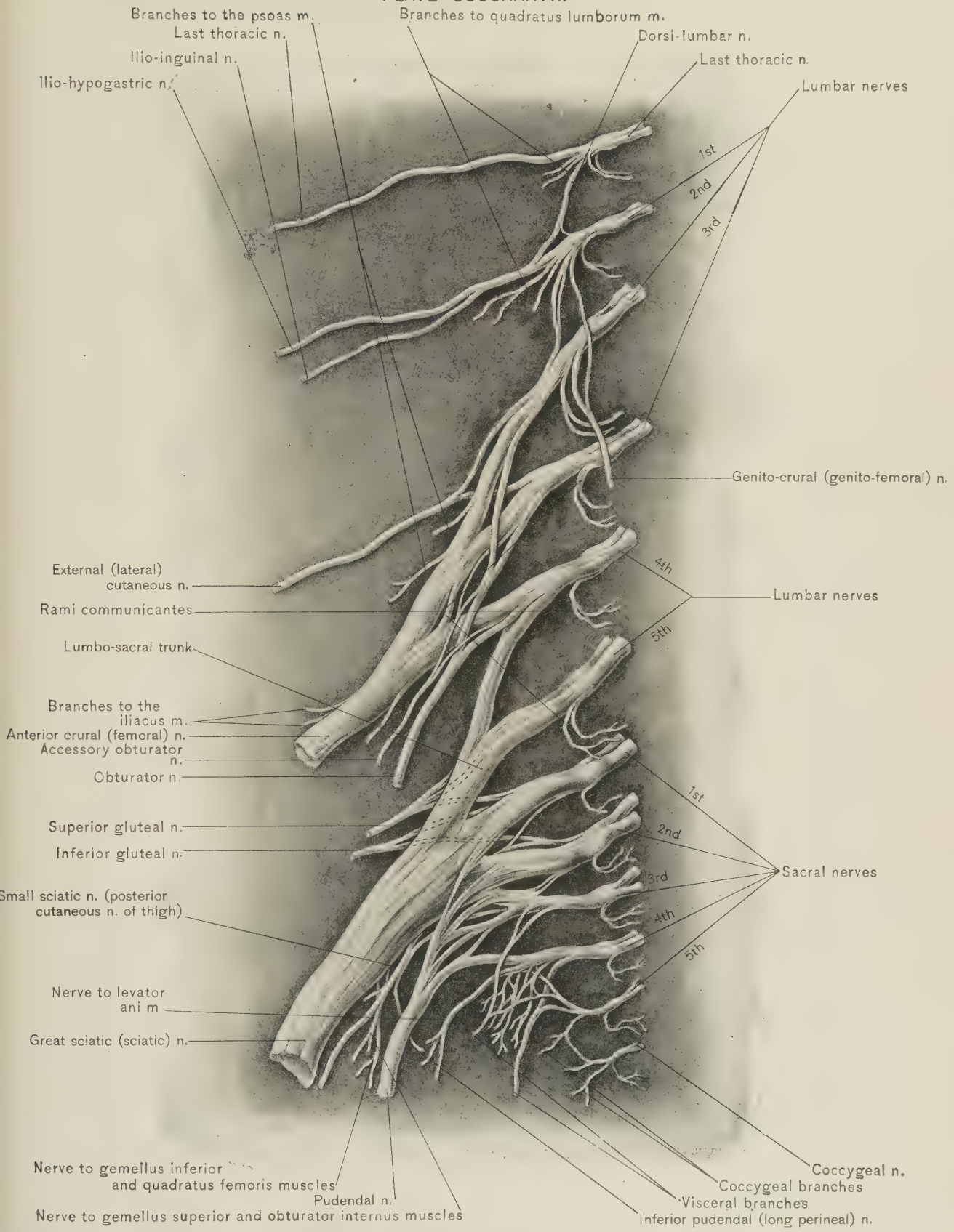

DIAGRAM OF THE LUMBAR AND SACRAL PLEXUSES.

The **ilio-hypogastric nerve** is a branch of the anterior division of the first lumbar nerve and may also receive a twig from the twelfth thoracic nerve. It passes through the upper part of the lateral border of the psoas major muscle, and runs in the extraperitoneal fat obliquely downward and lateralward across the front of the quadratus lumborum muscle behind the kidney to the crest of the ilium, where it pierces the transversalis (*transversus abdominis*) muscle. It runs forward along the crest of the ilium, between the transversalis (*transversus abdominis*) and internal oblique muscles, and divides into an iliac (*lateral cutaneous*) and a hypogastric (*anterior cutaneous*) branch about six centimeters (two and a half inches) behind the anterior superior spine of the ilium. The *iliac (lateral cutaneous) branch* passes through the internal and external oblique muscles above the crest of the ilium, and supplies the skin of the gluteal region behind the area of distribution of the lateral cutaneous, or iliac, branch of the last thoracic nerve. The *hypogastric (anterior cutaneous) branch* passes forward along the crest of the ilium, pierces the internal oblique muscle at the level of the anterior superior spine of the ilium, and passes through the aponeurosis of the external oblique muscle about two and a half centimeters (one inch) above the external abdominal (*subcutaneous inguinal*) ring. It sends *muscular branches* to the rectus abdominis and pyramidalis muscles, and *cutaneous branches* to the skin over the hypogastrium. The ilio-hypogastric nerve and its branches supply the external oblique, internal oblique, transversalis (*transversus abdominis*), rectus abdominis, and pyramidalis muscles, and the skin of the hypogastrium and of that portion of the gluteal region below the anterior part of the crest of the ilium.

The **ilio-inguinal nerve** arises in common with the preceding nerve from the anterior division of the first lumbar nerve and may also receive a twig from the twelfth thoracic nerve. It is situated below the ilio-hypogastric nerve, diverges from it in its onward course, and crosses the upper part of the iliacus muscle to pierce the transversalis (*transversus abdominis*) muscle near the anterior extremity of the iliac crest. It communicates with the ilio-hypogastric nerve above the iliac crest, where it lies between the transversalis (*transversus abdominis*) and internal oblique muscles, both of which it supplies. It passes through the internal oblique muscle anterior to the anterior superior spine of the ilium, and runs in front of the cremaster muscle and spermatic cord or round ligament through the inguinal canal, from which it emerges at the external abdominal (*subcutaneous inguinal*) ring. It supplies *muscular branches* to the transversalis (*transversus abdominis*), internal oblique, rectus abdominis, and pyramidalis muscles, and to the dartos, and *cutaneous branches* to the skin of the scrotum or labium and the upper and medial parts of the thigh. In the area in which it is encountered in the operation for inguinal hernia it is entirely sensory so that its

division in no way injures muscular innervation. It may however be caught by sutures and thus give rise to pain after the operation. For this reason the nerve should be visualized and retracted so that it will not be injured.

The **genito-crural** (**genito-femoral**) **nerve** arises from the anterior divisions of the first and second lumbar nerves by two roots which pass obliquely through the psoas major muscle and unite on the surface of the muscle to form a single nerve. The nerve runs downward in the extraperitoneal fat upon the psoas muscle, and upon the lateral side of the external iliac vessels and above Poupart's (*inguinal*) ligament divides into a genital (*external spermatic*) and a crural (*lumbo-inguinal*) branch.

The *genital* (*external spermatic*) *branch* accompanies the spermatic vessels through the inguinal canal and abdominal rings. Its branches pierce the internal spermatic fascia to supply muscular filaments to the cremaster muscle and end in the skin of the scrotum or labium majus. In the female it accompanies the round ligament.

The *crural* (*lumbo-inguinal*) *branch* runs under Poupart's (*inguinal*) ligament, and passes into the lateral compartment of the femoral sheath and sends off filaments to the femoral artery. It then pierces the lateral side of the femoral sheath, and passes through the fascia lata a little below Poupart's (*inguinal*) ligament and lateral to the femoral artery. It gives off cutaneous branches to the anterolateral aspect of the thigh, and a *communicating branch* to join the middle (*intermediate*) cutaneous nerve.

The **external** (**lateral**) **cutaneous nerve** arises from the anterior divisions of the second and third lumbar nerves. It pierces the lateral border of the psoas major muscle, and passes through the extraperitoneal fat obliquely across the iliacus muscle toward the anterior superior iliac spine. At this point it passes under Poupart's (*inguinal*) ligament into the thigh. It then divides into an anterior and a posterior branch.

The *anterior branch* continues downward in the fascia lata, and pierces it about ten centimeters (four inches) below the anterior superior iliac spine, to supply the skin of the anterolateral aspect of the thigh as far as the knee. It communicates with the middle (*intermediate*) cutaneous nerve, and sometimes with the long saphenous (*saphenous*) nerve.

The *posterior branch* perforates the fascia lata and supplies the skin of the posterolateral part of the proximal half of the thigh.

The **obturator nerve** takes its origin from the anterior divisions of the second, third, and fourth lumbar nerves. It passes between the psoas major muscle and the body of the fifth lumbar vertebra, and then runs in the extraperitoneal fat below and parallel with the medial border of the psoas major, and below the

level of the pelvic brim. In the latter part of its course it accompanies and lies above the obturator vessels, with which it passes through the deficiency in the obturator membrane at the upper part of the obturator foramen. On emerging from the pelvis it divides into an anterior and a posterior branch These are described with the lower extremity. This is the nerve which is exposed in the thigh for the Stoffel operation for spastic paraplegia.

The **accessory obturator nerve** is frequently absent. When present, it arises from the anterior divisions of the third and fourth lumbar nerves, from the roots of the obturator, or from the trunk of this nerve. It passes along the medial border of the psoas major muscle and across the horizontal ramus of the pubis, to the under surface of the pectineus muscle, behind which it divides into branches. These branches are muscular to the pectineus, articular to the hip-joint, and communicating to the obturator nerve.

The **anterior crural (femoral) nerve,** the largest branch of the plexus, arises from the anterior divisions of the second, third, and fourth lumbar nerves. Its roots pass through the deep portion of the psoas major muscle, and, emerging on the deep surface of the muscle, the roots unite into a single trunk which runs under the iliac fascia in the deep groove between the psoas and the iliacus muscles. It passes under Poupart's (*inguinal*) ligament into the thigh, where it lies lateral to the common femoral vessels. It lies under the iliac fascia while passing under Poupart's (*inguinal*) ligament. Within the lower abdomen it gives off three or four muscular branches which pass lateralward to the anterior surface of the iliacus. It also supplies a vascular filament which usually takes its origin a little above Poupart's (*inguinal*) ligament, but may arise considerably higher or lower. It is always present, and never fails to supply the common femoral artery, although its origin may vary. The branches of the anterior crural (*femoral*) nerve given off in the thigh are described with the lower extremity.

The anterior branch of the fifth lumbar nerve receives a fasciculus from the fourth lumbar nerve, and is then called the **lumbo-sacral trunk,** which passes downward to join the first sacral nerve, and thus assists in the formation of the sacral plexus.

Reflex retraction of the testis is caused through peripheral irritation of the genito-crural (*genito-femoral*) nerve. Neuralgia of any of the branches of the lumbar nerves may be caused by lumbar caries; distortions of the lumbar spine; lymphadenoma, cancer, abscess, aneursym, neuritis, or a number of other intra-abdominal disturbances.

The **lumbar spine** is the largest part of the spinal column in all dimensions except in length. Its bodies are thicker and wider, being bean- or kidney-shaped; its spinous processes are quadrilateral and more massive, and its transverse proc-

esses are very long, and consist of a costal and a transverse portion. Occasionally the costal portion of the transverse process is developed into a true lumbar rib. Having numerous muscles attached to it, it bears a greater strain than does any other part of the spinal column, and is most frequently affected by inflammatory disease, especially tuberculosis. It must bear the weight of the superimposed parts at all angles. When injured and in urgent need of rest for the purpose of repair, it is almost unceasingly mobile, for there is motion in the lumbar spine, due to breathing alone, while the patient lies upon the back. The patient cannot turn in bed without subjecting it to strain. These reasons sufficiently explain the stubbornness of injury or disease of the lumbar vertebræ. In a thin person considerably more than half of the anteroposterior diameter of the abdominal portion of the trunk above the umbilicus is taken up between the skin of the back and the front of the bodies of the vertebræ.

THE DIAPHRAGM (PLATE CCCCXXXVIII)

The diaphragm is the chief muscle of inspiration. It is a dome-shaped, musculo-aponeurotic sheet, which is a partition wall between the thoracic and abdominal cavities. Its upper or thoracic surface is convex, and its lower or abdominal surface concave. It forms the floor of the thoracic, and the roof of the abdominal cavity.

On account of the presence of the liver the dome ascends higher on the right side, extending to the level of the fifth chondro-sternal articulation, while on the left it reaches only to the level of the sixth chrondro-sternal articulation.

It *arises* from the whole circumference of the lower margin of the thoracic wall. Therefore it *arises* from the internal surface of the ensiform cartilage (*xiphoid process*), the cartilage and bony ends of the lower six or seven ribs, the bodies of the lumbar vertebræ and two aponeurotic arches, and the ligamenta arcuata interna (*medial lumbo-costal arch*) and externa (*lateral lumbo-costal arch*). The fibers from the various attachments or points of origin vary in length. Those from the ensiform cartilage (*xiphoid process*) are very short, while those from the ligamentous arches and from the lateral points of origin are much longer. The fibers converge for *insertion* into the central tendon, which is partially divided into three parts. Note that the fibers from the ensiform cartilage (*xiphoid process*) and those from the adjoining costal cartilages do not lie in contact; there is therefore generally a space on each side of the ensiform cartilage (*xiphoid process*) which is filled in with areolar tissue, and which may be traversed by a diaphragmatic hernia.

The **ligamentum arcuatum internum** (**medial lumbo-costal arch**) consists of a tendinous arch of fibers which is thrown across the upper end of the anterior

PLATE CCCCXXXVIII.

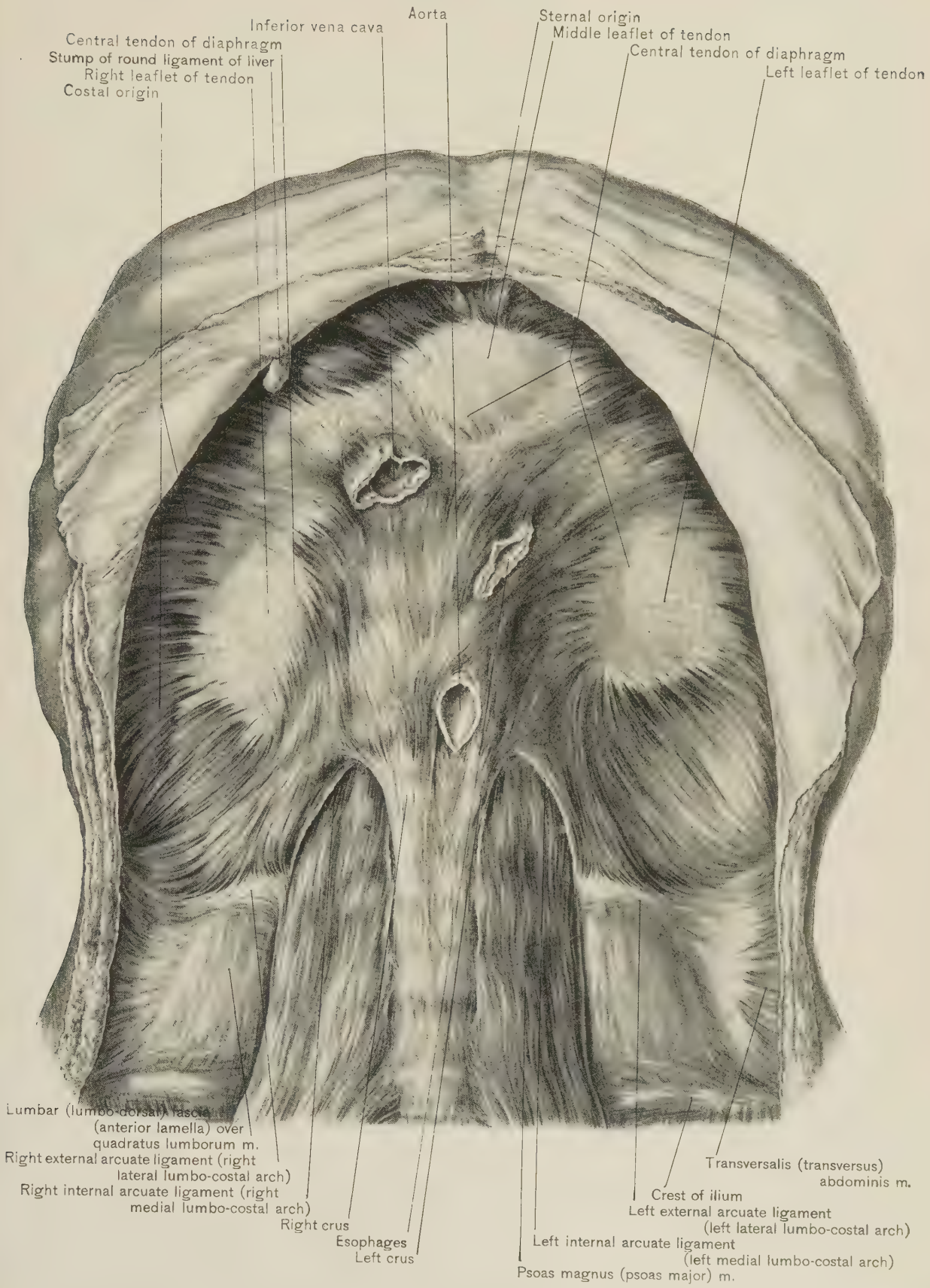
Aorta
Inferior vena cava
Central tendon of diaphragm
Stump of round ligament of liver
Right leaflet of tendon
Costal origin
Sternal origin
Middle leaflet of tendon
Central tendon of diaphragm
Left leaflet of tendon
Lumbar (lumbo-dorsal) fascia (anterior lamella) over quadratus lumborum m.
Right external arcuate ligament (right lateral lumbo-costal arch)
Right internal arcuate ligament (right medial lumbo-costal arch)
Right crus
Esophages
Left crus
Psoas magnus (psoas major) m.
Left internal arcuate ligament (left medial lumbo-costal arch)
Left external arcuate ligament (left lateral lumbo-costal arch)
Crest of ilium
Transversalis (transversus) abdominis m.

THE DIAPHRAGM.

surface of the psoas major muscle, and is a thickened part of the psoas portion of the iliac fascia. It extends from the side of the body of the second lumbar vertebra, where it is continuous with the crus of that side, to the tip of the transverse process of the first lumbar vertebra.

The **ligamentum arcuatum externum** (**lateral lumbo-costal arch**) is the thickened upper part of the anterior layer of the lumbar (*lumbo-dorsal*) fascia and arches across the anterior surface of the quadratus lumborum muscle. It extends from the tip of the transverse process of the first lumbar vertebra to the tip and lower margin of the last rib.

The diaphragm arises from the spinal vertebræ by two tendinous elongated bundles, the **crura of the diaphragm.** They have tendinous origins, the right arising from the bodies of the first, second, third, and fourth lumbar vertebræ, intervening cartilages, and the anterior common (*anterior longitudinal*) ligament; and the left, from the bodies of the first, second, and third lumbar vertebræ, the anterior common (*anterior longitudinal*) ligament, and the intervertebral discs. Both crura blend with the anterior common (*anterior longitudinal*) ligament of the spine. They converge, after passing anteriorly and medialward, and decussate in the midline, forming an arch. Behind this arch is the aortic opening of the diaphragm, through which pass the aorta, the vena azygos major (*azygos*), and the thoracic duct. Muscle fibers arise from this tendinous arch and pass upward and lateralward for *insertion* into the central tendon. The medial fibers, however, decussate above the aorta and surround the esophagus. In this decussation the fibers of the right side are the more anterior.

The **central tendon of the diaphragm** is a thin aponeurotic sheet which is located near the center of the dome. The central tendon is composed of three divisions or leaflets which vary in size, the right being the largest, the left, the smallest, and the middle, or ensiform, intermediate in size. The superior surface of the intermediate portion is in relation with the pericardium, and at its circumference gives attachment to that membrane. The pleuræ are in relation with the lateral portions. The tendon is made up of several layers of fibers which intermingle and cross one another, so as to give additional strength to it.

The main **openings in the diaphragm** are the aortic, the esophageal, and the opening for the inferior vena cava.

The **aortic opening** is formed by the arch made by the fibrous junction of the crura of the diaphragm. It is dorsal to the internal arcuate ligament (*medial lumbo-costal arch*) and is located immediately in front of the spinal column, opposite the body of the twelfth thoracic vertebra. It transmits the aorta, the vena azygos major (*azygos*), the thoracic duct, and two descending lymphatic trunks. At times the left sympathetic nerve also passes through this opening. In some

instances fibers from the sides of the vertebræ pass beneath the aorta, and thus convert the opening into a fibrous ring which is situated within the diaphragm, although the aortic opening is usually behind the diaphragm, and completed posteriorly by the anterior common (*anterior longitudinal*) ligament.

The **esophageal opening** is an elliptic orifice in the diaphragm, with its long diameter directed anteroposteriorly, bounded by the decussating medial muscle fibers from the crura which embrace the esophagus. It is dotsal to the intermediate leaflet of the central tendon. It is placed above, anterior to, and to the left of the aortic opening, on a level with the body of the tenth thoracic vertebra and the seventh costal cartilage. It transmits the esophagus and the vagus nerves, the esophageal branches of the thoracic aorta and the anastomosing esophageal branches of the coronary (*left gastric*) artery. At times the anterior margin of the opening is tendinous, and formed by the margin of the central tendon.

The **opening for the inferior vena cava, or foramen for the vena cava,** is quadrate in shape, and situated close behind the central tendon, at the junction of the right and intermediate leaflets of the tendon. It is higher than the other main openings, being opposite the eighth thoracic vertebra. Through it pass the inferior vena cava, a few lymphatics from the convex surface of the liver, and, generally, a branch from the right phrenic nerve. The walls of the vein are attached to the margins of the opening, and in this manner the terminal portion of the vein is continually held open.

Openings in the right crus transmit the sympathetic and greater and lesser splanchnics of the right side; those in the left crus, the greater and lesser splanchnic nerves of the left side and the vena azygos minor (*hemiazygos*). A space exists between the attachments to the ensiform (*xiphoid*) and the seventh costal cartilages, and here the peritoneum and pleura are separated only by areolar tissue.

Relations.—The diaphragm is in relation with the two pleuræ and the pericardium on its convex, or thoracic, surface, and with the peritoneum on its concave surface. The organs in relation with it, above, are the lungs and the heart; below it is in relation with the liver and its ligaments, the stomach, the spleen, the pancreas, the kidneys, and the suprarenal glands.

Blood Supply.—From the two phrenic branches of the aorta, the musculophrenic branches of the internal mammary arteries, and from the lower intercostal arteries.

Nerve Supply.—From the phrenic nerves and the lower five or six intercostal nerves. Small filaments are also sent to the diaphragm from the diaphragmatic (*phrenic*) plexuses, which are derived from the semilunar (*celiac*) ganglia and solar (*celiac*) plexus. At the point where the plexus joins filaments of

the right phrenic nerve, on the under surface of the diaphragm, close to the right surparenal gland, is situated the **diaphragmatic (phrenic) ganglion.** Branches of this ganglion are given off to the liver, the inferior vena cava, and the suprarenal gland. This ganglion is absent on the left side. It should be remembered that section of the phrenic nerve in the neck does not paralyze the diaphragm. The accessory phrenic which comes from the fifth cervical does not join the main nerve until this nerve has passed below the clavicle. The entire phrenic supply cannot be removed unless the nerve is exposed in the neck as it passes over the scalenus anterior and twisted so as to remove a part of the thoracic portion.

Action.—The action of the diaphragm is to deepen the chest from above downward; thus it is the powerful muscle of inspiration. When the muscular portion contracts it descends, pushing the abdominal viscera downward. When acting in conjunction with the abdominal muscles, it is a powerful force in the expulsion of feces and urine, and assists in parturition and in emesis. By its spasmodic contractions it plays an important rôle in coughing, sneezing, laughing, etc.

During contraction of the muscle the central tendon is only slightly, if at all, depressed. By their contraction, however, the fibers radiating from this central portion deeply depress the sides of the vault, and thus deepen the chest cavity. When contracting with the abdominal muscles, the diaphragm forms a barrier against which the abdominal viscera may be compressed.

When the diaphragm is paralyzed, respiration is performed by the intercostals and the accessory muscles of respiration.

Hiccup is produced by clonic or intermittent spasm of the diaphragm. It is caused by irritation of the phrenic nerve or some irritation referred through the symphatic fibers of the diaphragmatic (*phrenic*) plexuses. Thus hiccup often occurs after a meal or from distention of the stomach, or in pleurisy, pericarditis, and peritonitis.

The **iliac fascia** is a thin, fibrous membrane which entirely covers the iliacus and the psoas muscles and the lumbar plexus, and on which rest the iliac arteries. Laterally this fascia is attached to the medial lip of the crest of the ilium, along which it is continuous with the transversalis fascia and the anterior lamella of the lumbar (*lumbo-dorsal*) fascia, and medially to the ilio-pectineal line, along which it is continuous with the pelvic fascia. It may be divided into an iliac and a psoas portion.

The portion covering the iliacus muscle is attached laterally to the whole length of the medial border of the crest of the ilium, and medially to the brim of the pelvis. This part of the fascia is intimately connected with the part of Poupart's (*inguinal*) ligament lateral to the line of the external iliac vessels.

Behind the vessels it descends into the thigh, thus forming the posterior wall of the sheath of the femoral vessels. At the medial side of the vessels it is attached to the ilio-pectineal line behind the conjoined tendon (*falx inguinale*). It becomes continuous with the transversalis fascia on the medial and lateral sides of the external iliac vessels. An abscess beneath this fascia points below Poupart's (*inguinal*) ligament on the lateral side of the femoral vessels, and may pass over the brim of the pelvis and beneath the pelvic fascia to the perineum or to the gluteal region.

The portion in relation with the psoas major muscle is attached internally to the base of the sacrum, the upper and lower margins of the bodies of the lumbar vertebræ, and the intervertebral discs, thus forming tendinous arches over the concavities of the bodies of the vertebræ. These arches give origin to the psoas muscle, and transmit the lumbar vessels and branches of the sympathetic nerve (rami communicantes). Above, it forms the ligamentum arcuatum internum (*medial lumbo-costal arch*). Below the crest of the ilium the psoas portion of the iliac fascia becomes continuous laterally with the portion which covers the iliacus muscle. Above the iliac crest it is attached laterally to the anterior layer of the lumbar (*lumbo-dorsal*) fascia near the tips of the transverse processes of the vertebræ.

At the point where the iliac fascia is attached to the ilio-pectineal line it is continuous with the pelvic fascia. Medial to the psoas it is also attached to the capsular ligament of the hip-joint and to the horizontal ramus of the pubis, becoming continuous with the pubic portion of the fascia lata. Opposite the lateral half of Poupart's (*inguinal*) ligament the iliac and transversalis fasciæ blend, and become closely united to that ligament. Beneath the medial part of Poupart's (*inguinal*) ligament these fasciæ do not blend, but continue downward upon the common femoral vessels. The iliac fascia lies behind, and the transversalis fascia in front of them. Thus is formed the **femoral sheath,** described with the lower extremity. Below Poupart's (*inguinal*) ligament the iliac fascia continues to cover the psoas and iliacus muscles and the anterior crural (*femoral*) nerve.

In psoas abscess, which is usually due to caries of the vertebræ, the direction in which the pus will burrow is determined by this portion of the iliac fascia. If this fascia, which forms the sheath of the psoas muscle, remains intact, the pus will follow the course of the muscle and present below Poupart's (*inguinal*) ligament, at the lateral side of the femoral vessels. If the pus breaks through the sheath of the psoas, the collection will occupy the iliac fossa; it may gravitate into the pelvis, under the pelvic fascia, pass through the great sacro-sciatic (*greater sciatic*) foramen, and present in the gluteal region; or it may pass under the pelvic

PLATE CCCCXXXIX.

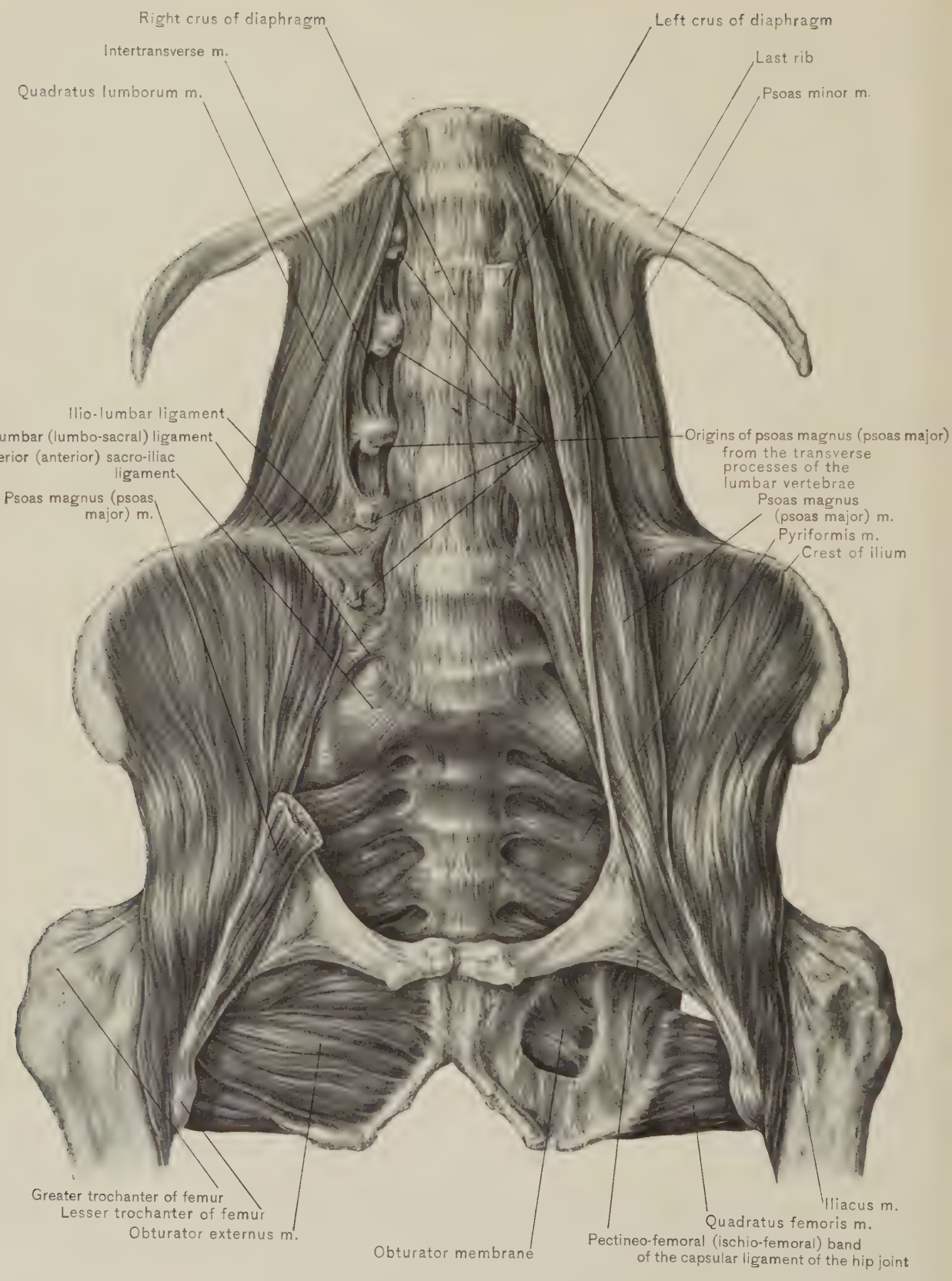
Right crus of diaphragm
Left crus of diaphragm
Intertransverse m.
Last rib
Quadratus lumborum m.
Psoas minor m.
Ilio-lumbar ligament
Sacro-lumbar (lumbo-sacral) ligament
Superior (anterior) sacro-iliac ligament
Origins of psoas magnus (psoas major) from the transverse processes of the lumbar vertebrae
Psoas magnus (psoas major) m.
Psoas magnus (psoas major) m.
Pyriformis m.
Crest of ilium
Greater trochanter of femur
Lesser trochanter of femur
Obturator externus m.
Obturator membrane
Iliacus m.
Quadratus femoris m.
Pectineo-femoral (ischio-femoral) band of the capsular ligament of the hip joint

QUADRATUS LUMBORUM, PSOAS, AND ILIACUS MUSCLES.

and obturator fasciæ, perforate the obturator fascia, and enter the ischio-rectal fossa. Thus the collection may be mistaken for an iliac, a gluteal, or an ischio-rectal abscess.

The **psoas magnus (psoas major) muscle** (Plate CCCCXXXIX) is a fusiform muscle which *arises* by five fasciculi from the transverse processes of all the lumbar vertebræ, from the intervertebral discs, and from the margins of the bodies of the vertebræ between the lower margin of the last thoracic vertebra and the upper margin of the last lumbar vertebra, inclusive. The slips are attached to the bodies of the vertebræ only at their prominent margins. Over the concavities of the bodies the muscle fibers arise from the tendinous arches formed by the psoas portion of the iliac fascia. The fibers converge as they pass downward and lateralward, the tendon appearing in the center of the muscle, at about the level of the crest of the ilium. The tendon and the narrow portion of the muscle pass along the brim of the pelvis, and the tendon passes beneath Poupart's (*inguinal*) ligament and over the capsule of the hip-joint, to be *inserted* into the lesser trochanter of the femur. Between the tendon and the capsule of the joint is a bursa which at times communicates with the interior of the joint through the capsule. While passing over the brim of the pelvis the tendon receives part of the insertion of the iliacus muscle. Within the muscle is found the lumbar plexus, the nerves from which run in its substance for some distance.

Relations.—In front of the psoas major muscle are: the psoas minor muscle, the iliac fascia, extraperitoneal fat, the genito-crural (*genito-femoral*) nerve, the kidney, the renal vessels, the spermatic (*internal spermatic*) or ovarian vessels, the ureter, the vas deferens (*ductus deferens*) (male), or the round ligament (female), the peritoneum, the intestines, and the external iliac and common femoral vessels. Behind it are: the lumbar vertebræ, the anterior lamella of the lumbar (*lumbo-dorsal*) fascia, the quadratus lumborum muscle, the brim of the pelvis, the horizontal ramus of the pubis, and the capsule of the hip-joint. To the lateral side are: the kidney, the colon, the iliacus muscle, and the anterior crural (*femoral*) nerve. On the medial side are: the crura of the diaphragm, bodies of the lumbar vertebræ, the lumbar arteries, the lumbar glands, the obturator nerve, the sympathetic ganglia and nerve, and the external iliac vessels. The aorta lies to the medial side of the left psoas muscle, and the inferior vena cava to the medial side of the right psoas.

Blood Supply.—Chiefly from the lumbar and ilio-lumbar arteries.

Nerve Supply.—From the lumbar plexus, through the second, third, and fourth lumbar nerves.

Action.—The psoas major muscle acts as a powerful flexor of the thigh upon the pelvis. When acting from below, the psoas flexes the lower thoracic

and the lumbar portions of the spinal column upon the pelvis, and the pelvis on the thigh. Owing to the angle formed by the neck of the femur with the shaft, the muscle cannot act as a lateral rotator of the thigh, as the point of insertion of the psoas muscle is lateral to the axis around which the limb rotates, and therefore the muscle may act as a medial rotator of the thigh.

The action of the psoas is well shown in coxitis or hip disease, in which irritation of this muscle causes it to be in a state of continuous or tonic contraction. Therefore the thigh is flexed upon the pelvis, and when the thigh is brought into a line with the trunk, the pelvis is flexed on the thigh and the lumbar portion of the spinal column is arched forward. Acting with the iliacus it also rotates the thigh medially during flexion, and laterally when the thigh is flexed or when the neck of the femur is fractured.

The **iliacus muscle** is wide and triangular. It *arises* from the upper half of the iliac fossa, the medial lip of the crest of the ilium, the ala of the sacrum, the ilio-lumbar, lumbo-sacral, and anterior sacro-iliac ligaments, the anterior superior spine of the ilium, and the capsular ligament of the hip-joint. The fibers converge and pass downward and medialward. The upper fibers join the tendon of the psoas muscle about five centimeters (two inches) above its insertion, and are *inserted* into the lesser trochanter of the femur; the lowest fibers are continued downward for insertion into the shaft of the femur for two and a half centimeters (one inch) below the lesser trochanter.

Relations.—In front of the iliacus are: the ilio-inguinal, the lateral cutaneous, and the anterior crural (*femoral*) nerves, the iliac fascia, extraperitoneal fat, the peritoneum, and the intestines. The cecum and vermiform appendix are anterior to it on the right side, and the sigmoid flexure (*iliac and pelvic colon*) on the left side. The deep femoral (*profunda femoris*) artery and the sartorius muscle rest upon it in the thigh. Behind it are the ilium, the capsule of the hip-joint, and the rectus femoris muscle. On its medial side is the psoas major muscle.

Blood Supply.—From the ilio-lumbar, the deep circumflex iliac, and the lateral circumflex artery.

Nerve Supply.—From the anterior crural (*femoral*) nerve.

Action.—The iliacus, like the psoas, is a flexor of the hip-joint and thigh. When acting from below, it draws the pelvis forward. It also aids to maintain the erect posture by supporting the spine upon the femur. Its action on the thigh is similar to that of the psoas.

The **psoas minor muscle** is a small, inconstant muscle, being absent in about forty per cent of cadavers. It *arises* from the adjacent borders of the last thoracic and first lumbar vertebræ and the intervening intervertebral disc. The

fibers converge and form a tendon which begins about five centimeters (two inches) below the origin of the muscle. The tendon is *inserted* by a broad expansion into the iliac fascia, ilio-pectineal line, and ilio-pectineal eminence.

The muscle lies in front of the psoas major muscle and behind the iliac fascia. The tendon lies to the medial side of the psoas major muscle as it passes along the brim of the pelvis.

Nerve Supply.—From the first lumbar nerve.

Action.—It flexes the vertebral column and tightens the ilio-psoas fascia.

The **quadratus lumborum muscle** is a thin, quadrilateral muscle, lying on the posterior abdominal wall. It *arises* five centimeters (two inches) beyond the medial lip of the crest of the ilium, near the junction of its middle and posterior thirds, from the ilio-lumbar ligament, and from the tips of the transverse processes of the lower three lumbar vertebræ. It is *inserted* into the medial half of the lower border of the last rib, the transverse processes of the upper three or four lumbar vertebræ, and the middle lamella of the lumbar (*lumbo-dorsal*) fascia, just lateral to the transverse processes.

Relations.—Anterior are: the anterior division of the last thoracic nerve, the ilio-lumbar (*lumbo-inguinal*) and ilio-hypogastric nerves, the lumbar arteries, the anterior lamella of the lumbar (*lumbo-dorsal*) fascia, subperitoneal fat, the kidney, the colon, and the psoas major muscle. Along the medial border of the muscle are the intertransverse muscles. The middle layer of the lumbar (*lumbo-dorsal*) fascia is behind it and separates it from the erector spinæ (*sacro-spinalis*) muscle.

Blood Supply.—From the lumbar arteries.

Nerve Supply.—From the twelfth thoracic and upper lumbar nerves.

Action.—The quadratus lumborum muscle acts as a lateral flexor of the thorax and of the lower thoracic and lumbar regions of the spinal column, and draws the last rib downward, thus assisting in expiration. When acting from its upper attachments it is also a lateral flexor of the pelvis.

THE PELVIC CAVITY

The **pelvic cavity** is that portion of the general abdominal cavity inclosed by the hip bones anteriorly and laterally, and the sacrum and the coccyx posteriorly. The hip bones, or innominate bones, join in front to form the symphysis pubis; while the sacrum forms its posterior boundary. The innominate bone, which is paired, is made up of three parts: *ilium*, *ischium*, and *pubis*. These meet in a hemispherical cavity, the *acetabulum*. This general pelvic cavity is divided into the true and the false pelvis.

The **false pelvis** (**pelvis major**) is that portion of the cavity which lies above the ilio-pectineal lines, and comes in relation with the abdominal contents of the hypogastric and iliac regions.

The **true pelvis** (**pelvis minor**), or the pelvic cavity proper, lies below the level of the ilio-pectineal lines. It has a superior opening, or inlet, and an inferior opening or outlet. It contains the pelvic viscera.

The **inlet** (**superior aperture**) of the true pelvis is the cordate space, bounded anteriorly by the pubic crest and the symphysis pubis; posteriorly by the anterior edge of the ala of the sacrum, and laterally, by the ilio-pectineal lines. These form the pelvic brim and are sometimes spoken of as the **linea terminalis**, which is divided into a sacral, iliac, and pubic portion. The diameters of the inlet (*superior aperture*) are the anteroposterior (conjugate), the transverse, and the oblique. The **anteroposterior**, or **conjugate, diameter** extends from the upper margin of the symphysis pubis to the middle of the sacral promontory. It averages about ten centimeters (four inches) in the male, and twelve centimeters (four and three-fourths inches) in the female. The **transverse diameter** extends transversely across the greatest width of the inlet (*superior aperture*). It averages about eleven centimeters (four and a half inches) in the male, and thirteen centimeters (five and one-fourth inches) in the female. The **oblique diameter** extends from the ilio-pectineal eminence, on one side, to the sacro-iliac joint on the other. It averages about ten and a half centimeters (four and one-fourth inches) in the male, and twelve and one-half centimeters (five inches) in the female. The **obstetrical inlet** is the least available space at the upper portion of the pelvic canal. It is bounded by a line passing one centimeter below the upper margin of the symphysis pubis, along the posterior margin of the oblique rami and the body of the pubis, past the ileo-pectineal eminences, the anterior margin of the ala of the sacrum, and the summit of the sacral promontory.

The **outlet** (**inferior aperture**) of the true pelvis is bounded anteriorly by the pubic arch and subpubic (*arcuate pubic*) ligament; posteriorly, by the tip of the coccyx and at the sides, by the tuberosities of the ischia. While the pelvic inlet (*superior aperture*) is a continuous bony ring, the circumference of the pelvic outlet (*superior aperture*) is partly bony and partly ligamentous. In the undissected subject the inlet (*inferior aperture*) appears open, but the outlet (*inferior aperture*) is closed by the tissues of the perineum. The diameters of the outlet (*inferior aperture*) are the anteroposterior, or conjugate, and the transverse. The **anteroposterior diameter** extends from the lower edge of the symphysis pubis to the tip of the coccyx; it averages about eight centimeters (three and one-fourth inches) in the male and twelve and a half centimeters (five inches) in the female. This measurement varies during life from ten to twelve

and one-half centimeters (four to five inches) owing to the mobility of the coccyx. The **transverse diameter** extends from the posterior part of one ischiatic tuberosity to a corresponding point on the opposite tuberosity; it averages about nine and a half centimeters (three and three-quarter inches) in the male, and twelve centimeters (four and three-quarter inches) in the female.

The **obstetrical outlet** is just above the anatomical outlet (*inferior aperture*) and is the circumference of greatest bony resistance of the true pelvis as well as the smallest in size. It is bounded by the posterior surface of the symphysis pubis about six millimeters (one-fourth inch) above the lower margin, the upper portions of the ischial tuberosities and the lower border of the sacrum.

The **cavity of the true pelvis** is a basin-shaped canal. This basin is formed by the bones of the pelvis with their lining structures of muscles and fasciæ on the sides, and by the muscles and fasciæ which close in the inferior portion, or outlet, below. It is three and a half to five centimeters (one and a half to two inches) in length anteriorly and twelve and a half to fifteen centimeters (five to six inches) posteriorly. The axis of the superior aperture is a line drawn at right angles to its center. If this line were continued it would pass from the tip of the coccyx to the umbilicus. The **anterior wall** is formed by the pubic bones and the subpubic (*arcuate pubic*) ligament. Each **lateral wall** is formed by the innominate bone, the obturator membrane, the internal obturator muscle, and the pelvic fascia; the **posterior wall** by the sacrum, the coccyx, the greater (*sacro-tuberous*) and lesser (*sacro-spinous*) sacro-sciatic ligaments, the pyriformes and coccygei muscles, and the **floor** by the structures which fill the outlet (*inferior aperture*) of the pelvis: the recto-vesical fascia, the levatores ani and coccygei muscles, the anal fascia, and the triangular ligament (*urogenital diaphragm*) of the perineum. The levatores ani form a partition which separates the pelvic cavity proper from the ischio-rectal fossæ.

As the visceral layer of the pelvic fascia or recto-vesical fascia forms the lining of the floor of the pelvic basin, a wound should not be described as having penetrated the pelvic cavity if it has not passed through this layer of fascia. The recto-vesical (*visceral*) layer of the pelvic fascia holds the same relation to the pelvic cavity, in connection with a penetrating or nonpenetrating wound of its floor, as the transversalis fascia does to the abdominal cavity under like conditions.

The pelvic cavity is shallow in front and deep behind. Its posterior wall curves, first downward and backward, and then downward and slightly forward. At its superior opening the cavity is cordate and wide; below this point it is nearly circular and its outlet (*inferior aperture*) is irregular and narrow. Therefore, the cavity is an inverted, irregular, truncated cone, bent upon itself so that

the concavity of the curve is directed forward. This cone becomes greater in circumference, and then rapidly tapers to the pelvic outlet (*inferior aperture*).

The **axis** of the pelvic cavity is a line, curved in conformity with the curve of the sacrum and coccyx, which passes through the center of the planes of the inlet (*superior aperture*) and the outlet (*inferior aperture*) and through the center of a series of planes set between these.

The **pelvic inclination** is such that in the erect posture, the anterior superior iliac spine and the symphysis pubis lie in the same vertical plane and the plane of the superior aperture forms an angle of fifty degrees to sixty degrees with the horizontal plane.

Several other measurements are of importance. The **intercrestal,** which is the greatest distance between the external lips of the iliac crests, is about twenty-nine centimeters (eleven and a half inches) in the male and twenty-seven centimeters (eleven inches) in the female. The **interspinous** diameter is the widest distance between the anterior superior iliac spines. It is about twenty-four centimeters (nine and a half inches) in the male and approximately the same in the female. The external anteroposterior (external conjugate) is the measurement of the distance from the tip of the first sacral spine to the anterior surface of the symphysis. It is about eighteen centimeters (seven and a quarter inches) in the male and seventeen centimeters (seven inches) in the female.

Sexual Differences.—The arrangement of the peritoneum and fascia of the pelvic cavity differs in the two sexes in shape, in the distribution of the blood vessels, in the conformation of the muscles filling the outlet (*inferior aperture*), and in the contained generative organs. The bony pelves of the two sexes differ in several respects: the male pelvis is deeper; the muscular attachments are more marked; the bones are thicker; the symphysis pubis deeper; the pubic arch is narrower; and the obturator foramen is elliptic in shape, with the long diameter vertical. The female pelvis is lighter in weight and shallower, but larger in most of its measurements; the alæ of the ilia are broader and more widely separated, the bones are thinner, the symphysis pubis is more shallow, the pubic arch is wider, the tuberosities of the ischia are more widely separated, the sacrum is wider and less curved, and has a less projecting promontory, and the obturator foramen is approximately triangular in shape.

The contents of the pelvis in both sexes are: coils of the small intestine, the sigmoid flexure (*pelvic colon*), the rectum, bladder, ureters, vessels, nerves, fasciæ, and peritoneum. The male pelvis (Plates CCCCXL and CCCCXLI) contains the prostate gland, prostatic urethra, vasa deferentia (*ductus deferentes*), and seminal vesicles, as well as the structures found in the pelvis of both sexes. The

PLATE CCCCXL.

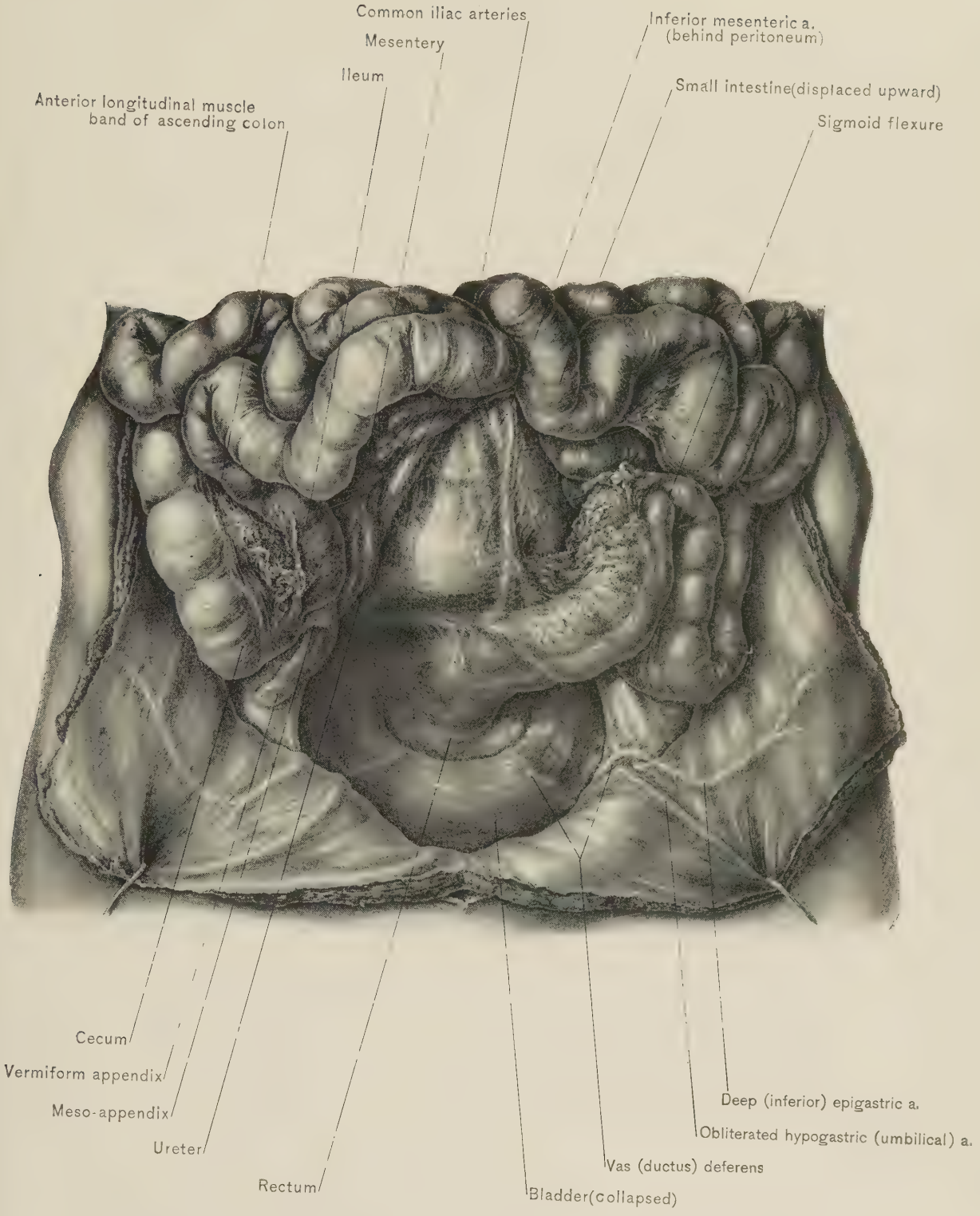

PELVIC CAVITY OF MALE—SUPERIOR VIEW.

PLATE CCCCXLI.

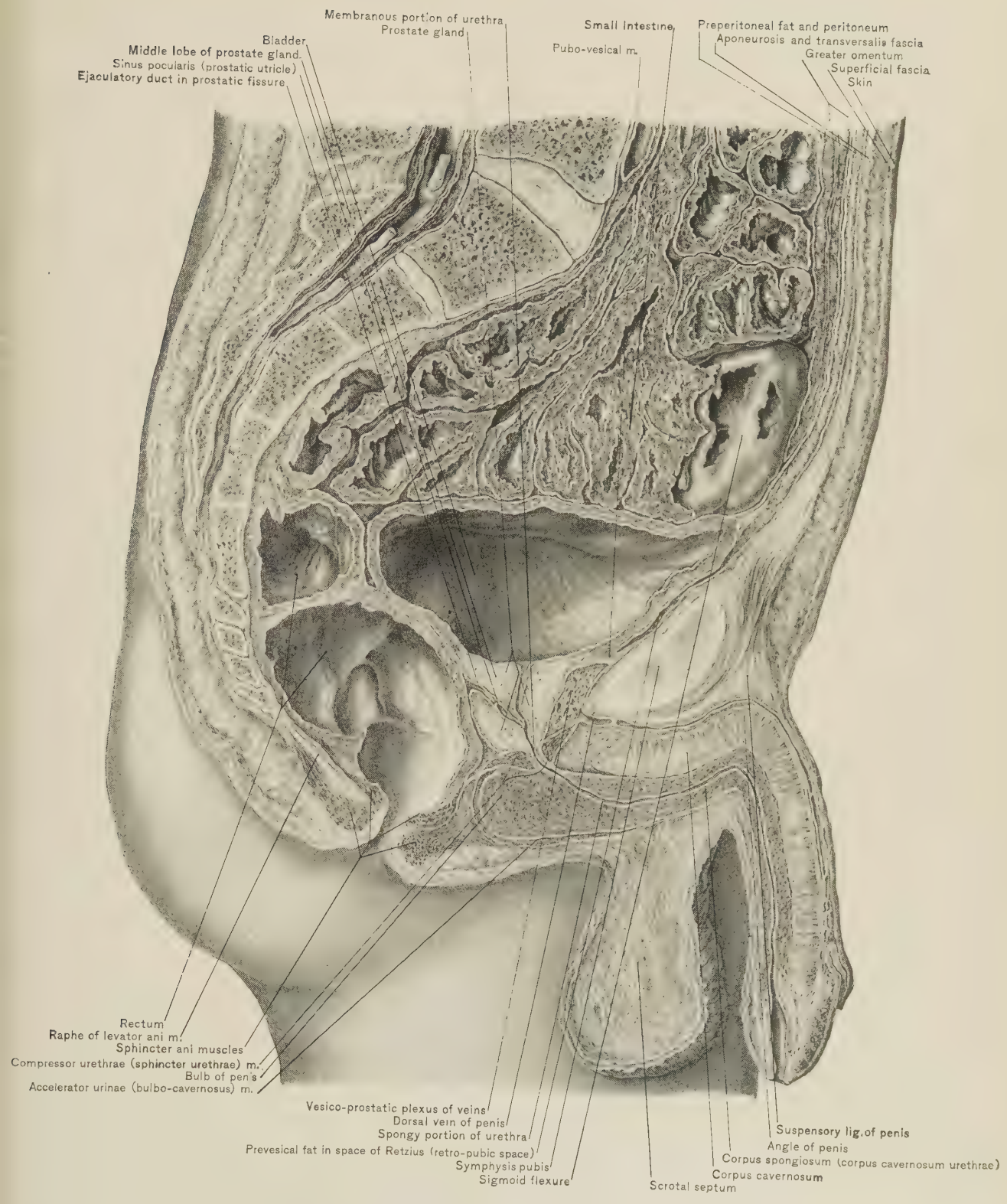

MALE PELVIS AND PERINEUM—SAGITTAL SECTION.

PLATE CCCCXLII.

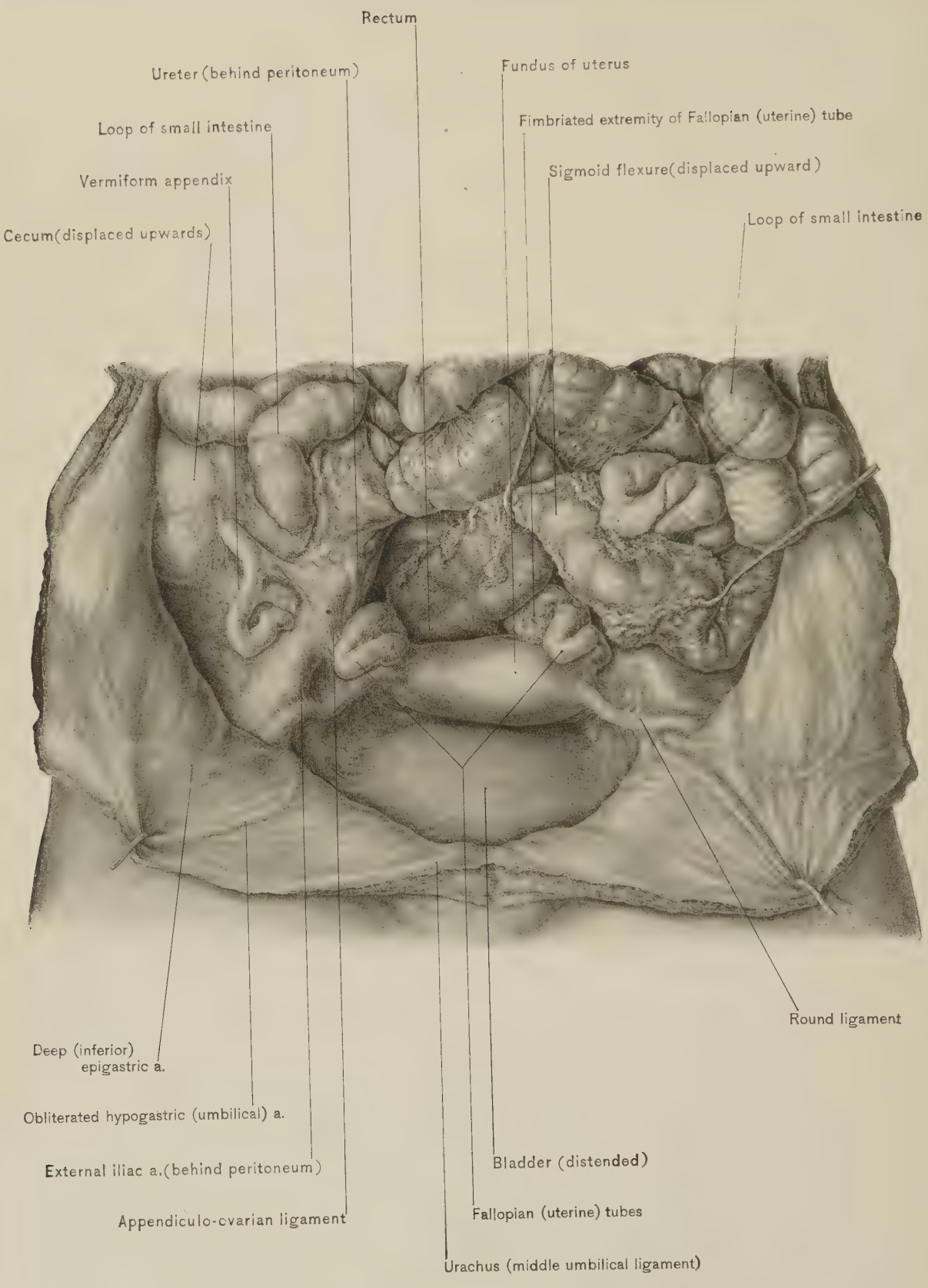

PELVIC CAVITY OF FEMALE—SUPERIOR VIEW

PLATE CCCCXLIII.

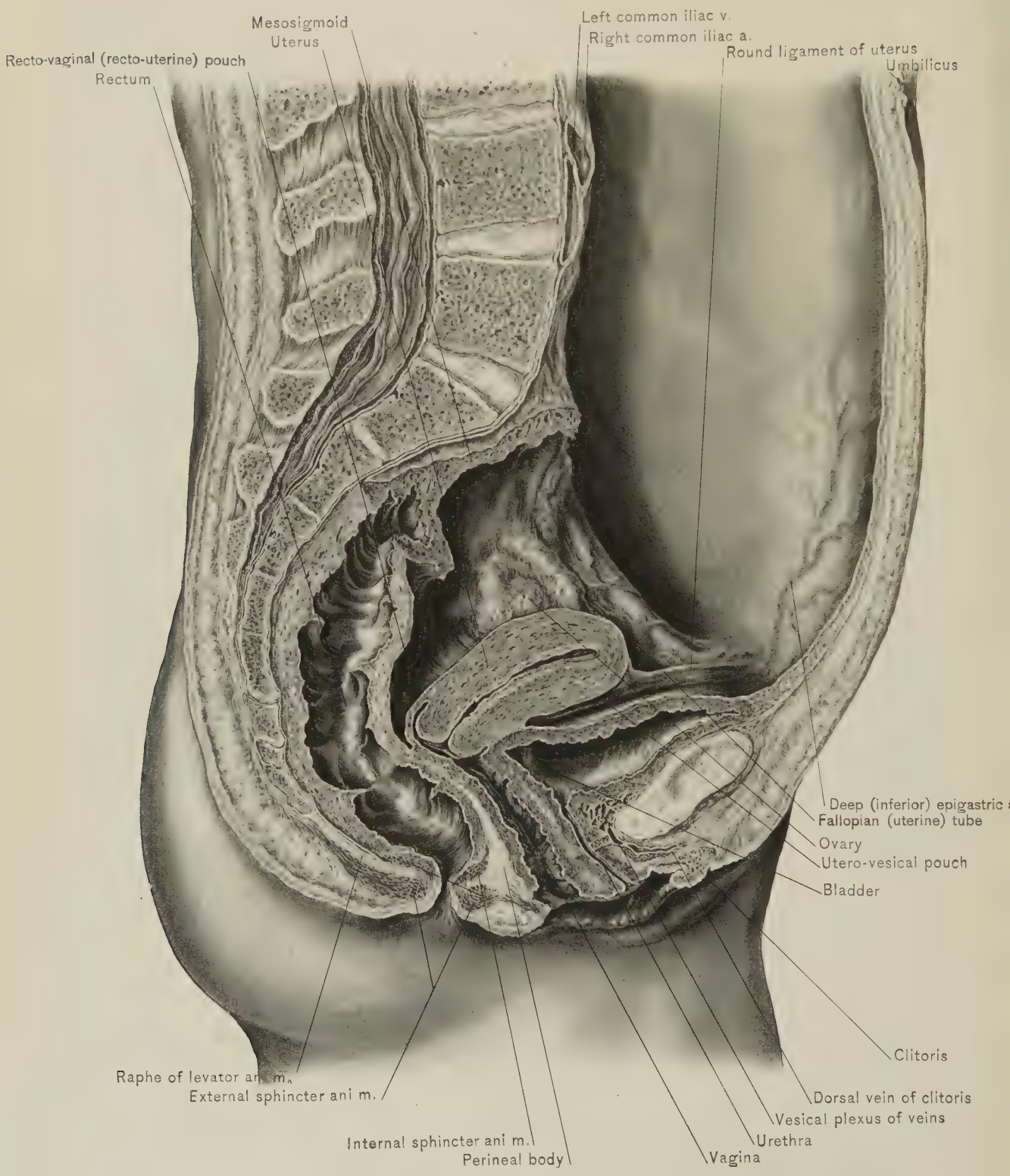

FEMALE PELVIS AND PERINEUM—SAGITTAL SECTION.

female pelvis (Plates CCCXLIII and CCCCXLIII) contains: the urethra, uterus, vagina, ligaments of the uterus, ovaries, and Fallopian (*uterine*) tubes.

The number of coils of the small intestine occupying the cavity depends largely upon the degree of distention of the bladder, and, to a slight extent, of the rectum and sigmoid flexure (*pelvic colon*). After displacing the smaller intestines and sigmoid flexure (*pelvic colon*), the rectum and bladder can be clearly seen.

The **sigmoid flexure** (**iliac and pelvic colon**) as described under the dissection of the abdominal cavity proper, chiefly occupies the left side of the pelvis, as a loop which is suspended from the left side of the posterior abdominal wall.

The **rectum** has been described as divided into three parts, the first part, however, is commonly included with the sigmoid flexure (*pelvic colon*). The rectum commences opposite the middle piece of the sacrum slightly to the left side of the median line, follows the concavity of this bone and of the coccyx, lying behind the bladder, seminal vesicles and prostate in the male, and the uterus and vagina in the female, ending in the median line of the perineum as the anus.

The **bladder** occupies the forepart of the pelvis, being situated between the pubic bones and the rectum in the male, and between the pubic bones in front and the uterus and vagina behind in the female.

Lying below the neck of the male bladder is the **prostate gland,** the apex of which rests against the superior layer (*superior fascia*) of the triangular ligament (*urogenital diaphragm*). The posterior surface of the prostate is in relation with the anterior wall of the rectum, from which it is separated by connective tissue and unstriped muscle fibers. It surrounds the first, or prostatic, portion of the urethra.

Between the bladder and the rectum, and behind the prostate, are the **seminal vesicles** and the terminal portions of the **spermatic ducts** (**ductus deferentes**), the ducts lying between the vesicles. From the relation existing between the anterior wall of the rectum and the prostate gland, between the rectum and the seminal vesicles, and between the rectum and that portion of the bladder-wall which lies immediately above the prostate and between the seminal vesicles, called the bas fond of the bladder, it follows that much can be learned about the prostate, the seminal vesicles, and the bas fond upon introducing the finger into the rectum. The bas fond of the bladder was formerly a favorite point for tapping the bladder in retention of urine by carrying a curved trocar into the rectum and thrusting it through the walls of the rectum and bladder immediately above the base of the prostate which was the guide in the operation.

In the female pelvis the cavity between the rectum and the bladder (recto-vesical pouch) is subdivided into a recto-vaginal and utero-vesical pouch by the **uterus,** the **broad ligaments,** and upper part of the **vagina.** The **ovaries** are

seen projecting from the posterior surface of the broad ligaments, and the **Fallopian (uterine) tubes** are located in the upper or free margin of those ligaments.

In the dissection of the contents of the pelvis the best idea of the relation of its contents is most conveniently obtained by examining them in the following order: peritoneum, pelvic fascia, blood-vessels, viscera, nerves, muscles, and lymphatics.

The **peritoneum** in the male, in its descent into the pelvis from the abdominal cavity proper, covers the front and sides of the first portion of the rectum, from which it is reflected to the bladder, covering the posterior wall, the sides, and the fundus of this organ. The reflection from the rectum to the bladder forms the **recto-vesical pouch,** the sides of which constitute the **posterior false ligaments of the bladder** (**sacro-genital folds**), and contain the obliterated hypogastric (*umbilical*) arteries, the vesical arteries, the ureters, and some sympathetic nerves. The pouch is pyramidal in outline, with the base directed upward and the apex downward. The apex of the pouch corresponds to a line connecting the ureters where they enter the bladder-wall. The lowest part of the pouch is ordinarily about seven and a half centimeters (three inches) from the anus; but it is readily seen how this distance can be increased or lessened by distention or collapse of the rectum and the bladder. So far as its relation to the rectum is concerned, it corresponds to the recto-uterine pouch, or Douglas' culdesac in the female.

From the sides of the bladder the peritoneum is reflected to the lateral walls of the pelvis, forming the **lateral false ligaments of the bladder;** and from the summit it is reflected over the urachus and the terminal portion of the obliterated hypogastric (*umbilical*) arteries to the anterior abdominal walls, forming the **superior false ligament** of the organ. The names are in reality unnecessary since these are merely folds of peritoneum. By drawing the bladder well forward and upward the posterior (*sacro-genital folds*) and lateral false ligaments are put on the stretch and can be clearly seen. The superior false ligament can also be well demonstrated by making traction in an upward direction on the anterior parietal peritoneum at the umbilicus. The arrangement of the peritoneum on the bladder affords the surgeon the opportunity of opening the bladder by carrying an incision through the abdominal walls, as in the operation of suprapubic cystotomy, without wounding that membrane. This arrangement of the peritoneum also permits of extraperitoneal rupure of the bladder and consequent extraperitoneal urinary extravasation. When **extraperitoneal urinary extravasation** takes place within the abdominal walls, if recognized early, the case may be brought to a favorable issue by opening up the prevesical space, irrigating, and draining it.

PLATE CCCCXLIV.

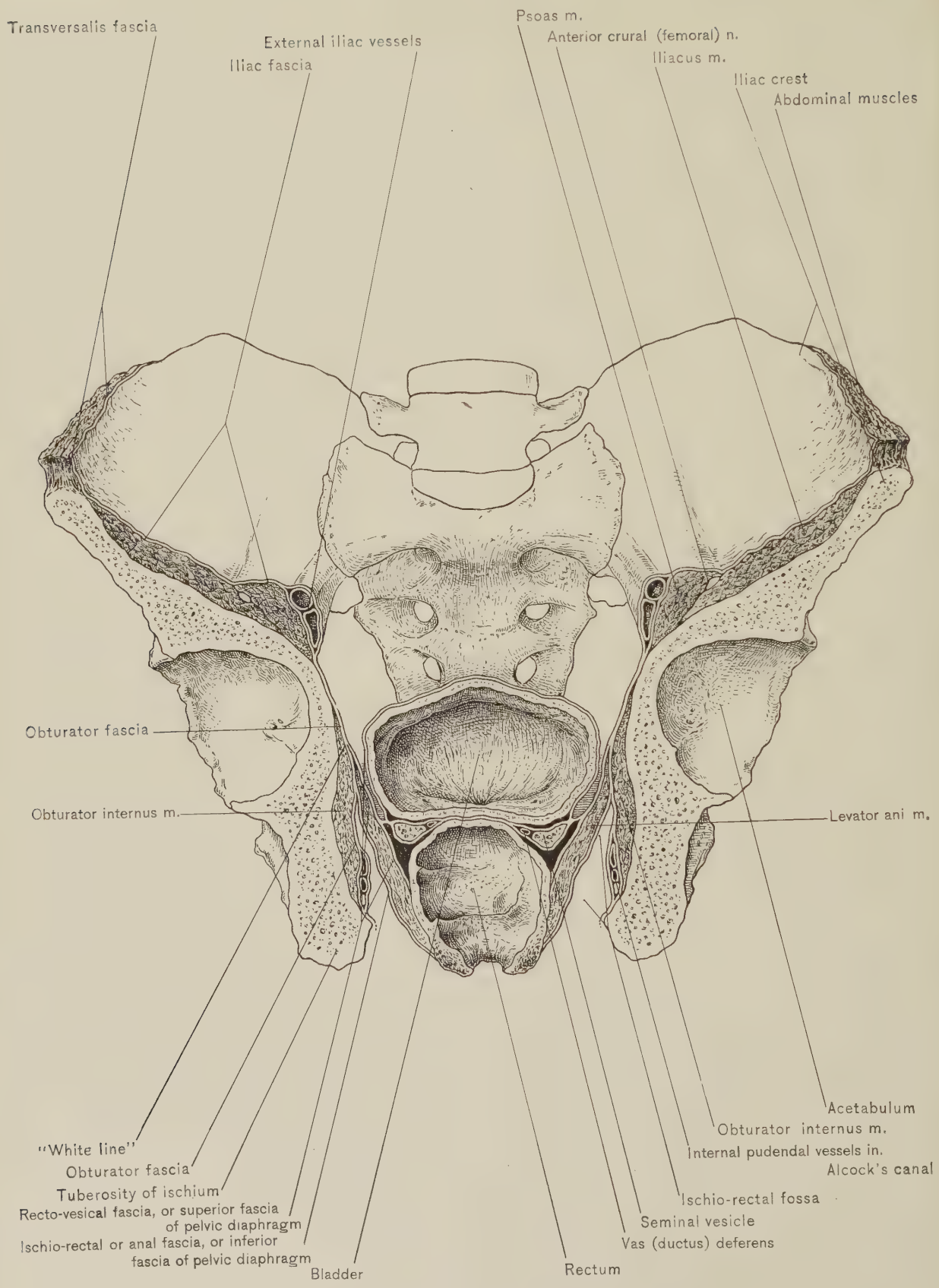

DIAGRAM OF PELVIC FASCIA.

In extraperitoneal rupture of the bladder, the best possible drainage is obtained by opening the prevesical space, and doing a suprapubic cystotomy and draining the bladder while at the same time the rent in the bladder may be sutured. The prevesical space is best drained by reaching it above Poupart's (*inguinal*) ligament and to the lateral side of the external iliac vessels.

For **intraperitoneal rupture of the bladder** an abdominal section and repair of the rent in the bladder are required to prevent a fatal result from peritonitis. If the tear cannot be sewed up, the operator can only wash out and drain the peritoneal cavity. The chances of avoiding general infection of the peritoneum are improved by making a perineal as well as an abdominal section; thus drainage from below, which is favored by gravity, is secured at the membranous urethra.

In the female, the peritoneum is reflected from the rectum upon the posterior surface of the vagina and the uterus. It passes upward to the fundus of the uterus, descends on the anterior surface of that organ to the beginning of the cervix uteri, and is reflected upon the bladder. At the sides of the uterus, the peritoneum turns over the Fallopian (*uterine*) tubes and ovaries and doubles upon itself, forming the broad ligaments of the uterus. Thus the intraperitoneal space in the female pelvis is subdivided into two parts by the uterus and the broad ligaments, the portion between the rectum and uterus being the recto-vaginal, or Douglas' pouch, and that between the uterus and bladder the utero-vesical pouch.

Dissection.—In order to study the pelvic fascia the peritoneum must be removed from one side by separating it from the extraperitoneal connective tissue with the finger. The layer covering the same side of the bladder must also be removed. After the peritoneum has been stripped off, a quantity of loose extra-peritoneal fatty tissue will be seen. This should be scraped away either with the finger or the handle of the scalpel, great care being taken to keep the fascia intact at the sides of the pelvis, where it is very thin. In the pelvis of the female the structures between the layers of the broad ligament should be preserved.

The **pelvic extraperitoneal connective tissue** is frequently inflamed as a result of inflammation of one of the adjacent pelvic viscera, most commonly of the uterus and the Fallopian (*uterine*) tubes. The condition is called **pelvic cellulitis,** and may lead to abscess formation. These abscesses are usually unable to descend and make an exit in the perineum, because they are unable to pass through the recto-vesical fascia. They must, therefore, ascend; and a large per-centage of them open near Poupart's (*inguinal*) ligament, in the inguinal region.

The **pelvic fascia** (Plate CCCCXLIV) consists of continuous layers of white fibrous tissue; it lines the pelvic cavity and forms a subserous covering for parts of the pelvic organs and a retentive sheath for others. In front, it is continuous

with the transversalis fascia; and on the sides, with the iliac fascia. Superiorly, it is attached to the body of the pubis, to the brim of the pelvis (ilio-pectineal line), and to the innominate bone above the attachment of the obturator internus muscle. It then spreads over the pyriformis muscle as a thin layer taking the name of the **fascia of the pyriformis.** It is gradually lost over the anterior surface of the sacrum. Above the obturator internus muscle it bridges a groove on the internal surface of the bone above the obturator foramen and converts it into a canal through which pass the obturator vessels and nerve. Anteriorly, it is attached to the posterior surface of the symphysis pubis. In its descent over the obturator internus muscle, it divides into the obturator and the recto-vesical (*superior fascia of the pelvic diaphragm*) fasciæ. This division is marked by a dense **white line** (**arcus tendineus**), which is on the level of a line drawn from the spine of the ischium to the posterior surface of the body of the pubis, just lateral to the lower part of the symphysis pubis.

The **obturator fascia** is the lateral division and continuation of the pelvic fascia. It extends downward from the white line over the obturator internus muscle and is attached to the innominate bone at the lower margin of the muscle. Above, it is continuous with the pelvic fascia; below, it is attached to the tuberosity of the ischium, and the rami of the pubes and ischium, and the margin of the great sacro-sciatic (*greater sciatic*) notch. In front, it is attached to the posterior surface of the pubic bones, in a line drawn downward and medialward from the upper anterior part of the obturator foramen to the lower part of the symphysis pubis; and behind, it extends into the gluteal region with the obturator internus muscle through the lesser sacro-sciatic (*lesser sciatic*) notch. It assists in forming the lateral wall of the ischio-rectal fossa, and contains Alcock's canal which transmits the internal pudendal vessels and nerve. As the obturator is a continuation of the pelvic fascia, and as both fasciæ cover the obturator internus muscle, some authors have described the pelvic fascia as the upper segment of the obturator fascia. The obturator fascia gives off two processes: the *superior layer of the triangular ligament* (*superior fascia of the urogenital diaphragm*) and the *ischio-rectal* or *anal fascia* (*inferior fascia of the pelvic diaphragm*). If the pelvic fascia is considered as the upper segment of the obturator fascia, the recto-vesical fascia (*superior fascia of the pelvic diaphragm*) is also a process of the obturator fascia. The superior layer of the triangular ligament (*superior fascia of the urogenital diaphragm*) is a fascial partition derived from the lower part of the obturator fascia, and passes medialward above the compressor (*sphincter*) urethræ muscle to join the corresponding layer of the opposite side. For further description, see the Perineum at p. 672.

The *ischio-rectal* or *anal fascia* (*inferior fascia of the pelvic diaphragm*), which lines the perineal surface of the levator ani muscle, is derived from the obturator fascia. Medially, it is lost upon the external sphincter ani muscle; in front, it is continuous with the superior layer of the triangular ligament (*fascia superior of the urogenital diaphragm*); and behind, it is continuous with the fascia upon the deep surface of the gluteus maximus muscle.

The **recto-vesical fascia** (**superior fascia of the pelvic diaphragm**), the visceral layer of the pelvic fascia, extends downward and medialward upon the superior surface of the levator ani muscle. Anterior to the rectum, the fasciæ of the two sides meet to complete the fascial partition between the perineum and the pelvic cavity, thus forming a barrier which hinders the passage of pus or extravasated urine from the perineum to the pelvis. Anteriorly it is attached to the posterior surface of the pubic bones, above the levator ani muscle and the obturator fascia; behind, it is continuous with the fascia of the pyriformis and laterally it is attached to the pelvic fascia above the origin of the levator ani muscle. Medially, it is continuous with the fibrous coat of the rectum and bladder, and forms the capsule of the prostate; when it reaches the bladder, it divides into two layers. The upper layer forms the fibrous coat of that viscus and the lower surrounds the prostate gland as a capsule, and also covers the seminal vesicles and the ejaculatory ducts. At and anterior to the apex of the prostate the recto-vesical fascia (*superior fascia of the pelvic diaphragm*) and the superior layer of the triangular ligament (*superior fascia of the urogenital diaphragm*) are so blended as to be inseparable.

The bands of the recto-vesical fascia which pass from the lower part of the pubic bones to the prostate and neck of the bladder are called the *pubo-prostatic*, or *anterior true, ligaments*, and the bands of this fascia which pass from the sides of the pelvis to the sides of the bladder are the *lateral true ligaments* of the bladder. The portion of the fascia attached to the rectum is sometimes called the ligament of the rectum.

In the female the recto-vesical fascia is reflected upon the uterus and the vagina and sends a prolongation over the latter.

Arteries of the Pelvis.—The arteries of the false pelvis are the *common* and the *external iliac arteries*. The arteries of the true pelvis are the *internal iliac* (*hypogastric*) *and its branches*.

The **common iliac arteries** begin at the bifurcation of the aorta on the front of the body of the fourth lumbar vertebra, a little to the left of the median line and terminate opposite the uppr margin of the sacro-iliac synchondrosis by dividing into the external iliac and internal iliac (*hypogastric*) arteries. The upper third of a line drawn from a point one centimeter (one-half inch) below and to the

left of the unbilicus to a point midway between the anterior superior iliac spine and the symphysis pubis, corresponds to the common iliac. The lower two-thirds of the line marks the line of the external iliac.

The *right common iliac artery* is the longer, owing to the bifurcation of the aorta to the left of the median line. It measures about five centimeters (two inches) in length.

Relations.—Anteriorly it is covered with peritoneum, and is crossed by the ovarian artery in the female, the termination of the ileum, sympathetic nerves to the hypogastric plexus, and, just before its bifurcation, by the ureter. On the left side the superior hemorrhoidal and sigmoid vessels also lie on the vessel. Posteriorly it is in relation with the right common iliac vein, the end of the left common iliac vein, and the beginning of the inferior vena cava. On the right side lie the beginning of the inferior vena cava, the termination of the right common iliac vein, and the psoas muscle. On the left side lie the termination of the left common iliac vein, the right common iliac vein, and the hypogastric plexus.

The *left common iliac artery* is four centimeters (one and three-fourths inches) long, a little shorter, but thicker, than the right.

Relations.—Anteriorly the ureter and, in the female, the ovarian artery cross it near its bifurcation; it is also in relation in front with the sympathetic nerves descending to the hypogastric plexus, the sigmoid flexure (*iliac and pelvic colon*), and the mesosigmoid (*pelvic mesocolon*). Behind it are the bodies of the fourth and fifth lumbar vertebræ, and the intervening cartilaginous disc, the left common iliac vein, and the psoas major muscle. To the left is the psoas muscle. To the right are the left common iliac vein, the hypogastric plexus, and the sacral artery, whle posteriorly but some distance away are the ilio-lumbar artery, the lumbo-sacral plexus, and the obturator nerve.

The common iliacs may be very short, one and a quarter centimeters (one half inch), or very long, eleven and a half centimeters (four and a half inches). The average length is between two and a half and seven and a half centimeters (one inch and three inches); or the common iliac arteries may be absent; in that case the external iliac and internal iliac (*hypogastric*) arise directly from the aorta.

Branches.—Each common iliac artery gives off a few small twigs to the peritoneum and extraperitoneal connective tissue, also a few to the ureter but the only branches of any consequence are its terminal divisions: the external iliac and internal iliac (*hypogastric*) arteries.

The left common iliac artery can be more readily ligated, owing to its relations. The operation of ligation may be done either extra- or transperitoneally, the latter method being more commonly employed. An incision about fifteen centimeters (six inches) in length is made usually in either semilunar line or

PLATE CCCCXLV.

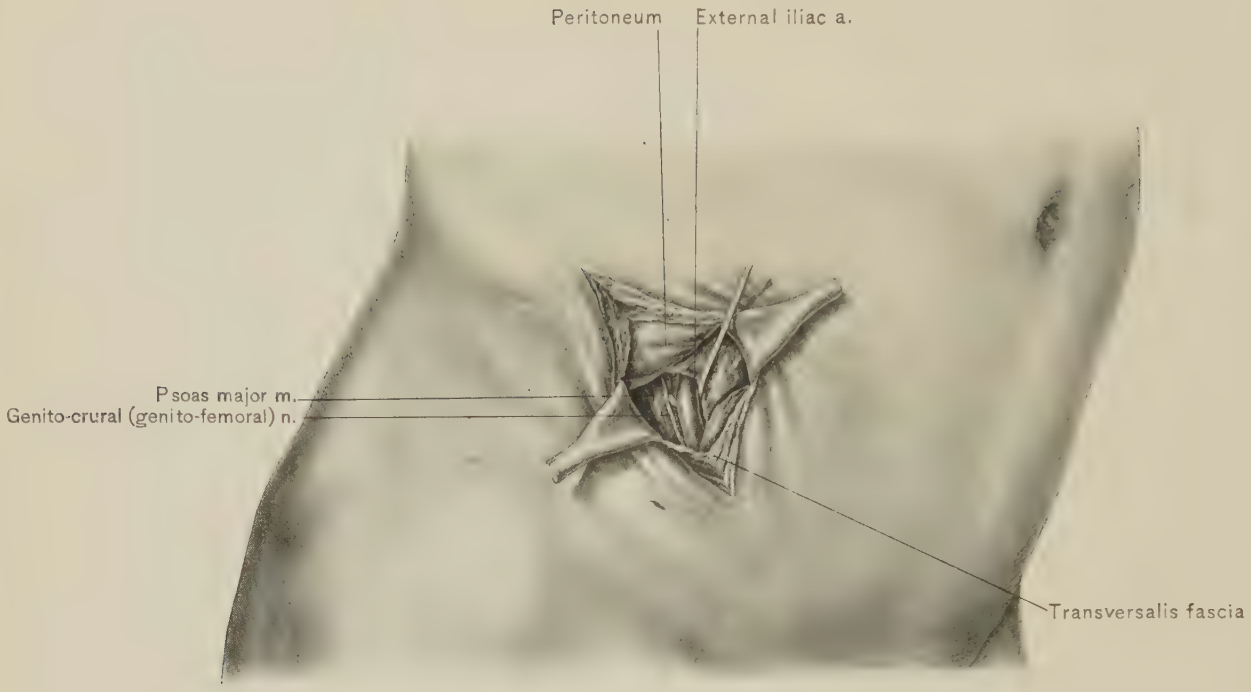

A

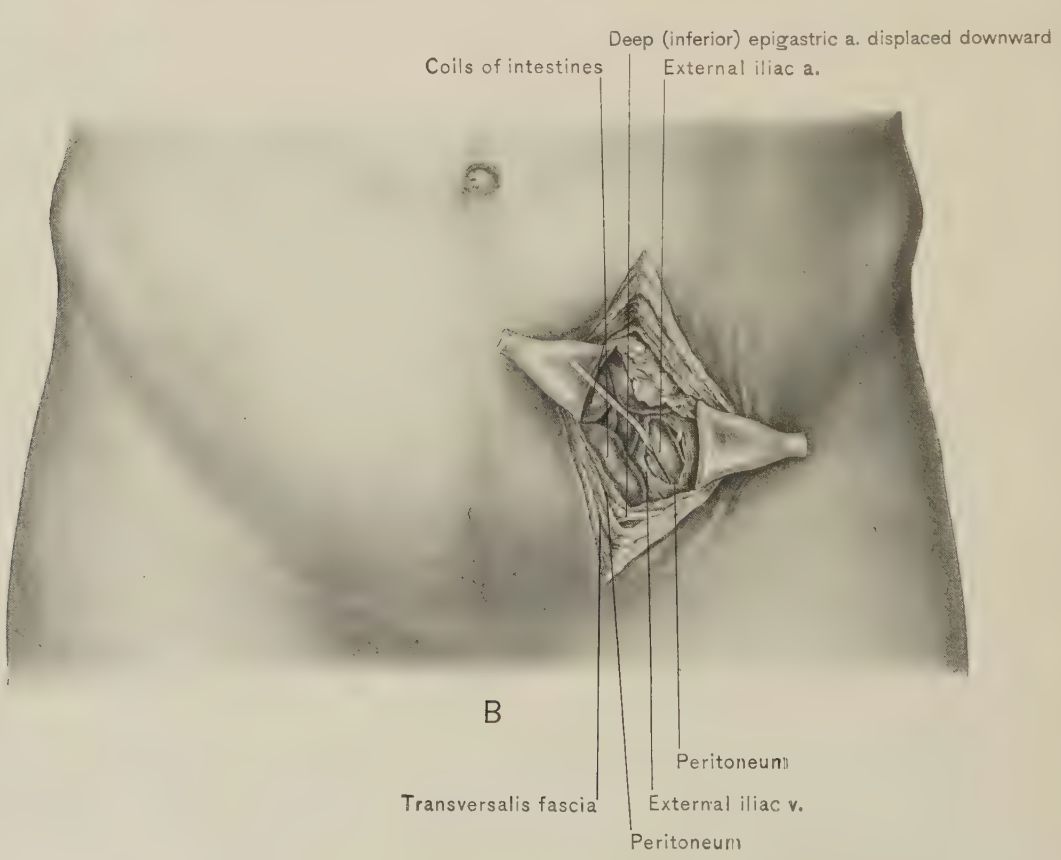

B

LIGATION OF EXTERNAL ILIAC ARTERY.

(A) EXTRAPERITONEAL METHOD. (B) TRANSPERITONEAL METHOD.

through either rectus muscle, extending from the level of the umbilicus nearly to the symphysis pubis. The abdomen being opened, the peritoneum covering the artery is incised and the needle passed mediolaterally on the left side and lateromedially on the right, away from the vein. The ureters must be avoided, and on the left side also the superior hemorrhoidal artery. The internal iliac (*hypogastric*) artery may be approached through the same incision and ligated. The vein has been ligated in cases of septic thrombosis.

The **collateral circulation** after ligation of the common iliac artery is established by the anastomosis between the lateral and middle sacral arteries, the former being branches of the posterior division of the internal iliac (*hypogastric*); the internal mammary and the deep (*inferior*) epigastric; the lumbar branches of the aorta and the ilio-lumbar and deep circumflex iliac; the deep (*inferior*) epigastric and obturator by their pubic branches; the hemorrhoidal arteries; the uterine and ovarian arteries; posterior sacral branches and the gluteal (*superior gluteal*); and between the vesical, hemorrhoidal, uterine, vaginal, obturator, and lateral sacral arteries and their fellows of the opposite side.

The **external iliac artery** is the direct continuation of the common iliac artery. It begins at the bifurcation of the latter at the sacro-iliac synchondrosis and runs along the brim of the true pelvis to Poupart's (*inguinal*) ligament, terminating at a point midway between the anterior superior spine of the ilium and the symphysis pubis behind Poupart's (*inguinal*) ligament, where it becomes the *femoral artery*. The external iliac artery is about eight to ten centimeters (three and a half to four inches) in length. Its course can be indicated on the surface by drawing a curved line, with its convexity lateralward, from the bifurcation of the aorta twelve millimeters (one-half inch) below and to the left of the umbilicus to a point midway between the anterior superior spine of the ilium and the symphysis pubis (Plate CCCCXLV).

Relations.—Like the common iliac, it lies behind the peritoneum. It is also covered by a condensed portion of extraperitoneal connective tissue, known as Abernethy's fascia. Anteriorly it comes in relation with the genital (*external spermatic*) branch of the genito-crural (*genito-femoral*) nerve, which crosses the lower third of the artery obliquely; and at its termination with the circumflex iliac vein, which crosses it to empty into the external iliac vein; also at its lower part with the spermatic (*internal spermatic*) vessels. The vas deferens (*ductus deferens*) and, in the female, the ovarian vessels cross it to gain the cavity of the pelvis, and the ureter sometimes passes in front of it, instead of crossing the common iliac artery. The external iliac lymphatic glands lie along the course of the artery.

Posteriorly, the artery comes in relation with its vein, in the upper part of its course, but in the lower part of its course the vein lies medial to it; then with

the medial border of the psoas muscle, and lower down, behind Poupart's (*inguinal*) ligament, with the tendon of the psoas. The iliac fascia lies behind it.

On its medial side are the external iliac vein, the peritoneum, the iliac fascia descending to become the pelvic fascia, the vas deferens (*ductus deferens*) in the male, and the ovarian vessels in the female. The right external iliac vein at first ies to the medial side of its artery, but gradually passes behind the latter. On its lateral side are the genito-crural (*genito-femoral*) nerve, the psoas muscle, and the iliac fascia.

The external iliac artery may vary somewhat in length. It may be either shorter or longer than normal, depending upon the low or high bifurcation of the common iliac artery. When long, a loop of it may extend into the cavity of the pelvis. It may also be smaller in size than normal, especially when the femoral arises from some branch of the internal iliac (*hypogastric*) artery, usually the sciatic (*inferior gluteal*) artery, in which case it may end in the profunda femoris.

The branches of the external iliac artery are the deep (*inferior*) epigastric, the deep circumflex iliac artery, and a few small branches to the psoas muscle and lymphatic glands.

The **deep (inferior) epigastric artery** arises from the external iliac artery, as a rule close to Poupart's (*inguinal*) ligament, but may arise several centimeters higher up; or it may even arise from the femoral below Poupart's (*inguinal*) ligament, and sometimes from the profunda femoris artery. It frequently gives off the deep circumflex iliac artery, or an **abnormal obturator** artery; occasionally it arises from the obturator artery. Sometimes it is found to be double. This artery has been described with the structures of the abdominal wall.

The **deep circumflex iliac artery** arises from the lateral side of the external iliac artery close to Poupart's (*inguinal*) ligament and passes lateralward and upward to the anterior superior iliac spine between the transversalis fascia and peritoneum, or in a sheath-like canal formed by the junction of the transversalis and iliac fasciæ. It perforates the transversalis fascia and the transversalis (*transversus abdominis*) muscle near the anterior superior iliac spine and then runs between the transversalis (*transversus abdominis*) and internal oblique muscles, along the crest of the ilium, dividing into an ascending branch which anastomoses with the lumbar and intercostal arteries, and an iliac or marginal branch which anastomoses with the ilio-lumbar artery.

The deep circumflex iliac artery may arise in common with the deep (*inferior*) epigastric or rarely from the femoral. Like the epigastric, it may be given off higher up than normal, but generally a little below that vessel, or it may be double.

PLATE CCCCXLVI.

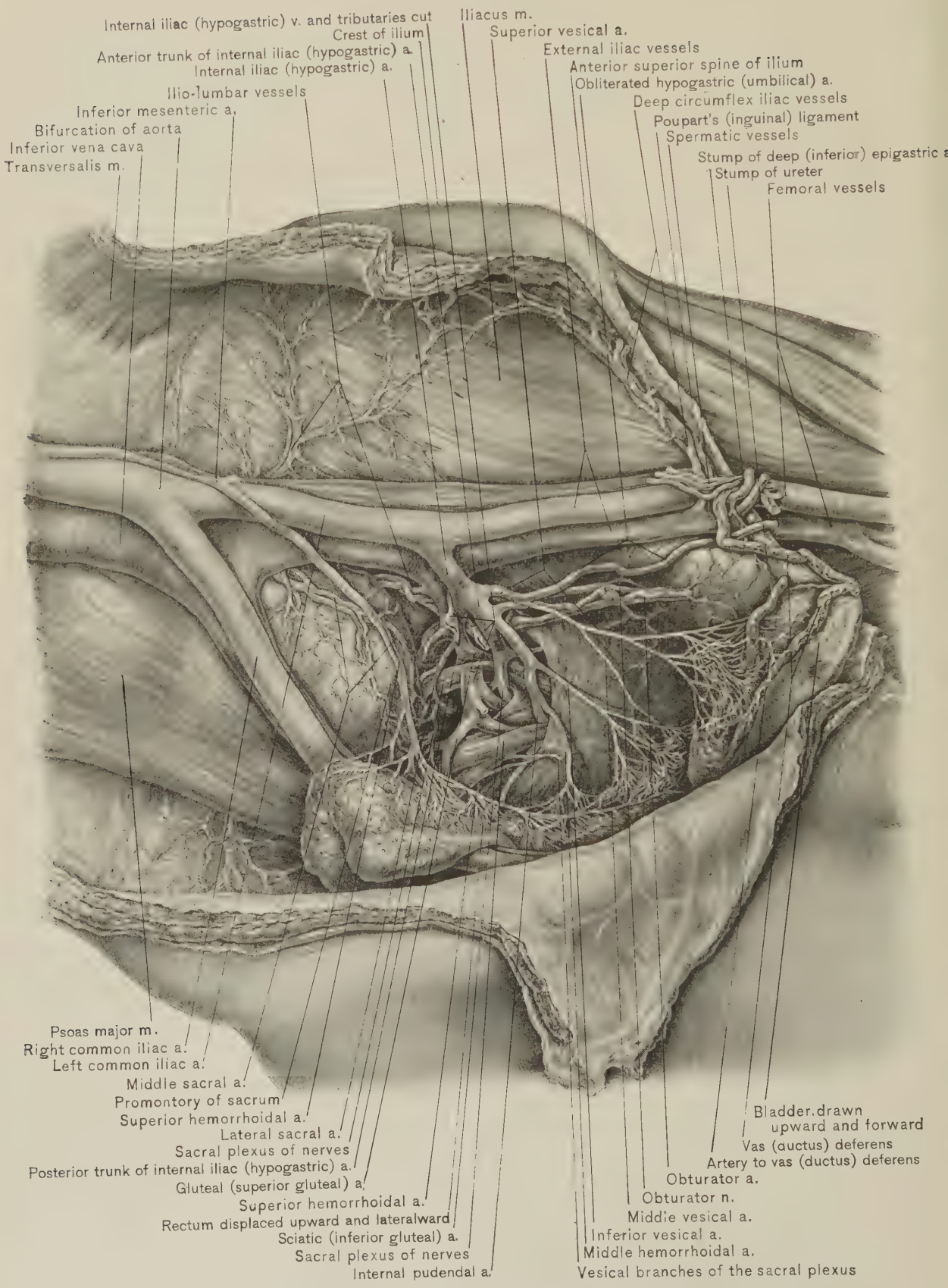

INTERNAL ILIAC (HYPOGASTRIC) ARTERY AND ITS BRANCHES.

The companion veins of this artery usually empty by a single trunk, which crosses the lower portion of the external iliac artery, into the external iliac vein, but may join the deep (*inferior*) epigastric vein.

The **internal iliac (hypogastric) artery** (Plate CCCCXLVI) is short, thick, and smaller than the external iliac. It is two and a half to four centimeters (one to one and a half inches) in length, and arises as one of the two terminal branches of the common iliac artery, at the upper margin of the sacro-iliac synchondrosis on the medial border of the psoas muscle. It descends downward and backward for about three and a half centimeters (one and a half inches) into the pelvis, in the extraperitoneal fat, and just above the upper margin of the great sacro-sciatic (*greater sciatic*) notch divides into an anterior and a posterior branch. It is an interesting fact that the combined length of the common and internal iliac (*hypogastric*) arteries is uniform, so that a greater length of one entails shortening of the other.

Relations.—It rests posteriorly upon the internal iliac (*hypogastric*) vein, the lumbo-sacral cord, and the pyriforims muscle, and is crossed on its medial side by the ureter, and covered by peritoneum; the psoas major muscle and termination of the external iliac vein lie upon its lateral side.

During fetal life the internal iliac (*hypogastric*) is twice as large as the external, and appears to be the direct continuation of the common iliac. It does not dip into the pelvis, but passes to the bladder and along its side to the summit, from which it extends along the anterior wall of the abdomen to the umbilicus, through which it passes to the placenta. While within the abdominal cavity the vessel is known as the *hypogastric artery*, after passing through the umbilicus, it becomes the *umbilical artery*. The umbilical arteries wind around the umbilical vein, helping to form the umbilical cord, and are distributed to the placenta. After the placental circulation has ceased, all but a short portion of the lower end of the hypogastric artery becomes obliterated and forms the obliterated hypogastric artery or lateral umbilical ligament. The proximal end becomes greatly reduced in size and forms the root of the superior vesical artery.

The *anterior trunk of the iliac (hypogastric) artery* gives off visceral and parietal branches. The visceral branches are the superior vesical, middle hemorrhoidal; and in the female the uterine, and vaginal; and in the male the inferior vesical. The parietal branches are the obturator, internal pudendal, and sciatic (*inferior gluteal*) arteries.

The *posterior trunk of the internal iliac (hypogastric) artery*, shortly after the bifurcation of the parent stem, gives off, from its posterior surface, an ascending branch, the *ilio-lumbar;* and, below this, the two *lateral sacral arteries*. It then emerges from the pelvis as the *gluteal (superior gluteal) artery*.

The **superior vesical artery** begins as a trunk which is large in proportion to the branches given off. This portion of the artery is the patulous part of the hypogastric artery, which, even in the adult, appears to be the continuation of the trunk of the internal iliac (*hypogastric*). It supplies the summit and the upper part of the bladder. It gives off a branch to the vas deferens (*ductus deferens*), known as the *artery of the vas deferens* (*ductus deferens*); twigs to the urachus and ureter; its most posterior branch, the *middle vesical artery*, descends to the base of the bladder and adjacent under-surface of the seminal vesicle. This latter vessel may be given off from the unobliterated trunk of the hypogastric artery.

The **inferior vesical and the middle hemorrhoidal arteries** frequently arise by a common trunk from the anterior trunk of the internal iliac (*hypogastric*). The **inferior vesical artery** runs forward upon the levator ani to the base of the bladder, the seminal vesicle, the ureter, and the prostate, the last inosculating with the prostatic branches of the other side. Sometimes one of these prostatic branches is large and supplies parts normally supplied by the internal pudendal; it is then known as an accessory pudendal artery. In the female the inferior vesical artery gives off vaginal branches. The artery to the vas deferens (*ductus deferens*) may arise from the inferior instead of the superior vesical artery. The **middle hemorrhoidal artery** runs medially on the levator ani to go to the rectum, there anastomosing above with the superior hemorrhoidal from the inferior mesenteric, and below with the inferior hemorrhoidal from the internal pudendal artery. It is through this anastomosis that an infection around the anus may infect the portal circulation.

The **uterine artery** (Plate CCCCXLVII) arises from the anterior division of the internal iliac (*hypogastric*) just below or in common with the vaginal or middle hemorrhoidal, and passes downward and medialward on the levator ani toward the cervix uteri. It crosses in front of the ureter one to one and a half centimeters (one-third to three-fifths of an inch) from the cervix uteri. It then turns upward, and ascends in a tortuous course between the layers of the broad ligament and on the side of the uterus. It sends numerous branches at a right angle to its course to spread over both surfaces of the uterus in a tortuous manner, and anastomoses with the uterine branch of the ovarian artery. The *cervical branch* of the uterine artery springs from that vessel as it crosses the ureter. It passes directly medialward and divides into four or five branches, one of which anastomoses with the cervical artery of the opposite side so as to form the *circular artery of the cervix*. Other branches anastomose with branches of the vaginal to form the azygos arteries of the vagina, which run along the median line of the vaginal wall, one lying in front and the other behind. In hysterectomy the uterine

PLATE CCCCXLVII.

artery should be tied less than one centimeter (half an inch) from the cervix to avoid the ureter. The artery should be exposed and ligated under the eye and the needle carrying the suture should be inserted against the uterus and not away from it.

The **vaginal arteries** arise from the internal iliac (*hypogastric*), although one or more of them may arise in common with the uterine, or the middle hemorrhoidal artery. The vaginal artery is often described as corresponding to the inferior vesical in the male. As a rule, there are only two; but there may be three, or even four. They run anteriorally on the levator ani to pass to the sides of the vagina to supply its walls, and then anastomose with each other, with branches from the other side, and with branches of the uterine artery. The anastomoses with the branches of the uterine artery form two vertical trunks along the median line of the vagina, one of which is upon its anterior, and the other upon its posterior, wall. These are known as the *azygos arteries of the vagina.* The lowermost branches extend to the vestibule, where they communicate with the bulbal branch of the internal pudenal artery. Small branches from the vaginal arteries pass to the rectum.

The **obturator artery** arises from the anterior trunk of the internal iliac (*hypogastric*), although it may be a branch of the posterior trunk. It runs downward and forward along the lateral wall of the pelvis below its brim to the upper part of the obturator foramen, through which it passes in company with its vein and the obturator nerve. It lies between the obturator nerve which is above and in front of it, and the vein which is below and behind it. Like the other branches of the internal iliac (*hypogastric*), it runs in the extraperitoneal fat between the peritoneum and the fascia. It passes out of the pelvis through an opening at the upper part of the obturator foramen caused by a deficiency in the obturator membrane at that point, usually passing over the upper border of the pelvic fascia and not, as a rule, piercing it, as the other arteries do, in order to pass out of the pelvis. The nerves, however, lie on the outside of the pelvic fascia, and therefore do not pierce the fascia. Just before reaching the foramen the obturator vessels and nerve lie in the **obturator canal** which is formed by the pelvic fascia bridging over the groove in the medial surface of the horizontal ramus of the pubic bone. At this point it is crossed by the vas (*ductus*) deferens. Through this canal an obturator hernia may pass and not carry the pelvic fascia, obturator internus muscle, or obturator membrane with it. In the pelvis the obturator artery gives off *iliac, vesical,* and *pubic branches.* After it emerges from the obturator foramen it divides into an *anterior* and a *posterior branch.* The *iliac* (*muscular*) *branch* is a nutrient artery to the ilium, supplies the psoas and iliacus muscles, and anastomoses with the ilio-lumbar artery. The *vesical*

branches supply the bladder. The *pubic branch* passes upward behind the pubis, anastomoses with the pubic branch of the deep (*inferior*) epigastric artery and with the pubic branch of the obturator artery of the other side, and supplies the adjacent structures. This anastomosis may enlarge to form an **abnormal obturator** artery which replaces the normal artery. Outside of the pelvis the obturator artery divides into an *anterior* and a *posterior branch* which form a circle on the circumference of the obturator membrane and are described with the lower extremity. In one of every three cases the obturator artery arises from the deep (*inferior*) epigastric; occasionally, from both the deep (*inferior*) epigastric and internal iliac (*hypogastric*), and, rarely, from the external iliac just before it passes under Poupart's (*inguinal*) ligament to become the femoral. When it arises from the deep (*inferior*) epigastric artery, it may pass above and to the medial side of the femoral ring, so that it might be cut by a deep incision made for the relief of a constriction in femoral hernia, especially if during the operation Gimbernat's (*lacunar*) ligament is divided. Usually a small artery is then given off from the anterior trunk of the internal iliac (*hypogastric*), taking the usual course of the obturator artery. This is more fully treated in the description of the thigh under femoral hernia, to which the reader is referred. See Vol. II.

The **internal pudendal artery,** the smaller of the two terminal branches of the anterior trunk of the internal iliac (*hypogastric*) artery, passes downward, backward and lateralward in front of the sacral plexus and the pyriformis muscle to leave the pelvis at the lower margin of the greater sacro-sciatic (*greater sciatic*) foramen, where it pierces the fascia and passes between the pyriformis and coccygeus muscles. It then crosses the lateral surface of the spine of the ischium with its accompanying nerve and vein, under cover of the gluteus maximus muscle, and rëenters the pelvis through the lesser sacro-sciatic (*lesser sciatic*) foramen. With the vein and nerve, it crosses the obturator internus muscle, then lies in the lateral wall of the ischio-rectal fossa, and passes forward in Alcock's canal in the obturator fascia. The artery continues forward in this canal and over the obturator internus muscle to the ramus of the ischium. In this position the dorsal nerve of the penis is above it and the perineal nerve is below it. The artery then pierces the deep (*superior*) layer of the triangular ligament (*urogenital diaphragm*) of the urethra and then runs upward and forward between the layers of the triangular ligament (*urogenital diaphragm*) along the pubic arch in the substance of the compressor (*sphincter*) urethræ muscle to within one and a quarter centimeters (one-half inch) of the symphysis, where it pierces the anterior (*inferior*) fascia of the triangular ligament (*urogenital diaphragm*). Between the layers of the triangular ligament (*urogenital diaphragm*) it gives off the artery of the bulb and the artery of the corpus cavernosum, and then pierces

the superficial or anterior layer (*inferior fascia*) of the triangular ligament (*urogenital diaphragm*) and divides into the dorsal and deep arteries of the penis or clitoris. The artery of the bulb passes medialward and slightly upward in the substance of the compressor (*sphincter*) urethræ muscle, and upon reaching the urethra passes through an opening in the anterior or superficial layer (*inferior fascia*) of the triangular ligament (*urogenital diaphragm*) to be distributed to the bulb and the corpus spongiosum (*corpus cavernosum urethræ*). This artery should be avoided in the operation of lateral lithotomy. It is usually one centimeter (one half inch) above the central tendon of the perineum. The artery of the corpus spongiosum (*corpus cavernosum urethræ*) is given off higher up than the artery of the bulb; it runs along the ramus of the pubes, perforates the superficial layer (*inferior fascia*) of the triangular ligament (*urogenital diaphragm*) near the subpubic (*arcuate pubic*) ligament, and then enters the crus penis. In the female the artery ends in the crus clitoridis.

The dorsal artery of the penis is the continuation of the internal pudendal, and also pierces the anterior or superficial layer (*inferior fascia*) of the triangular ligament (*urogenital diaphragm*) close to the subpubic (*arcuate pubic*) ligament. It then passes between the two layers of the suspensory ligament of the penis, the single centrally placed vein separating it from the artery of the opposite side. The dorsal nerve of the penis lies on its lateral side, and still further laterally lies the deep external pudenal branch of the common femoral artery. At the glans the two dorsal arteries anastomose to encircle the corona. In the female the termination of the internal pudendal artery is called the dorsal artery of the clitoris.

Relations.—At first the internal pudenal artery lies anterior to the pyriformis muscle and the sacral plexus, and lateral to the rectum. It is covered by the gluteus maximus muscle and the great sacro-sciatic (*sacro-tuberous*) ligament as it crosses the spine of the ischium, and in a thin subject can be felt pulsating at this point. This point may be located by taking the spot at the junction of the medial third with the lateral two-thirds of a line drawn from the top of the great trochanter when rotated medialward, to the base of the coccyx. Next, it lies in a fibrous canal (Alcock's canal) formed by the obturator fascia and the falciform process of the great sacro-sciatic (*sacro-tuberous*) ligament, and rests in that fascia against the medial surface of the obturator internus muscle, which assists in forming the lateral wall of the ischio-rectal fossa. Accompanying it are its venæ comites and the pudenal nerve. Within the pelvis, and upon the spine of the ischium, it gives off some twigs to the adjacent muscles. In the perineum its branches are *muscular* to the obturator internus muscle, the *inferior hemorrhoidal, superficial perineal (perineal), transverse perineal, artery of the*

bulb, artery of the corpus cavernosum, and *dorsal* and *deep arteries of the penis* or *clitoris.* These are described with the perineum.

The **sciatic** (**inferior gluteal**) **artery,** the larger of the two terminal branches of the anterior trunk of the internal iliac (*hypogastric*), descends behind the internal pudendal artery, pierces the pelvic fascia, and passing between the first and second or second and third sacral nerves leaves the pelvis through the lower part of the greater sacro-sciatic (*greater sciatic*) foramen, lying behind and lateral to the internal pudendal artery. Within the pelvis it lies upon the pyriformis muscle and the sacral plexus, and gives off branches to the pyriformis, coccygeus, and levator ani muscles, to the rectum, and to the base and neck of the bladder, the seminal vesicles, and the prostate gland. It appears in the buttock between the pyriformis and the gemellus superior muscles. In the gluteal region it descends upon the obturator internus tendon and gemelli muscles lying on the medial side or posterior surface of the sciatic nerve with which it descends. It is a short trunk, and gives off, in this region, the coccygeal, muscular, articular, anastomotic, cutaneous, and arteria comes nervi ischiatici. These branches are described with the gluteal region.

The **ilio-lumbar artery** is derived from the posterior trunk of the internal iliac (*hypogastric*) and passes upward and lateralward between the obturator nerve and the lumbo-sacral plexus, beneath the psoas major muscle and the external iliac vessels, lying close to the pelvic wall. It runs beneath the iliacus muscle to the upper part of the iliac fossa, where it divides into an iliac and a lumbar branch. The *iliac branch* supplies the iliacus muscle, and enters an oblique nutrient canal of the ilium to supply that bone. Other branches pass along the iliac crest to supply the adjacent portions of the abdominal and gluteal muscles, and anastomose with the circumflex iliac, external (*lateral*) circumflex, and epigastric arteries. The *lumbar branch* ascends to supply the psoas major and quadratus lumborum muscles, sends a small spinal branch through the lumbosacral intervertebral foramen to the spinal cord and its meninges, and anastomoses with the last lumbar artery.

The **lateral sacral arteries,** branches of the posterior division of the internal iliac (*hypogastric*), are usually two in number, a superior and an inferior. The *superior lateral sacral artery* passes downward and medialward, anastomosing with branches of the middle sacral arteries, to the first anterior sacral foramen which it enters to supply the cauda equina and spinal membranes, and emerges on the back at the upper posterior sacral foramen, to supply the skin and muscles over the sacrum, anastomosing in that locality with the gluteal (*superior gluteal*) artery. The *inferior lateral sacral artery* passes medialward across the first sacral nerve and the pyriformis muscle and then downward upon the front of the sacrum

along the medial side of the anterior sacral foramina and lateral to the sacral sympathetic ganglia. In front of the coccyx it anastomoses with branches of the middle sacral and the lateral sacral arteries of the opposite side. It gives off larger branches which enter the anterior sacral foramina and anastomose with the lateral and anterior spinal arteries. They then emerge from the posterior sacral foramina to be distributed to the skin and muscles over the sacrum, anastomosing with branches from the gluteal (*superior gluteal*) artery. The lateral sacral arteries supply branches to the pyriformis and coccygeus muscles, to the sacral plexus, and to the rectum, and larger branches to the contents of the spinal canal. Medial branches anastomose with the middle sacral artery.

The **gluteal** (**superior gluteal**) **artery,** the continuation of the posterior trunk of the internal iliac (*hypogastric*), and the largest branch of the internal iliac (*hypogastric*), is short and thick. Passing backward, it pierces the pelvic fascia and runs between the first sacral nerve and the lumbo-sacral cord through an osseotendinous arch formed by the margin of the bone and the upper edge of the pelvic fascia. In company with its venæ comites and the superior gluteal nerve, it leaves the pelvis at the upper part of the greater sacro-sciatic (*greater sciatic*) foramen and above the pyriformis muscle and appears in the buttock under cover of the gluteus maximus and between the gluteus medius and pyriformis to supply the buttock. Within the pelvis it sends muscular branches to the coccygeus, pyriformis, levator ani, and obturator internus muscles, and a nutrient artery to the innominate bone just before its exit from the pelvis. Outside the pelvis it divides into a superficial and a deep branch. These are described with the gluteal region.

The gluteal (*superior gluteal*) artery, as well as the sciatic (*inferior gluteal*) and internal pudendal arteries, may require ligation for wounds or aneurysm. The surface lines of these arteries and the surface markings of the points of exit of these vessels from the pelvis are described with the gluteal region.

Veins of the Pelvis.—The veins of the false pelvis (*pelvis major*) are the *common iliac* and the *external iliac veins.* The veins of the true pelvis (*pelvis minor*) are the *internal iliac* (*hypogastric*) *and its tributaries,* and the *hemorrhoidal and vesico-prostatic plexuses* in the male, and the *vaginal and uterine* (*utero-vaginal*) *plexuses* in the female. The latter empty into the internal iliac (*hypogastric*) vein by the venæ comites of branches of the internal iliac (*hypogastric*) artery.

The **common iliac veins** are formed by the external iliac and internal iliac (*hypogastric*) veins and their tributaries. They differ in their relations to the corresponding arteries on the two sides of the body. The *left common iliac vein* is in relation with both arteries, since it crosses from its position below and to the

right side of the left common iliac artery to the right side of the spinal column, where it lies behind the right common iliac artery and joins the right common iliac vein to form the inferior vena cava. The *right common iliac vein* ascends behind its companion artery, but gradually passes toward the right side of the latter to join the vein of the opposite side to form the inferior vena cava.

The **external iliac vein** is the continuation upward of the common femoral vein. It begins at Poupart's (*inguinal*) ligament to the medial side of the termination of the external iliac artery and ends at its junction with the internal iliac (*hypogastric*) to form the common iliac vein at the sacro-iliac synchondrosis. The left lies to the medial side of its companion artery throughout its course, whereas the right at first lies medial to its artery and then behind it. The deep circumflex iliac vein and the deep (*inferior*) epigastric veins empty into it a little above Poupart's (*inguinal*) ligament.

The **internal iliac (hypogastric) vein** is formed by tributaries which have the same course as the branches of the internal iliac (*hypogastric*) artery, with the exception that it receives no vein which corresponds to the obliterated hypogastric (*umbilical*) artery. It receives blood from the exterior of the pelvis; also from the organs in the cavity of the pelvis through the hemorrhoidal and vesico-prostatic plexuses in the male, and through the vaginal and uterine (*utero-vaginal*) plexuses in the female. The internal iliac (*hypogastric*) vein terminates opposite the sacro-iliac articulation, where it unites with the external iliac vein to form the common iliac vein. In its course it lies at first on the medial side of, and then behind the internal iliac (*hypogastric*) artery. It contains no valves.

The pregnant uterus or new growths may cause obstruction of the circulation in the veins of the pelvis; or septic emboli may cause thrombosis and phlebitis of these veins; or the veins may be the seat of primary phlebitis. Obstruction in the internal iliac (*hypogastric*) vein or its tributaries in the female, either through pressure, as by the gravid womb, or by thrombosis, may cause varicose veins in the vagina or vulva, or edema of the vulva. Emboli from thrombi in the internal iliac (*hypogastric*) vein are a frequent cause of death after gynecological operations. The external iliac vein may likewise be pressed upon by pelvic growths or the pregnant uterus; or it may be the seat of phlebitis, or thrombosis, as in phlegmasia alba dolens after child-birth, conditions which cause edema of the lower extremity.

The veins forming the various plexuses in the pelvis are noted for their great tortuosity. They also have very frequent anastomoses.

The **vesico-prostatic plexus of veins** is found surrounding the neck and base of the bladder and the prostate gland. It receives the dorsal vein of the penis and the veins from the vesical venous plexus, and communicates behind with the

hemorrhoidal plexus. Its veins are of large size, and in old men may become varicose and contain phleboliths, or vein-stones. It empties into the internal iliac (*hypogastric*) by means of a single vein.

The **vesical plexus** surrounds the fundus, sides, and anterior and posterior surfaces of the bladder and empties into the vesico-prostatic plexus.

The **uterine (utero-vaginal) plexus of veins** is formed by large veins from the uterus. It is situated along the sides and superior angles of the uterus. Unlike the uterine arteries, the veins do not run a tortuous course. They anastomose frequently with themselves and with the ovarian veins. The blood from the uterine plexus of veins returns partly through the ovarian veins and partly through the uterine veins which accompany the uterine arteries.

The **vaginal plexus of veins** is found in the mucous and muscular coats of the vagina, being especially marked near the vaginal orifice. It communicates with the hemorrhoidal plexus behind, and with the vesical plexus in front, and is drained by the vaginal veins which empty into the internal iliac (*hypogastric*) veins.

The **dorsal vein of the penis** is an exception to the rule that the veins of the pelvis follow the same general course as the arteries. It pierces the two layers of the triangular ligament (*urogenital diaphragm*) and divides into two branches which communicate with the internal pudendal and obturator veins, and enter the vesico-prostatic venous plexus instead of the internal pudendal veins.

The **pudendal veins** begin at the corpus cavernosum, with the vein issuing from that body alongside the artery, and communicate with the dorsal vein of the penis.

The **ilio-lumbar and middle sacral veins** usually empty into the common iliac vein.

The **hemorrhoidal plexus of veins** surrounds the lower part of the rectum and is situated between the mucous and muscular coats. Its blood is distributed to the internal pudendal vein through the inferior hemorrhoidal, to the internal iliac (*hypogastric*) vein through the middle hemorrhoidal, and to the inferior mesenteric and portal veins through the superior hemorrhoidal vein. This plexus, therefore, is a link between the systemic and portal systems of veins, and explains the occurrence of hemorrhoids in obstruction of the portal vein, as in cirrhosis of the liver, as well as in obstruction of the local systemic veins, as by pelvic tumors and the pregnant uterus. The veins of this plexus are destitute of valves. It also accounts for the occasional occurrence of pylephlebitis after rectal suppuration.

The **viscera of the pelvis** comprise the rectum, the bladder, and the lower portion of the ureters in both sexes; the uterus, ovaries, and vagina, and their

adnexa, in the female, and the prostate, seminal vesicles, and vasa deferentia (*ductus deferentes*) in the male.

The **rectum** (Plate CCCCXLVIII) is the terminal portion of the large bowel. It begins at the lower end of the sigmoid flexure (*pelvic colon*) at the third sacral vertebra and opposite the greater sacro-sciatic (*greater sciatic*) foramen (see description of sigmoid flexure, p. 408). It ends at the anus a short distance in front of the tip of the coccyx. It is about fifteen centimeters (six and a half inches) in length, and of varying diameter in its different parts. It is described as composed of two parts, an upper and a lower, which correspond to the second and third portions of the rectum in the old descriptions. It follows the curve of the sacrum and coccyx, lying behind the bladder, the seminal vesicles and their ducts and the prostate in the male; and behind the uterus and vagina in the female.

The *first, or upper, portion of the rectum* is twelve and a half centimeters (five inches) in length and is the most dilated portion of the rectum. It lies upon the front of the sacrum and extends downward from the third sacral vertebra to about two and a half centimeters (one inch) in front of the tip of the coccyx, at which point the rectum bends backward, the angle thus formed marking the division between the two portions of the rectum. The upper two-thirds of the upper portion lie in the sacro-coccygeal hollow, and this portion of the gut is correspondingly curved, convex posteriorly and concave anteriorly, while its lower third rests against the musculo-fibrous structure situated between the coccyx and anus, called the *ano-coccygeal body*, or ligament. Just above the junction of the first with the second portion the bowel is dilated, and forms the *ampulla of the rectum.* The peritoneum covers the anterior surface and sides of the upper third, forming the pararectal fossa on each side. It covers the anterior surface of the middle third of, and is reflected onto the bladder in the male and the vagina in the female, forming the bottom of the recto-vesical or recto-vaginal pouch. This is about seven and a half centimeters (three inches) from the anus and about two and a half centimeters (one inch) above the prostate in the male. The lowest third is covered by the pelvic fascia and is devoid of peritoneum. The foregoing is especially important when resection of the rectum for cancer is considered.

The *second, or lower, portion of the rectum,* the *anal canal,* is four to five centimeters (one and a half to two inches) in length, and begins at about the apex of the prostate or the tip of the coccyx, whence it passes downward and backward to the anus. It is encircled throughout almost its entire extent by the internal sphincter ani muscle which permits its walls to separate only during the passage of feces. The external sphincter guards its orifice, the anus. Above the outer sphincter is the levator ani muscle which supports the bowel. Because of the

PLATE CCCCXLVIII.

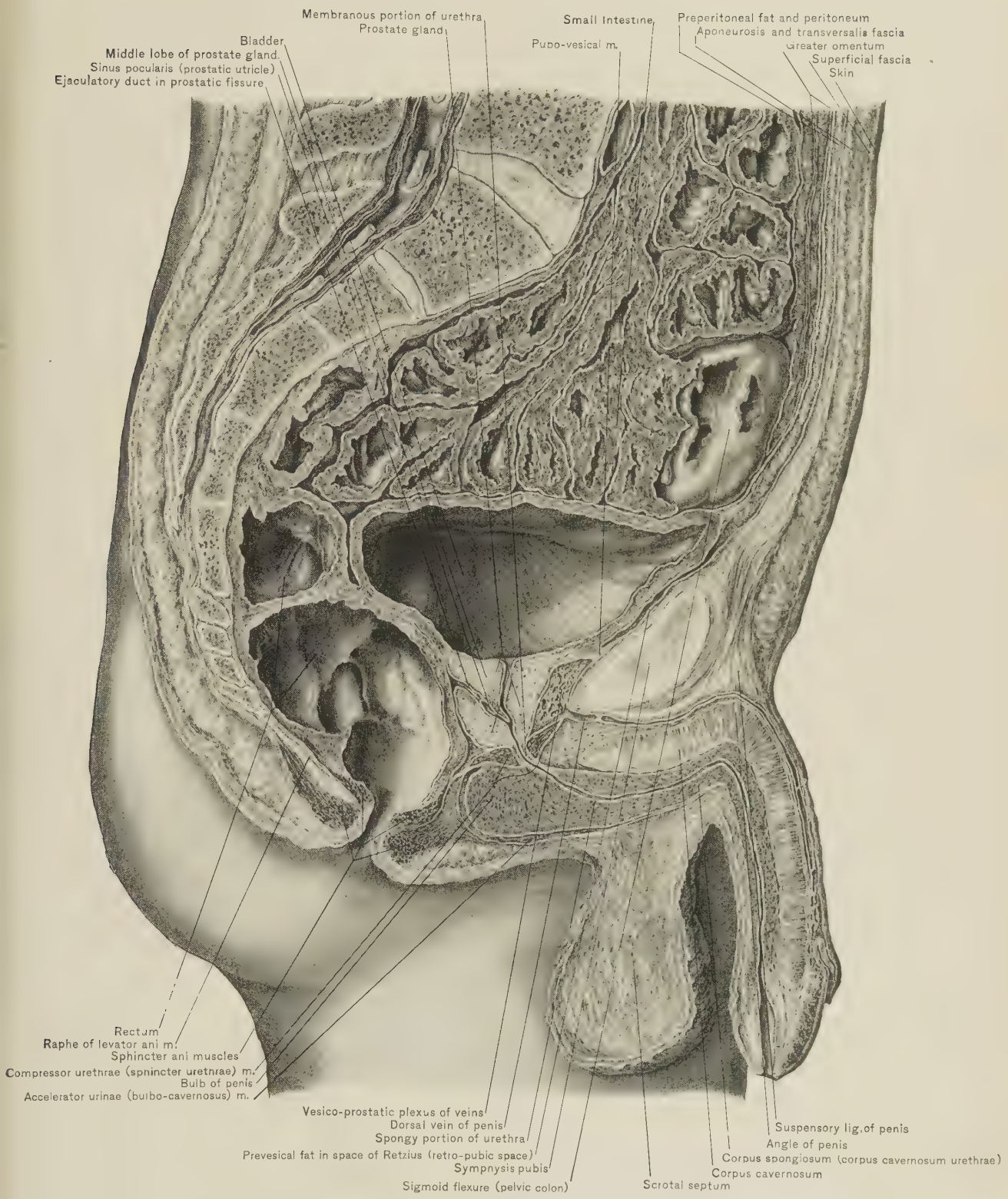

MALE PELVIS AND PERINEUM—SAGITTAL SECTION.

recession of the anal canal, an angular interval separates the lower end of the rectum from the urethra and bulb of the penis. This portion of the rectum has no peritoneal covering.

The *walls of the rectum* are made up of serous, fibrous, muscular, submucous, and mucous coats.

The *serous*, or *peritoneal, coat* covers the front and sides of the first portion. The lower limit of the peritoneal covering on the posterior surface of the bowel is at the commencement of the rectum, opposite the third sacral vertebra and about twelve and a half centimeters (five inches) from the anus. This limit inclines downward as the anterior surface of the rectum is approached. On this surface the lowest limit of the peritoneum is about seven and a half centimeters (three inches) from the anus, when the bladder is partly distended; it may be reduced to six centimeters (two and a half inches) when the bladder is empty, and may be increased to ten centimeters (four inches) in full distention of the bladder. In the male this covering is reflected upon the bladder, thus forming the *recto-vesical pouch;* in the female, upon the vagina, forming the *recto-vaginal* (*recto-uterine*) *pouch*, or *culdesac of Douglas.*

The *fibrous coat* is delicate and is derived from the recto-vesical fascia.

The *muscular coat* is composed of an external longitudinal and an internal circular layer. The longitudinal layer is most marked upon the anterior and posterior walls, but is not arranged in bands. Some of the longitudinal fibers are attached to the coccyx, and form a *recto-coccygeal muscle.* The circular fibers are most numerous in the second or terminal portion of the rectum, where they form the *internal sphincter ani muscle.*

The *submucous coat* is composed of rather lax areolar tissue, which is especially loose in children, and at times permits prolapse of the mucous coat. As in other portions of the intestine, the submucous layer contains the vessels and nerves which supply the mucous and muscular layers. The *veins of the rectum* in this layer communicate with the portal venous system through the superior hemorrhoidal tributary of the inferior mesenteric vein, and with the systemic circulation through the middle and inferior hemorrhoidal veins which are tributaries of the internal iliac (*hypogastric*) vein. The dependent position of these vessels and their liability to pressure from hardened feces and disturbances in the portal and systemic circulations, explain the frequency of a varicose condition of these veins, with the formation of hemorrhoids. The *arteries of the rectum* form a plexus in this layer; they are derived from the superior, middle, and inferior hemorrhoidal arteries.

The *mucous coat* is of a reddish color and is thicker and more vascular than in the colon. In the first portion of the rectum and lower end of the sigmoid flexure

(*pelvic colon*) it forms three or more oblique or transverse folds (plicæ recti), described by Houston, which are situated upon the front and sides of the bowel. The largest of these folds is situated on the right side of the gut, about on a level with the line of reflection of the peritoneum from the bladder to the rectum. As a rule, there are two other folds, one about two and a half centimeters (one inch) above the large fold and the other about the same distance below it; they project from the left side of the gut. The plicæ recti can be seen during life by placing the patient in the knee-chest position, and, with the proper instruments, distending the rectum and allowing air to enter. These folds may hinder the introduction of a bougie or rubber tube.

Through the rectum, in the male, Cowper's (*bulbo-urethral*) glands (when inflamed), the prostate gland, the base of the bladder, the seminal vesicles, the spermatic ducts, and the contents of the recto-vesical pouch may be palpated; and in the female, the uterus, ovaries, Fallopian (*uterine*) tubes, and contents of the rectovaginal (*recto-uterine*) pouch may be felt. An inflamed appendix extending into the pelvis may also be felt through the rectum.

Malformations.—These malformations are the result of defects in embryologic development. The rectum and anus are developed separately, the former from ectodermal and mesodermal structures and the latter from epidermal structures. In studying these defects it is necessary for the student to review the embryology of the region. Very early in the development of the embryo the lower portion of the primitive gut connects with the neurenteric canal (post-anal gut), but this junction disappears, leaving the intestine closed behind it and terminating in a cloaca common to it and the urachus. During the second month of fetal life the perineal partition divides this dilatation into a urogenital and a rectal segment. At about the same time a depression forms at the anal site (proctodeum). This is lined by epiderm, and extends inward to meet the blind end of the ectodermal tube, into which it opens. This occurs at about the third month. The anal valves are a remains of the cloacal membrane which separates the two chambers. In arrested or irregular development of these structures we have the basis for the various malformations which are observed such as: (A) Imperforate anus, either (1) a congenital narrowing of the anus; (2) closure of the anus by a thin membrane; (3) entire absence of the anus, the rectum ending as a blind pouch at varying distances from the perineum; (4) imperforate anus with fecal fistula opening into the uterus or vagina, bladder or urethra, or on the surface of the body. (B) Imperforate rectum with anus normally placed, either (1) a membranous obstruction of the rectum; or (2) extensive obliteration or total absence of the rectum. (C) The rectum and anus may be normal, but the ureters, uterus or vagina may open into the rectal cavity. (D)

PLATE CCCCXLIX.

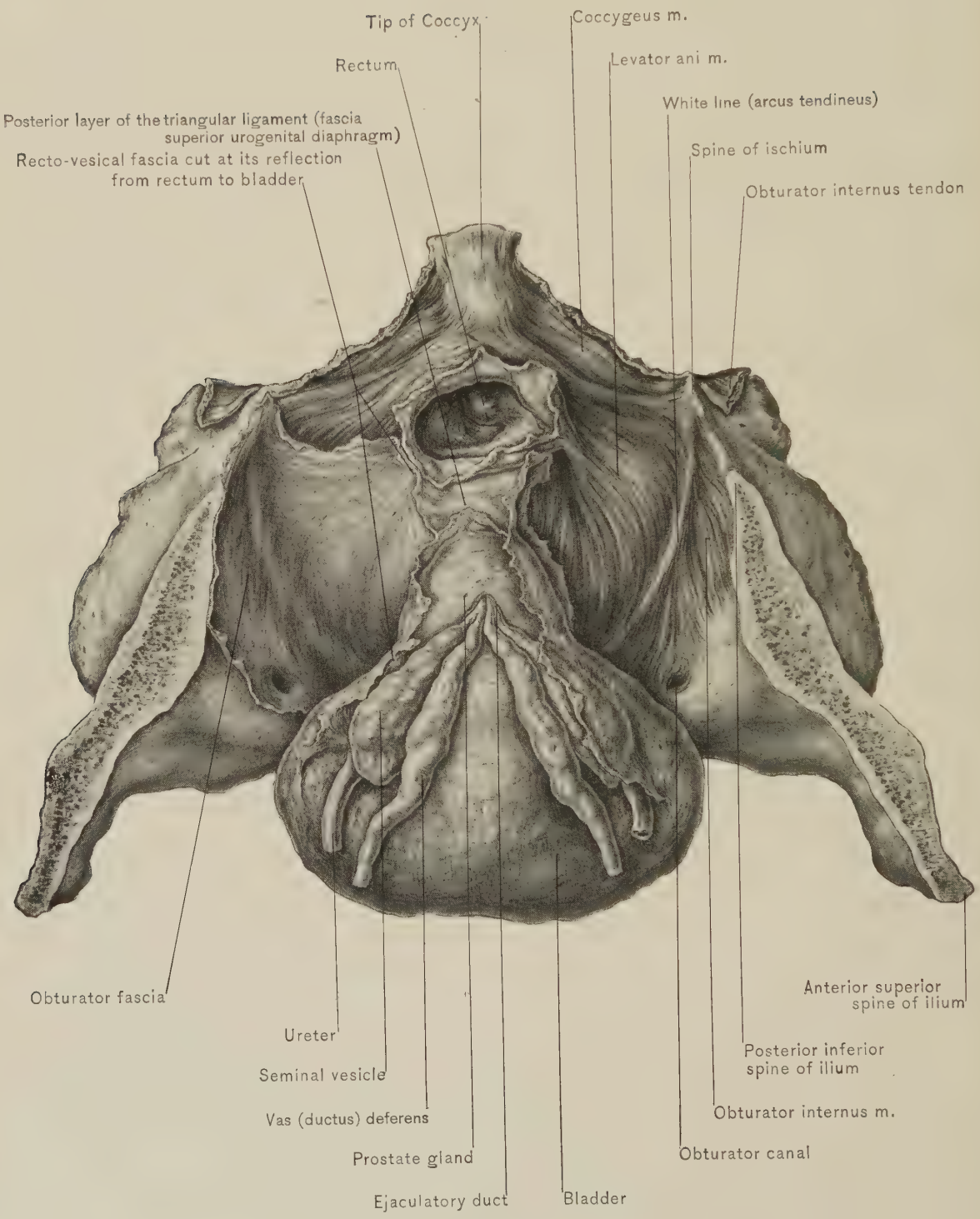

BLADDER, PROSTATE, SEMINAL VESICLES, VASA DEFERENTIA (DUCTUS DEFERENTES).

There may be an absence of the large intestine, absence of a normal anus, and instead a fecal opening at the umbilicus or elsewhere.

The **bladder** (Plate CCCCXLIX) is a hollow, fibro-muscular viscus, which is the urinary reservoir, situated in the pelvis above the urethra, the prostate, the triangular ligament of the urethra, and the levator ani muscle. When empty, the bladder is almost entirely within the pelvis; but when distended, it ascends into the abdominal cavity behind the recti muscles, and may extend as high as the umbilicus. The shape of the organ usually varies with the age of the person, being longer and narrower in the infant than in the adult. This fact is due to development of the viscus from the allantoic duct of fetal life, the bladder being the lower unobliterated portion of that fetal structure the upper portion of which atrophies and remains as the **urachus,** which is found as a fibrous cord running from the summit of the bladder to the umbilicus. In the further development of the individual we find the urogenital section of the cloaca divisible into an upper urinary part and a lower part, the urogenital canal. In both the male and female the urinary part becomes the bladder. The long, narrow bladder of the infant projects above the crest of the pubis even when empty, a fact to be borne in mind when operating upon this organ in children.

The adult bladder when moderately distended measures about twelve and a half centimeters (five inches) in its long axis and about seven and a half centimeters (three inches) in its transverse diameter. Its average capacity is about half a liter (one pint), but this varies with the age and habits of the individual. In the female, the bladder is greater in its transverse than in its vertical diameter, and is said to have a greater capacity.

The distended bladder is divided into a summit, or apex, a body, a base, or fundus, and a neck, or cervix.

The **summit of the bladder** is directed forward and upward. It is rounded in form, and is connected with the umbilicus by the *urachus*, the obliterated portion of the allantoic stalk of fetal life. In front of this fibrous cord the summit of the bladder is devoid of peritoneum, which in distention of the bladder is carried upward by the urachus.

The **body of the bladder** connects the apex with the base but is not sharply marked off from either. It is in contact, in front, with the pubo-prostatic ligaments, the symphysis pubis, the bodies of the pubic bones, and, when distended, with the anterior abdominal wall. The anterior surface is free from peritoneal covering. The anterior and the parts of the lateral surfaces of the bladder which are not covered with peritoneum, are loosely united to the adjacent structures by areolar and fatty tissues containing numerous veins. This prevesical areolar tissue and fat is continuous with the extraperitoneal areolar tissue.

The space between the posterior portion of the symphysis pubis and the anterior surface of the bladder is known as the **space of Retzius** (**retro-pubic space**). This space extends laterally as far as the hypogastric arteries and their visceral branches. It extends upwards to the umbilicus between the peritoneum and the transversalis fascia, where it is bounded on either side by the obliterated hypogastric artery (*lateral umbilical ligament*). Below it is limited by the pubo-prostatic ligaments and the fascia covering the levator ani muscle.

Distention and movements of the bladder are favored by these loose connections. The space which this loose areolar tissue occupies has just been described. Posteriorly, the body of the bladder is covered with peritoneum, and is in relation, in the male with the rectum, in the female with the uterus, and in both sexes with the small intestine and sigmoid flexure, which gravitate to the pelvis. The *sides* of the body of the organ are crossed obliquely upward and forward by the obliterated hypogastric arteries (*lateral umbilical ligaments*). Above and behind these arteries the body of the bladder is covered by peritoneum, but in front of and below them, the bladder rests against the pelvic and transversalis fasciæ, and is free from peritoneum. Crossing the hypogastric arteries (*lateral umbilical ligaments*) will be seen the vasa deferentia (*ductus deferentes*) which pass along the sides of the body of the bladder. In passing downward into the pelvis the vasa deferentia (*ductus deferentes*) run between the ureter and the bladder and then along the medial sides of the ureters.

The **base, fundus,** or **bas fond, of the bladder** faces downward and backward. It is broad and flat when the bladder is distended, but becomes narrower when empty. In the male it rests against the upper portion of the rectum, from which it is separated by areolar tissue. At the upper margin of the base of the bladder, and about two and a half centimeters (one inch) above the prostate gland, the peritoneum is reflected from the rectum to the bladder to form the recto-vesical pouch. The portion of the base in relation with the rectum is triangular in shape. The triangle is bounded behind by the recto-vesical fold of peritoneum; at the sides by the seminal vesicals and the vasa deferentia (*ductus deferentes*); and its apex extends forward to the base of the prostate gland. This triangle varies in size with the distention of the bladder, as the fold of peritoneum is carried upward by the distended bladder; it almost corresponds to the trigone of the bladder which is seen on the internal surface of the bladder. In the female the base of the bladder lies in contact with the lower portion of the uterus and the upper part of the vagina.

The **neck,** or **cervix, of the bladder** is the constriction at the outlet of the bladder, and is continuous with the urethra; it is surrounded by the prostate gland in the male and looks downward when the individual is in the upright position.

The neck of the bladder is held firmly in position by the encircling prostate, which in its turn is held in place by the recto-vesical fascia and the deep layer of the triangular ligament (*fascia superior of the urogenital diaphragm*), although slight descent of the prostate and neck of the bladder does occur when the latter organ is much distended.

The **relation of the peritoneum to the surfaces of the bladder** is very important in all operations upon that organ. When empty, the peritoneum covers all portions of the bladder except where it lies in contact with the pubic bones, the triangular ligament (*urogenital diaphgram*), and the lower part of the rectum or the cervix uteri and the vagina. When the organ is distended, the area covered by peritoneum is mostly posterior, and is bounded above by the urachus, below by the line connecting the orifices of the ureters, and anteriorly at the sides by the obliterated hypogastric arteries (*lateral umbilical ligaments*).

When the bladder is empty and relaxed, a vertical section of it and the upper part of the urethra is usually Y-shaped. Its upper portion drops downward upon the lower part, making a cup-like depression instead of a convexity at the site of the bladder. As the bladder is distended the depression or concavity disappears. It has been claimed that this cup-like depression is found only after death, and is due to relaxation of the muscle wall, and that even when empty, the bladder, during life, always maintains a rounded form. The latter is the finding in the experience of the author. When moderately distended, it is ovoid in shape, the larger end being directed downward and backward toward the rectum in the male, and toward the uterus and vagina in the female. In its ascent the urachus at the summit of the bladder will carry the anterior fold of peritoneum upward with it, above the level of the pubic bones. When the bladder is well distended, this area which lacks peritoneal covering may extend five centimeters (two inches) or more above the pubic crest. This fact is of advantage in the operation of suprapubic cystotomy, since it permits of an extraperitoneal approach for entering the bladder. In tapping the bladder above the pubis with a trocar, it is well to push the instrument backward, rather than downward, in order to prevent it from entering the cellular tissue interposed between the bladder and the pubis, the space of Retzuis (*retropubic space*). Posteriorly, the peritoneum is reflected from the rectum to the bladder, and comes into contact with that organ just above the seminal vesicles and the entrance of the ureters. When the bladder is empty, the sac thus formed, the rectovesical pouch, may be only five centimeters (two inches) from the anus; when the bladder is distended, it carries this pouch upward until it is two and a half centimeters (one inch) or more higher, thus allowing the bladder to be tapped through the rectum without any danger of opening the peritoneal cavity.

This operation should, however, not be countenanced any longer. The capacity of the bladder is variable in both sexes.

Structure.—The wall of the bladder is composed of a fibrous, a muscular, a submucous, and a mucous coat, with a peritoneal coat in some parts. Its thickness may vary greatly in different subjects, and even in the same subject under different degrees of distention. When moderately stretched, it is about three millimeters (one-eighth of an inch) thick but when contracted may reach the thickness of twelve millimeters (one-half inch). It is thickest at the trigone.

The peritoneal investment of the bladder, by its reflection over the urachus above, and from the side and back of the bladder below, forms the **false ligaments of the bladder.**

The **fibrous coat of the bladder** is continuous with the recto-vesical fascia, and covers the muscular coat. It is thickest near the base of the organ, where it is continuous with the capsule of the prostate and the pubo-prostatic (*middle pubo-vesical*) or anterior true, ligaments, and is less distinct near the summit of the bladder. At the side it is continuous over the levator ani muscle, and forms the **lateral true** (**lateral pubo-vesical**) **ligaments,** while above it is continuous with the urachus, forming the **superior true** (**middle umbilical**) **ligaments.**

The **muscular coat** consists of three layers of unstriated muscle fibers. The *outer layer of muscle fibers* is arranged longitudinally, and is more readily demonstrable than the other two. It is seen best on the anterior and posterior surfaces and on the summit of the bladder. At the sides, the fibers are more oblique and irregular. In front they are attached to the prostate in the male, and in both sexes form two muscle bands, the *pubo-vesical muscles*, attached to the dorsal surface of the pubic bones close to the symphysis. The *middle muscular layer* is composed of circular fibers, and is most marked at the neck of the bladder, where it forms the *internal sphincter of the bladder.* The *inner muscular layer* is arranged chiefly in a longitudinal direction, although it is somewhat retiform. When the bladder is well distended, this layer of muscle fibers becomes so thin that open meshes are left between them, and pouches, or sacculi, of the mucous membrane may form as a result of chronic obstruction to the exit of urine. These muscle fibers may also become hypertrophied and form ridges upon the inner surface of the organ. A stone may be so lodged in a saccule that a sound does not strike it.

The **submucous coat** is placed between the muscular and mucous coats, and consists of areolar and elastic tissues, through which the vessels and nerves ramify.

The **mucous coat,** or mucous membrane, or inner layer, as well as the orifices of the bladder, can be studied after opening the bladder. During life and soon

after death the mucous membrane, in the healthy state, is of a pale rose color. It is smooth when the bladder is full and wrinkled when it is empty, except at the urinary trigone where it is always smooth owing to the close attachment to the muscular wall of the bladder. This triangular area, the **vesical trigone,** is opposite the triangle seen on the inner surface of the base of the bladder, which is in relation with the rectum. Within the bladder, this triangle is bounded on the sides by lines drawn between the vesical orifices of the urethra and ureters, and above by a transverse elevation between the orifices of the ureters, called plica ureterica. The apex, which is below, is at the internal opening of the urethra, the internal urinary meatus. The mucous membrane is continuous with the mucous membrane of the ureters and of the urethra.

The **orifices of the ureters,** situated at the posterior angles of the trigone, are about five centimeters (two inches) apart, and about four centimeters (an inch and a half) from the internal urinary meatus. A slight elevation of the mucous membrane, the **uvula vesicæ,** or **uvula of Lieutaud,** projects forward into the internal urinary meatus. It is smaller in the female than in the male.

The female bladder usually presents a lessened anteroposterior diameter, owing to the encroachment of the vagina and uterus; and an increased lateral diameter, owing to the greater width of the pelvis. As the symphysis pubis is not so deep as in the male, the urinary orifice lies nearer its lower border. Lateral asymmetry is frequently observed in the female bladder.

Relations.—In the adult male the bladder, when empty or when containing little urine, is in relation, in front and below, with the base of the prostate gland, the pubo-prostatic ligaments, and the body of the pubes; behind with the peritoneum, rectum, ureters, vasa deferentia (*ductus deferentes*), and seminal vesicles. In the female, it is in relation posteriorly with the ureters, uterus, and vagina. The superior and posterior surfaces are covered by peritoneum.

The **ligaments of the bladder** are five true—two anterior (*pubo-prostatic*, or *middle pubo-vesical*), two lateral (*lateral pubo-vesical*), and a superior (*middle umbilical*), the urachus; and five false, consisting of peritoneal folds—two posterior (*sacro-genital*), two lateral, and one superior.

Of the *true ligaments*, the anterior, the *pubo-prostatic, or middle pubo-vesical, ligaments* are formed by the recto-vesical fascia, and extend from the posterior surface of the pubic bones at the sides of the symphysis to the neck of the bladder and the base of the prostate. They contain some muscle fibers which are continuous with the external muscular layer of the wall of the bladder. The *lateral true,* or *lateral pubo-vesical, ligaments* extend from the sides of the prostate and the base of the bladder to the levator ani muscle. They also are formed by the recto-vesical fascia. The *superior true,* or *middle umbilical, ligament* is

formed by the urachus, which is an obliterated portion of the allantoic stalk extending from the summit of the bladder to the umbilicus. These are all continuous with the fibrous coat of the bladder-wall.

Of the *false ligaments*, the two *posterior* are the recto-vesical (*sacro-genital*) folds, the utero-vesical in the female, and contain the obliterated hypogastric (*umbilical*) arteries, the ureters, and vessels and nerves passing to the bladder. The *lateral alse ligaments* are peritoneal folds extending between the sides of the bladder and the lateral walls of the pelvic cavity. The *superior false ligament* is the fold of peritoneum which passes from the summit of the bladder to the abdominal wall and covers the urachus and obliterated hypogastric (*umbilical*) arteries.

Blood Supply.—The blood supply of the bladder is derived from the superior, middle, and inferior vesical, obturator, and internal pudendal arteries, and also from branches from the uterine and vaginal arteries, in the female.

The **veins** form a large plexus about the organ, especially marked at its base, where they communicate with the prostatic plexus and form the **vesico-prostatic plexus**; they empty into the internal iliac (*hypogastric*) vein.

The **lymphatics** accompany the blood vessels and empty into the pelvic glands alongside of the internal iliac (*hypogastric*) and common iliac arteries.

Nerve Supply.—The nerve supply of the bladder is derived from the pelvic plexuses of the sympathetic, and through these plexuses its nerves are chiefly derived from the third and fourth sacral nerves and from the upper lumbar nerves.

Rupture of the bladder may occur from overdistention or from direct violence applied to a distended bladder. It may rupture at its posterior part, and the urine be poured into the peritoneal cavity; or it may tear at its anterior or nonperitoneal portion, and the urine be extravasated into the pelvic extraperitoneal connective tissue. In the former instance a violent and fatal peritonitis will result unless the condition is detected early, the bladder rent sewed, the abdominal and pelvic cavities drained, and a catheter left in the urethra to drain off the urine as quickly as it reaches the injured viscus. In some instances it may be considered better to drain the bladder suprapubically. The symptoms of intraperitoneal rupture of the bladder are inability to urinate, collapse of the organ, and little or no urine and some blood in the bladder. The catheter may sometimes be carried into the abdomen in which case warm sterile water injected into the bladder disappears and cannot be drawn off. Cases have occurred in which abdominal dropsy was mistaken for a distended bladder, and the catheter pushed through the bladder into the peritoneal cavity under the supposition that it had not been introduced far enough, thus emptying the belly of its serum under the impression that the fluid came from the bladder. Although this may occasionally occur to the novice, it is inexcusable.

The **ureters** dip into the pelvis over the iliac vessels near the bifurcation of the common iliac artery, whence they curve downward, forward, and somewhat medialward in the extraperitoneal connective tissue and beneath the posterior false ligaments (*sacro-genital folds*) of the organ to the back of the base of the bladder. They enter the bladder very obliquely, about five to five and a half centimeters (two to two and a quarter inches) back of the prostate and two and a half centimeters (one inch) medial to the median line. They pass obliquely downward and lateralward through the wall of the bladder for about twelve millimeters (half an inch) and open into the bladder about two and a half centimeters (one inch) from the internal urinary meatus and from each other. The ureter is narrowest at the vesical orifice, and for that reason a calculus is more likely to be arrested at that point. The mode of entrance of the ureters produces a valve-like orifice which allows the urine to flow into the bladder, and at the same time prevents regurgitation of urine. In the posterior false ligaments (*sacro-genital folds*) the ureters cross behind and below the obliterated hypogastric (*umbilical*) arteries, and are crossed by the vasa deferentia (*ductus deferentes*) which run between them and the bladder and then medial to them. *In the female* they lie behind the broad ligaments in their descent and then pass forward under them. They next run directly through the plexus of veins situated behind the loop of the uterine artery, and here lie eight to ten millimeters (one-third to three-fifths of an inch) from the side of the cervix. It is here that they may be ligated or injured during the operation of hysterectomy. If the needle used for ligation of the uterine arteries is passed close to the wall of the uterus and away from the ureter this accident will be a rare one. They finally run to the side of the vagina, then pass in front of it, and enter the bladder in front of the upper portion of the vagina. In this location a calculus in the ureter can be palpated through the vagina. In the pregnant female the posterior part of the large curve formed by the ureters is straightened out by being lifted upward with the broad ligament, but it is still behind this ligament, immediately beneath the peritoneum. Although the greater part of the curve changes, the lower part remains the same as in the non-pregnant condition, so that there is no interference with the ureters at their entrance into the bladder.

Blood Supply.—The blood supply of the ureters is derived from the renal, spermatic or ovarian, internal iliac (*hypogastric*), and vesical arteries. The veins correspond to the arteries. The lymphatics empty into the pelvic and lumbar glands.

Nerve Supply.—The nerve supply of the ureters is derived from the sympathetic plexuses in relation with arteries which furnish their blood supply.

The **prostate** is a firm, musculo-glandular body situated at the neck of the bladder and surrounding the first or prostatic portion of the urethra. In shape it

is irregularly pyramidal, and resembles a horse-chestnut. In breadth it measures three and three-quarters centimeters (one and a half inches) from side to side at the base (its widest part), and its length is three centimeters (one and one-fourth inches). It is flattened from before backward and its anteroposterior diameter is slightly less than one and three-quarters centimeters (three-fourths of an inch). It weighs about twenty-four grams (six drams). Behind, it rests upon the anterior wall of the rectum, four to five centimeters (an inch and a half to two inches) above the anus.

The **base of the gland** is directed upward toward the bladder, is attached to the muscular coat of the wall of that organ, and is nearly opposite the middle of the symphysis pubis. The **apex** is directed downward, and is situated just above the deep layer of the triangular ligament (*superior fascia of the urogenital diaphragm*). The **anterior surface** is one and a half to two centimeters (one-half to three-fourths of an inch) behind the lower half of the symphysis pubis and is in relation with the prostatic plexus of veins, fat, and areolar tissue. The **posterior surface** is in relation with the rectum. Its **lateral surfaces** are opposed to the anterior fibers of the levator ani muscle which supports the gland, and are called the levator of the prostate. An irregular artery, usually a branch of the internal iliac (*hypogastric*), is sometimes found running along the side of the prostate gland on its course to the dorsum of the penis. It may be the source of dangerous hemorrhage in lateral lithotomy.

The prostate is inclosed in a dense fibrous **capsule** formed by the recto-vesical fascia. The anterior portion of the capsule is continuous with the pubo-prostatic (*middle pubo-vesical*), or anterior true, ligaments of the bladder. By incising the capsule, the gland will be brought into view.

The base of the prostate is surrounded by the thick **prostatic plexus of veins,** which is most marked upon its sides and anterior surface. It receives the dorsal vein of the penis, which runs along the anterior aspect of the prostate and divides into two portions which are lost in the prostatic plexus. The plexus also receives the veins from the vesical plexus, veins from the prostate, and communicates with tributaries of the internal pudendal vein. In old men these veins often become distended and tortuous, phleboliths are not uncommon, and the resulting obstruction causes cyanosis of the penis. These veins may give rise to considerable hemorrhage in suprapubic prostatectomy. They should be injured as little as possible. Injury with resulting thrombosis may offer a nidus for embolus.

The prostate is divided into **two lateral lobes** by an **anterior** and a **posterior median furrow.** A slight bulging of the gland toward the bladder, between the neck of the bladder and the prostatic urethra in front, and the two lateral lobes at either side and behind, is called the **third,** or **middle, lobe.** This lobe varies much

in size, and may even be absent, and when hypertrophied is a cause of retention of urine and dysuria. In some cases this middle lobe may act as a ball-valve. On the posterior surface of the gland this lobe is bounded in front by a transverse cleft, the **prostatic fissure,** which extends deeply forward toward the middle of the prostatic urethra and contains the ejaculatory ducts and the sinus pocularis (*prostatic utricle*). This fissure really cuts off the so-called middle lobe from the rest of the organ.

Structure.—Three-fourths of the prostatic body is composed of unstriated muscle tissue, and the other one-fourth consists of branched tubular glands which are more plentiful beneath the urethra. The muscle tissue is continuous with the sphincter of the bladder, and the ducts of the glands empty into the prostatic sinuses. The secretion of the gland dilutes and gives bulk to the semen. The contraction of the muscle tissue at the base of the gland is supposed to prevent regurgitation of the semen into the bladder, and the remainder to assist in accelerating its passage through the urethra. Near the apex the gland is probably connected by striated muscle fibers with the transverse perineal muscle.

Blood Supply.—The blood supply of the prostate is derived from the middle hemorrhoidal, inferior vesical, and internal pudendal arteries. The veins enter the prostatic plexus which drains into the internal iliac (*hypogastric*) vein.

Nerve Supply.—The nerve supply of the prostate is derived from the hypogastric plexus of sympathetic nerves.

The **lymphatics** follow the vessels and empty into the lumbar glands.

The **prostatic urethra** is that portion of the urethra which is inclosed by the prostate. It measures about three centimeters (one and a quarter inches) in length, is widest at its commencement at the bladder and narrowest as it leaves the apex of the gland and enters the triangular ligament (*urogenital diaphragm*). Longitudinally, along the middle of the floor of the prostatic urethra, there is a narrow fold or ridge composed of mucous membrane and the subjacent structure of the prostate; it is called the **verumontanum** (**urethral crest**). The verumontanum (*urethral crest*) is highest at its middle and gradually fades away at either end. Upon each side of this is a furrow called the **prostatic sinus** which contains the orifices of the **prostatic ducts,** which carry the secretion from the glandular tissue of the prostate. In the fore-part of the verumontanum (*urethral crest*) and just anterior to its highest portion, is a small blind pouch, the **sinus pocularis** (**prostatic utricle**), which is the homologue of the uterus. In its lateral margins are the slit-like orifices of the ejaculatory ducts. The ejaculatory ducts and sinus pocularis (*prostatic utricle*) occupy the prostatic fissure which bounds the middle lobe of the prostate in front.

The **sinus pocularis** (**prostatic utricle**) is a pocket about twelve millimeters (one-half inch) in length, and extends upward and backward under the verumontanum (*urethral crest*) into the prostatic fissure. Its wall has a musculo-fibrous structure, contains the ejaculatory ducts, and is lined with mucous membrane, upon the inner surface of which small glands open. These glands are analogous to the uterine glands.

The **seminal vesicles** are irregularly lobulated and elongated pouches situated along the sides of the triangular area at the base of the bladder. They are widest at their upper free divergent ends, where they measure twelve millimeters (one-half inch), and are quite narrow at their convergent ends, where they join the vasa deferentia (*ductus deferentes*) opposite the base of the prostate. They are about six centimeters (two and one-half inches) in length, and about six millimeters (one fourth of an inch) in thickness. They are irregular in size and outline, even differing considerably on the two sides in the same individual. Posteriorly they rest upon the recto-vesical fascia and rectum. Upon the medial side of each vesicle is the lower, enlarged, convoluted end of the vas deferens (*ductus deferens*). The triangular area of the bladder located between the diverging vasa deferentia (*ductus deferentes*) and seminal vesicles rests upon the rectum and corresponds with the trigone of the bladder. The seminal vesicles are covered by a fibrous sheath, which is derived from the recto-vesical fascia and contains some involuntary muscle tissue. When this sheath is removed, the seminal vesicles are observed to be tortuous tubes ten to twelve centimeters (four to five inches) in length. Each tube is about the width of a goose-quill, presents several blind branches or diverticula, is closed at its upper end, and opens below into the ejaculatory duct.

Blood Supply.—The blood supply of the seminal vesicles is derived from the inferior vesical and middle hemorrhoidal arteries.

Nerve Supply.—The nerve supply is from the pelvic sympathetic plexuses.

Function.—The function of the seminal vesicles is to secrete a fluid which augments the bulk of the semen.

The **vas deferens** (**ductus deferens**), the duct of the testis, is the continuation of the epididymis, and extends from the globus minor (*cauda epididymidis*) to the prostatic portion of the urethra. It passes upward in the spermatic cord and enters the abdominal cavity through the internal abdominal (*abdominal inguinal*) ring, where it lies to the lateral side of the deep (*inferior*) epigastric artery. Thence it runs in the extraperitoneal fat anterior and medial to the external iliac vessels and obliterated hypogastric (*umbilical*) artery, and passes into the pelvis to the side of the bladder. It passes downward and backward upon the side of the bladder to its base, running between the bladder and the ureter, and then

PLATE CCCCL.

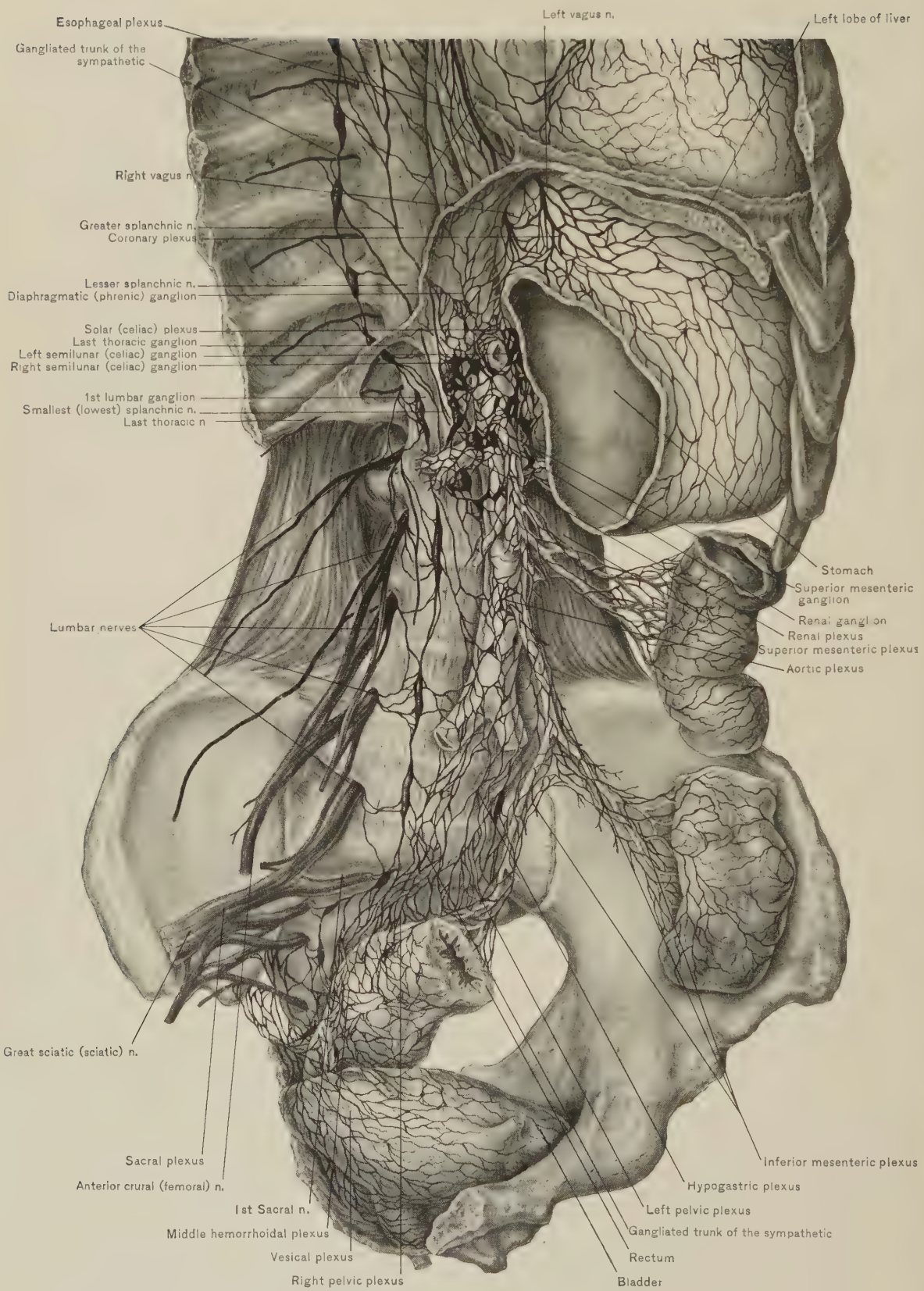

SYMPATHETIC PLEXUS.

medial to the latter. It runs along the medial side of the seminal vesicle between the base of the bladder and the rectum as a dilated tube, or *ampulla*, which contains pouches, or *sacculi*. Opposite the base of the prostate it abruptly becomes narrow and joins the open end of the seminal vesicle to form the ejaculatory duct.

According to its relations and position during its course and extent, the vas deferens (*ductus deferens*) may be divided into four portions: the **testicular portion,** extending along the epididymis from the globus minor (*cauda*) to the top of the testicle; the **funicular portion,** extending from the latter point to the external abdominal (*subcutaneous inguinal*) ring; the **inguinal portion,** occupying the inguinal canal, and the **pelvic portion,** extending from the internal abdominal (*abdominal inguinal*) ring to the termination at the ejaculatory duct.

The vas deferens (*ductus deferens*) is about sixty centimeters (twenty-four inches) long, fifteen centimeters (six inches) being situated in the spermatic cord and along the epididymis, and the balance in the general abdominal cavity. In the terminal dilated portion of the duct its walls are comparatively thin and its lumen large. The diameter of this portion of the duct is about two and a half millimeters (one-tenth of an inch), the wall is about one millimeter (one twenty-fifth of an inch) thick, and its lumen measures about one half a millimeter (one-fiftieth of an inch). The thickness of its walls gives the duct its cord-like character.

The **ejaculatory duct,** one on each side, is formed by the union of the excretory duct of the seminal vesicle and vas the deferens (*ductus deferens*) opposite the base of the prostate, and passes forward, downward, and medialward, behind the middle lobe of the prostate and through the prostatic fissure to open into the floor of the prostatic urethra on the verumontanum (*urethral crest*) at the lateral margin of the sinus pocularis (*prostatic utricle*). It lies close to its fellow of the opposite side, near the median plane.

The vas deferens (*ductus deferens*), seminal vesicle, and the ejaculatory duct consist of smooth or non-striated muscle, ensheathed in fibrous tissue and lined with mucous membrane. It is about three millimeters (one-eighth of an inch) wide above, and narrows to about one millimeter (one twenty-fifth of an inch) near its termination, its lumen decreasing to one half a millimeter (one-fiftieth of an inch). It is about two centimeters (three-fourths of an inch) in length.

The **nerves of the pelvis** are the sympathetic and the spinal.

The **sympathetic nerve trunks** (Plate CCCCL) of the pelvis, like those of the neck, thorax, and abdomen, are arranged in two chains of ganglia. The trunk enters the pelvis in front of the ala of the sacrum. Each chain is composed of four or five ganglia which are situated upon each side of the front of the sacrum medial to the anterior sacral foramina, the adjacent ganglia being connected by non-

medullated nerve-fibers. As it descends it passes in front of the branches of the middle sacral artery, behind the peritoneum and pelvic colon. Branches from the lowest ganglia on each side join together upon the front of the coccyx behind the rectum into a single small ganglion, *the ganglion impar.* The *lateral branches* of these ganglia, two from each ganglion, like those higher up, communicate with the corresponding sacral nerves, the last one either with the last sacral or the coccygeal nerve. The medial branches communicate with the opposite counterparts across the front of the sacrum, the upper two branches sending filaments to the hypogastric and pelvic plexuses, while the others form a plexus which accompanies the middle sacral artery.

The **hypogastric plexus** of nerves lies upon the sacral promontory between the common iliac arteries and behind the left common iliac vein; it is formed by filaments from the aortic plexus, lumbar ganglia, and first two sacral ganglia. It contains no ganglia and divides below into the two inferior hypogastric or pelvic plexuses. It sends filaments to the pelvic viscera.

The **pelvic**, or **inferior hypogastric, plexuses** are downward and forward continuations of the bifurcated hypogastric plexus, receiving reinforcing filaments from the second, third, and fourth sacral nerves, which are para-sympathetic in origin, and from the sacral ganglia. These plexuses lie upon the sides of the rectum. Branches following the course of the corresponding blood-vessels are given off to the pelvic viscera.

The middle **hemorrhoidal plexus** arises from the back part of the pelvic plexus. It supplies the rectum and inosculates with the inferior mesenteric plexus above, and branches of the internal pudendal nerve below.

The **vesical plexus** is derived from the pelvic plexus and chiefly from the fibers derived from the third and fourth sacral nerves. It supplies the bladder, upon the sides and base of which its branches accompany the vesical arteries. The plexus contains many medullated nerve-fibers which are derived from the spinal nerves. They send filaments to the seminal vesicles and vas deferens (*ductus deferens*), some of the latter continuing in the spermatic cord with the spermatic plexus.

The **prostatic plexus** lies below the vesical plexus, is connected with it, and is formed by large nerves given off from the lower part of the pelvic plexuses. The prostatic plexus is continued forward through the triangular ligament *urogenital diaphragm* on each side to form the **cavernous plexus** of the penis.

Along the side of the prostate, are the ganglia prostatica, from six to twelve millimeters (one-fourth to one-half inch) in length. Branches of these ganglia pass to the prostate, to the seminal vesicles, and to the corpora cavernosa of the

penis in the male and the clitoris in the female. These last-named are called *cavernous nerves.*

The **vaginal plexus** is formed from the lower part of the pelvic plexus, and supplies the mucous lining of the vagina, the erectile tissue at its forward part, and the clitoris. It contains many medullated nerve-fibers derived from the spinal nerves.

The **uterine (utero-vaginal) plexus** is also derived from the lower part of the pelvic plexus, but above its accessions from the sacral nerves. It passes between the folds of the broad ligament in company with the uterine arteries, and its branches, together with others from the ovarian plexus, enter the substance of the uterus to supply that organ.

The **spinal nerves in the pelvis** are the sacral and coccygeal.

There are five *sacral nerves* on each side. They all pass through the sacral foramina except the last sacral which emerges from the spinal canal between the sacrum and coccyx, and communicate with the gangliated trunk of the sympathetic by rami communicantes. They divide into anterior and posterior branches.

The *posterior divisions of the sacral nerves* have been described with the back of the neck, shoulders, and trunk.

The *anterior divisions of the sacral nerves* are much larger than the posterior divisions, and grow smaller from above downward. The first and parts of the second, third and fourth sacral nerves, together with the lumbo-sacral trunk, form the sacral plexus. The *pudental plexus* is formed by parts of the anterior rami of the second, third and fourth sacral nerves.

The *fourth sacral nerve* divides into an ascending branch which enters the sacral plexus, and a descending branch which enters the coccygeal plexus. The nerve also gives off muscular and cutaneous branches. A *perineal branch* pierces the floor of the pelvis by passing between the coccygeus and levator ani muscles, and near the tip of the coccyx supplies filaments to the external sphincter ani muscle and skin. A *gluteal cutaneous* or perforating cutaneous *branch,* which may arise from the second and third sacral, pierces the great sacro-sciatic (*sacro-tuberous*) ligament, runs under the gluteus maximus muscle, winds around the lower border of the muscle, and supplies the skin over its lower and medial part. *Muscular branches* supply the levator ani and coccygeus muscles.

The *anterior division of the fifth sacral nerve* divides into an ascending and a descending branch which assist in forming the coccygeal plexus.

The *coccygeal plexus* is formed by the anterior division of the last three spinal nerves: the descending branch of the fourth sacral nerve, the ascending and descending branches of the fifth sacral nerve, and the coccygeal nerve. Some

of the branches of this plexus enter the hypogastric plexus, and others supply the coccygeus and gluteus maximus muscles and the skin over the coccyx.

The *anterior division of the coccygeal nerves* supplies the coccygeus muscle and filaments to the gluteus maximus.

The **sacral plexus** (Plate CCCCLI) is formed by the anterior divisions of some of the lower spinal nerves. Just below the brim of the pelvis a part of the anterior division of the fourth lumbar joins the anterior division of the fifth lumbar nerve to form the *lumbo-sacral trunk*. This trunk joins the anterior divisions of the first and parts of the second and third sacral nerves to form the sacral plexus, the fourth sacral nerve also contributing to it by supplying a branch to the pudendal nerve. Therefore, the sacral plexus is formed by these nerves and the lumbo-sacral trunk. The shape of the plexus is triangular, with the base of the triangle situated at the intervertebral foramina, while the apex formed by the branches of the plexus is at the lower part of the great sacro-sciatic (*greater sciatic*) foramen. The sacral plexus lies in front of the pyriformis muscle, and is covered anteriorly by the parietal pelvic fascia which separates it from the pelvic vessels and viscera. The uppermost roots are longer than the lowermost. The sciatic (*inferior gluteal*) artery passes between the nerve-roots at the lower part of the plexus, and the superior gluteal artery between the lumbo-sacral trunk and the anterior division of the first sacral nerve. The *branches* of this plexus, divided into *collateral* and *terminal*, are: the great sciatic (*sciatic*) and small sciatic (*posterior cutaneous* of *thigh*), pudendal, superior and inferior gluteal, muscular, and visceral. The *collateral* branches are the superior and inferior gluteal, the small sciatic (*posterior cutaneous of thigh*), muscular, and visceral. The *terminal* branches are the great sciatic (*sciatic*) and the pudendal nerves.

The *great sciatic* (*sciatic*) *nerve* (Plate CCCCLII) is the continuation of the apex of the sacral plexus. It contains fibers from all the nerves of the plexus. It is the largest nerve in the body, being twelve millimeters (half an inch) in width and nearly half as thick. It leaves the pelvis through the great sacro-sciatic (*greater sciatic*) foramen, usually under the pyriformis, but sometimes over or through it, or it may even be pierced by that muscle. It may also consist of two strands, one perforating the muscle and the other passing either above or below it. These strands may reunite below the muscle or continue as the *external* popliteal (*common peroneal*) and *internal popliteal* (*tibial*) *nerves*. Below the pyriformis, the great sciatic (*sciatic*) nerve is covered by the gluteus maximus muscle and the upper end of the long head of the biceps femoris, and passes downward over the lateral rotators of the thigh, between the tuber ischii and trochanter major, but nearer the tuber ischii. The remainder of its course is described with the lower extremity.

PLATE CCCCLI.

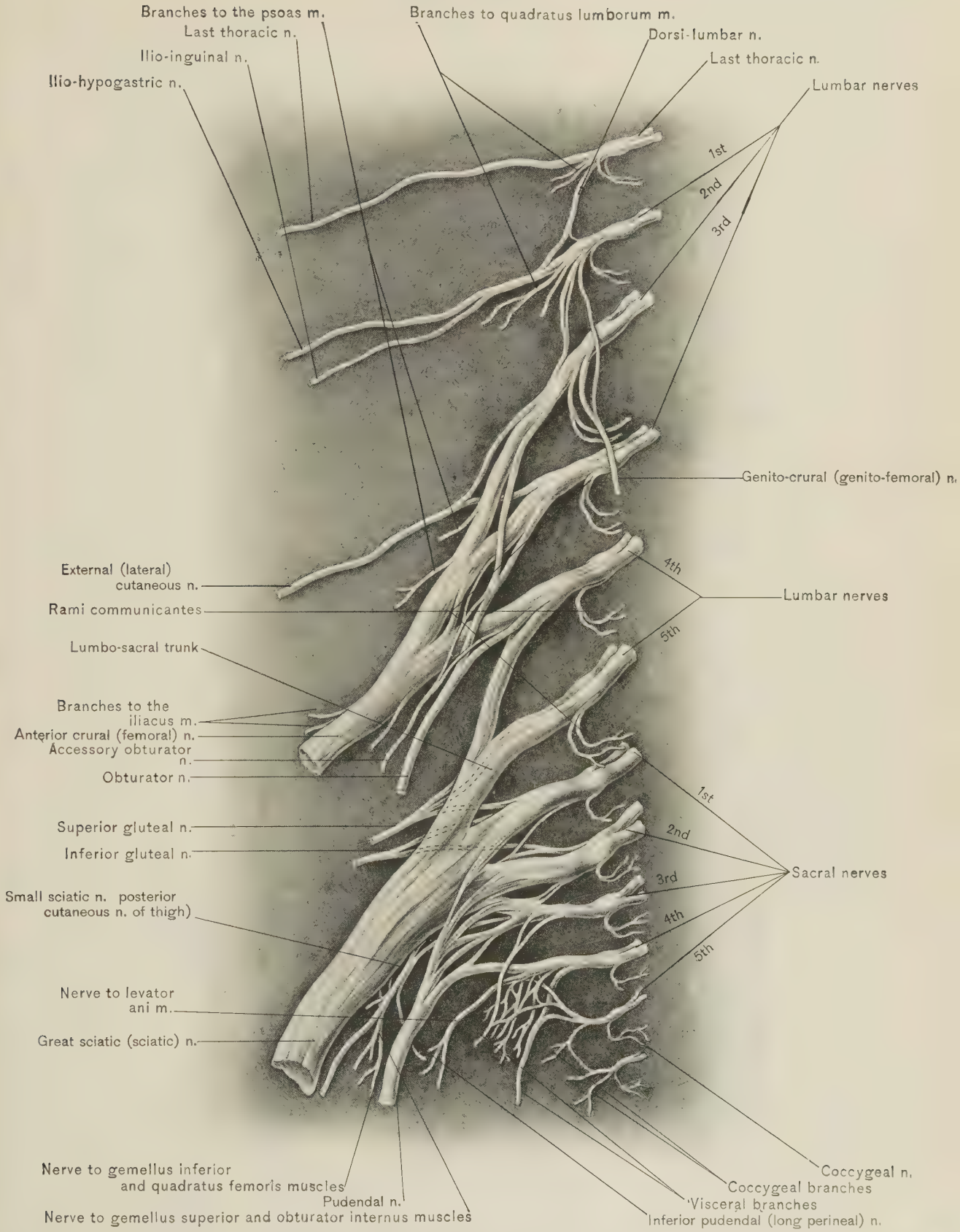

DIAGRAM OF THE LUMBAR AND SACRAL PLEXUSES.

PLATE CCCCLII.

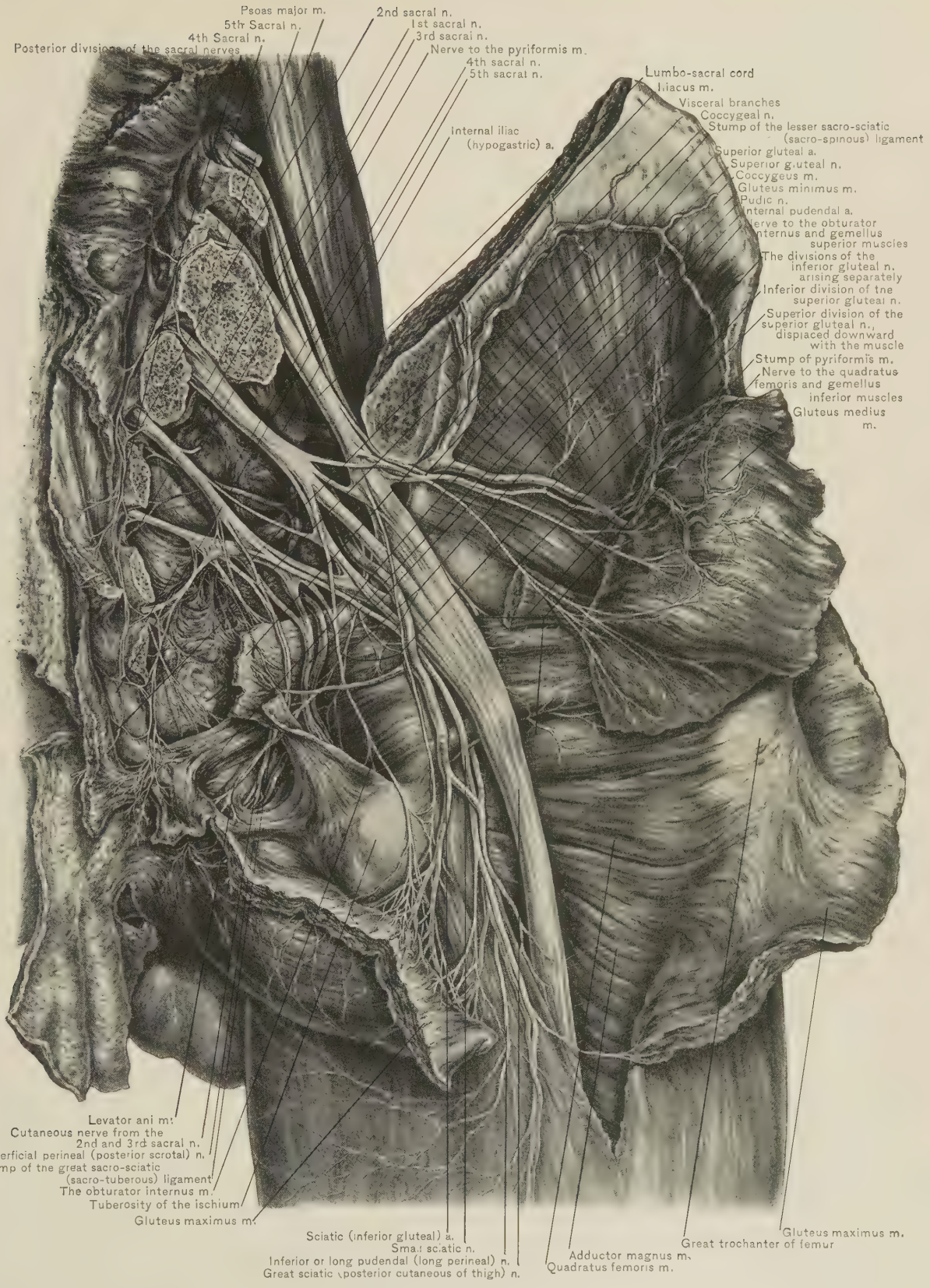
Psoas major m.
5th Sacral n.
4th Sacral n.
Posterior divisions of the sacral nerves
2nd sacral n.
1st sacral n.
3rd sacral n.
Nerve to the pyriformis m.
4th sacral n.
5th sacral n.
Lumbo-sacral cord
Iliacus m.
Visceral branches
Coccygeal n.
Stump of the lesser sacro-sciatic (sacro-spinous) ligament
internal iliac (hypogastric) a.
Superior gluteal a.
Superior gluteal n.
Coccygeus m.
Gluteus minimus m.
Pudic n.
Internal pudendal a.
Nerve to the obturator internus and gemellus superior muscles
The divisions of the inferior gluteal n. arising separately
Inferior division of the superior gluteal n.
Superior division of the superior gluteal n., displaced downward with the muscle
Stump of pyriformis m.
Nerve to the quadratus femoris and gemellus inferior muscles
Gluteus medius m.
Levator ani m.
Cutaneous nerve from the 2nd and 3rd sacral n.
Superficial perineal (posterior scrotal) n.
Stump of the great sacro-sciatic (sacro-tuberous) ligament
The obturator internus m.
Tuberosity of the ischium
Gluteus maximus m.
Sciatic (inferior gluteal) a.
Small sciatic n.
Inferior or long pudendal (long perineal) n.
Great sciatic (posterior cutaneous of thigh) n.
Adductor magnus m.
Quadratus femoris m.
Gluteus maximus m.
Great trochanter of femur

THE SACRAL PLEXUS.

The *pudendal nerve* arises from the second, third, and fourth sacral nerves. It is often discussed under the *pudendal plexus*. It passes out of the pelvis through the great sacro-sciatic (*greater sciatic*) foramen, below the pyriformis muscle, accompanies the internal pudendal vessels across the spine of the ischium, reenters the pelvis by way of the lesser sacro-sciatic (*lesser sciatic*) foramen, and, ensheathed by the obturator fascia, passes forward in the lateral wall of the ischio-rectal fossa and divides into the perineal and dorsalis penis nerves. The pudendal nerve, as it passes through the lesser sacro-sciatic (*lesser sciatic*) foramen, usually gives off the *inferior hemorrhoidal nerve* which is accompanied by the *inferior hemorrhoidal vessels*. It crosses the ischio-rectal fossa to the lower end of the rectum, where it supplies muscular branches to the external sphincter ani, cutaneous filaments to the peri-anal integument, and communicating branches to the inferior pudendal (*long perineal*) and superficial perineal (*posterior labial or scrotal*) nerves. The perineal and dorsalis penis nerves are described in the discussion of the perineum and penis, respectively.

The *superior gluteal nerve* arises from the lumbo-sacral trunk and the first sacral nerve. With the superior gluteal artery, it enters the gluteal region through the great sacro-sciatic (*greater sciatic*) foramen above the pyriformis muscle. Like the artery, it divides into a superior and an inferior branch; these branches run between the gluteus medius and gluteus minimus muscles. The *superior branch* supplies the gluteus medius and gluteus minimus; the *inferior branch* supplies these muscles and the tensor fasciæ femoris (*tensor fasciæ latæ*) muscle.

The *inferior gluteal nerve* arises from the second and third sacral nerves, and leaves the pelvis through the great sacro-sciatic (*greater sciatic*) foramen below the pyriformis muscle. It supplies the gluteus maximus muscle. As it is usually adherent to the small sciatic nerve, (*posterior cutaneous nerve of thigh*) it is sometimes described as a branch of that nerve.

The *small sciatic nerve* (*posterior cutaneous nerve of thigh*) arises from the posterior surface of the second and third sacral nerves. It leaves the pelvis through the great sacro-sciatic (*greater sciatic*) foramen below the pyriformis muscle, running downward on the posterior surface of the great sciatic (*sciatic*) nerve, and is accompanied by the sciatic (*inferior gluteal*) artery in its downward passage beneath the gluteus maximus, to which muscle it gives a branch that probably is derived from the inferior gluteal nerve which is adherent to the small sciatic nerve (*posterior cutaneous nerve of thigh*) in this region. Its further course is described with the lower extremity and its inferior pudendal (*long perineal*) branch with the perineum.

The *muscular branches* of the sacral plexus supply the pyriformis, obturator internus, two gemelli, and quadratus femoris muscles.

The *nerve to the pyriformis muscle* arises from the first, second, or first and second sacral nerves.

The *nerve to the obturator internus muscle* arises from the cord formed by the union of the lumbo-sacral trunk with the first sacral nerve. It accompanies the internal pudendal vessels and pudendal nerve through the great sacro-sciatic (*greater sciatic*) foramen, over the spine of the ischium, and through the lesser sacro-sciatic (*lesser sciatic*) foramen to the medial surface of the obturator internus muscle which it supplies. It also gives a branch to the superior gemellus muscle. Another branch to the superior gemellus muscle is given off from the lower part of the sacral plexus.

The *nerve to the quadratus femoris muscle* is a branch of the third sacral nerve and also supplies the inferior gemellus muscle. It passes through the lower part of the great sacro-sciatic (*greater sciatic*) foramen, and then beneath the gemelli muscles and the tendon of the obturator internus and over the capsule of the hip-joint to the anterior or deep surface of the quadratus femoris. It also sends an *articular branch* to the hip-joint.

The *visceral branches of the sacral plexus* (white rami communicantes) are derived from the third, fourth, and fifth sacral nerves. They enter the pelvic or inferior hypogastric plexus and from these to the pelvic viscera.

The **uterus,** or **womb** (Plate CCCCLIII), is a hollow viscus with thick muscular walls and projects upward from the vagina into the pelvic cavity between the rectum and the bladder. It is pyriform in shape with flattened anterior and posterior surfaces. It is about seven and a half centimeters (three inches) long, five centimeters (two inches) wide at its broadest part, and about two and a half centimeters (one inch) thick from before backward. The weight of the virgin uterus is about twenty-eight grams (seven drams), that of the postparous organ about forty-eight grams (twelve drams). The uterus is divided into a body, an isthmus, and a cervix, or neck.

The **body of the uterus** has the form of a truncated cone whose apex is at the isthmus. The base of the cone, or the *fundus,* is rounded, directed upward, and is that portion of the uterus which projects above the entrance of the Fallopian (*uterine*) tubes, and forms the roof of the uterine cavity. The body has two surfaces, three margins, and two superior angles. The *anterior surface* is flattened, and covered by peritoneum, which at the level of the isthmus is reflected upon the bladder, forming the utero-vesical pouch. This surface is in relation with the peritoneum and the bladder. Usually there are no intestinal coils between the uterus and the bladder, although in parous women the fundus may point somewhat backward, and some portion of the intestine may then occupy the utero-vesical pouch. The *posterior surface* is convex and covered

PLATE CCCCLIII.

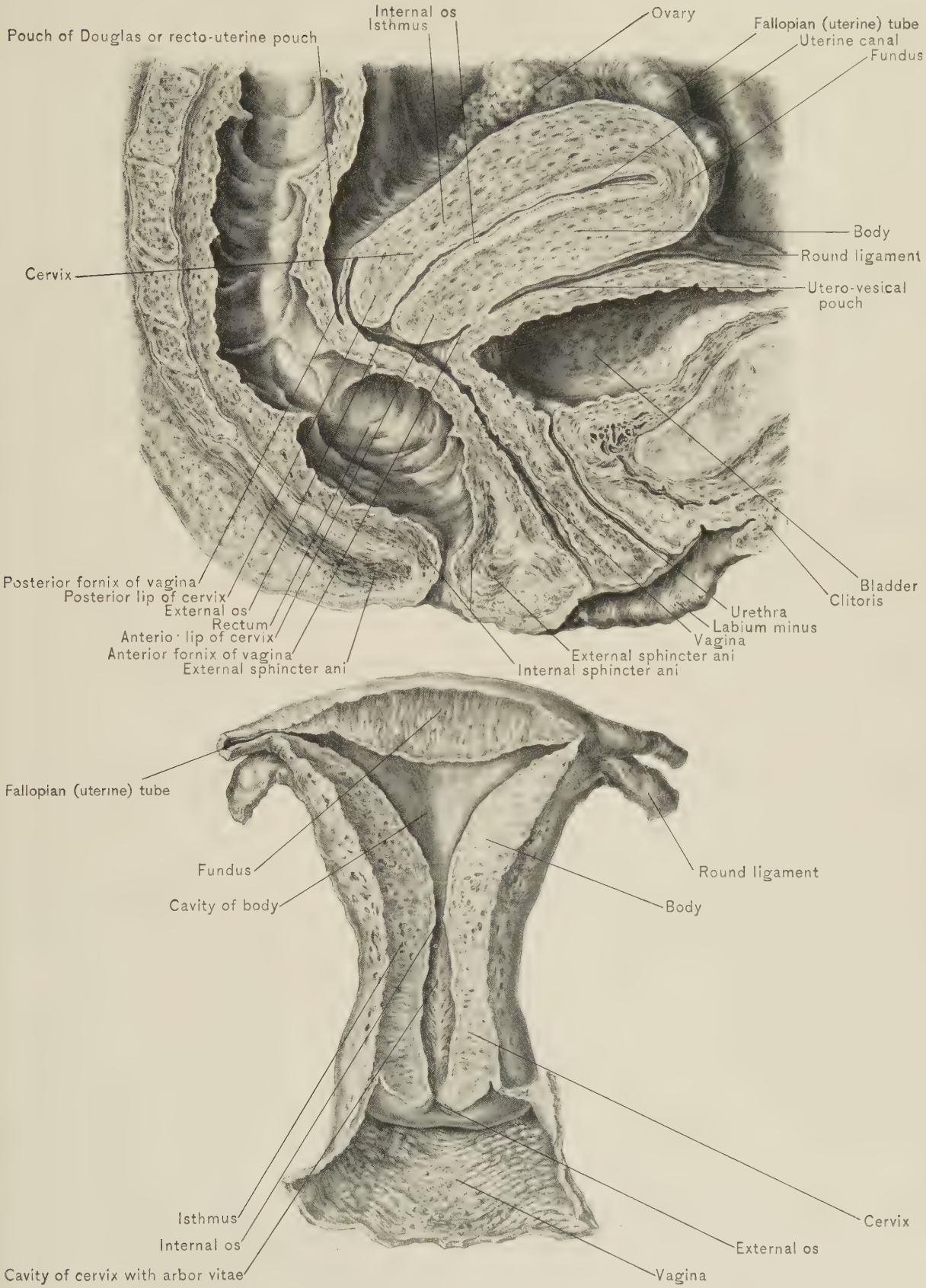

SECTIONS OF UTERUS AND VAGINA.

by peritoneum which descends to the posterior wall of the vagina, from which it is reflected to the rectum and forms the recto-uterine pouch, or the pouch of Douglas. This pouch is slightly deeper on the left than on the right side. This surface is in relation with the peritoneum, rectum, coils of small intestine, and sigmoid flexure. The *lateral margins* give attachment to the broad and round ligaments, which swing the uterus in the pelvic cavity, and to the ovarian ligaments. The superior border of the uterus is rounded and is covered by peritoneum. From the *superior angles*, or *cornua*, of the uterus extend the Fallopian (*uterine*) tubes.

The **isthmus** is the narrow or constricted part of the uterus situated at the junction of the body and the cervix. It is most marked in infants, but becomes less apparent as puberty approaches, and may disappear entirely after parturition. In the virgin uterus it is located at about the middle of the organ, while in the post-parous uterus it is found at the junction of its middle and lower thirds. The isthmus is the weak part of the organ, where pathologic flexures occur, and where rupture during parturition is most likely to take place.

The **cervix** is the lowest of the three portions of the uterus and projects downward into the vagina through the upper end of the anterior wall. In the virgin it comprises one-half of the length of the uterus; in the parous organ, about one-third. It is cylindrical in form and constricted at each end. Its surface may be divided into a supravaginal portion, a zone of vaginal attachment, and an intravaginal portion. The *supravaginal portion* composes two-thirds of the cervix anteriorly and about one-half of it posteriorly. Anteriorly it is in relation with the bladder, posteriorly it is covered by peritoneum, and laterally is attached to the broad ligaments and is in relation with the uterine vessels and the ureter which is eight to fifteen millimeters (one-third to three-fifths of an inch) from the cervix. The *zone of vaginal attachment* is placed highest posteriorly and inclines downward as the anterior surface of the cervix is approached. For that reason the anterior wall of the intravaginal portion is less than one-third of the anterior wall of the cervix, although on the posterior wall the intravaginal portion is one-half the length of the cervix. The *intravaginal portion* of the cervix is a cone-shaped body, the extremity of which presents the external opening of the cavity of the uterus, the *external os*. In the virgin the external os is a rounded opening, but after childbirth it takes the form of a transverse slit. Under the latter condition it is very easy to divide the lower end of the cervix into an *anterior* and a *posterior lip*. The anterior lip is lower than the posterior, but, owing to the higher attachment of the vaginal wall behind, the posterior lip appears to be longer. These lips usually become notched and irregular in outline after childbirth due to laceration of the cervix. This

may be unilateral, bilateral, or stellate, and may require repair. Carcinoma is more likely to develop in a cervix that has been torn than in an uninjured one. A smooth mucous membrane, similar to that of the vagina, covers the intravaginal portion of the cervix.

Atresia of the cervix may result from injuries, operations, or the application of caustics; or it may be a congenital condition. It causes retention of the menstrual fluid, as soon as menstruation begins, the uterus and Fallopian (*uterine*) tubes becoming distended with blood, a condition known as hematometra, which blood may escape into the pelvic cavity and accumulates in Douglas' (*recto-uterine*) pouch. This condition requires reëstablishment of the cervical canal or, if this is impossible, hysterectomy.

The position of the uterus is normally in the anterior and central portion of the female pelvis, slightly to the left of the median line, between the bladder and the rectum. Owing to the firm attachments of the ligaments that hold it in position the cervix is not very mobile. The position of the fundus is very variable, but it usually points in the direction of the long axis of the body. Distention of the bladder and the rectum and intra-abdominal pressure change the position of the fundus, while circumstances that diminish or modify the support of the organ, such as tears of the pelvic floor, usually bring about displacements of the entire organ.

The displacements of the uterus that may occur are anteversion, anteflexion, retroversion, retroflexion, prolapse, and inversion.

The uterus in nullipara is usually found anteflexed or anteverted. In retroversion and retroflexion the fundus is found turned backward and can be felt through the rectum, lying in the curve of the sacrum, where it may be caught during pregnancy by the promontory of the sacrum. If this should occur an immediate attempt, under anesthesia if necessary, should be made to release it. If this is not done, or if the condition does not correct itself miscarriage may result.

By anteversion is meant a turning forward of the entire organ, while anteflexion signifies that the fundus is bent forward upon itself at the isthmus, so as to form an angle with the cervix. When the uterus occupies these positions, coils of small intestine and the sigmoid flexure rest upon the posterior surface of the organ and lie in Douglas' (*recto-uterine*) pouch. When the uterus is retroflexed or retroverted, the intestines occupy the utero-vesical pouch.

Anteversion and anteflexion may be caused by strong sacro-uterine ligaments, by firm attachment of the organ to the base of the bladder, or by an imperfectly developed vagina. Retroflexion and retroversion are brought about by the relaxation of the broad, sacro-uterine, and round ligaments, intra-abdominal

pressure being the direct cause of the displacement, and injuries to the pelvic floor usually the primary factor.

Prolapse of the uterus is caused by the relaxation of the pelvic floor and intra-abdominal pressure, the uterus descending to the vaginal outlet, after carrying the vagina and bladder with it. Inversion of the uterus is a condition in which the organ is turned inside out and forced downward toward the vulvar orifice.

The **cavity of the uterus** is about six and a quarter centimeters (two and one-half inches) long in the virgin and seven and a half centimeters (three inches) in length in the postparous womb, and its anterior and posterior walls are normally in contact. It is divided into three portions: the cervical canal, the internal os, and the cavity of the body. The *cervical canal* is about two and a half centimeters (one inch) long, and is spindle-shaped. On its anterior and posterior walls are found ridges, formed by longitudinal folds of mucous membrane, from which other folds extend obliquely; these folds are called the *arbor vitæ* (*plicæ palmatæ*). The arbor vitæ (*plicæ palmatæ*) are usually obliterated after the first childbirth. The mucous membrane which lines the cervical canal contains numerous small mucous glands, the glands of Naboth, which secrete a thick, tenacious mucus. At times the ducts of these follicles become occluded, and the glands become distended with their secretion, thus forming small cysts, called *ovules of Naboth*, or Nabothian cysts. The *internal os* is the narrowest part of the cavity of the uterus, and is within the isthmus of the uterus. It is about six millimeters (one-quarter of an inch) long and about three millimeters (one-eighth of an inch) in diameter. The longitudinal limbs of the arbor vitæ (*plicæ palmatæ*) extend to its upper end. The internal os leads from the cervical canal to the cavity of the body of the uterus. The *cavity of the body of the uterus* is triangular, with curved sides and smooth surfaces. It is lined with a smooth mucous membrane which is firmly attached to the muscular coat with little, if any, intervening connective tissue. This membrane contains numerous tubular follicles which become enormously enlarged during pregnancy. At each of the upper angles the cavity is funnel-shaped, and ends in the opening of the corresponding Fallopian (*uterine*) tube.

The relation of the length of the body of the uterus to that of the cervix alters after childbirth; in nullipara, the body is only a little longer than the neck but it forms fully two-thirds of the entire organ in those who have borne children.

The **wall of the uterus** is composed of serous, muscular, and mucous coats.

The *serous coat* is composed of peritoneum, and covers all of the uterus with the exception of the intravaginal portion of the cervix, and the anterior surface and sides of the supravaginal portion of the cervix.

The *muscular coat* consists of three layers of fibers which become very marked in the pregnant uterus. The *outer layer* is longitudinal and sends prolongations into the round, ovarian, and sacro-uterine ligaments, and into the Fallopian (*uterine*) tubes. The *middle layer* is composed of interlacing longitudinal and transverse fibers, some of which are continued into the muscular coat of the vagina. This layer is very thick, and contains venous plexuses. The innermost fibers form *sphincters* at the internal os and the orifice of the Fallopian (*uterine*) tubes. The *internal layer* is composed of longitudinal fibers and is quite thin. Its fibers are found in the arbor vitæ (*plicæ palmatæ*) in the cervical canal. The blood-vessels ramify through the middle layer.

The *mucous coat* lines the entire cavity of the uterus. It varies in thickness in different parts, being much thinner in the body than in the cervix. It is lined with ciliated columnar epithelium down to the external os, where a gradual transition into laminated squamous epithelium takes place. It contains the small, tubular, utricular glands. In the cervical canal these mucous glands may become distended, and are then known as ovules of Naboth.

Blood Supply (Plate CCCCLIV).—The blood supply of the uterus is derived chiefly from the uterine and the ovarian arteries. A small amount is supplied through the funicular artery or the artery to the round ligament, which is a branch of the superior vesical. The course of the uterine artery to its anastomosis with the ovarian artery has been described at p. 570. It sends numerous branches to supply the muscle of the organ. The *ovarian artery* is a branch of the aorta. After crossing the brim of the pelvis, in front of either the common or the external iliac artery, the ovarian artery passes medialward, between the folds of the broad ligament, sending branches to the ovary, the Fallopian (*uterine*) tube, and a terminal branch to anastomose with the uterine artery. During pregnancy the uterine artery does not increase in size to any appreciable extent. It loses its tortuous character and becomes a straight vessel which lies along the side of the uterus; while the ovarian artery becomes much larger than the uterine.

The **veins of the uterus** form a network in the muscular coat of the organ and open into the *uterine plexus of veins* which is found along the side of the uterus. At the upper end of this plexus there is a communication with the ovarian vein, and at the lower extremity with the vaginal and vesical plexuses. Near the middle of the plexus the *uterine vein* arises. It follows the course of the uterine artery and empties into the internal iliac (*hypogastric*) vein. Unlike the artery, it is not tortuous.

The **lymphatics of the uterus** consist of a superficial and a deep set. The superficial set is subperitoneal, and the deep set is found in the substance of the uterus. The lymphatics from the cervix and vagina, with the exception of

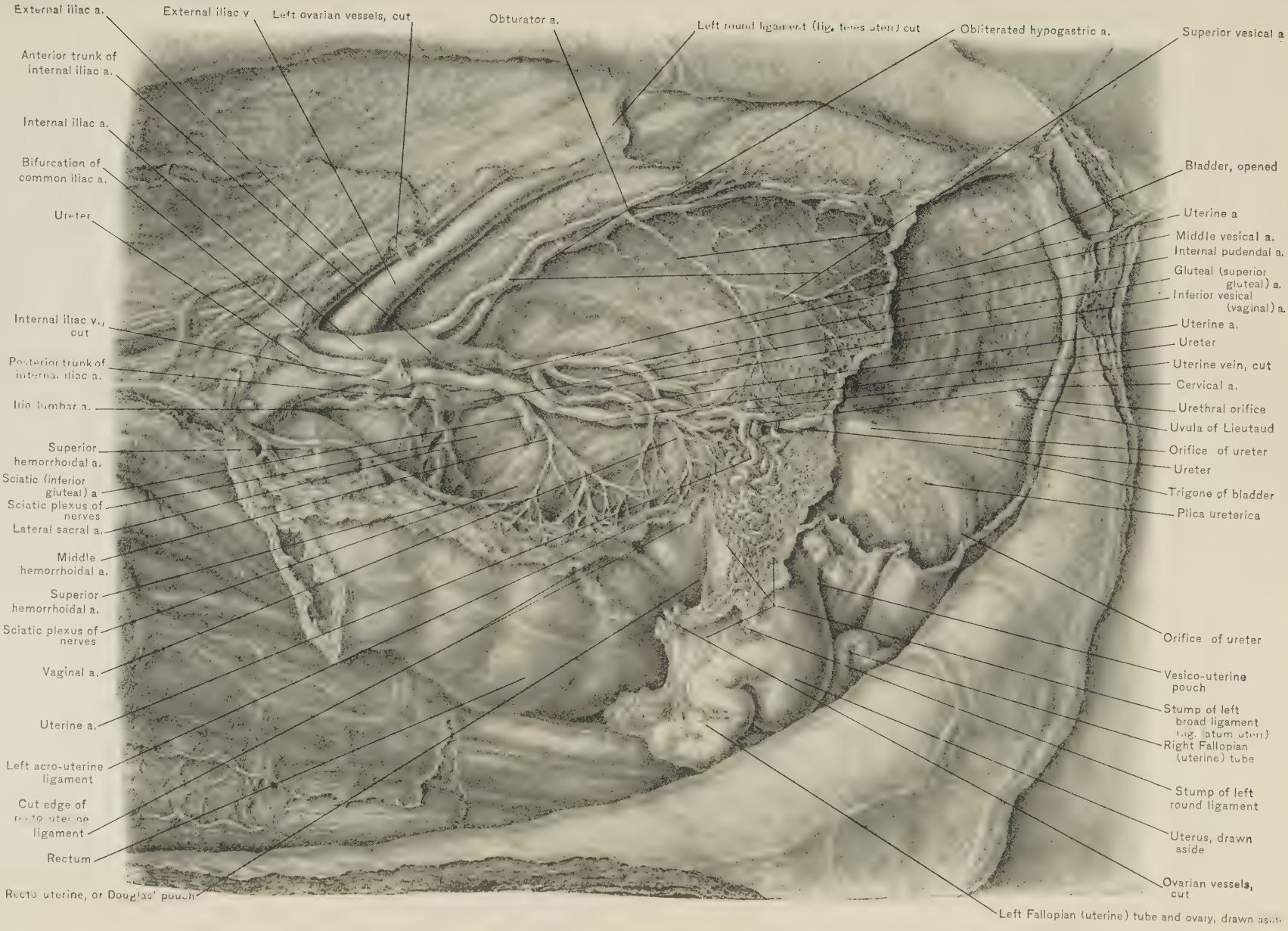
External iliac a.
External iliac v
Left ovarian vessels, cut
Obturator a.
Left round ligament (lig. teres uteri) cut
Obliterated hypogastric a.
Superior vesical a
Anterior trunk of internal iliac a.
Internal iliac a.
Bifurcation of common iliac a.
Ureter
Bladder, opened
Uterine a
Middle vesical a.
Internal pudendal a.
Gluteal (superior gluteal) a.
Inferior vesical (vaginal) a.
Uterine a.
Ureter
Uterine vein, cut
Cervical a.
Urethral orifice
Uvula of Lieutaud
Orifice of ureter
Ureter
Trigone of bladder
Plica ureterica
Internal iliac v., cut
Posterior trunk of internal iliac a.
Ilio lumbar a.
Superior hemorrhoidal a.
Sciatic (inferior gluteal) a
Sciatic plexus of nerves
Lateral sacral a.
Middle hemorrhoidal a.
Superior hemorrhoidal a.
Sciatic plexus of nerves
Vaginal a.
Uterine a.
Left acro-uterine ligament
Cut edge of recto uterine ligament
Rectum
Recto uterine, or Douglas' pouch
Orifice of ureter
Vesico-uterine pouch
Stump of left broad ligament (lig. latum uteri)
Right Fallopian (uterine) tube
Stump of left round ligament
Uterus, drawn aside
Ovarian vessels, cut
Left Fallopian (uterine) tube and ovary, drawn aside

those from the vaginal outlet, terminate in the internal iliac (*hypogastric*) and sacral glands and glands on the rectum. Those from the body and fundus of the organ pass laterally between the layers of the broad ligament and join others from the ovaries, Fallopian (*uterine*) tubes, and broad ligaments. They accompany the ovarian artery as far as the lumbar glands, into which they empty. Another set empties into the glands around the external iliac artery, while still others follow the ligamentum teres to the glands of the groin. The uterine lymphatics are enormously enlarged during gestation.

Nerve Supply.—The nerve supply of the uterus is derived from the third and fourth sacral nerves and from the inferior hypogastric and ovarian sympathetic plexuses.

The **ligaments of the uterus** are of two kinds: peritoneal, or false, and fibro-muscular, or true. There are three pairs of false ligaments and four pairs of true ligaments, the *true ligaments* being found between the layers of peritoneum of the false ligaments. The *peritoneal*, or *false*, *ligaments* are two anterior, or vesico-uterine, two lateral, or broad, and two posterior, or recto-uterine.

The *two anterior*, or *vesico-uterine*, *ligaments* are poorly defined folds or layers of peritoneum, formed by the reflection of that membrane from the bladder to the uterus. They join the uterus at about the level of the internal os.

The *lateral*, or *broad*, *ligaments* (are formed by reflection of the peritoneum from the sides of the uterus and vagina transversely lateralward to the pelvic walls. They somewhat resemble the wing of a bat in shape. Between the two layers of each ligament are contained the following structures: the Fallopian (*uterine*) tube; the ovary and its ligaments; the parovarium; the duct of Gärtner (*longitudinal duct of epoöphoron*), which represents the lower part of the Wolffian duct, but is seldom seen in the human subject; the hydatids of Morgagni (*appendices vesiculosi*); the uterine and ovarian vessels; the uterine plexus of nerves; extraperitoneal connective tissue; and the following ligaments of the uterus, all of which are composed of muscle tissue: the round, the ovarian, and the utero-pelvic. The ureters are seen lying between the folds of the broad ligaments. The two layers of the broad ligament form a free margin above, but below they are reflected upon neighboring structures. Each ligament presents four borders: the superior, or tubal, the medial, or uterine, the lateral, or obturator, and the inferior or recto-vesical, the latter two borders deriving their name from their relation to the obturator and recto-vesical fasciæ. Each ligament presents an anterior and a posterior surface, the latter being broader vertically.

The *superior*, *tubal*, or *free border* is formed by the peritoneum in turning around the Fallopian (*uterine*) tube. At the lateral part of this border the posterior surface of the ligament is seen to form a sharp curved fold, with its con-

cavity directed lateralward, situated between the fimbriated extremity of the Fallopian *uterine* tube and the inferior, or recto-vesical, border, and is called the *infundibulo-pelvic* (*suspensory*) *ligament*, which transmits the ovarian vessels.

The *medial*, or *uterine*, *border* is attached to the side of the uterus and vagina, and gives passage to the loop between the uterine and ovarian arteries and to the uterine plexus of veins.

The *lateral*, or *obturator*, *border* lies against the obturator fascia and gives passage to the uterine vessels and the round ligament.

The *inferior*, or *recto-vesical*, *border* is directed toward the recto-vesical fascia and the levator ani muscle and between its layers contains subperitoneal connective tissue, fat, the uterine vessels and nerves, and the ureter.

The *false posterior*, or *recto-uterine*, *ligaments*, which are composed of peritoneum, are two single serous layers which pass backward from the posterior surface of the uterus and vagina to the upper portion of the rectum, where they are continuous with the peritoneal coat of the rectum. These folds of peritoneum form the lateral boundaries of the pouch of Douglas (*recto-uterine pouch*). Lateral to each of these false ligaments are found the true or muscular utero-sacral ligaments, extraperitoneal connective tissue, and anastomosing branches of the uterine and hemorrhoidal vessels.

The *muscular*, or *true*, *ligaments of the uterus* are found in four pairs running between the folds of the peritoneal ligaments. They are the round, the utero-sacral, the utero-pelvic, and the utero-ovarian ligaments.

The *round ligaments* are composed of muscular and connective tissue. They extend from the sides of the uterus to which they are attached immediately below and in front of the Fallopian (*uterine*) tubes, and describe a curve by passing upward and lateralward beneath the anterior layers of the broad ligaments to reach the brim of the pelvis. Each ligament then crosses the external iliac vessels and turns forward to the lateral side of the deep (*inferior*) epigastric artery, where it passes through the internal abdominal (*abdominal inguinal*) ring to enter the inguinal canal. In the inguinal canal it is accompanied by the remains of the processus vaginalis which at times remains patulous after birth and takes the name of the *canal of Nuck* (*vaginal process*). The round ligament while in the inguinal canal receives additional muscle fibers which correspond to the cremaster muscle of the male. It gives off other muscle fibers which strengthen the external abdominal (*subcutaneous inguinal*) ring, after which it passes through the external (*subcutaneous inguinal*) ring to be lost in small fasciculi which ramify through the connective tissue of the mons veneris (*mons pubis*). The *funicular artery*, a branch of the superior vesical, and a small plexus of veins are found in the round ligament. These ligaments become relaxed in backward displacements

of the uterus and are sometimes shortened in the inguinal canal or intra-abdominally to correct these displacements.

The *utero-sacral ligaments* are flat muscle bands, which extend from the uterus at the level of the internal os, beneath the layers of the recto-uterine ligaments, to the sides of the sacrum, opposite the lower borders of the sacro-iliac articulation. In the first part of their course they are in relation with the lateral walls of the pouch of Douglas (*recto-uterine pouch*) and finally run on each side of the rectum near the junction of the sigmoid flexure and the upper portion of the rectum.

The *utero-pelvic ligaments*, enclosed between the folds of the broad ligaments, are two bands of muscle fibers which pass from the pelvic fascia over the upper part of the internal obturator muscle to the sides of the uterus and the vagina. They ensheathe the uterine and vaginal vessels and nerves.

The *utero-ovarian ligaments*, or *ligaments of the ovaries*, are two rounded cords which spring from the muscle tissue of the uterus near its junction with the Fallopian (*uterine*) tubes. They pass between the layers of the broad ligaments to the attached border and medial end of the ovary.

Action.—The action of these various ligaments is to hold the uterus in its normal position and to convey to that organ its vessels and nerves, as well as to maintain the normal relations between the uterus and its appendages.

Hysterectomy.—The main anatomic points to be remembered in the removal of the uterus, either through the abdominal wall or through the vagina, are the following: the uterus is held in place by the broad, utero-vesical, and recto-uterine peritoneal ligaments and the muscular ligaments which are found within the serous folds. The blood supply of the uterus is furnished by the ovarian and uterine arteries. The ovarian artery is found in the broad ligament just below the Fallopian (*uterine*) tube and anastomoses, near the superior angle of the uterus, with the uterine artery. The uterine artery passes to the uterus between the two layers of the lower portion of the broad ligament, describing in its course a curve downward and backward within which is found a plexus of veins through which the ureter passes. It is here that the ureter may be injured in hysterectomy or in operations for the removal of cysts or fibroids in the layers of the broad ligament. The veins in the broad ligaments are in the form of a pampiniform plexus. The peritoneal covering of the uterus entirely surrounds that organ with the exception of the intravaginal portion of the cervix and the anterior surface of the supravaginal portion of the cervix. The vagina is attached to the cervix below the level of the internal os. In front, the uterus is closely connected with the bladder, and behind, with the rectum. Coils of small intestine are in relation with the fundus and posterior surface of the body of the uterus,

and to these or the greater omentum the organ may become adherent through inflammatory adhesions. The uterus is removed through the vagina (vaginal hysterectomy), or through an incision in the abdominal wall either through the linea alba or the rectus muscle. In the operation through the linea alba of the abdominal wall the incision passes through skin, superficial fascia, the aponeurosis of the external oblique, internal oblique and transversalis muscles blended at the linea alba, transversalis fascia, preperitoneal fat, and peritoneum. Many small vessels in the subcutaneous tissues will be severed, but their bleeding will be of no moment, as it is readily controlled. The hand is then passed into the abdominal cavity to ascertain the relations of the uterine appendages to the uterine tumor. There may be many adhesions found, and these will have to be either separated with the finger or cut between ligatures. The method of removal of the uterus depends to a great extent upon the method to be used in treating the stump. With the aid of a uterine forceps the uterus is brought up into the wound. If the stump is to be treated intraperitoneally, the next step is to ligate the ovarian vessels. The ovarian artery will be found in the upper portion of the broad ligament. It should be tied with two ligatures at the lateral side of the ovary and divided between them. Clamps are then applied doubly to the broad ligaments and the ligaments separated between these. If the tubes and ovaries are not removed the ovarian artery should be ligated to the medial side of the ovary and the tube ligated and its end cauterized. The uterine artery is found between the folds of the lower portion of the broad ligament. It should be severed between two ligatures near the uterus, care being taken to avoid the ureter which passes below the broad ligament, through the plexus of uterine veins found in the loop of the uterine artery, parallel with the cervix and from three-quarters to one and a half centimeters (one-third to three-fifths of an inch) from it, and over the upper part of the vaginal wall to reach the bladder. All ligatures must be firmly tied, preferably doubly, or there will be bleeding especially from the pampiniform plexus of veins found in the broad ligament. The mass is then brought into the wound and a cuff of peritoneum is reflected from the uterus beginning just above the level of the utero-vesical fold and extending to the level of the internal os. The bladder is carried forward with the anterior part of the cuff. The muscle of the uterus is then severed by a V-shaped incision and the uterus removed. There will be no hemorrhage following this step if the vessels have been properly ligated, as practically all the blood to the uterus is carried by the uterine and ovarian arteries. The stump is cauterized, the mucous membrane and musculature of the uterine canal are sutured, the sides of the V are firmly held together by sutures, and the peritoneal cuff is brought together by a continuous suture after the stumps of the tubes, if the tubes and ovaries

have not been removed, and the round ligaments have been sutured to the cervical stump.

In removing the entire organ through the abdomen, after having ligated the uterine and ovarian arteries and the broad ligament, a circular incision is made through the serous covering about thirteen millimeters (half an inch) above the utero-vesical fold. The attachment of the vaginal wall to the upper portion of the cervix is severed, and the cervix separated from its external mucous covering, care being taken to do all cutting and stripping close to the body of the cervix so as not to damage the ureter or the bladder. The mass is then removed and the vaginal walls allowed to fall into place and sutured from above. The peritoneum is then sutured and the abdomen closed. If the tubes and ovaries have not been removed, these with the round ligament must be sutured to the vaginal stump.

In removing the uterus through the vagina the cervix is forcibly drawn downward into the vulvar orifice and the anterior and posterior lips united by a row of sutures whose ends are allowed to remain long, being used to draw the organ downward. This suturing prevents the escape of any infectious material from the uterus. The posterior vaginal wall is incised around the cervix and close to it, and the vaginal wall pushed away from the cervix by the finger. When the peritoneum is reached in Douglas' (*recto-uterine*) pouch, it is incised from side to side. The anterior vaginal wall is then incised close to the cervix to avoid injuring the bladder, ureters, or uterine arteries. Upon reaching the vesico-uterine fold of peritoneum an incision is carried through it from side to side. The cervix is thus entirely freed and the base of the broad ligaments exposed. Ligatures are then passed through the broad ligament not further than thirteen millimeters (half an inch) from the lateral margin of the cervix, great care being taken to avoid including the ureters. With scissors the broad ligament is then cut away between the ligature and the uterus, keeping close to that organ. Any bleeding points are immediately ligated. The upper portions of the broad ligament are then ligated in the same manner. The tubes and ovaries are usually ligated at their uterine side, and allowed to remain, as it is difficult to carry a ligature lateral to them; and, owing to the tenseness of the infundibulo-pelvic (*suspensory*) ligament, such a ligature is liable to slip from the stump and cause bleeding from the ovarian vessels. After ligating the one broad ligament, the other can be more readily dealt with, and the uterus freed and removed. The peritoneum is sutured after all bleeding points have been controlled and the vaginal mucous membrane closed by interrupted sutures after this.

The **vagina** is a hollow tube which extends from the vulva to the cervix uteri. Its axis forms a curve whose concavity is directed forward. It is con-

tracted at its lower end, the *introitus vaginæ*, and widens in its ascent, becoming loose and roomy near its upper end, thus readily permitting the sweep of the examining finger around the pelvis in contact with its bony, fascial, and ligamentous walls. The vagina is a muscular tube lined with a rugous mucous membrane, and is strengthened upon its outside by condensed connective tissue. Like all tubular viscera, its wall contains longitudinal and transverse muscle fibers, the former being superficial. The canal lies between the bladder and urethra in front, and the rectum behind. The **mucous membrane of the vagina** is arranged similar to that of the cervix, except that its crosswise rugæ or folds are transverse instead of oblique. The anterior and posterior longitudinal folds are called the *anterior* and *posterior columns*. The mucous lining is continuous with that of the cervix and vulva, and consists of squamous epithelium. The arches formed by the reflection of the wall of the vagina upon the front and back of the cervix uteri are known as the *anterior fornix* and the *posterior fornix*, the latter being much larger and deeper because of the higher attachment of the vaginal wall on the posterior aspect of the cervix and consequent greater length of the posterior wall of the vagina. The walls of the vagina lie in contact, the anterior and posterior walls being in apposition; the anterior wall is about six and a quarter centimeters (two and one-half inches) and the posterior nine centimeters (three and one-half inches) in length. The direction of the vagina is upward and slightly backward. Its walls are elastic and readily elongated, for otherwise coitus would be impossible without excruciating pain and great danger of serious injury to the vagina. The inlet may be temporarily narrowed by the engorged bulbi vestibuli, or by the action of the constrictor vaginæ and levator ani muscles. As the lower end of the vagina pierces the triangular ligament (*urogenital diaphragm*), the orifice is rendered quite firm and unyielding.

Relations.—The vagina is surrounded by its sheath of pelvic fascia. In front of the vagina are the urethra, the base of the bladder, and the terminations of the ureters; the vesical orifices of the ureters lying in front of the vagina and about three centimeters (one and one-fourth inch) below the os uteri; behind it, are the perineal body, levator ani muscle, rectum, and the peritoneum forming the cul-de-sac of Douglas (*recto-uterine pouch*); its sides give attachment to the recto-vesical fascia, levator ani muscles, and broad ligaments, and the ureters pass obliquely forward along the sides in the upper third of the vagina.

The ducts of Gärtner (*longitudinal ducts of epoöphoron*), fetal remains, may be found alongside the lateral wall of the vagina in the upper half of its extent. These are the origin of the vaginal cysts of adult life. They are thin, fibrous cords and are regarded by some authors as ending in Skene's ducts, two little

PLATE CCCCLV.

EXTERNAL GENITALS OF VIRGIN.

orifices sometimes observed at the sides of the external urinary meatus. The lower end of the vagina is partially closed in the virgin by two crescentic folds of mucous membrane known as the **hymen.** After the hymen has been ruptured fragments of it persist and are known as the **carunculæ hymeneales.**

Blood Supply.—The blood supply of the vagina is very rich. The arteries are from the uterine, the vesical, the vaginal, the middle hemorrhoidal and the internal pudendal, all of which are branches of the internal iliac (*hypogastric*). The *vaginal veins* form a dense plexus which communicates with the plexuses of the uterus, bladder, rectum, broad ligament, and vulva. The blood finally reaches the internal iliac (*hypogastric*) vein.

The *lymphatics of the vagina* pass to the inguinal, sacral, and the external and internal iliac (*hypogastric*) glands. Some from the lower part pass forward to the perineum and thence to the groin.

Nerve Supply.—The nerve supply is derived from the pelvic plexuses of the sympathetic, the fourth sacral nerve, and the internal pudendal (*pudendal*) nerve.

Atresia of the vagina is usually a congenital condition, but may be the result of injuries or surgical operations. The inlet may become closed after ulcerating lesions of the vulva.

In the congenital variety it may be due to an imperforate hymen or to absence of the vagina in whole or in part. When the uterus and ovaries are absent, atresia of the vagina causes no symptoms. When they are present, retention of the menstrual fluid causes trouble as soon as menstruation begins. The uterus and Fallopian (*uterine*) tubes become distended with menstrual blood, the latter eventually escaping into the pelvic cavity, and accumulating in Douglas' (*recto-uterine*) pouch.

The **hymen** (Plate CCCCLV) is usually a thin semilunar fold of fibrous tissue with its concavity directed upward, partly closing the vaginal orifice. It varies very much in thickness and elasticity, and may remain unbroken until parturition.

Digital examinations of the pelvic organs are readily made through the vagina, and growths and tumors thus palpated. Displacements and diseases of the uterus and adnexa, as well as effusions, can be recognized in this manner. A vermiform appendix occupying the pelvis, as well as an ureteral calculous in the lower end of the ureter may be palpated through the vagina.

When the pelvic floor has been injured, usually as a result of childbirth, a relaxation of the vaginal outlet takes place, and the perineal body becomes shallower owing to the tears of the sphincter ani and levator ani muscles and fasciæ. These tears may take place subcutaneously. The pelvic contents, being deprived

of support, become displaced, the usual result being retrodisplacement and prolapse of the uterus. The relaxed vaginal walls, especially the posterior, bulge at the vulvar orifice, and the condition becomes known as prolapse of the vaginal walls. When the rectum is found bulging into the prolapsed posterior vaginal wall, the name *rectocele* is given to the condition. *Cystocele* is the term applied when the bladder is found in the prolapsed anterior vaginal wall. When the tear of the perineum involves the rectum, incontinence of feces ensues, and the feces will be discharged through the vagina.

In the Emmett operation for repair of the lacerated perineal structures, the crest of the prolapse or rectocele is first determined, the posterior surface of the vagina is then denuded from the sphincter ani muscle along the labia to the lowest remains of the hymen and across to the crest of the rectocele, and from there to the opposite side, leaving a denudation somewhat triangular in shape. Sutures unite the incision on each side, extending into the sulci, and deep sutures catch the ends of the levator and sphincter ani muscles and approximate them. There have been numerous modifications of this operation. Whichever operation is used care should be taken to suture the muscular laceration. Suture of the mucous membrane alone is worthless.

Besides repairing the rectal sphincters and the levator ani and their sheaths the surgeon should suture the superficial transverse perineal muscle so as to approximate the posterior commissure. In repairing a cystocele just as much care should be taken to repair the relaxed fascia which assists in supporting the bladder.

To correct a cystocele or prolapse of the anterior vaginal wall, an oval denudation is made and the side of the oval approximated by suture after first exposing the torn fascia and repairing this laceration. In this denudation the ureters must not be damaged. They enter the bladder approximately at the positions of five and seven o'clock.

Wounds of the vagina, on account of its vascularity, may give rise to serious and even fatal hemorrhage. Owing to the thin vaginal wall between the bladder and vagina, and the rectum and vagina, the occurrence of vesico-vaginal and recto-vaginal fistulæ is not uncommon.

The **ovaries** (the testes muliebres of Galen) (Plate CCCCLVI), the sexual glands of the female, are two almond-shaped bodies each having two margins, two ends, and two surfaces; they are approximately four centimeters (an inch and a half) long, two and a half centimeters (one inch) wide, and one and a quarter centimeters (a half inch) thick, though varying considerably in size, and weigh about seven grams (half an ounce). They are smooth and pink in the young nulliparæ and puckered and gray in the elderly multiparæ. They

PLATE CCCCLVI.

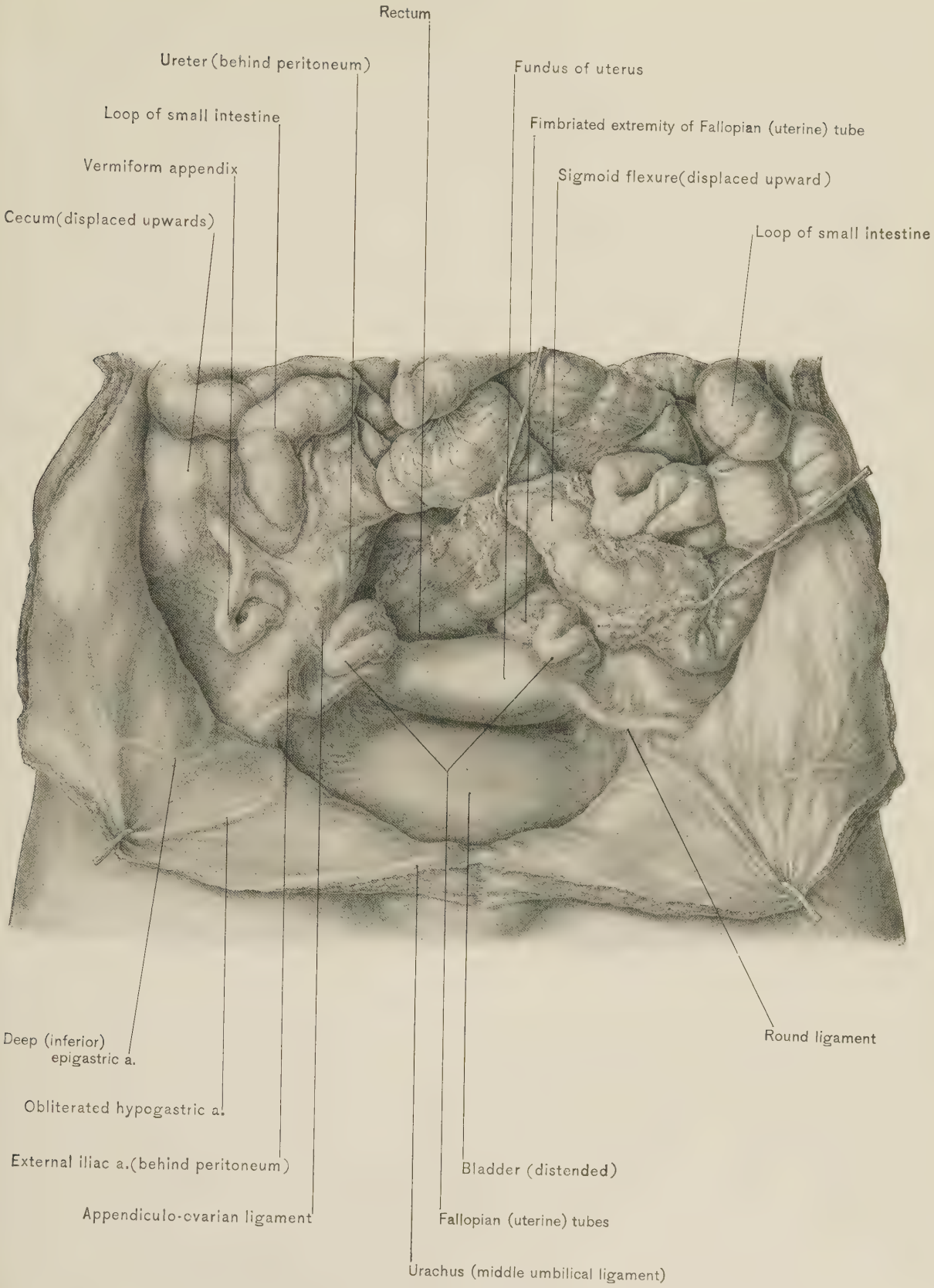

PELVIC CAVITY OF FEMALE—SUPERIOR VIEW.

are usually suspended in a small secondary fold or peritoneum, the mesovarium, which is derived from the posterior surface of the broad ligaments. In the virgin the ovary lies against the lateral pelvic wall in a hollow (ovarian fossa of Claudius) just beneath the external iliac vessels. The direction of the long axis of the ovary in its normal position is in dispute, various authorities placing it vertically, obliquely, or horizontally, with varying lateral deviations to or from the medial plane. The truth probably is that this very movable organ may occupy any of these positions, maintaining the one which it happens to assume early in life until it is displaced by pregnancy, after which it seldom, if ever, returns exactly to its original place. The surfaces usually face medialward and lateralward, while the borders are directed forward and backward.

The **anterior border** is less curved than the posterior, and is thinner. It is at this border that the vessels and nerves enter and leave the ovary, and the peritoneal layers unite, thus giving rise to the term *attached margin*.

The **posterior border** is free and rounded and enveloped by peritoneum, the entire ovary having the appearance of being hung upon the back of the broad ligament by its anterior edge.

The ends, or poles, of the ovary are tubal and uterine. The **upper, or tubal, pole** is connected with the fimbriated extremity of the Fallopian (*uterine*) tube by one of its fimbriæ, and has passing from it a peritoneal fold, the *ovario-pelvic*, or *infundibulo-pelvic, ligament* (*suspensory ligament of the ovary*), to the lateral pelvic wall. The **lower, or uterine, pole** is connected with the uterus by a round cord, the *utero-ovarian ligament* (*ligament of the ovary*), which is attached to the side of the body of the uterus between the Fallopian (*uterine*) tube and the round ligament.

The **surface of the ovary** is smooth before puberty, but after this period it becomes more uneven with advancing age, because of the pitting due to scars following the periodical rupture of Graafian vesicles.

The **vessels and nerves of the ovary** pass into it through the two layers of the mesovarium and enter the organ through the *hilum*, which is found on the anterior border.

Blood Supply.—From the ovarian artery and at times this is supported by branches of the uterine. This artery takes a tortuous course; its walls are thick and its caliber narrow. The veins empty into the plexus found in the broad ligament, the blood from which empties largely into the ovarian vein; the left vein then empties into the renal vein at right angles, its opening being free from any valve. The right vein empties into the inferior vena cava, its opening being protected by a valve; in this respect the ovarian veins are similar to the spermatic veins in the male.

The *lymphatics of the ovary* ascend with the veins to the glands along the vena cava or aorta at the level of the kidney.

Nerve Supply.—From the ovarian plexus of the sympathetic and from the uterine nerves.

The **parovarium** (**epoöphoron**), also called the organ of Rosenmüller, the female epididymis, lies in the broad ligament between the ovary and the tube, and consists of numerous divergent tubules beginning close to the anterior or attached margin of the ovary and extending toward the Fallopian (*uterine*) tube, where they join a large longitudinal tube. It is best seen by transmitted light and is readily overlooked. It is formed by part of the Wolffian body of the embryo. These tubules may give rise to intraligamentary cysts of considerable size which may be mistaken for an ovarian cyst.

The **Fallopian** (**uterine**) **tubes,** or **oviducts,** are two trumpet-shaped tubes which pass from the superior angles of the uterus to the ovaries in the upper or free margins of the broad ligaments. Their cavities are continuous with the cavity of the uterus, and thus form a passageway between the exterior and the peritoneal cavity. Generally, however, this channel is closed at the ovarian end on account of the close proximity of the ovary to the fimbriated end of the tube. Each tube is about ten centimeters (four inches) long. Near the uterine end it is straight and narrow, but widens toward the middle and becomes somewhat tortuous, and finally ends in a trumpet-shaped extremity which is fringed with a circle of *fimbriæ*. One of these fimbriæ is attached to the upper extremity of the ovary, and takes the name of the **tubo-ovarian ligament,** or the **ovarian fimbria.** The narrow, uterine end is known as the **isthmus of the tube,** the widened central portion as the **ampulla,** and the trumpet-shaped end as the **infundibulum,** or **fimbriated extremity.** The width of the tubes varies from about three millimeters (an eighth of an inch) at the uterine end to about fifteen millimeters (three-fifths of an inch) at the ovarian end, the fimbriæ often forming an expansion of about twenty-five millimeters (one inch).

The Fallopian (*uterine*) tubes have four coats: serous, fibrous, muscular, and mucous.

The *serous coat* is incomplete, the muscular coat being uncovered along a portion of its circumference where the folds of the broad ligament are attached. This fact explains why the tube may rupture into the interserous space of the broad ligament or into the general peritoneal cavity.

The *fibrous coat* is continuous with the extraperitoneal connective tissue of the broad ligament; it is very rich in vessels.

The *muscular coat* consists of circular and longitudinal layers, the latter being external to the former.

The *mucous coat* is thrown into longitudinal folds. These are very simple in the isthmus, but become quite complicated in the ampulla. They generally end in the fimbriæ.

Blood Supply.—The blood supply of the Fallopian (*uterine*) tubes is furnished by branches from the ovarian and uterine arteries. The veins empty into the venous plexus found in the broad ligament.

The *lymphatics* empty into those of the ovary, finally being carried to the lumbar glands.

Nerve Supply.—From the uterine and ovarian plexuses of the sympathetic.

Removal of the ovary and tube.—The anatomic points to be remembered when removing the ovaries and tubes are as follows: the ovary is connected to the broad ligament by its attached or anterior margin, the mesovarium through which the vessels and nerves pass to the organ. The ovary is attached to the uterus by the utero-ovarian ligament (*ligament of ovary*), a prolongation of the muscle substance of the uterus, and is connected to the fimbriated extremity of the Fallopian (*uterine*) tube by the ovarian fimbria, or tubo-ovarian ligament. The blood supply of the ovary is obtained from the ovarian artery, a branch of the aorta. The Fallopian (*uterine*) tube is a trumpet-shaped tube which extends from the superior angle of the uterus along the free border of the broad ligament to a point a short distance lateral to the ovary. Its canal is continuous with that of the uterus, and opens into the general peritoneal cavity. It is supplied by branches from the ovarian and uterine arteries. The ovarian artery enters the broad ligament from the pelvic brim and passes between the folds of the ligament, beneath the Fallopian (*uterine*) tube, to the upper part of the body of the uterus, where it anastomoses with the uterine artery. It sends numerous branches to the ovary and the Fallopian (*uterine*) tube. The ovarian vein has the same general course as the ovarian artery. In the broad ligament near the ovary it forms a plexus which communicates with the plexus of the uterine veins. The peritoneum is reflected from the pelvic walls to the uterus as the broad ligament, the free border of which immediately surrounds the Fallopian (*uterine*) tube.

The **female bladder** is situated between the bodies of the pubic bones in front, and the uterus and vagina behind. It is smaller than that of the male in the anteroposterior diameter, but is much broader at the base. With the exception of its attachment to the vagina and cervix uteri instead of the rectum, and the absence of the prostate, the female bladder has practically the same connections as the male. The interior of the organ is the same as that of the male, but as the urethra is shorter and more dilatable, the ureters are more accessible in the female, and since the symphysis pubis is less deep in the female, the urethral orifice lies nearer its lower border. The openings of the ureters lie at the lateral or

basal angles of the vesical trigone; the line connecting them forms the base of this triangular space, and the apex is at the internal urinary meatus or vesical opening of the urethra. A fold of mucous membrane running from the orifice of the urethra to that of the ureter and which can be indistinctly felt through the vaginal wall, acts as a guide by which a catheter may be passed into the ureter. While a catheter can be guided into the ureter simply by the sense of touch, it can be more readily introduced with the aid of the cystoscope.

Blood Supply.—The blood supply of the female bladder is the same as that of the male bladder, with the exception that small branches from the uterine and vaginal arteries carry blood to it. The veins form plexuses which join those of the uterus, rectum, and vagina, and finally empty into the internal iliac (*hypogastric*) vein.

The *lymphatics* empty into the pelvic glands.

Nerve Supply.—From the third and fourth sacral nerves and the pelvic plexuses of the sympathetic.

The **female urethra** is about four centimeters (one and a half inches) in length, and is slightly curved, with its convexity downward and backward. It really represents only the upper part of the male urethra. It may be divided into three portions: the pelvic, between the bladder and the triangular ligament (*urogenital diaphragm*); the membranous, between the layers of the triangular ligament (*urogenital diaphragm*); the vaginal, between the triangular ligament (*urogenital diaphragm*) and the meatus, this portion running in the upper part of the wall of the vagina, where it is surrounded by a plexus of veins (plexus of Santorini). The female urethra is flaccid and collapsed when empty, and is capable of great dilatation.

The Blood Supply and Nerve Supply of the female urethra are derived from the vessels and nerves of the vagina.

In *ligation* (Plate CCCCLVII) of the external iliac artery, which operation may be required for aneurysm or wounds of the vessel, two methods may be employed: the extraperitoneal, and the intra- or transperitoneal. The upper and lower portions of the vessel are usually avoided owing to the proximity of the internal iliac (*hypogastric*) artery above and the deep (*inferior*) epigastric and deep circumflex iliac below.

In the former operation an incision is made, beginning two centimeters (three-fourths of an inch) above Poupart's (*inguinal*) ligament and a slightly lateral to its midpoint and parallel to it, to a point opposite the anterior superior iliac spine. If the artery is deep seated, this incision should be made curved with its convexity downward and lateralward to gain more room. After cutting through the abdominal muscles the peritoneum should be pushed upward and medialward

PLATE CCCCLVII.

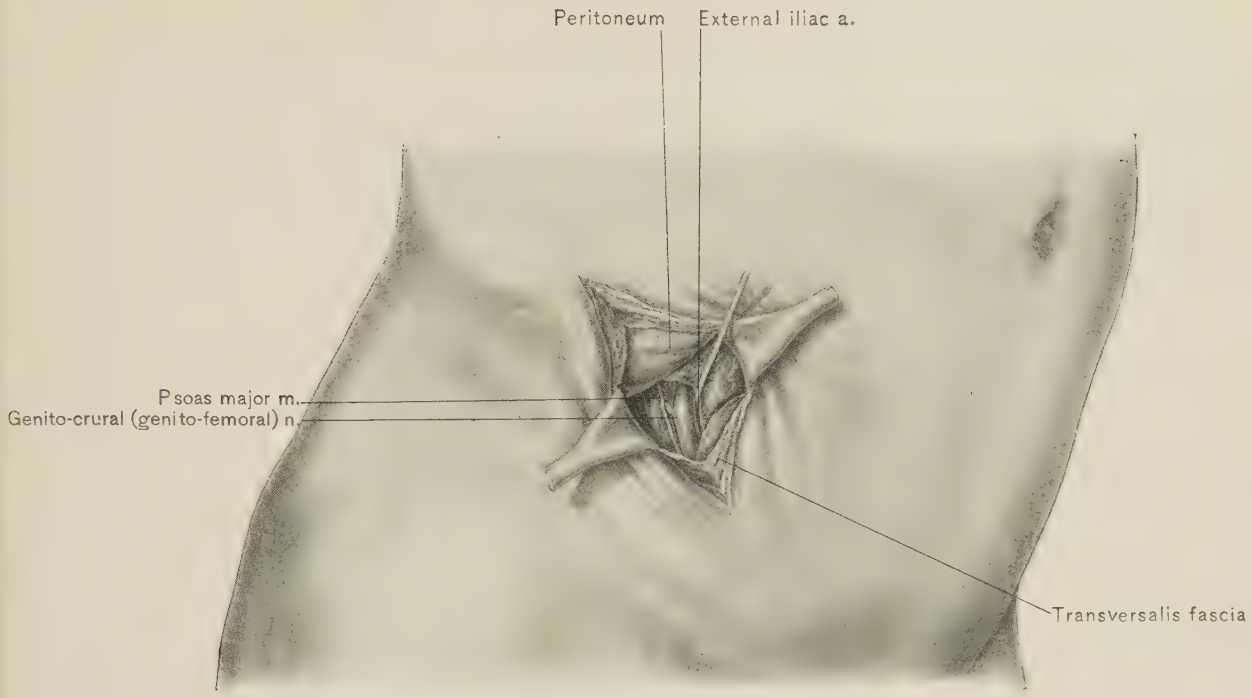

A

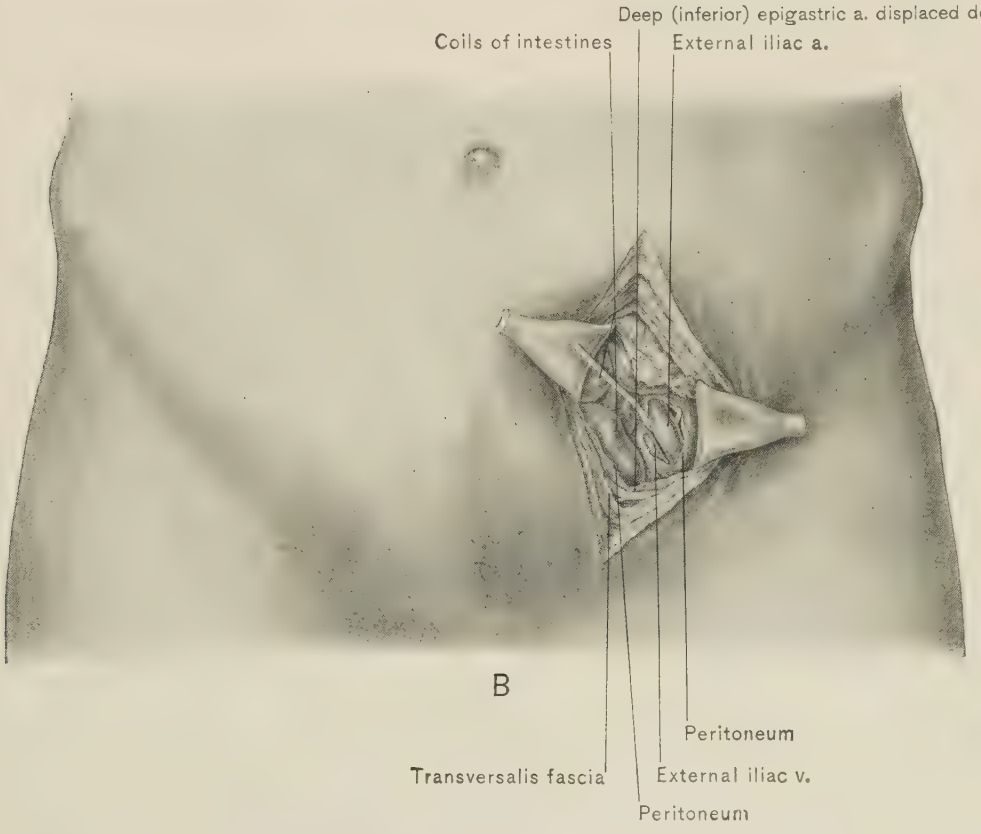

B

LIGATION OF EXTERNAL ILIAC ARTERY.
(A) EXTRAPERITONEAL METHOD. (B) TRANSPERITONEAL METHOD.

PLATE CCCCLVIII.

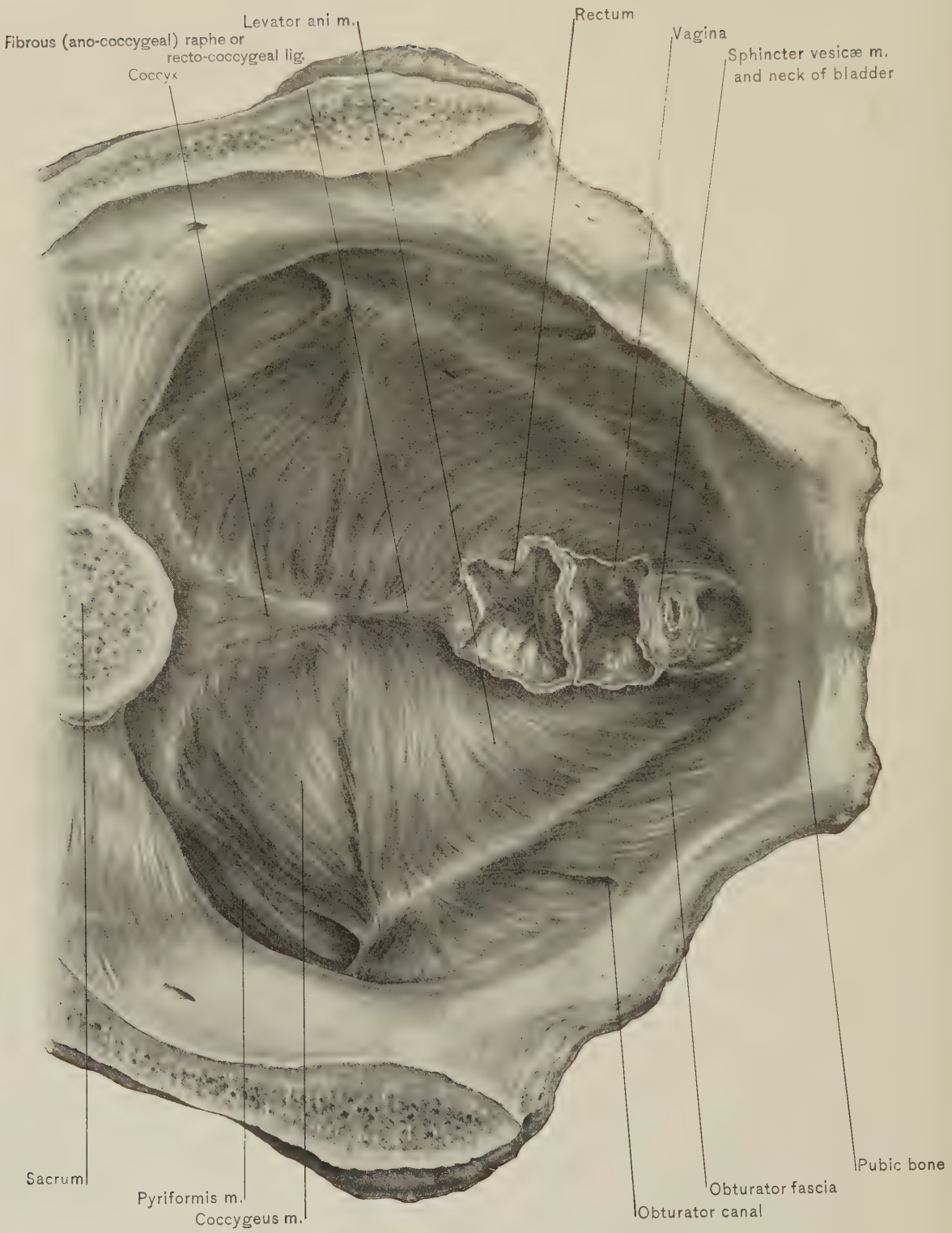

MUSCLES IN FLOOR OF PELVIS—SUPERIOR VIEW.

from the iliac fossa till the vessel is reached. The needle is then passed from the medial to the lateral side, care being taken to avoid injuring the vein.

In the intra- or transperitoneal method the incision is made either in the semilunar line or through the rectus abdominis muscle, beginning about two and a half centimeters (an inch) below the level of the umbilicus and extending downward for about ten centimeters (four inches). After the peritoneal cavity is opened the intestines are displaced and the peritoneum over the artery incised parallel to the vessel and the latter exposed. A ligature is then passed from the medial to the lateral side. The advantage of this operation over the other is that the vessel may be tied in any part of its course that seems desirable, and that the common iliac artery may be ligated through the same incision.

The **muscles within the pelvis** (Plate CCCCLVIII) are the levator ani, the coccygeus, and the obturator internus.

The **levator ani muscle** *arises* from the posterior surface of the body of the pubis, the spine of the ischium, and from the white line or lower border of the pelvic fascia in the interval formed by the divergence of the recto-vesical and obturator fasciæ. The fibers of the muscle may be divided into three sets. The anterior fibers pass along the sides of the prostate in the male and the vagina in the female and meet the corresponding fibers of the opposite levator ani muscle in the interval between the rectum and the prostate or vagina, where they are *inserted* into the central tendon of the perineum; the middle fibers blend with the longitudinal fibers of the rectum and the external sphincter ani; the posterior fibers are divided into those which join with corresponding fibers of the other levator ani muscle to form the median recto-coccygeal fibrous (*ano-coccygeal*) raphe, and those that are *inserted* into the tip of the coccyx. The nerve supply of the levator ani muscle is derived from the inferior hemorrhoidal nerve and the fourth and fifth sacral nerves. This muscle is more fully described with the perineum, at p. 674.

The **coccygeus muscle** is a small triangular muscle that is supported laterally by the sacro-sciatic (*sacro-spinous*) ligament, with which it blends. It *arises* from the spine of the ischium immediately above the origin of the levator ani muscle, and is *inserted* into the side of the coccyx, the lateral sacro-coccygeal ligament, and the last two sacral vertebræ. At times the muscle will be seen to be pierced by branches from the fourth and fifth sacral nerves and the coccygeal nerve which form a plexus on its pelvic surface.

Nerve Supply.—From the fourth and fifth sacral nerves and the coccygeal nerve.

Action.—Its action is to pull the coccyx forward.

The **obturator internus muscle** *arises* from the part of the medial surface of the anterolateral wall of the pelvis which is formed by the obturator membrane and the bone around it—namely, from the medial surface of the body of the pubis, the descending ramus of the pubis, the ascending ramus of the ischium, from the innominate bone between the great sacro-sciatic (*greater sciatic*) notch and obturator foramen, the whole of the medial surface of the obturator membrane, and the lateral surface of the obturator and pelvic fasciæ. Its origin is limited above by the brim of the pelvis. Its fibers end in a strong tendon which forms a right angle as it turns around the anterior margin of the lesser sacro-sciatic (*lesser sciatic*) foramen, through which it passes to be *inserted* into the medial side of the upper portion of the greater trochanter of the femur. The tendinous expansion of this muscle, into which the fibers converge, is corrugated into four or five folds which fit into corresponding depressions in the cartilage surrounding the lesser sacro-sciatic (*lesser sciatic*) foramen. A bursal sac is generally found between the tendon and cartilage. The superior and inferior gemelli muscles are inserted into the tendon of this muscle. These will be described with the gluteal region.

Blood Supply.—The blood supply of the obturator internus is derived chiefly from the obturator artery.

Nerve Supply.—The nerve supply is derived from the fifth lumbar and the first and second sacral nerves.

Action.—The action of the obturator internus is to rotate the femur lateralward when extended and to abduct the flexed thigh.

THE LYMPHATICS OF THE ABDOMEN AND PELVIS

The **lymphatics of the abdomen and the pelvis** may be divided into the *parietal*, ramifying in the abdominal and pelvic walls, and the *visceral*, which drain the abdominal and pelvic viscera.

The **parietal lymphatic vessels** may be subdivided into a superficial and a deep set, the superficial set running in the skin and subcutaneous tissues, including those in the skin and subcutaneous tissue of the external genitalia, and ending for the most part in the superficial inguinal glands, the deep set accompanying the deep arteries in the abdominal and pelvic parietes and emptying into the lumbar glands.

The *superficial lymphatics of the abdominal wall* ramify in the superficial fascia and follow the course of the blood-vessels situated in the latter. Those of the anterior abdominal wall below the level of the umbilicus follow the superficial epigastric vessels and terminate in the superior set of inguinal glands, whereas those above the level of the umbilicus pass upward to the axillary glands. Some of the superficial lymphatics of the lateral portion of the abdominal wall follow the

superficial circumflex iliac artery and enter the superior set of inguinal glands, and others follow the lumbar and ilio-lumbar arteries and enter the lumbar glands.

The *superficial lymphatics of the penis* begin in the prepuce, encircle the corona and there receive the lymphatics from the anterior two-thirds of the urethra, and pass along the dorsum and side of the organ under the skin to its root, to be equally distributed to the most medial superficial inguinal glands on each side. The deep lymphatics of the penis pass along the dorsal vein to the lymphatic gland along the internal iliac (*hypogastric*) artery.

The *lymphatics of the scrotum* in the male and those of the external generative organs of the female run to the superficial inguinal lymphatic glands. Those from the testicle pass along the spermatic artery to the lumbar glands. Therefore in carcinoma of the testicle the inguinal glands do not become enlarged until the scrotum is attacked, the lumbar glands being the ones primarily involved.

The *deep lymphatics of the anterior and lateral abdominal walls* follow the deeper blood-vessels. Those of the upper anterior part follow the superior epigastric artery and enter the internal mammary glands, the efferent vessels of which enter the anterior mediastinal glands. The deep lymphatics of the upper lateral part follow the anterior intercostal and musculo-phrenic arteries and terminate in the internal mammary lymphatic glands. Those of the lower anterior part of the abdominal wall follow the deep (*inferior*) epigastric and deep circumflex iliac arteries and terminate in the external iliac glands, and other deep lymphatics from the lateral abdominal wall follow the lumbar and ilio-lumbar arteries and join the lumbar glands.

The *superficial lymphatics of the pelvic wall* are those of the gluteal region, perineum, and proximal part of the thigh. They empty into the superficial inguinal glands.

The *deep lymphatics of the pelvic wall* accompany the obturator, gluteal (*superior gluteal*), sciatic (*inferior gluteal*), internal pudendal, and sacral arteries. They terminate in the internal iliac (*hypogastric*) and sacral glands.

The *lymph glands of the abdominal and pelvic walls* may be divided into superficial and deep glands.

The *superficial* set of *abdominal parietal glands* are the superior set of the superficial inguinal glands or oblique inguinal glands, or inguinal glands proper, situated above Poupart's (*inguinal*) ligament. These glands receive the superficial lymphatics from the penis and the scrotum and the anterior two-thirds of the urethra in the male, and from the external genitalia and the lower part of the vagina in the female. Organisms transmitted along the lymph vessels in venereal disease of the integuments of the penis or the pudenda or the wall of the anterior two-thirds of the urethra cause inflammation and enlargements of the

oblique glands, called *buboes*. These glands also become enlarged in malignant disease of the external genitalia and of the anus. Their efferent vessels enter the pelvis beneath Poupart's (*inguinal*) ligament, pass through the external iliac glands, to end in the lumbar glands. They receive the deep (*inferior*) epigastric, deep circumflex iliac, and ilio-lumbar lymphatics.

There are no superficial parietal pelvic lymph glands.

The *deep lymph glands of the abdomen and pelvis* are situated chiefly along the posterior wall of the general abdominal cavity, and from their relations with neighboring structures are described as external iliac, internal iliac (*hypogastric*), sacral, lumbar, and celiac glands.

The *external iliac glands* lie along the external and common iliac vessels, and are five or six in number. They receive the lymph vessels from the inguinal and femoral glands, those from the lower abdominal wall which accompany the deep (*inferior*) epigastric and deep circumflex iliac vessels, and some of the efferent lymphatics from the internal iliac (*hypogastric*) glands. Their efferent vessels terminate in the lumbar glands. They communicate with the internal iliac (*hypogastric*) glands.

The *internal iliac* (*hypogastric*) *glands* are located in the pelvic cavity along the course of the internal iliac (*hypogastric*) artery and its branches, and are about ten or twelve in number. Their afferent vessels accompany the branches of the internal iliac (*hypogastric*) artery and tributaries of the internal iliac (*hypogastric*) vein. Therefore they receive the deep lymphatic vessels from the pelvic wall, nearly all the lymphatics from the pelvic viscera, the deep lymphatics from the penis or clitoris, the perineum, posterior part of the scrotum or labia majora, and the posterior part of the urethra, the deep lymphatics of the gluteal region, and those lymphatics from the proximal part of the thigh which drain the tissues supplied by the obturator artery. Their efferent vessels join the lumbar glands.

The *sacral glands* are found in the extraperitoneal fat in front of the sacrum, four or five being located in the lower part of the mesosigmoid opposite the promontory of the sacrum. They receive the lymphatics from the rectum and posterior wall of the pelvis, and their efferent vessels join the lumbar glands.

The *lumbar glands* are divided into one median and two lateral chains.

The *median chain of lumbar glands*, the *aortic lumbar glands*, is situated in the extraperitoneal fat along the abdominal aorta and inferior vena cava. It is composed of six or seven glands which extend from the bifurcation of the aorta to the second lumbar vertebra. These glands receive the efferent vessels from the external iliac, internal iliac (*hypogastric*), and sacral glands, the lymphatics from the testicles or ovaries, kidneys, suprarenal glands, and posterior portion of the diaphragm and some of the efferent vessels from the lateral chains of

lumbar glands. Their efferent vessels usually unite to form a *right and left lumbar lymph trunk*, which with small efferent vessels from the lateral chains empty into the receptaculum (*cisterna*) chyli. The left lumbar trunk receives the lymphatics from the lower half of the descending colon and sigmoid flexure.

The *lateral chains of lumbar glands*, the *transverse lumbar, or psoas, glands*, are placed behind the psoas muscles between the transverse processes of the lumbar vertebræ. The glands composing these chains are smaller than those of the median chain and are twenty or more in number. They receive the lymphatics which accompany the lumbar arteries and their branches from the spinal canal, the lumbar region of the back of the trunk, and the lateral and posterior abdominal walls. Some of their efferents terminate in the lumbar glands of the median chain, and the others empty into the receptaculum (*cisterna*) chyli.

The *celiac glands* are situated in front of the abdominal aorta around the celiac axis (*celiac artery*) above the origin of the superior mesenteric artery. They are about fifteen in number and receive the lymphatics from the hepatic and superior gastric (*gastric and paracardial*), inferior gastric (*gastro-epiploic and subpyloric*), splenic (*left suprapancreatic*), and pancreatic (*left suprapancreatic*) glands. Their efferent vessels terminate in the intestinal lymph trunk and receptaculum (*cisterna*) chyli.

The **visceral lymph glands** of the general abdominal cavity are the hepatic, superior gastric (*gastric and paracardial*), inferior gastric (*gastro-epiploic and subpyloric*), mesenteric, mesocolic, and splenic (*left suprapancreatic*) glands.

The *hepatic lymph glands* are located between the layers of the lesser omentum in front of the portal vein. They receive those deep lymphatics from the interior of the liver which accompany the radicles of the portal vein, the superficial lymphatics from the anterior portion of the superior surface of the liver, most of the superficial lymphatics from the inferior surface of that organ, and the lymphatics from the gall-bladder. Their efferent vessels terminate in the celiac glands.

The *superior gastric* (*gastric and paracardial*) *lymph glands* are placed between the layers of the lesser omentum along the lesser curvature of the stomach. They receive the superior gastric lymphatics which follow the branches of the pyloric (*right gastric*) and coronary (*left gastric*) arteries. Their efferent vessels follow the coronary (*left gastric*) artery and vein to the left end of the lesser curvature, and there receive some lymphatics from the left lobe of the liver which follow the hepatic branch of the coronary (*left gastric*) artery. From the left side of the lesser omentum they follow the coronary (*left gastric*) artery and vein between the layers of the gastro-phrenic ligament and behind the lesser peritoneal cavity and terminate in the celiac glands.

The *inferior gastric*, or *gastro-epiploic* and *subpyloric, lymph glands* are situated between the layers of the greater omentum along the gastro-epiploic vessels and greater curvature of the stomach. They are six or eight in number and receive the lymphatics from the lower part of the stomach, that is, the part supplied by the branches of the gastro-epiploic arteries. Their efferent vessels pass from left to right, are joined by the lymphatics from the upper part of the duodenum, and run between the pancreas and pylorus of the stomach to terminate in the celiac glands.

The *mesenteric lymph glands* are situated in the extraperitoneal connective tissue between the layers of the mesentery, and vary from one hundred to one hundred and fifty in number. They are arranged in two groups. The glands of the larger group are in relation with the vasa intestini tenuis (*intestinal arteries and veins*) and their anastomosing branches, and are seldom nearer than four centimeters (one and a half inches) to the intestine except at the lower part of the ileum. They receive the lymphatics to the jejunum and ileum and their efferent vessels terminate in the glands of the second group which are much larger. The other group of mesenteric glands lies along the superior mesenteric vessels. Their efferent vessels empty into the receptaculum (*cisterna*) chyli either by means of a common trunk, the *intestinal lymph trunk*, or they may empty by means of three or more trunks. The intestinal lymph trunk is joined by the efferent vessels of the mesocolic glands and some of those from the celiac glands. Enlargement of the mesenteric lymph glands usually occurs in disease of the intestine particularly in typhoid fever, tuberculosis or malignancy of the bowel. The enlarged glands can sometimes be palpated through the abdominal wall.

The *mesocolic lymph glands* are about thirty in number and are situated in the extraperitoneal fat in relation with the colic arteries and their anastomosing loops. They receive the lymphatics from the vermiform appendix, cecum, ascending colon, transverse colon, and upper part of the descending colon. Their efferent vessels terminate in the efferent vessels of the group of mesenteric glands situated along the superior mesenteric vessels. A group of these glands found in the angle between the ileum and ascending colon is called the ileo-colic chain of glands.

The splenic (*left suprapancreatic*) glands are about ten in number, and are situated along the splenic vessels. They receive the lymphatics from that part of the cardiac end of the stomach supplied by the vasa brevia, and the lymphatics from the spleen and pancreas. Their efferent vessels join the celiac glands.

PLATE CCCCLIX.

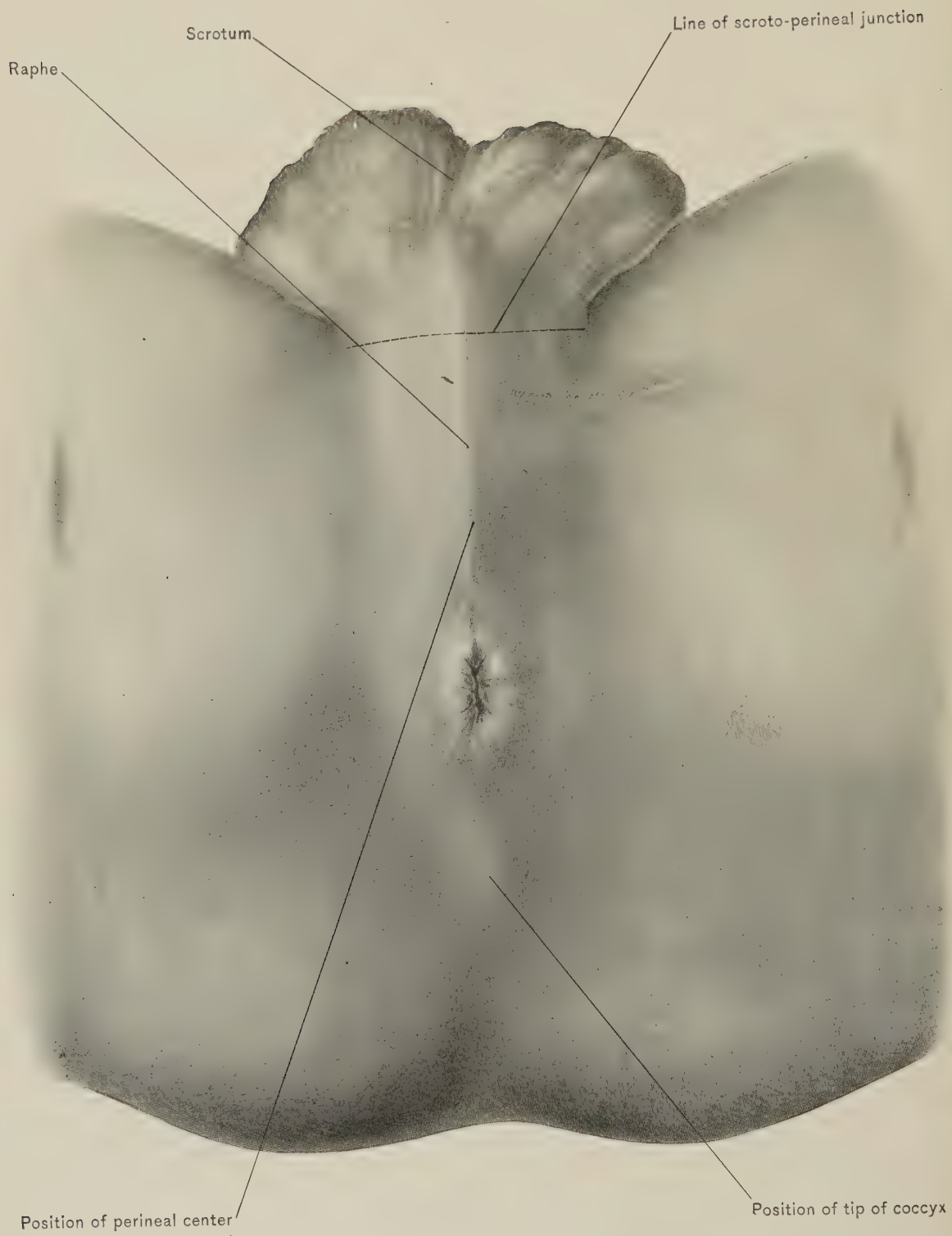

SURFACE OF MALE PERINEUM.

MALE PERINEUM

The **perineum** (Plate CCCCLIX) is composed of all the structures which occupy the outlet of the pelvis. Its outline is quadrilateral. The *superficial boundaries* of the perineum are: anteriorly, the scrotum; laterally and posteriorly, the thigh and the buttocks. The *deep boundaries* are: anteriorly, the pubic arch and subpubic ligament; posteriorly, in the mid-line, the tip of the coccyx; on either side the descending ramus of the pubis, the ascending ramus of the ischium, the tuberosity of the ischium, and the greater sacro-sciatic (*sacro-tuberous*) ligament overlapped by the gluteus maximus muscle. It measures laterally ten or twelve centimeters (four or five inches) between the tuberosities of the ischia. Its depth is from five to seven centimeters (two to three inches), and about two and one-half centimeters (one inch) at the pubes The perineum is arbitrarily divided, by a transverse line through the tuberosities of the ischia, into an anterior portion, the **urogenital triangle** or the perineum proper, which transmits the urethra, and a posterior portion, the **anal,** or **rectal, triangle,** which contains the anus and the terminal portion of the rectum.

Dissection.—The subject should be placed on his back, with the buttocks projecting slightly beyond the end of the table. A block of wood of sufficient size is then placed beneath the pelvis, to elevate the perineum to a convenient height. A medium-sized bougie or lithotomy staff should now be passed into the bladder, as it is more difficult to pass either of these instruments after the limbs have been placed in position for this dissection. To prevent the body from sliding away from the block and from the end of the table, a strip of bandage is placed across the abdomen, above the crests of the ilia, and tied at that end of the table which is beneath the buttocks. The legs and thighs are then strongly flexed and abducted. The legs should be fixed in this position by first tying a roller bandage, five centimeters (two inches) wide, around one leg immediately below the flexed knee, and then passing it beneath the table, and finally around the other leg below the knee in the same manner. The flexed knees may be still further secured by fastening a roller bandage around one knee, then carrying it beneath the nape of the neck, and tying it to the opposite knee. With the subject thus fixed upon the table, it will be impossible for the body to slip out of position. The dissection of this part cannot be successfully carried out unless the cadaver is placed in the lithotomy position just described. The scrotum is raised and held forward by means of hooks.

Surface Anatomy.—A study of the surface exposed shows the skin of the perineum to be dark in color and covered with short, crisp hairs, which should be shaved before proceeding further. The surface will be seen to be slightly convex in the mid-line, owing to the prominence caused by the bulb and the forward

continuation of the corpus spongiosum (*corpus cavernosum urethræ*) through both of which the urethra passes.

The bony prominences which can be distinctly felt are: anteriorly, the bodies of the pubic bones and the pubic arch; posteriorly, the tip of the coccyx; laterally, the descending rami of the pubes, the ascending rami and the tuberosities of the ischia.

The **perineal raphe** divides the perineum equally into two lateral halves. It is a pigmented ridge in the skin, and extends from the anterior margin of the anus forward along the mid-line of the perineum to the scroto-perineal junction, and is continuous with the median raphe of the scrotum. The median raphe is the line of safety of the perineum—that part where the blood-vessels are fewest, no vessels passing from one side to the other across it, since it is the line of fusion of the two fetal halves of the perineum. When practicable, in operations, incisions are made through this line.

The **central tendon of the perineum** (*common tendon of perineal muscles*), or perineal center, is in the line of the perineal raphe midway between the center of the anus and the line of junction of the scrotum with the perineum. At the perineal center, which is at the center of the base of the triangular ligament of the perineum (*urogenital diaphragm*), the superficial transverse perineal, the accelerator urinæ (*bulbo-cavernosus*), and the sphincter ani muscles, and some of the anterior fibers of the levator ani muscle meet in a common tendon which is blended with the triangular ligament (*urogenital diaphragm*) in this location. The perineal raphe and the perineal center are important landmarks in all operations performed in this region.

The **bulb of the corpus spongiosum** (**bulb of urethra**) lies immediately above or anterior to the central tendon about two centimeters in front of the center of the anus, and the **artery of the bulb** runs just anterior to a line from the tuberosity of the ischium to the perineal center. A knife introduced at the perineal center and pushed upward and slightly backward, will enter the membranous portion of the urethra. The bulb of the corpus spongiosum (*bulb of urethra*) is comparatively small in the child and large in advanced life; hence there is danger of wounding it in lateral perineal lithotomy in old men.

Cock's external urethrotomy is performed for the relief of urinary retention due to stricture which is impermeable to the passage of a catheter. With the left index finger passed into the rectum up to the apex of the prostate gland, the urethra is opened behind the stricture by a median perineal incision, and the stricture divided.

The **white line of the anus** is situated at the margin of the anus, at the muco-cutaneous junction, and is a guide to the surgeon in operations upon this

part. It is the line of demarcation between the respective areas involved in internal and external hemorrhoids, and marks the position of the interval between the external and internal sphincter ani muscles.

The **anus** is the dilatable aperture at the lower extremity of the alimentary tract. It is situated in the anal triangle in the median line, and its center is four centimeters (one and a half inches) in front of the tip of the coccyx. The skin around it is pigmented and thrown into folds, which are most numerous posteriorly. *Fissures of the anus* are painful linear cracks or ulcers which sometimes develop in the creases between these folds. In the integument immediately around the anus are situated a number of sweat glands, known as the **circumanal glands.** Sebaceous glands are also found in connection with the hair of this region. Suppuration of these glands produces a superficial perirectal abscess, which may be mistaken for abscess of the ischio-rectal fossa.

Congenital Defects.—Due to the fact that the anus and rectum are developed separately, the former from epidermal, the latter from ectodermal and mesodermal structures, congenital malformations are not uncommon. The anus may be constricted without complete occlusion, it may be separated from the rectum by a thin membrane, or it may be entirely absent. The anus may be normal but the rectum imperforate, separated by a membrane from the anus. The rectum and anus may be normal but the ureters, the vagina, or the uterus may open into the rectum. The operation for the relief of imperforate anus consists of searching for the rectum through an incision into the perineum immediately anterior to the coccyx; if the rectum cannot be found, the only alternative is colostomy. **Dermoid cysts,** which are occasionally found in the coccygeal region, originate from the so-called postanal gut, a portion of the hind gut situated posterior to the anal opening, which, normally, is obliterated. These are known as **sacro-coccygeal, or pilonidal, cysts.** Termination of the urethra in the perineum is known as **perineal hypospadia.**

The **ischio-rectal fossæ** are situated at the sides of the anus, between it and the tuberosities of the ischia. In the skin over one of these fossæ the mouth of a **complete fistula-in-ano** or an **incomplete external fistula-in-ano** is found; it is at this point that tenderness is detected in inflammation and abscess of the ischio-rectal fossæ.

Rectal Examination.—The rectum, one of the most important surgical avenues, should always be examined with the finger, and the parts in relation with the anterior wall should be carefully studied and their position accurately determined before dissecting the perineum. On introducing the finger into the bowel, with its dorsal surface presenting to the concavity of the sacrum and coccyx, the resistance offered by the contraction of the *external sphincter ani muscle* will first

be felt, and at about two and one-half centimeters (one inch) above the external sphincter the resistance offered by the contraction of the *internal sphincter ani muscle* will be noticed. About twelve millimeters (one-half inch) above the internal sphincter ani and through the anterior wall of the rectum the prostate gland will be felt, the outline of which should be carefully defined in order to be able to compare the normal size with hypertrophy of this organ. The *prostate gland* in the healthy adult is a body about the size of a large chestnut, and is felt from four to five centimeters (one and one-half to two inches) from the anus. Its size and consistency can be more satisfactorily made out when the bladder is at least half full, the prostate then being pressed downward is more readily brought within reach of the finger.

The *base of the bladder* is felt immediately beyond the prostate as a soft and somewhat elastic structure at a distance of six centimeters (two and one-half inches) from the anus. When the bladder is distended, the finger, introduced into the rectum and placed in contact with the base of the bladder, can detect fluctuation when the fingers of the other hand tap over the hypogastric region. The *seminal vesicles* may be felt beyond the prostate gland as two soft oblong bodies at the sides of the base of the bladder; they are about five centimeters (two inches) in length, and twelve millimeters (one-half inch) in width. They can be satisfactorily palpated when the bladder is full.

Through the anterior wall of the rectum, between the level of the internal sphincter ani muscle and that of the prostate, the track of the *membranous portion of the urethra* can be felt. It is important to remember this when attempting to pass an instrument into the bladder in obstruction of this portion of the urethra, since the finger in the rectum may act as a safe director and assist in locating the point of obstruction. In children the prostate gland is rudimentary, and the wall of the urethra at this point is less resistant, so that in passing an instrument into the bladder there is danger of perforating the urethra.

The **valves of Houston** (**transverse rectal folds**) are three or four transverse semilunar folds of mucous membrane in the lower part of the rectum, which frequently become the site of ulcerative inflammation; they can be easily detected with the finger. Division of the muscle fibers forming the floor of the ulcer may be necessary in order to effect a cure of the ulcerative process.

The ischio-rectal fossæ, which are on each side of the rectum, can be palpated through the rectum, thus affording a means of early detection of inflammation in these fossæ.

Dissection.—Having made the digital examination of the rectum as directed, the lower part of the bowel should now be moderately distended with rags, cotton, or oakum, and the margins of the anus brought together with

PLATE CCCCLX.

SUPERFICIAL FASCIA OF MALE PERINEUM.

sutures. In the dissection of the perineum, as in that of the abdominal walls, it is preferable to raise the skin in one large flap, instead of making a number of incisions, as is often advised. Two incisions, cutting only through the skin, are made, each one commencing a short distance above the line of junction of the scrotum with the perineum, and carried downward and laterally, along the descending ramus of the pubes external to the tuberosity of the ischium, to meet the other incision posteriorly a short distance behind the tip of the coccyx. The flap thus marked out is reflected from behind forward, and should include the skin of the posterior third of the scrotum. Great care is necessary in removing the skin surrounding the anus, in order to preserve the external sphincter ani muscle, some of the fibers of which are inserted into the skin.

The **skin** in the region of the perineum is thin and loosely connected with the subjacent parts, so that blows in this location are attended by early and extensive ecchymosis. It is well supplied with blood vessels and nerves.

The **superficial fascia** (Plate CCCCLX) of the entire perineum should be studied before beginning the dissection of the individual triangles. Near the anus the superficial fascia contains considerable fat, which extends deeply upward upon each side of the rectum in the shape of a soft, elastic pad, which permits distention of the lower part of the rectum. Anteriorly, or toward the scrotum, the fat diminishes in quantity, disappearing entirely in the scrotum, where it is replaced by the involuntary muscle fibers of the dartos.

The superficial fascia covering the urogenital triangle consists of a superficial and a deep layer. The **superficial layer** contains more or less fat, and is continuous with the same layer of the superficial fascia of the scrotum and the thighs and with the superficial fascia of the anal triangle. The **deep layer of the superficial fascia,** or **fascia of Colles,** is densely membranous and contains no fat. It has the same shape as the urogenital triangle, which it covers. It is attached posteriorly to the lower edge, or the base, of the anterior layer of the triangular ligament (*inferior fascia of the urogenital diaphragm*), and winds around the posterior border of the transverse perineal muscles. It is attached on each side to the rami of the pubes and ischium, and for practical purposes is best described as being continuous with the deep fascia of the thighs at this point. Anteriorly, it passes over the scrotum, penis, and spermatic cord to the anterior wall of the abdomen where it becomes continuous with the fascia of Scarpa (*membranous layer of superficial fascia of abdomen*). It forms the immediate covering for the muscles of the urogenital triangle, or the perineum proper.

The **superficial,** or **anterior, intra-aponeurotic space,** or **superficial perineal interspace,** situated in the urogenital triangle, is bounded superficially by the deep layer of the superficial fascia, Colles' fascia; deeply, by the superficial

layer of the triangular ligament (*inferior fascia of urogenital diaphragm*); laterally, by the attachment of both to the pubic arch, and posteriorly it is closed by the fusion of Colles' fascia to the base of the triangular ligament (*urogenital diaphragm*). It contains the bulb of the corpus spongiosum (*bulb of urethra*); the bulbous portion of the urethra; the terminal portion of the ducts of Cowper's (*bulbo-urethral*) glands; the crura of the penis; the accelerator urinæ (*bulbo-cavernosus*), the erector penis (*ischio-cavernosus*), and the transverse perineal muscles; the superficial perineal (*perineal*) and transverse perineal vessels, the anterior, and sometimes the posterior, superficial perineal (*posterior scrotal*) nerves; the terminal part of the inferior pudendal (*long perineal*) nerve; the artery of the corpus cavernosum, and the dorsal artery, vein, and nerve of the penis. Posteriorly, the space is divided into two lateral compartments by adherence of Colles' fascia to the median raphe of the accelerator urinæ (*bulbo-cavernosus*) muscle; anteriorly, the two compartments are not completely separated.

Extravasated urine enters the superficial intra-aponeurotic space of the perineum proper when the urethra is ruptured at the junction of its bulbous and membranous portions. As the space becomes distended, the urine passes in the direction in which it meets the least resistance, namely, into the scrotum and thence over the body of the pubis, between the spine of the pubis and the symphysis pubis, into the abdominal wall by way of the scroto-abdominal passage. It cannot enter the ischio-rectal fossæ on account of the attachment of the deep layer of the superficial perineal fascia to the base of the triangular ligament (*urogenital diaphragm*); neither can it find its way externally upon the medial sides of the thighs on account of the attachment of the deep layer of the superficial fascia to the descending rami of the pubes and the rami of the ischia; its entrance into the pelvis is prevented by the superficial layer of the triangular ligament (*inferior fascia of urogenital diaphragm*) which is stretched across the urogenital triangle as a firm, resisting diaphragm. Having reached the abdominal wall, it accumulates beneath the superficial fascia in this location, being unable to pass to the anterior surface of the thighs on account of the attachment of the deep layer of the superficial fascia of the abdomen to the deep fascia along Poupart's (*linguinal*) ligament and the external lip of the crest of the ilium. Pus or blood within the superficial perineal interspace, if the effusion is extensive enough, will follow the same course. Owing to the density and attachments of the deep layer of the superficial fascia, extravasated urine causes little or no fluctuation in the perineum, and an abscess produces only a firm and tender swelling.

In the anal triangle the superficial fascia is composed of only one layer, the adipose, or superficial, layer. By following the superficial fascia laterally from the

PLATE CCCCLXI.

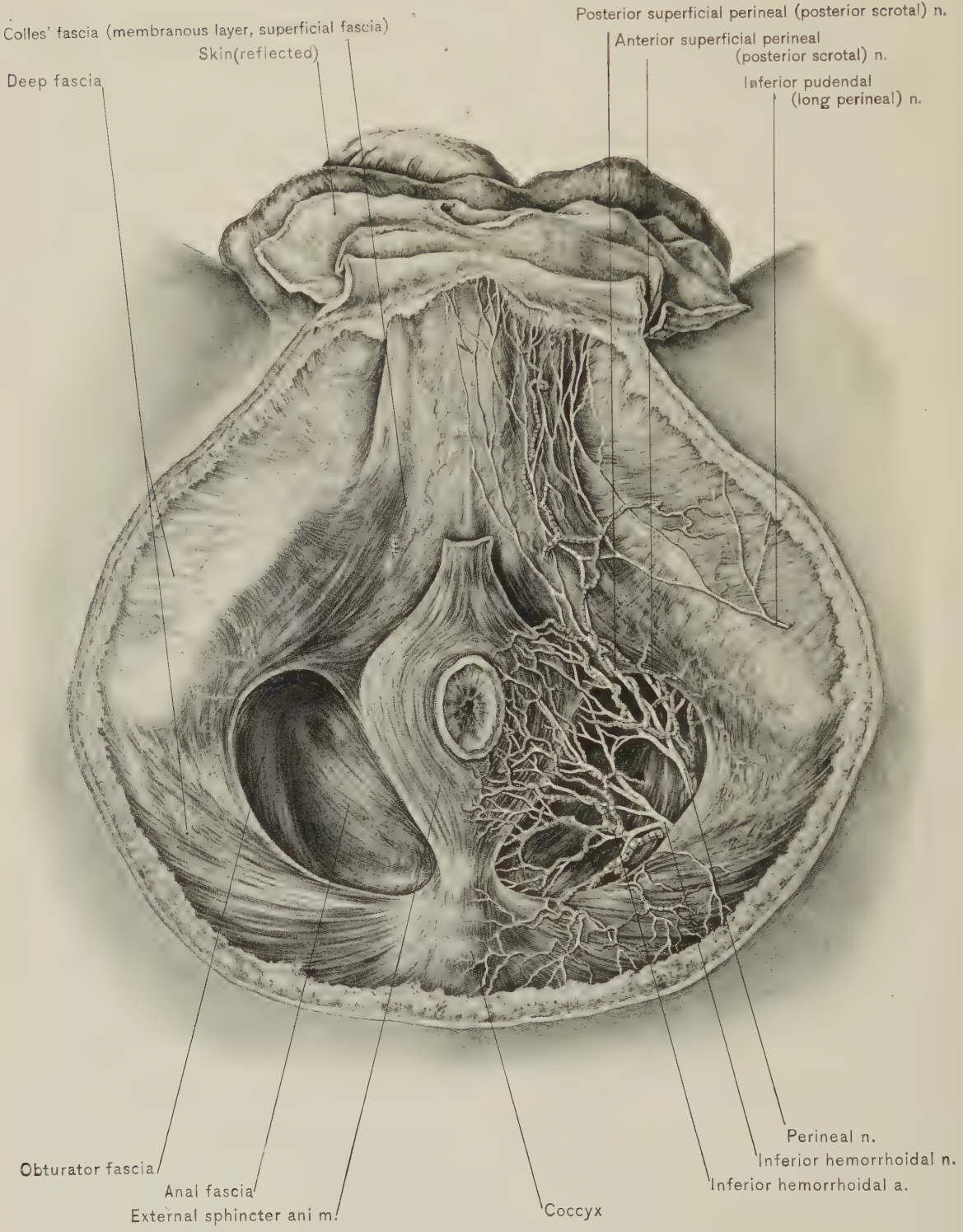

ISCHIO-RECTAL FOSSAE AND FASCIA OF COLLES (MEMBRANOUS LAYER, SUPERFICIAL FASCIA) OF MALE PERINEUM.

anus, it will be seen to change from a pliant pad in the ischio-rectal fossa to a dense, tough layer over the tuberosity of the ischuim. In this last region the fat lobules are separated by fibrous septa which connect the skin with the underlying bony structures, and with intervening bursae between the fascia and the bone, which, when the body rests on the tuberosities of the ischia, act as cushions. Distension of one of these bursæ is commonly called a "bachelor's button."

Dissection.—The superficial fascia, like the skin, should be removed in one large flap, reflected from before backward. In the urogenital triangle the superficial layer only is removed. The anal triangle, which includes the anus and the ischio-rectal fossæ, should be dissected before the urogenital triangle, or perineum proper. The fat contained in the ischio-rectal fossæ should be dissected out on one side, regardless of the blood vessels and nerves passing through it, while on the other side the blood vessels and nerves should be carefully preserved.

The **external sphincter ani muscle** encircles the anus, and is closely adherent to the skin. It is attached posteriorly to the tip of the coccyx, and anteriorly to the central tendon of the perineum, where it meets the medial ends of the transverse perineal muscles, the posterior portion of the accelerator urinæ (*bulbo-cavernosus*) muscles, and some of the fibers of the levator ani muscles. A number of the longitudinal fibers of the rectum pass through the external sphincter ani muscle on their way to the skin.

Superficially, it is in relation with the skin; deeply, with the levator ani muscles and internal sphincter ani muscle; medially, with the internal sphincter ani and some of the rectal mucous membrane, and upon its lateral aspects, with the fat of the ischio-rectal fossæ.

Blood Supply.—From the inferior hemorrhoidal branches of the internal pudendal artery. Its veins empty into the internal pudendal vein, and its lymphatics into the inguinal glands.

Nerve Supply.—From the inferior hemorrhoidal, and fourth sacral nerves.

Action.—It is a voluntary aid to the closure of the anus. It flexes the coccyx and braces the central tendon of the perineum.

The **ischio-rectal fossæ** (Plate CCCCLXI) are the spaces intervening between the rectum medially, and the rami and tuberosities of the ischia laterally. Each fossa is cuneiform in shape, its base being directed downward, and formed by the skin and superficial fascia; the edge of the wedge is directed upward, and is situated at the line along which the anal fascia springs from the obturator fascia. Each ischio-rectal fossa measures about five centimeters (two inches) from before backward, two and one-half centimeters (one inch) laterally, and between five and seven centimeters (two and three inches) in depth, being deepest

laterally near the tuberosity of the ischium. The medial wall is the longest. Each ischio-rectal fossa is bounded anteriorly by the deep layer of the superficial fascia covering the transverse perineal muscle, and by the base of the triangular ligament (*urogenital diaphragm*) of the perineum. Posteriorly, it is bounded by the gluteus maximus muscle and the great sacro-sciatic (*sacro-tuberous*) ligament. The medial boundary is formed by the levator ani and the coccygeus muscles, covered by the anal fascia. The lateral boundary is composed of the obturator fascia, the obturator internus muscle, and the ischium.

The **contents of the ischio-rectal fossa** are fat, the inferior hemorrhoidal vessels and nerve, the origins of the superficial perineal (*perineal*) artery and the perineal nerve, and the perineal branch of the fourth sacral nerve. In the lateral wall are the internal pudendal vessels and the pudendal nerve, and the dorsal nerve of the penis, and beneath the medial wall is the rectum.

The internal pudendal vessels, the pudendal nerve and the dorsal nerve of the penis are inclosed in a sheath, *the canal of Alcock*, formed by the obturator fascia, and are about four centimeters (one and a half inches) above the lower border of the tuberosity of the ischium. The *inferior hemorrhoidal artery* and *nerve*, which are branches of the internal pudendal artery and pudendal nerve respectively, pierce the medial wall of Alcock's canal and cross the space obliquely from the posterior portion of its lateral wall. They divide into a number of branches which supply the lower part of the rectum, the levator ani, and the sphincter ani muscles, the superficial fascia, and the skin. The inferior hemorrhoidal arteries anastomose with the same vessels of the opposite side and with branches of the middle and superior hemorrhoidal arteries. The radicles of the inferior hemorrhoidal veins often become varicose, and form **hemorrhoids,** or **piles.** At the posterior border of the space are seen the perineal branch of the fourth sacral nerve, which pierces the coccygeus muscle to supply the external sphincter ani, and some branches of the small sciatic nerve. The superficial perineal (*perineal*) artery and the superficial perineal (*posterior scrotal*) nerves run through the anterolateral part of the space. The *ano-coccygeal body* is an indefinite mass of fibrous and muscular tissue, the muscle fibers belonging to the levator ani and the external and internal sphincter muscles. It lies between the tip of the coccyx and the anus, giving support to the lower part of the rectum and the anus.

The **ischio-rectal, or anal, fascia** covers, and is in close relation with the superficial surface of the levator ani and the coccygeus muscles. Laterally, it springs from the obturator fascia just below the origin of the levator ani muscle; medially, it is continuous with the deep fascia covering the lateral portion of the external sphincter ani muscle; anteriorly, it is continuous with the deep layer of

PLATE CCCCLXII.

SUPERFICIAL MUSCLES, ARTERIES, AND NERVES OF MALE PERINEUM.

the triangular ligament (*superior fascia of urogenital diaphragm*), and at the anterior margin of the levator ani with the rectovesical fascia; posteriorly it blends with the deep fascia on the deep surface of the gluteus maximus muscle.

Ischio-rectal abscess.—The dependent position and the imperfect blood supply of the ischio-rectal fossæ favor the development of absceses in the soft fat of these fossæ. Such abscesses should be opened early, as they soon distend the fossa and may open in one of the two directions in which the pus meets with least resistance: through the skin or into the rectum. An ischio-rectal abscess opening both into the rectum and through the skin forms a **complete fistula-in-ano;** when it opens only into the rectum, it forms an **incomplete internal fistula,** and when it opens only externally, an **incomplete external fistula.** In a complete, as well as in an incomplete internal fistula the tissues in the immediate neighborhood may become emphysematous through escape of gas from the rectum into the tissues. When the pus of an ischio-rectal abscess finds its way into the rectum, the opening is most frequently from one to four centimeters (one-half to one and a half inches) from the anus, as the anal fascia and levator ani muscle and their attachments act as barriers which divert the pus downward to the level of the internal sphincter ani muscle.

In opening an ischio-rectal abscess care should be taken to avoid wounding the rectum and the internal pudendal vessels. The incision may be made from before backward in the line of the fibers of the external sphincter ani muscle, and slightly nearer to the tuberosity of the ischium than to the anus. This incision crosses the external hemorrhoidal vessels and is followed by trifling bleeding.

Dissection.—Remove the deep layer of the superficial fascia by carrying a vertical incision from the base of the scrotum along the mid-line as far as the posterior limit of the urogenital triangle; at right angles to the first, make a second incision extending lateralward upon each side to the tuberosity of the ischium, thus severing its connection with the lower margin of the triangular ligament (*urogenital diaphragm*); each half can then be reflected laterally. This will expose the vessels, nerves, and muscles situated in the superficial perineal interspace. Displacing the adjacent borders of the accelerator urinæ (*bulbo-cavernosus*) and erector penis (*ischio-cavernosus*) muscles exposes the superficial layer of the triangular ligament (*inferior fascia of urogenital diaphragm*).

The **superficial perineal (perineal) artery** (Plate CCCCLXII) rises from the internal pudendal at the anterior and lateral part of the ischio-rectal fossa. It pierces the medial wall of Alcock's canal and then the base of the triangular ligament (*urogenital diaphragm*), and runs either over or under or through the transverse perineal muscle; thence forward, between the accelerator urinæ (*bulbo-cavernosus*) and the erector penis (*ischio-cavernosus*) muscles, both of which it supplies,

and is finally distributed to the scrotum to the dartos muscle and integument which it supplies by a number of long slender branches, called the *posterior scrotal arteries*, which anastomose with the external pudendal branches of the common femoral artery. It is accompanied by the anterior superficial perineal nerve.

The **transverse perineal artery** usually arises from the superficial perineal (*perineal*), where this vessel is in relation with the transverse perineal muscle; it may also arise from the internal pudendal artery. It runs medially, either over or under the transverse perineal muscle, which it supplies, to the central point of the perineum, where it ends by supplying the parts in that region and where it anastomoses with the corresponding artery of the opposite side. It is this artery which is severed in the operation of lateral lithotomy.

The **veins** accompanying the foregoing arteries empty into the internal pudendal vein.

The **cutaneous nerves of the perineum** (Plate CCCCLXII) are the anterior and posterior superficial perineal (*posterior scrotal*) and the inferior pudenal (*long perineal*).

The **anterior, or medial, superficial perineal (posterior scrotal) nerve,** a branch of the perineal division of the pudendal in the ischio-rectal fossa, pierces Colles' fascia (*membranous layer of superficial fascia*) at its junction with the base of the triangular ligament (*urogenital diaphragm*), passes either under or through the transverse perineal muscle, and accompanies the superficial perineal (*perineal*) artery to the scrotum. It gives off muscular branches to the levator ani and the superficial muscles, and cutaneous branches to the integument and the fascia of the scrotum and around the root of the penis.

The **posterior, or lateral, superficial perineal (posterior scrotal) nerve** is also derived from the perineal division of the pudendal nerve in the anterior part of the ischio-rectal fossa. It runs forward in the superficial surface of Colles' fascia to the scrotum. Sometimes it pierces Colles' fascia at its junction with the base of the triangular ligament (*urogenital diaphragm*), and passes forward either over or under the transverse perineal muscle, accompanying the superficial perineal (*perineal*) artery. It sends filaments to the sphincter ani muscle and to the skin in front of the anus. It receives a communicating branch from the inferior hemorrhoidal nerve. At the back part of the scrotum it communicates with the anterior or medial superficial perineal (*posterior scrotal*) nerves and with the inferior pudendal (*long perineal*) nerve.

The **inferior,** or **long, pudendal (long perineal) nerve** is a branch of the small sciatic (*posterior cutaneous nerve of the thigh*). It pierces the fascia lata about two and a half centimeters (one inch) above the ischial tuberosity, passes obliquely upward and medially over the ascending ramus of the ischium, and then runs forward over or pierces the deep layer of the superficial fascia of the perineum. It is

distributed to the integument of the scrotum and outer part of the perineum, communicating with the posterior branch of the perineal nerve. It also communicates with the inferior hemorrhoidal nerve. In its course to the perineum it gives off collateral branches to the skin of the proximal and medial aspect of the thigh. Pain referred to the back of the thigh in affections of the perineum or scrotum in the male, and of the perineum or vulva in the female, is explained through the connection of the small sciatic nerve (*posterior cutaneous nerve of the thigh*) with the posterior superficial perineal nerve (*posterior scrotal*) by means of the inferior pudendal (*long perineal*) and by the cutaneous branches of the latter.

The muscles occupying the superficial perineal interspace which are seen at this stage of the dissection are the accelerator urinæ (*bulbo-cavernosus*) in the median line, the erector penis (*ischio-cavernosus*) at the side, and the transverse perineal below. They form two muscular triangles, the common perpendicular of which is formed by the acceleratores urinæ (*bulbo-cavernosi*); the base of each triangle, by the transverse perineal; and the hypothenuse, by the erector penis (*ischio-cavernosus*).

The **accelerator urinæ,** or **bulbo-cavernosus, muscle** lies on the bulb of the corpus spongiosum (*bulb of urethra*) and on the portion of the corpus spongiosum (*corpus cavernosum urethræ*) just anterior to the bulb. It is a double muscle, the two symmetrical halves being united in the median line on the superficial surface of the bulb by a median tendon or raphe. It consists of three sets of fibers: posterior, middle, and anterior. The posterior fibers are *inserted* into the anterior layer of the triangular ligament (*urogenital diaphragm*) on each side of the bulb; some of the most posterior fibers are *inserted* beneath the crus penis into the middle of the ischio-pubic ramus; the middle fibers, comprising the greater part of the muscle, surround the bulb and the adjacent part of the corpus spongiosum (*corpus cavernosum urethræ*) and join the fibers of the opposite muscle in a common tendon between the corpus spongiosum (*corpus cavernosum urethræ*) and the corpora cavernosa (*corpora cavernosa penis*); the anterior fibers form two long narrow muscular bands which diverge from one another like the limbs of the letter V, and passing around the corpus cavernosum (*corpus cavernosum penis*), terminate in a common tendon covering the dorsal vessels of the penis.

Action.—The action of the accelerator urinæ (*bulbo-cavernosus*) muscle as a whole is to compress the bulb and to expel the last drop of urine in this part of the urethra, after the bladder has been emptied. It also assists in expelling the semen. The middle fibers assist in the erection of the corpus spongiosum (*corpus cavernosum urethræ*) by compressing the erectile tissue of the bulb, and the anterior fibers assist in the same process, by compressing the dorsal vein of the penis. The part the muscle plays in the emission of semen is involuntary.

The **erector penis,** or **ischio-cavernosus, muscle** covers the crus penis. It is narrower at the ends than in the middle, and is situated along the lateral boundary of the urogenital triangle. It *arises* by muscular and tendinous fibers from the inner surface of the tuberosity of the ischium behind the crus penis, from the crus itself, and from the ischio-pubic ramus on both sides of the crus. Its fibers ascend, cover the crus penis, and terminate in a small aponeurosis which is *inserted* into the inferior surface of the crus and into the lateral and dorsal aspects of the corpus cavernosum penis.

Action.—The action of the muscle is to compress the crus penis and to assist in producing erection of the penis by retarding the escape of the venous blood.

The **superficial transverse perineal muscle** is small and lies along the base of the urogenital triangle. It *arises* from the medial and anterior surface of the tuberosity of the ischium, and passes forward and medially to be *inserted* into the central tendon of the perineum, where it joins the corresponding muscle of the opposite side, the accelerator urinæ (*bulbo-cavernosus*), the sphincter ani, and the anterior fibers of the levator ani. In the operation of lateral lithotomy this muscle is divided, thus establishing a communication between the two triangles of the perineum—the urogenital and the anal. It is around the lower border of this muscle that the deep layer of the superficial fascia winds to become continuous with the base of the triangular ligament (*urogenital diaphragm*). The two superficial transverse perineal muscles together were formerly known as the perineal digastric muscle.

Action.—It helps to fix the central tendon of the perineum during the contraction of the accelerator urinæ (*bulbo-cavernosus*).

Blood Supply.—The blood supply of the accelerator urinæ (*bulbo-cavernosus*), erector penis (*ischio-cavernosus*), and the transverse perineal muscles is derived from the superficial and transverse perineal arteries.

Nerve Supply.—The nerve supply of the accelerator urinæ (*bulbo-cavernosus*), erector penis (*ischio-cavernosus*), and the transverse perineal muscles is derived from the muscular branches of the perineal nerve.

Dissection.—Divide and reflect the superficial transverse perineal muscle and the crus penis and erector penis (*ischio-cavernosus*) muscle of one side, and remove the accelerator urinæ (*bulbo-cavernosus*) muscle from the bulb, thus exposing the anterior layer of the triangular ligament (*urogenital diaphragm*), the bulb of the corpus spongiosum (*corpus cavernosum urethræ*) and the dorsal artery, vein, and nerve of the penis.

The **triangular ligament** (**urogenital diaphragm**) (Plates CCCCLXIII; CCCCLXIV) is a strong fibrous membrane which stretches across that portion of

PLATE CCCCLXIII.

Corpus spongiosum (corpus cavernosum urethrae)
Dorsal a.of penis
Dorsal n.of penis
Arteries of corpus cavernosum (deep arteries of penis)
Dorsal v.of penis
Crus penis
Erector penis (ischio-cavernosus) m.
Colles' fascia (membranous layer, superficial fascia of perineum)
Transverse perineal m.(cut)
Dorsal nerve of penis
Internal pudendal a.
Perineal n.
Perineal a.
External sphincter ani m.
Gluteus maximus m.
Levator ani m.
Superficial layer of triangular lig. (inferior fascia of urogenital diaphragm)
Bulb of corpus spongiosum (bulb of urethra)

SUPERFICIAL LAYER OF TRIANGULAR LIGAMENT OF MALE PERINEUM.
(INFERIOR FASCIA OF UROGENITAL DIAPHRAGM OF MALE PERINEUM).

PLATE CCCCLXIV.

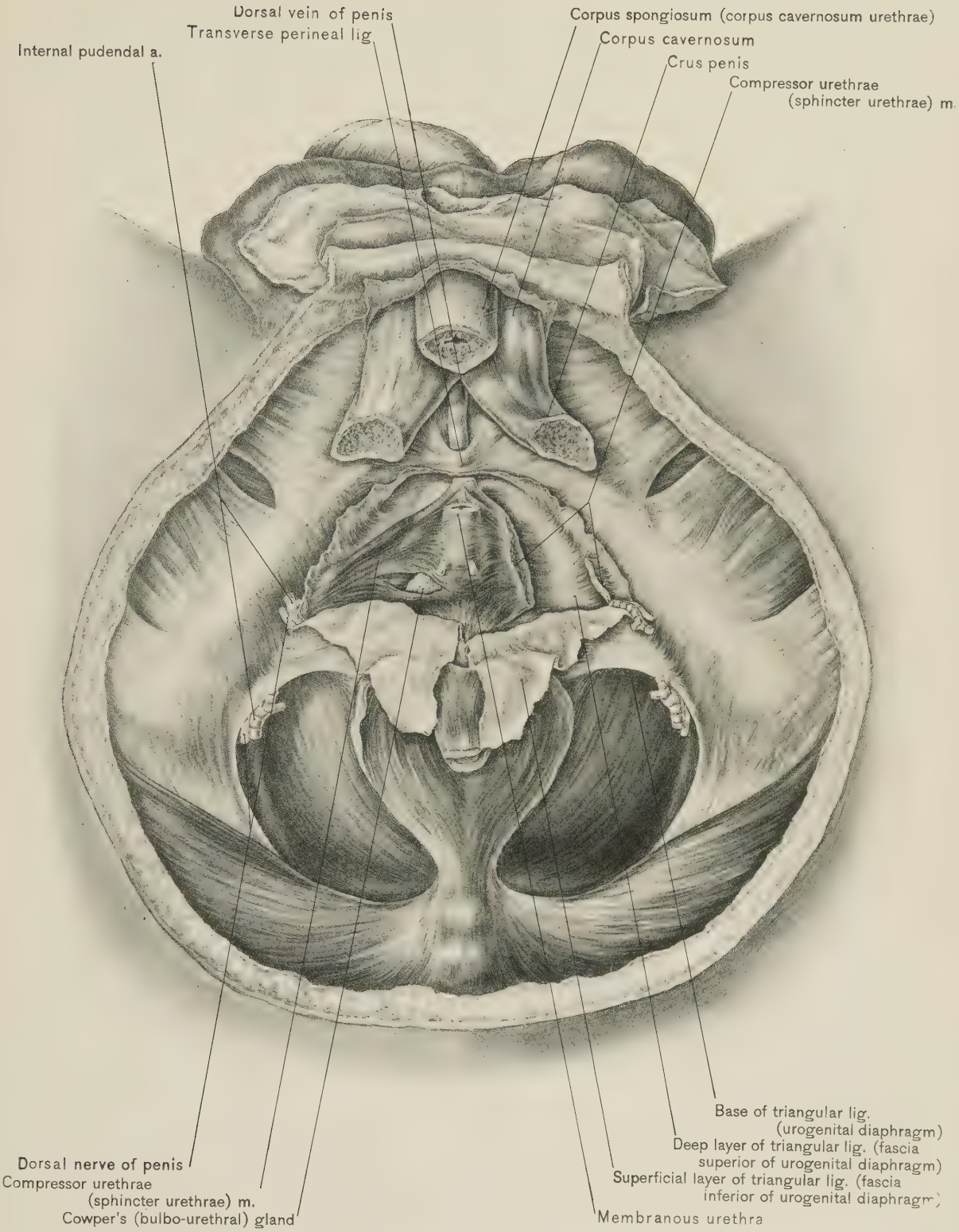
Dorsal vein of penis
Transverse perineal lig.
Internal pudendal a.
Corpus spongiosum (corpus cavernosum urethrae)
Corpus cavernosum
Crus penis
Compressor urethrae (sphincter urethrae) m.
Base of triangular lig. (urogenital diaphragm)
Deep layer of triangular lig. (fascia superior of urogenital diaphragm)
Superficial layer of triangular lig. (fascia inferior of urogenital diaphragm)
Membranous urethra
Dorsal nerve of penis
Compressor urethrae (sphincter urethrae) m.
Cowper's (bulbo-urethral) gland

TRIANGULAR LIGAMENT (UROGENITAL DIAPHRAGM) AND COMPRESSOR URETHRAE (SPHINCTER URETHRAE) MUSCLE.

the outlet of the pelvis occupied by the perineum proper. It measures about four centimeters (one and a half inches) from base to apex, its base being directed backward and its apex forward. Like the obturator membrane, it is part of the ligamentous wall of the pelvis. It is composed of two layers, the dense aponeurotic membrane, which is the *inferior*, or *superficial, layer* of the triangular ligament (*fascia inferior of the urogenital diaphragm*), and the fascial partition passing on the deep surface of the compressor urethræ (*sphincter urethræ*) muscle, the *superior*, or *deep, layer of the triangular ligament* (*fascia superior of the urogenital diaphragm*). In front, the triangular ligament (*urogenital diaphragm*) is attached to the subpubic (*arcutae pubic*) ligament, except in the center, where the dorsal vein of the penis passes between these two structures; laterally, to the rami of the pubes and ischium more deeply than the crus penis, and near its base, in the median line, it blends with the central tendon of the perineum in the interval between the urethra and the rectum. The base of the triangular ligament (*urogenital diaphragm*) is continuous with the deep layer of the superficial perineal fascia; its deep surface near its base is continuous with the anal fascia and the superior layer of the ligament. Laterally, the layers of the triangular ligament (*urogenital diaphragm*) are continuous with the obturator fascia, and the superior layer is fused with the endo-pelvic fascia which covers the inferior surface of the prostate.

The **transverse perineal ligament** is formed by fibers of the triangular ligament (*urogenital diaphragm*) which pass from one side of the pubic arch to the other near the subpubic (*arcuate pubic*) ligament. In relation with the superficial surface of the triangular ligament (*urogenital diaphragm*) are the contents of the superficial perineal interspace previously described. Some of the fibers of the ligament are reflected upon the bulb of the corpus spongiosum (*bulb of urethra*) and strengthen its fibrous investment. At about two and one-half centimeters (one inch) below the symphysis pubis the triangular ligament (*urogenital diaphragm*) is perforated by the urethra. It is pierced by the arteries of the corpora cavernosa penis, the dorsal arteries and nerves of the penis, the arteries to the bulb, and the ducts of Cowper's (*bulbo-urethral*) glands, and, finally, at the base, where it becomes continuous with the deep layer of the superficial perineal fascia, by the superficial perineal vessels and nerves (*perineal vessels and posterior scrotal nerves*). In rupture of the spongy urethra the triangular ligament (*urogenital diaphragm*) prevents the urine from gaining access to the pelvis, and in rupture of the membranous urethra it prevents the urine from escaping from the pelvis into the more superficial tissues of the perineum.

The first obstruction to the passage of an instrument through the urethra, provided it contains no strictures and is otherwise normal, is the lower margin of the urethral orifice of the triangular ligament (*urogenital diaphragm*); this

natural obstruction is to be borne in mind when passing such an instrument. The base of this ligament is divided in the operations of lateral and median lithotomy and in perineal sections in which the membranous urethra is attacked.

Dissection.—Divide the triangular ligament (*urogenital diaphragm*) or the superficial layer of the ligament, at its attachment to the rami of the pubes and ischium and turn it medialward, upon the side of the perineum from which the crus penis has been removed. Next carefully trace the structures occupying the deep perineal interspace proper.

The **deep perineal interspace** is situated in the perineum proper between the two layers of the triangular ligament (*urogenital diaphragm*). It contains the compressor urethræ (*sphincter urethræ*) muscle, the membranous urethra, Cowper's (*bulbo-urethral*) glands and their ducts, the arteries of the bulb, the internal pudendal arteries, the arteries of the corpora cavernosa penis, and the dorsal arteries, vein, and nerves of the penis.

The **compressor urethræ** (**sphincter urethræ**) **muscle** (Plate CCCCLXIV) consists of transverse fibers, and completely surrounds the membranous portion of the urethra, being enclosed in the layers of the triangular ligament (*urogenital diaphragm*). It *arises* on each side from the ischio-pubic ramus for a distance of about twelve millimeters (half an inch). The fibers pass medially and separate into two sets, one of which passes anterior and the other posterior to the membranous urethra. The muscles of the two sides are *inserted* into a median raphe, the most anterior fibers being inserted into the connective tissue filling the angular interval at the junction of the crura of the penis, and the most posterior fibers into the perineal center. The most medial fibers form a continuous circular investment for the membranous urethra.

Blood Supply.—From the internal pudendal artery and the artery of the bulb.

Nerve Supply.—From the perineal division of the pudendal nerve.

Action.—The action of the muscle is to diminish the caliber of the membranous urethra and thus aid in the retention of urine in the bladder, to compress the veins of the penis in erection of that organ, and to assist in expelling urine and semen. Beneath the fibers of the compressor urethræ (*sphincter urethræ*), and surrounding the urethra are involuntary circular muscle fibers which are continuous with the muscle fibers of the bladder, and which assist in forcing forward the urine and the semen. The membranous urethra may be the site of spasmodic stricture, or urethrismus, resulting from some pathologic condition of the pendulous urethra.

The **deep transverse perineal muscle** *arises* from the inferior ramus of the ischium and passes medially where it interlaces with its fellow of the opposite

side in a tendinous raphe. It lies in the same plane as the compressor urethræ (*sphincter urethræ*) and is enclosed by the two layers of the triangular ligament (*urogenital diaphragm*).

Nerve Supply.—From the perineal branch of the pudendal nerve.

Action.—The muscle is a tensor of the central point of the perineum.

Cowper's (bulbo-urethral) glands are two small, reddish-yellow racemose glands, about the size of a pea, situated behind and below the membranous urethra, one on each side of the median line, in the substance of the compressor urethræ (*sphincter urethræ*) muscle. They are overlapped by the posterior end of the bulb, from which they are separated by the anterior layer of the triangular ligament (*urogenital diaphragm*). The duct of each gland is two and a half to four centimeters (one to one and a half inches) in length. It pierces the superficial layer of the triangular ligament (*urogenital diaphragm*), runs forward in the bulb along the floor of the bulbous urethra, and then obliquely enters the bulbous urethra at its floor. Sometimes these glands are so small as to escape detection. Their secretion is accessory to the seminal fluid.

The **artery of the bulb of the urethra** is a vessel of considerable size. It arises from the internal pudendal artery just after it has pierced the superior layer of the triangular ligament (*urogenital diaphragm*) and passes medially and forward through the substance of the compressor urethræ (*sphincter urethræ*) muscle, one centimeter anterior to a line drawn from the tuberosity of the ischium to the perineal center. It pierces the anterior layer of the triangular ligament (*urogenital diaphragm*) to enter the posterior part of the bulb. Thence it continues forward in the corpus spongiosum (*corpus cavernosum urethræ*) and the compressor urethræ (*sphincter urethræ*) muscle, and supplies the bulb of the urethra and the posterior third of the corpus spongiosum (*corpus cavernosum urethræ*). It furnishes small branches to Cowper's (*bulbo-urethral*) glands. In the operation of lateral lithotomy it is specially desirable to avoid wounding this vessel, as the resulting hemorrhage is sometimes difficult to control.

The **membranous portion of the urethra** is included between the two layers of the triangular ligament (*urogenital diaphragm*), and is situated about two and a half centimeters (one inch) below the pubic arch, from which it is separated by the dorsal vein of the penis and the subpubic (*arcuate pubic*) ligament. It extends from the apex of the prostate gland behind, to the bulb of the penis in front. With the exception of the external urinary meatus, it is the narrowest and least dilatable part of the entire urethra, and is without exception the most unfavorable location for stricture. It measures less than two centimeters (three-fourths of an inch) along its upper surface and about one and one-fourth centimeters (half an inch) along its lower surface, its length inferiorly being

considerably reduced by the projection backward of the bulb of the corpus spongiosum (*bulb of urethra*). It is separated from the rectum by the compressor urethræ (*sphincter urethræ*) muscle, Cowper's (*bulbo-urethral*) glands, the deep layer of the triangular ligament (*urogenital diaphragm*) and the levator ani muscle.

The **internal pudendal artery,** the smaller of the two terminal divisions of the anterior trunk of the internal iliac (*hypogastric*) artery, leaves the pelvis through the greater sacro-sciatic (*greater sciatic*) foramen between the pyriformis and coccygeus muscles and above the sciatic artery. It crosses the lateral surface of the spine of the ischium under cover of the gluteus maximus muscle, and re-enters the pelvis through the lesser sacro-sciatic (*lesser sciatic*) foramen, where it crosses the obturator internus muscle. In this latter situation it is accompanied by two venæ comites, the perineal nerve, and the dorsal nerve of the penis, which are included with the internal pudendal artery in the canal of Alcock, which is a tubular sheath formed by the obturator fascia. It runs forward in this canal, lying about four centimeters (an inch and a half) above the lower margin of the tuberosity of the ischium. It ascends along the ramus of the ischium, pierces the posterior layer of the triangular ligament (*urogenital diaphragm*), runs along the medial margin of the ramus of the pubis, between the fibers of the compressor urethræ (*sphincter urethræ*) muscle at its origin, and at the anterior part of the deep perineal interspace gives off the artery of the corpus cavernosum (*deep artery of the penis*), and continues through the anterior layer of the triangular ligament (*urogenital diaphragm*) as the dorsal artery of the penis. The portion of the vessel exposed in this dissection is that included between the two layers of the triangular ligament (*urogenital diaphragm*), from which arises the artery of the bulb, already described.

The **artery of the corpus cavernosum** (**deep artery of the penis**) (Plate CCCCLXV) arises as one of the terminal branches of the internal pudendal, pierces the anterior layer of the triangular ligament (*urogenital diaphragm*), enters the corpus cavernosum at about the junction of the middle and posterior thirds. When it reaches the center of the corpus it divides into an anterior and a posterior branch, the former supplying the anterior two-thirds, the latter the posterior third of the structure.

The **dorsal artery of the penis** arises as one of the terminal branches of the internal pudendal artery, pierces the superficial layer of the triangular ligament (*urogenital diaphragm*), runs upward between the crus penis and the body of the pubis, passes between the two layers of the suspensory ligament of the penis and runs in the dartos along the dorsum of the penis, between the dorsal vein and nerve, to the glans, around the base of which, with the dorsal artery of the

PLATE CCCCLXV.

Dorsal vein of penis
Dorsal artery of penis
Arteries to corpus cavernosum (deep arteries of penis)
Dorsal nerve of penis
Urethra
Bulb of corpus spongiosum (bulb of corpus cavernosum urethrae)
Compressor urethrae (sphincter urethrae) m.
Internal pudendal a.
Artery of bulb
Segment of bulb(everted)
Dorsal nerve of penis
Duct of Cowper's (bulbo-urethral) gland
Urethra
Triangular ligament (urogenital diaphragm)
Deep layer of triangular lig. (fascia superior of urogenital diaphragm)
Superficial layer of triangular lig. (fascia inferior of urogenital diaphragm)

DEEP VESSELS AND NERVES OF MALE PERINEUM.

opposite side, it forms a complete arterial circle. It supplies the integument of the penis.

The **internal pudendal vein** accompanies the internal pudendal artery, and receives branches corresponding to those of the artery, with the exception of the dorsal vein of the penis, which gives only a small branch to the internal pudendal vein.

The **dorsal vein of the penis,** a rather large vessel, returns the blood from the skin, the glans, the prepuce, the corpus spongiosum (*corpus cavernosum urethræ*) and the corpora cavernosa of the penis. It consists at first of two branches which run along the dorsum of the penis and unite near the root into a single trunk. It runs between the two layers of the suspensory ligament of the penis, gives off a branch to the internal pudendal vein, passes between the subpubic (*arcuate pubic*) ligament and the triangular ligament (*urogenital diaphragm*) and empties into the prostatic plexus of veins which opens into the hypogastric veins.

The **pudendal nerve,** a branch of the lower part of the sacral plexus, accompanies the internal pudendal artery from the pelvis over the spine of the ischium into the ischio-rectal fossa and into Alcock's canal. After giving off the inferior hemorrhoidal nerve at the posterior part of the external wall of the ischio-rectal fossa, it divides into two terminal branches—the perineal nerve and the dorsal nerve of the penis.

The **dorsal nerve of the penis,** the continuation of the pudendal nerve, accompanies the internal pudendal artery in Alcock's canal, through the posterior layer of the triangular ligament (*urogenital diaphragm*), and between the anterior and posterior layers of the triangular ligament (*urogenital diaphragm*), finally to pierce the anterior layer and run along the lateral side of the dorsal artery. It gives off the nerve to the corpus cavernosum, which supplies the erectile tissue of the crus penis and corpus cavernosum. It supplies the anterior two-thirds of the penis, including the glans.

The **perineal nerve,** the shorter and larger of the two terminal divisions of the pudendal nerve, is seen in the lateral part of the ischio-rectal fossa. It divides into cutaneous and muscular branches. The *cutaneous branches* are the anterior and posterior superficial perineal (*posterior scrotal*) nerves, and have already been described. The *muscular branches* supply twigs to the bulb and to the compressor urethræ (*sphincter urethræ*), the levator ani, the transverse perineal, the accelerator urinæ (*sphincter urethræ*) and erector penis (*ischio-cavernosus*) muscles. One branch, the nerve to the bulb, innervates the urethra as far forward as the glans.

The **subpubic ligament** (**arcuate ligament of pubis**) is situated below the symphysis and the bodies of the pubes, and laterally between the rami of the pubes. Its apex is directed upward and is fused with the interarticular fibro-

cartilage; its base is directed toward the membranous urethra. Note the small aperture between the subpubic (*arcuate pubic*) ligament and the triangular ligament (*urogenital diaphragm*) for the passage of the dorsal vein of the penis.

Dissection.—Remove the compressor urethræ (*sphincter urethræ*) muscle to expose the superior layer of the triangular ligament (*fascia superior of the urogenital diaphragm*).

The **superior, deep,** or **posterior, layer of the triangular ligament** (**fascia superior of the urogenital diaphragm**) is derived from the obturator division of the pelvic fascia, and is the fascial partition situated between the compressor urethræ (*sphincter urethræ*) and the levator ani muscles. It is pierced by the membranous urethra, the internal pudendal artery and veins, and the dorsal nerve of the penis. Laterally, it is attached to the ischio-pubic rami; anteriorly, to the subpubic (*arcuate pubic*) ligament, from which it is partly separated by the dorsal vein of the penis, and posteriorly, it blends with the deep surface of the superficial layer of the triangular ligament (*fascia inferior of the urogenital diaphragm*) at the posterior margin of the compressor urethræ (*sphincter urethræ*) muscle. Anterior to the anterior margin of the levator ani muscle the deep layer of the ligament is adherent to the recto-vesical fascia, and especially to that part forming the capsule of the prostate gland. This layer of the triangular ligament is thinner than the superficial layer, or triangular ligament (*urogenital diaphragm*) proper; the descriptions of the perineum would be less obscure and more accurate if the deep layer were considered the anterior part of the anal fascia. The anal fascia could then be described as adherent to the deep surface of the posterior portion of the triangular ligament (*urogenital diaphragm*), and as composed of an anterior and a posterior portion.

Dissection.—Remove the posterior, or deep, layer of the triangular ligament (*urogenital diaphragm*) and the anal fascia to expose the inferior surface of the levator ani muscle.

The **levator ani muscle** (Plate CCCCLXVI) is a thin sheet of muscle which lies superficial to the recto-vesical fascia. Its *anterior fibers arise* from the inferior portion of the posterior surface of the body of the pubis, between the recto-vesical fascia and the superior layer of the triangular ligament (*fascia superior of the urogenital diaphragm*), and external to the pubo-vesical muscle. The *posterior fibers arise* from the pelvic surface of the spine of the ischium. The *intermediate* fibers have an *aponeurotic origin* from the white line of the pelvic fascia in the angle of divergence of the recto-vesical and the obturator fasciæ. Its anterior fibers pass backward and downward around the lateral aspect of the prostate gland to be *inserted* into the central tendon of the perineum, and have been termed the *levator prostatæ*. Its intermediate fibers pass downward along the

PLATE CCCCLXVI.

LEVATOR ANI MUSCLE OF MALE PERINEUM.

PLATE CCCCLXVII.

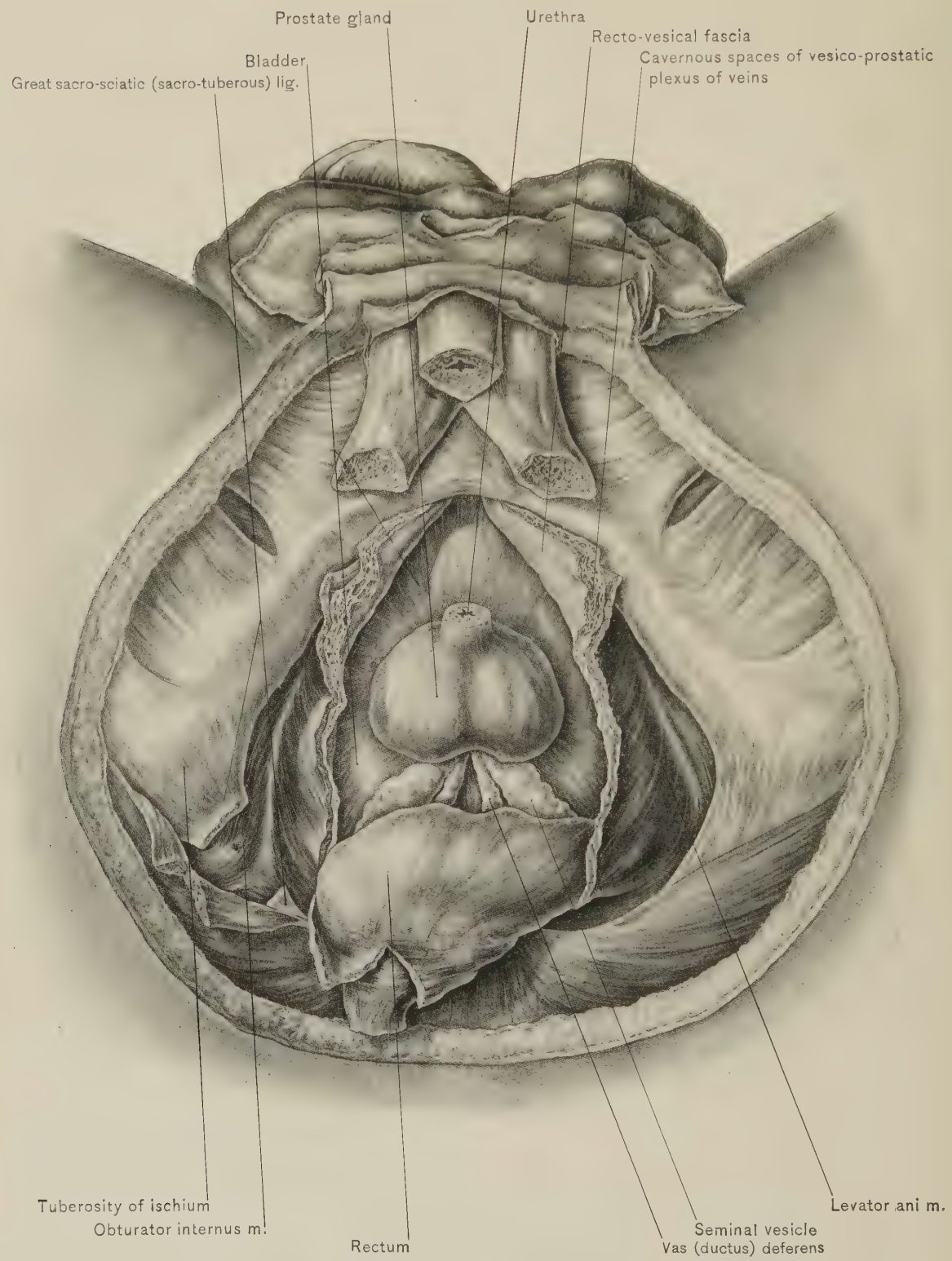

PELVIC ORGANS SEEN IN DISSECTION OF MALE PERINEUM.

side of the rectum to be *inserted* into the side of the rectum, interlacing with the fibers of the external sphincter ani muscle. Its posterior fibers pass downward and medialward to be inserted into the side of the lower part of the coccyx and the fibrous raphe connecting the coccyx with the rectum.

Nerve Supply.—From the inferior hemorrhoidal nerve and by special branches from the third and fourth sacral nerves, the latter supplying the pelvic surface.

Action.—It elevates the pelvic floor and the coccyx, thus compressing the abdominal and pelvic viscera and aiding in the expulsion of the contents of the rectum and bladder.

Dissection.—After dividing the anterior and middle fibers of the levator ani muscle and the recto-vesical fascia, displace the rectum to expose the prostate gland, the neck and base of the bladder, the seminal vesicles, the terminal portions of the spermatic ducts, or vasa deferentia (*ductus deferentes*), the ejaculatory ducts, and the junction of the ureters with the bladder. (Plate CCCCLXVII)

The suprapubic approach for the removal of vesical calculi has been almost universally adopted unless coexisting conditions such as urethral stricture, hypertrophied prostate, or impacted urethral calculi demand a perineal incision. For this reason a formal description of the operations of lateral and median lithotomy are omitted in this revision of the text.

The **recto-urethral space** has been exposed by the previous dissection. The apex of this space is at the junction of the rectum with the middle lobe of the prostate. The sides are formed by the anterior fibers of the levator ani. This is the space through which the knife passes in the operation of median perineal cystotomy.

Perineal Prostatectomy.—This route is chosen when a suprapubic operation is not indicated, especially in those cases in which the enlarged prostate does not present into the bladder but into the posterior urethra. The method of choice is Young's operation, known as conservative perineal prostatectomy, inasmuch as it conserves the connection between the ejaculatory ducts and the urethra, the enucleation being entirely extra-urethral.

A sound, which later acts as a guide for the urethrotomy, is introduced in the posterior urethra, and the patient is placed in the lithotomy position, with the thighs completely flexed upon the abdomen, so as to bring the perineum nearly parallel with the floor. A V-shaped incision is made over the posterior portion of the bulb, about five centimeters (two inches) from the anus, the arms of the incision being parallel with the ischio-pubic rami, each arm being about five centimeters (two inches) in length. The scalpel is carried to the level of the deep fascia, after which the necessary exposure is obtained largely by blunt dissection.

The index finger is pushed through the soft cellular tissue to either side of the central tendon of the perineum. This opens up a space which is bounded anteriorly, by the transverse perineal muscles, and laterally by the levator ani muscles. The central tendon is engaged within the blades of a bifid retractor, thus putting the tendon and the associated muscles on the stretch, so that they can be severed close to the bulb without danger of injuring the latter.

The greatest danger of the operation lies in injury to the rectum during the division of the recto-urethralis muscle. This muscle lies beneath the two branches of the levator ani muscles and covers the membranous urethra inserting into the anterior wall of the rectum. Injury to the rectum can be avoided by care in dividing the central tendon, displacing the bulb forward and dividing the muscle close to the urethra. The rest of the operation is carried on in the space provided by division of the muscle. This space is bounded posteriorly, by the rectum; anteriorly, by the prostate, the membranous urethra, and the deep perineal interspace within the confines of the triangular ligament (*fascia superior of urogenital diaphragm*), and laterally, by the levator ani muscles. The urethra is then incised in its long axis, over the sound, at a point just distal to the apex of the prostate. The incision should be just large enough to allow the introduction of a Young's prostatic tractor. The edges of the urethral incision, including the mucous membrane, are caught on either side with clamps and ligatures and the urethral sound withdrawn. The prostatic tractor is then inserted into the bladder through the perineal wound; after spreading its blades the prostate can be drawn downward and forward into the wound by pulling on the tractor and turning it upward and backward over the symphysis pubis.

The remaining structure to be divided is the posterior layer of the recto-vesical fascia. A transverse incision is made through the fascial layer near to the apex of the prostate. The anterior layer of fascia, which is bound to the prostatic sheath is brought into view; the incision is enlarged, and the rectum mobilized, bringing the prostate and the seminal vesicles into view. The rectum is held with a retractor, so as not to obtrude itself upon the operative field.

These preliminary steps of the operation having been properly performed, there will be a good exposure of the posterior, or rectal, surface of the prostate; in fact the gland may be brought almost, if not actually to the surface of the perineum. The gland is then enucleated. The sheath, composed of pelvic fascia, is incised on either side of the median line, the incision, being about one and a half centimeters (three-fourths of an inch) in depth, is carried down to the true capsule, when with the finger or blunt dissector the gland is removed in halves.

The prostatic bed is packed with gauze and the wound is closed.

PLATE CCCCLXVIII.

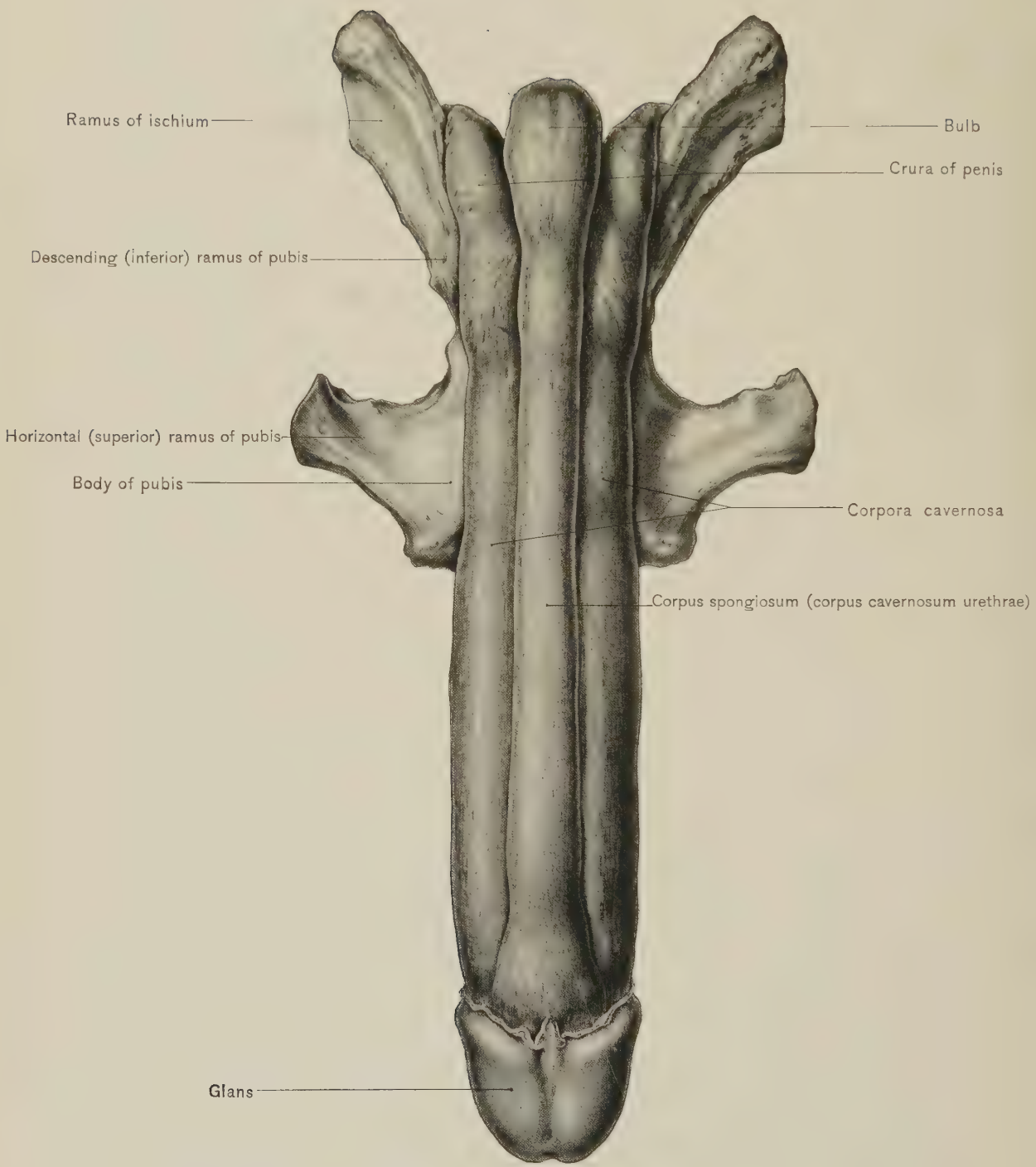

BODIES OF PENIS (DISTENDED).

THE EXTERNAL GENITALS OF THE MALE

The **external genital organs of the male** are the penis, the testicles, the spermatic cords, and the scrotum. In their description the entire length of the urethra is included.

The **penis,** the organ of copulation of the male, is composed of three rod-like bodies of erectile tissue enveloped by fascia and integument. These bodies (Plate CCCCLXVIII) are the two corpora cavernosa (*corpora cavernosa penis*) and the corpus spongiosum (*corpus cavernosum urethræ*). The **corpora cavernosa** are situated side by side in the dorsal portion of the penis, and form about two-thirds of the bulk of the organ. They are slightly separated anteriorly, where they terminate in blunt, conical extremities; they are widely separated posteriorly, where they commence as the crura of the penis; in the remainder of their extent they are closely united. The **crus penis,** the posterior portion of the corpus cavernosum, begins as a cuneiform body, is attached on its lateral aspect to the medial surface of the ischio-pubic ramus, and lies between Colles' fascia and the triangular ligament (*urogenital diaphragm*). The two crura converge as they pass forward, and become closely adherent just anterior to the subpubic (*arcuate pubic*) ligament. The corpora cavernosa are composed of erectile tissue, and are enveloped by a strong sheath, the **tunica albuginea.** The outer layer of the tunica albuginea invests both corpora cavernosa; its inner layer projects dorsally between the corpora cavernosa, forming the septum penis which further down becomes imperfect and is called the **pectiniform septum;** the latter incompletely separates them, the slit-like apertures permitting passage of anastomotic arteries and communication between the blood spaces. Each corpus cavernosum is supplied by the artery of the corpus cavernosum which traverses it.

The **corpus spongiosum** (**corpus cavernosum urethræ**) is situated in the under portion of the penis, in the groove between the corpora cavernosa. It is composed of erectile tissue and is also surrounded by the tunica albuginea, and through its erectile tissue passes the spongy portion of the urethra. It is divided into the bulb, the body, and the glans.

The **bulb of the penis** (**urethral bulb**), or of the corpus spongiosum (*corpus cavernosum urethræ*), is the posterior expanded portion of the corpus spongiosum (*corpus cavernosum urethræ*), situated in the superficial interspace of the perineum proper and surrounded by the accelerator urinæ (*bulbo-cavernosus*) muscle. It is about four centimeters (one and three-quarter inches) long and one and one-half centimeters (five-eighths of an inch) wide. It transmits the bulbous part of the spongy portion of the urethra, which enters it at its deep surface and runs nearer to that surface.

The **body** of the corpus spongiosum (*corpus cavernosum urethræ*) is of uniform diameter, the urethra lying nearer to its inferior surface.

The penis is arbitrarily divided, for purposes of description, into a main portion and two ends, called the root, the body, and the glans.

The **root of the penis** is formed by the crura, which are the posterior portions of the corpora cavernosa converging from their attachments to the sides of the subpubic arch to unite at the proximal end of the penis proper. The suspensory ligament of the organ, as it descends from the pubic symphysis and lower part of the linea alba of the abdomen, also forms part of the root of the penis. The form and dimensions of the erect penis are well demonstrated by making a deep narrow puncture in one or both crura penis and then inserting a blow-pipe and inflating the corpora cavernosa.

The **body** of the penis has the form of a prism with rounded margins, the corpus spongiosum (*corpus cavernosum urethræ*) and corpora cavernosa forming its lateral surfaces, and the corpora cavernosa its dorsal surface; this is most noticeable when the organ is erect. (Plate CCCCLXIX.)

The **glans penis** is the peculiar cordate expansion of the corpus spongiosum (*corpus cavernosum urethræ*) around the tapering anterior extremities of the corpora cavernosa. It has a well-defined, elevated border, called the *corona of the glans*, the depression back of it being called the *neck of the penis*. The vertical linear orifice at the apex of the glans is the *external urinary meatus*, or *external orifice of the urethra*.

The **skin of the penis** is pigmented, thin, and highly elastic, and is loosely attached to the body of the penis by the subcutaneous tissue. On the under surface of the penis it contains the continuation of the highly pigmented raphe of the perineum and the scrotum. At the neck of the penis it extends over the glans as a free double fold, called the *prepuce*, or *foreskin*. The skin of the glans is closely adherent. The *frenulum of the prepuce* is a small median fold extending from the prepuce to the under surface of the glans. It contains vessels which cause considerable hemorrhage if cut, or torn, as sometimes happens in coitus when the vaginal orifice is small.

The skin of the penis contains sebaceous glands, which are especially numerous at the neck of the penis. They secrete an odorous whitish substance which helps to form the *smegma præputii*. The smegma consists mainly of broken down desquamated epithelial cells from the adjacent surfaces of the glans and prepuce. When the prepuce is long and covers the glans, this secretion collects, and its odor causes considerable annoyance. When the prepuce covers the glans and the preputial orifice is small, a **congenital phimosis** exists.

The **dartos** is the subcutaneous tissue of the penis, and is continuous with the dartos of the scrotum. Its more superficial portion is composed of loose connec-

PLATE CCCCLXIX.

TRANSVERSE SECTION THROUGH BASE OF GLANS.

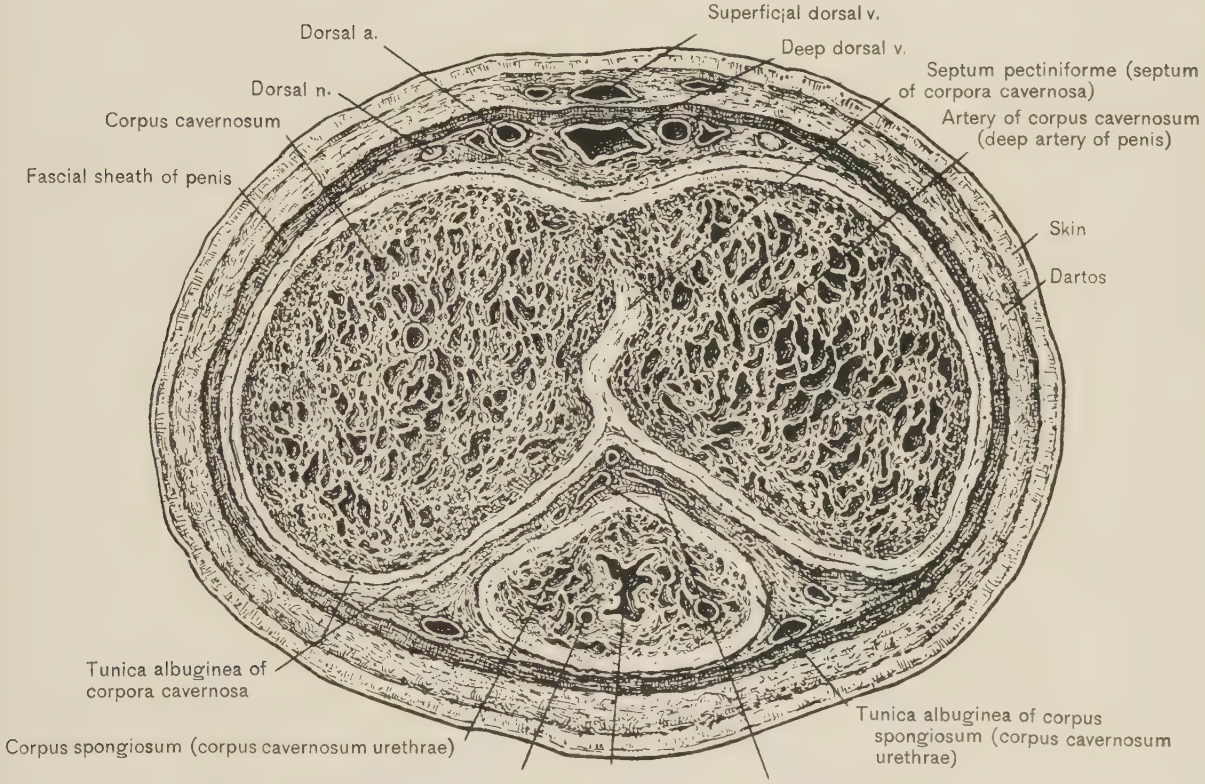

TRANSVERSE SECTION THROUGH BODY OF PENIS.

PLATE CCCCLXX.

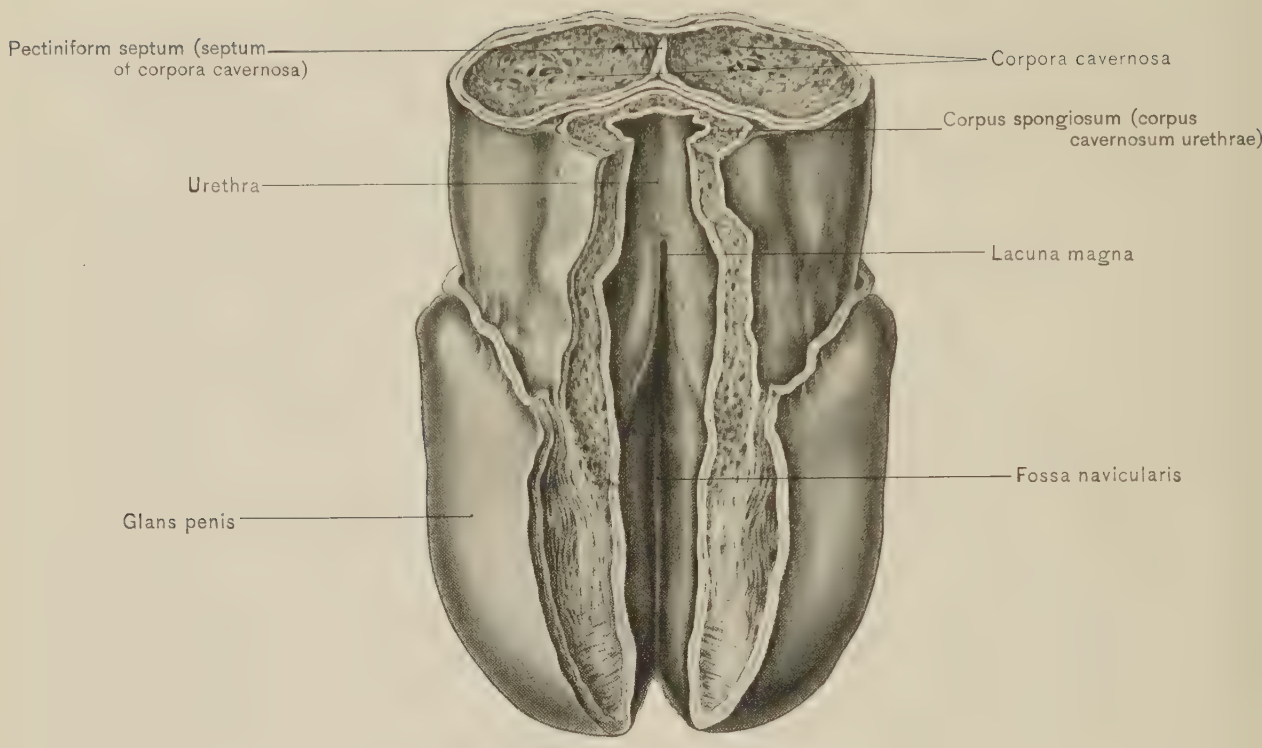

ANTERIOR PORTION OF URETHRA.

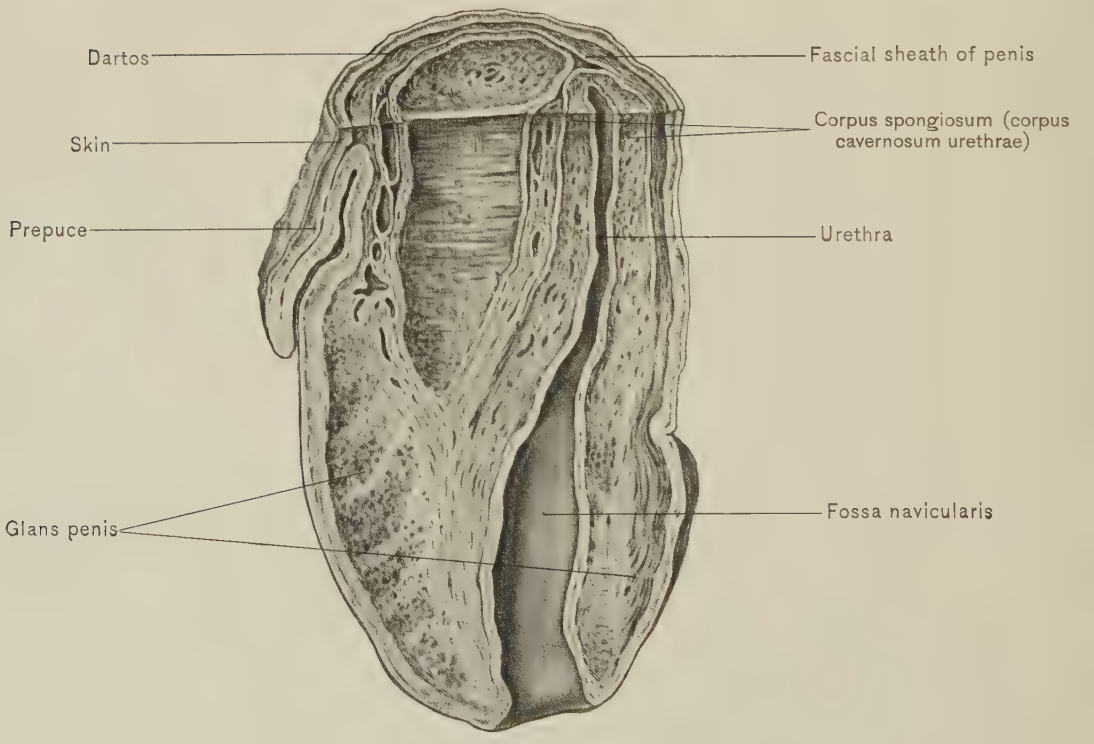

SAGITTAL SECTION OF ANTERIOR PORTION OF PENIS.

PLATE CCCCLXXI.

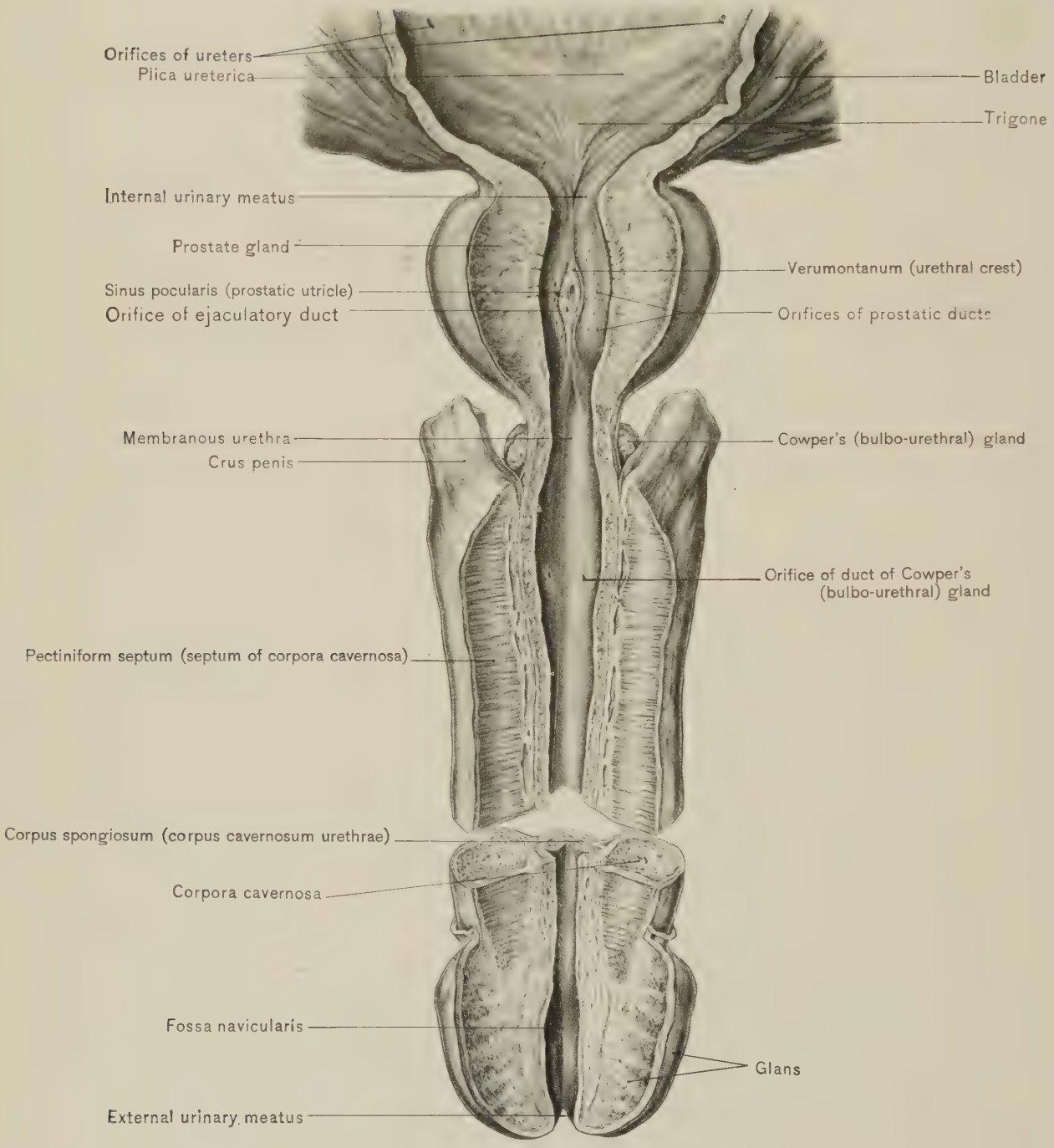

MALE URETHRA CLEFT DORSALLY.

tive tissue which permits excessive swelling in edema of the penis. Like the dartos of the scrotum, it contains unstriped muscle fibers. Its deep portion is more dense, and forms a **fascial sheath** of great elasticity, which invests the three bodies of the penis and at the angle of the penis is continuous with the suspensory ligament of the organ. The dartos extends between the two layers of skin forming the prepuce, and at the preputial orifice its muscle fibers, according to Sappey, form the *sphincter of the prepuce.*

The **suspensory ligament of the penis** is a strong, fibrous band which is attached to the lower part of the linea alba and to the front of the symphysis pubis; it blends with the fascial sheath of the penis just anterior to the bodies of the pubic bones.

The **angle of the penis** is at the point of suspension, or where the dependent portion of the flaccid organ is joined by the suspensory ligament.

The **urethra** (Plates CCCCLXX and CCCCLXXI) is the urinary canal; it extends from the internal urinary meatus at the neck of the bladder through the prostate gland, the triangular ligament (*urogenital diaphragm*), and the spongy body of the penis to the external urinary meatus, and is divided into prostatic, membranous, and spongy (*cavernous*) portions.

The length of the urethra in the flaccid condition of the penis, as determined by frozen sections, is about seventeen centimeters (seven inches). This may be increased by enlargement of the middle lobe of the prostate gland. The diameter of the canal varies with the size of the individual and of the penis, the ratio between the size (circumference) of the canal as compared with that of the penis being about four to nine; but this is variable.

The **prostatic portion of the urethra** is described with the prostate gland. It is about three centimeters (one and a quarter inches) in length, and is directed downward and a little forward, being slightly curved, with the concavity upward. It is the widest and most dilatable portion of the urethra, and contains in its posterior wall, or floor, the orifices of the sinus pocularis (*prostatic utricle*), ejaculatory ducts, and prostatic ducts, and a ridge in the median line—the verumontanum (*urethral crest*).

The **membranous urethra** extends from the apex of the prostate gland to the superior surface of the bulb of the corpus spongiosum (*urethral bulb*). It is the narrowest, shortest, and least dilatable portion of the urethra, and being fixed by its passage through the two layers of the triangular ligament (*urogenital diaphragm*), it is also the least movable portion.

It is directed downward and forward, and measures from one and one-fourth to two centimeters (one half to three-fourths of an inch) in length, its upper anterior wall being slightly the longer because of the convergence of the two layers of the triangular ligament (*urogenital diaphragm*) as they pass downward and

backward. The greater part of it is situated between the two layers of this ligament, is surrounded by the compressor urethræ (*sphincter urethræ*) muscle and is separated from the subpubic (*arcuate pubic*) ligament by an interval of about two and a half centimeters (one inch) and by the anterior part of the compressor urethræ (*sphincter urethræ*) muscle and a plexus of veins. Posterolaterally, it is in relation with Cowper's (*bulbo-urethral*) glands. Its wall contains some non-striated muscle fibers continuous with those of the prostate.

In uncomplicated *rupture of the membranous urethra* the urine passes into the deep perineal interspace. The density and attachments of the superficial layer of the triangular ligament (*fascia inferior of the urogenital diaphragm*) prevent the extravasated urine from escaping superficially at the perineum proper; it may burrow backward along the levator ani to the ischio-rectal fossa or upward into the pelvis, and cause pelvic cellulitis.

The **spongy urethra,** or **cavernous portion,** is the longest of the three divisions, being about fourteen centimeters (five and a half inches) in length. Like the body in which it lies, it has a posterior and an anterior expansion; the former, the *bulbous portion,* about two or three centimeters (three-fourths to one and a quarter inches) in length, is within the bulb; the latter, the *fossa navicularis,* one to two centimeters (one-half to three-fourths of an inch) long, is within the glans penis.

When there is a tight stricture of the spongy portion of the urethra and ulceration of the mucous membrane behind the stricture, forcible micturition may rupture the urethra. If this accident occurs, the urine escapes into the erectile tissue, and the resulting inflammation may be so active as to cause gangrene of the glans and of the corpus spongiosum (*corpus cavernosus urethræ*).

The **external urinary meatus,** a vertical slit at the apex of the glans, is the external orifice of the urethra, and is narrower and less dilatable than any part of the canal; hence, an instrument which will pass the external meatus will also pass through a normal urethra. To permit the passage of larger sized bougies it is sometimes necessary to enlarge the meatus by an incision downward toward the frenulum of the prepuce.

The **narrowest points of the urethra** are the external urinary meatus, and where the membranous portion passes through the superficial layer of the triangular ligament (*fascia inferior of the urogenital diaphragm*). Just behind these points a calculus may lodge in the urethra. The **widest points** are the fossa navicularis, the bulbous portion, and the center of the prostatic portion.

In the quiescent state the walls of the urethra are always in contact. The coaptation of the urethral walls at the external meatus and at the fossa navicularis is vertical; at the upper end of the navicular fossa it is like an inverted ⊥; in the remainder of the spongy (*cavernous*) portion and in the membranous portion,

it is transverse or stellate. In the prostatic portion it is like an inverted ∩ on account of the projection of the verumontanum (*urethral crest*).

In **passing urethral bougies** or stiff catheters through the pendulous portion of the male urethra the canal accommodates itself to the curve of the instrument, but in passing through the portion posterior to the angle of the penis, which is almost immovable, the instrument must follow the direction of the urethra. In introducing a bougie the patient must be in the dorsal recumbent position, and the penis be held vertically upward to obliterate the angle of the organ. The instrument is held parallel with, and close to the crease of the groin and is passed into the urethra until the fixed portion of the canal is entered. Then the instrument is brought to the median plane of the body, and while being retained in that plane is depressed between the legs. The advancing beak of the instrument must follow the curve of the canal as soon as it reaches the fixed portion of the urethra; this is especially true in the bulbous and membranous portions. Difficulty in passing instruments is frequently encountered where the urethra passes through the superficial layer of the triangular ligament (*fascia inferior of the urogenital diaphragm*). Here the urethra is immovable and the broader bulbous portion suddenly narrows at its junction with the membranous portion at the superior surface of the bulb. This difficulty can be overcome if the beak of the instrument is made to follow the roof of the canal. When strictures are present, false passages formed in introducing these instruments are usually just superficial to the superficial layer of the triangular ligament (*fascia inferior of the urogenital diaphragm*) at the bulbo-membranous junction.

Rupture of the urethra may be produced by the body falling on the perineum astride some hard substance, thus crushing the wall of the canal against the pubic orch. The bulbous and membranous portions are more commonly involved, urine being extravasated into one or both of the perineal interspaces.

The **mucous membrane of the urethra** contains numerous simple follicular invaginations, called *glands of Littré* (*urethral glands*), or *lacunæ*. One lacuna, situated in the dorsal wall of the urethra, two and a half centimeters (one inch) from the external meatus, larger than the others, is termed the *lacuna magna*, and may arrest the point of a small instrument passed into the urethra. The orifices of the ducts of Cowper's (*bulbo-urethral*) glands are in the floor of the bulbous portion of the urethra about two and one-half centimeters (one inch) anterior to the superficial layer of the triangular ligament (*fascia inferior of the urogenital diaphragm*).

The **Diseases of the Penis and Urethra.**—The urethra and penis are subject to numerous diseases, all of which are accompanied by more or less morbid worry incidental to disease of the genital apparatus.

Venereal warts are frequently found upon the inner layer of the prepuce close to the corona, often resembling a cock's comb in form.

Chancres are generally located upon the margin or inner surface of the prepuce or the corona glandis, where they are sometimes unnoticed.

Chancroids are similarly situated, but tend to spread rapidly, sometimes forming wide, irregular areas of ulceration which may destroy much of the prepuce and the glans. They are then said to be phagedenic. These ulcers occasionally cause intense suffering and permanent deformity of the organ.

Gonorrhea is a specific urethritis accompanied by a profuse purulent discharge. The mucous membrane and submucous tissue of the urethra are swollen and infiltrated and, being less elastic than normally, rupture of the submucous tissue is apt to occur during erection of the penis. The cicatricial tissue which develops contracts subsequently and forms a stricture. If the inflammation is sufficiently active, small areas of the mucous membrane may ulcerate, eventually leaving a contracting scar and stricture which narrows the caliber of the canal. The inflammatory thickening and cicatricial contraction may be so great as to cause a permanent narrowing, thus obstructing the flow of urine and causing a damming-back into the bladder, the ureters, and the renal pelves. The inflammation may extend into the bladder, causing cystitis, or into the prostatic ducts, giving rise to prostatitis; or it may invade the ejaculatory ducts to the seminal vesicles, causing vesiculitis; or from the ejaculatory ducts it may pass along one or both vasa deferentia (*ductus deferentes*) to the epididymis and testicle, causing acute epididymitis and, less frequently, an acute orchitis.

Chordee is a painful incident of gonorrhea, in which erection of the corpora cavernosa penis makes traction upon the underlying tender, swollen, and inflamed spongy body (*corpus cavernosum urethræ*) which is at the time less capable of elongation than normally, because of infiltration with inflammatory exudate which decreases its elasticity. It therefore is submitted to great tension, and checks elongation of the corpora cavernosa, which become bowed, occupying the relation to the spongy body (*corpus cavernosum urethræ*) of a bow to its string. This condition also endangers the integrity of the mucous lining and submucous tissue of the urethra which may rupture and cause hemorrhage and additional inflammatory action and exudation.

Stricture consists of a narrowing of the caliber of part of the urethral canal, and may be *spasmodic* or *organic*. *Spasmodic stricture* is chiefly due to spasm of the compressor urethræ (*sphincter urethræ*) muscle, and therefore occurs in the membranous urethra. It is frequently encountered in the passage of sounds, catheters, and bougies. It also may arise from internal causes, generally some form of nervous irritation. *Organic stricture* is due either to a contracting scar

of the urethral wall, or to plastic infiltration and thickening of the walls, with resulting narrowing of the canal. The force of the stream is diminished although the expulsive efforts are increased.

Phimosis is a common condition in which the preputial orifice is so narrowed that the glans penis cannot be uncovered.

In *circumcision*, the operation for the relief of phimosis, the prepuce is drawn well forward and a sufficient portion of the redundant prepuce removed, the glans penis being protected by a pair of circumcision forceps held between the apex of the glans and the line of incision. The mucous membrane is then divided from the preputial orifice to the neck of the penis and trimmed so that it can be accurately approximated to the remainder of the prepuce. The two surfaces are then sutured and a dressing applied.

Paraphimosis is the condition in which a narrow foreskin has been retracted behind the corona, with resulting edema of the prepuce and enlargement of the glans from interference with the return circulation. It requires prompt relief to prevent strangulation of the parts beyond it and necrosis of the prepuce. Gradual compression of the glans slowly forces the blood backward through the annular constriction at the neck of the penis, so that the prepuce can be drawn forward. Failing this, the prepuce may be divided longitudinally, or a series of incisions may be made in the edematous prepuce to allow escape of serum, lessen tension, and permit the prepuce to pass over the corona.

Epitheliomata and **other malignant growths** of the penis require amputation of that organ and careful dissection of the inguinal glands.

Amputation of the penis may be performed by the circular or the flap method. Hemorrhage is limited by tying a rubber ligature around the penis above the point of amputation. The skin incisions are then made down to the tunica albuginea. The corpus spongiosum (*corpus cavernosum urethræ*) is separated from the corpora cavernosa, and severed by cutting downward and forward. The urethra is dissected out and the corpora cavernosa are divided. The urethra is sutured to the skin in such manner that its extremity will always be free, or a small hole is made in the posterior flap, through which the urethra may be protruded and sutured to the edges of this opening.

The parts divided in amputation of the penis include: the skin, the dartos, the fascial sheath, the dorsal arteries, veins, and nerves, the corpora cavernosa with their surrounding tunica albuginea and contained arteries, and the corpus spongiosum (*corpus cavernosum urethræ*) with the urethra, the artery and the tunica albuginea of the corpus spongiosum (*corpus cavernosum urethræ*). In an amputation of the penis the skin must not be drawn too far forward lest the stump be left uncovered. In circumcision the penis may

be left uncovered if the skin is drawn too far over the glans before severing the prepuce.

Congenital malformations of the penis or of the urethra are quite common, although the more serious ones are not frequently seen. The external urinary meatus may be found on the side of the glans, near the pubis, or even in the groin. It may be circular, instead of a vertical slit, and may be so small that the urine cannot flow freely. The entire urethra may be absent, with exstrophy of the bladder; or the bladder may be entirely absent, the dilated ureters ending in the urethra. Congenital vesico-vaginal and vesico-rectal fistulæ are rare developmental anomalies. Different portions of the urethra may be too fully developed, presenting diverticula, sinuses, or pouches, which may be affected by catarrhal or ulcerative processes. The fossa navicularis may be so developed that it forms a considerable pouch or cul de sac. The verumontanum (*urethral crest*) is sometimes so much enlarged as to obstruct the urethra.

Hypospadias is a congenital defect in which there is faulty development of the floor of the urethra, the opening through which the urine escapes being situated at some point between the normal site of the meatus and the scrotum, or as far posterior as the perineum proper. Depending upon the position at which the urethra opens, the various forms of hypospadias are known as glandular, penile, and perineal. If the opening is situated in the perineum and associated with a cleft scrotum, the appearance will be that of a female, with the exception of the developed penis. Cases are on record where this condition at birth gave the impression that the infant was a female, the mistake not being discovered until the penis had had time fully to develop.

Epispadias is a congenital defect in which there is a deficiency in the roof, or upper wall, of the urethra. The opening in the urethra may be situated at any point between the normal site of the external urinary meatus and the pubis. In some cases the defect is associated with congenital absence of the pubic symphysis and with exstrophy of the bladder.

The operations for restoring the urethra in hypospadias and in epispadias are plastic in character and consist of inverting and sliding flaps of skin so as to make the urethra extend to the glans.

THE SCROTUM AND TESTICLE

The **scrotum** is the pouch which hangs from the anterior part of the perineum and the subpubic region at the root of the penis; it contains the testicles and their pedicles, the spermatic cords. The layers of tissue in the scrotum or investing the testicles are: the skin, the superficial fascia, and the superficial

part of the dartos muscle, the three forming a common investment for both testicles; the intercolumnar (*external spermatic*) fascia, the cremasteric fascia, the infundibuliform (*internal spermatic*) fascia, and the tunica vaginalis, these last four forming individual investments for each testicle.

The **integument of the scrotum,** formed chiefly by the prolongation downward of the integument of the abdomen and that of the perineum, is thin, translucent, and darker in color than that of the penis; it is provided with sebaceous glands and hairs, and is thrown into transverse folds (rugæ). The presence of the furrows between the folds on the surface of the integument offers favorable points for the deposit of cutaneous excretions and foreign material; the consequent irritation is at times one of the exciting factors in causing epithelioma of this part which, from the fact that it usually occurs in chimney-sweeps, is called "soot wart," or "chimney-sweeps' cancer." These furrows also favor retention of moisture, hence the liability of the scrotum to eczema and other cutaneous lesions. The integument of the scrotum is very elastic and permits of great distention, as is seen in large scrotal herniæ, tumors of the testicle, and hydrocele. The contractility of the dartos is marked in young individuals and is increased by cold or friction.

Along the median line of the scrotum is the *median raphe,* a dark ridge, continuous with the median raphe of the perineum, which shows the line of union of the two halves of the scrotum. The left half of the scrotum reaches to a lower level than the right because of the greater length of the left spermatic cord. When the scrotum is distended, the superficial veins are rendered prominent, and should be avoided when tapping a hydrocele.

Dissection.—The integument of the penis and the scrotum is reflected after making two incisions, one along the dorsum of the penis and the other along the under surface of that organ and along the raphe of the scrotum as far as the junction of the latter with the perineum; the dartos of the penis and scrotum will then be exposed.

The **dartos** is the superficial fascia of the scrotum and the penis. It contains no fat, and is a reddish, thin, fascial layer, containing yellow elastic tissue and bundles of unstriped muscle fibers. Its superficial portion is elastic areolar tissue; its deep portion is more membranous in character. It is continuous with the superficial fascia of the abdomen and the perineum. In the scrotum the muscle fibers generally run at right angles to the scrotal wrinkles which they cause. The dartos sends a median partition into the scrotum between the two testicles, which forms an incomplete *scrotal septum.*

The **external spermatic, or intercolumnar, fascia** is the fascia immediately beneath the dartos. It is the continuation of the intercolumnar fascia of the

external abdominal (*subcutaneous inguinal*) ring, carried downward over the testicle and the spermatic cord in the descent of the testicle.

The **middle spermatic, or cremasteric, fascia** contains longitudinal bundles of striated muscle fibers derived from the lower margin of the internal oblique during the descent of the testicle from the abdomen. It contracts, elevating the testicle, during active contraction of the abdominal muscles. Its contraction is also induced by gentle friction or stroking in the neighborhood of the groin and the upper medial side of the thigh, producing the *cremasteric reflex*, which is of value in diagnosis of certain diseases of the nervous system.

The **internal spermatic, or infundibuliform, fascia** is the innermost fascial tunic of the spermatic cord and the testicle, and is a process of the transversalis fascia of the abdominal wall, which was carried into the scrotum in the descent of the processus vaginalis and the testicle.

The **tunica vaginalis testis** is the serous sac in relation with the testicle, and is the unobliterated portion of the processus vaginalis of the peritoneum which descends into the scrotum just in advance of the testicle.

The **scrotal fasciæ** may be greatly distended by *serous effusions* in dropsical conditions due to disease of the heart, kidney, or liver, or other circulatory obstruction, sometimes causing such tumefaction of the scrotum as to hide the penis. The scrotum may be distended by urine extravasated into the superficial perineal interspace.

The scrotum is also capable of enormous distention by inguinal hernia, the gut passing downward in the tunica vaginalis of the cord and into the scrotum, which may become as large as a human head. In such cases the glans may be the only portion of the penis which is visible, and even that may be concealed in a depression, from which urine escapes.

Blood Supply.—The superficial and deep external pudendal, and the superficial perineal (*posterior scrotal*) branches of the internal pudendal arteries supply the skin and the dartos, while the cremasteric branch of the deep (*inferior*) epigastric artery supplies the cremasteric and the other two spermatic fasciæ.

Nerve Supply.—From the ilio-inguinal, genito-crural (*genito-femoral*), and the anterior superficial perineal (*posterior scrotal*) nerves, and the inferior pudendal (*long perineal*) branch of the small sciatic nerve (*posterior cutaneous nerve of the thigh*).

The **veins of the scrotum** empty into the internal saphenous (*great saphenous*) vein, the dorsal vein of the penis, and the internal pudendal vein. The scrotal *lymphatics* terminate in the inguinal glands situated near the medial part of Poupart's (*inguinal*) ligament, those of the testicle passing along the spermatic cord finally to enter the lumbar glands.

PLATE CCCCLXXII.

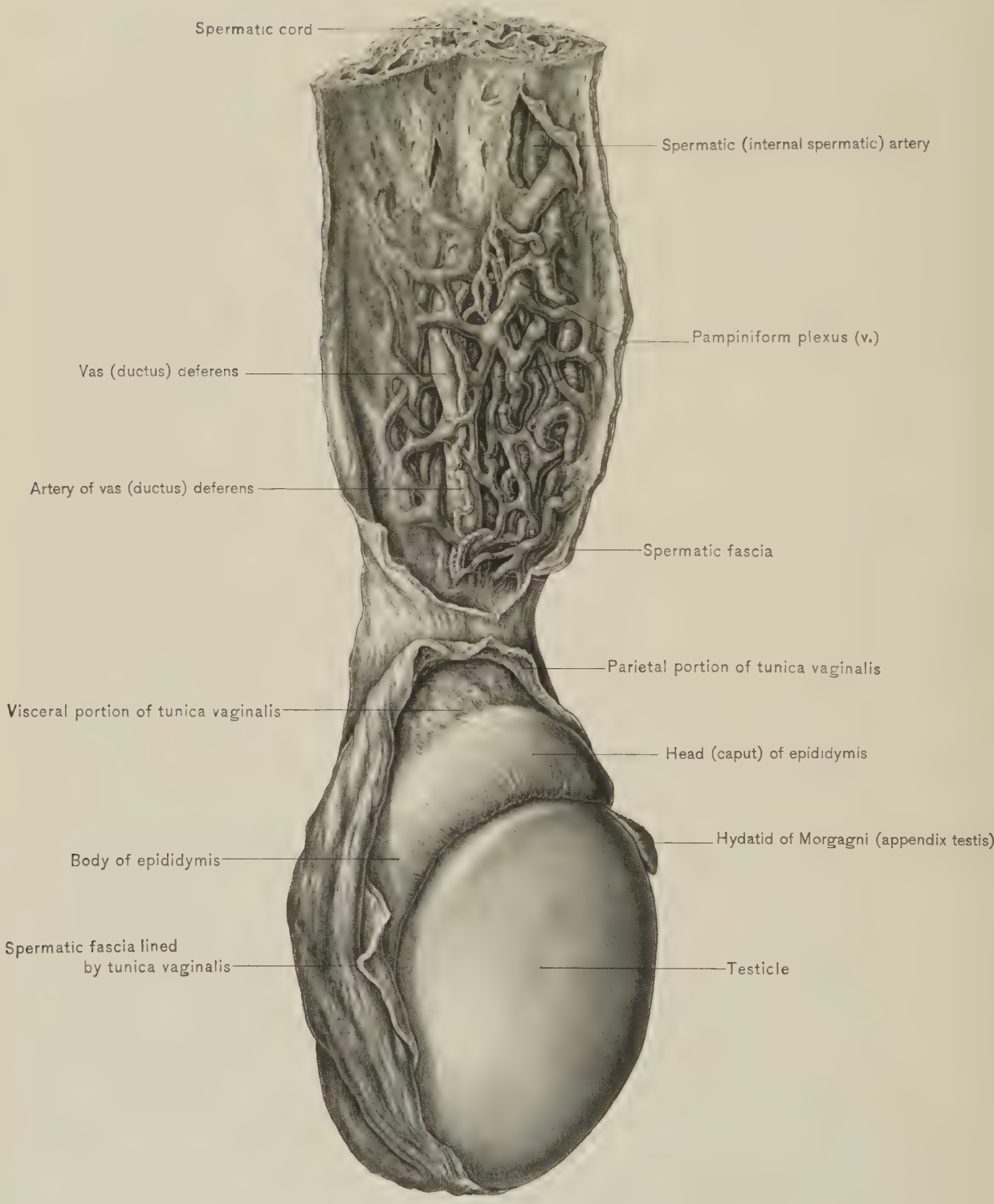

RIGHT TESTICLE AND SPERMATIC CORD—ANTERIOR VIEW.

PLATE CCCCLXXIII.

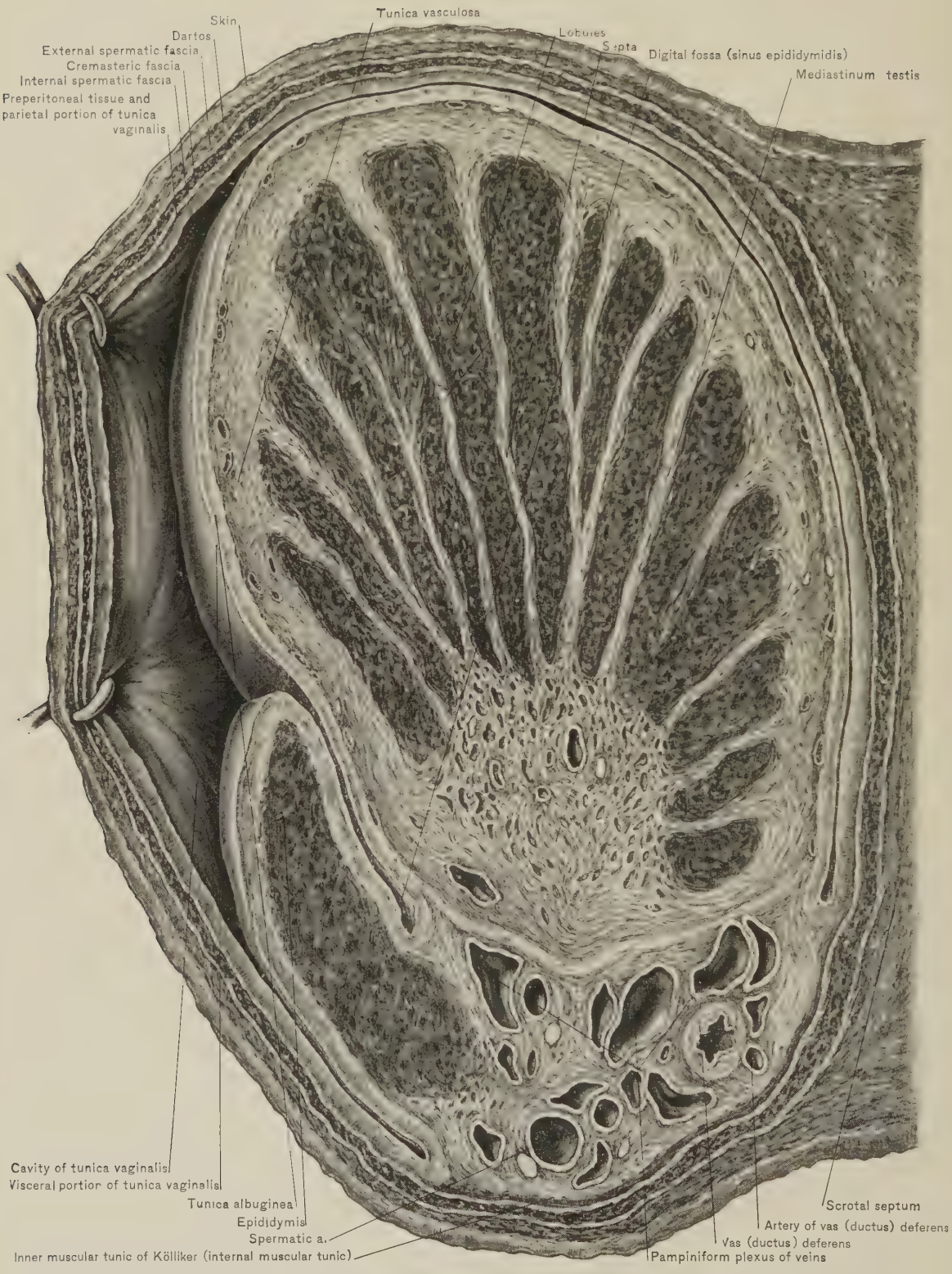

TRANSVERSE SECTION OF TESTICLE AND SCROTUM.

Elephantiasis scroti is a disease of the lymphatics, causing enormous enlargement of the scrotal tissues; Owen claims to have been authentically informed of a case in the West Indies that was computed to weigh two hundred pounds, "to which the patient had been anchored for many years and declined separation by surgical operation."

The **testicle** (Plates CCCCLXXII and CCCCLXXIII) is the homologue of the ovary, and is lodged in the scrotum, into which it descends from the abdomen through the inguinal canal just before or shortly after birth. Its connection with the internal abdominal (*abdominal inguinal*) ring is by means of the spermatic cord which is composed of the excretory duct, afferent and efferent vessels, nerves, and lymphatics of the testicle, the remains of the processus vaginalis, and the three spermatic fasciæ.

The testicle sometimes fails to descend in the usual manner. It may remain in the abdomen, or stop in the inguinal canal, or it may descend too far and be found in the perineum, or, descending through the femoral canal and saphenous opening (*fossa ovalis*), it may lodge between the superficial and deep fasciæ of the thigh. The descent of the testicle is described with the inguinal canal.

As the testicle hangs suspended by the spermatic cord in the scrotum its long axis is directed from below upward, forward, and lateralward. It is ovoid in shape, and a little flattened from side to side, measuring about four centimeters, (one and a half inches) in its long, or vertical, axis, about three centimeters, (one and a quarter inches) in its anteroposterior diameter, and a little less than two and one-half centimeters (one inch) in thickness. Its weight usually ranges from twenty to twenty-four grams (five to six drams). Its surface is formed by a smooth, white investment of dense fibrous tissue known as the tunica albuginea.

The **hilum of the testicle** is at the posterior border of the organ, and is the place where the blood vessels, the nerves, the lymphatics, and the seminiferous tubules leave or enter the testicle. In *inversion of the testicle* the contents of the spermatic cord have been twisted by rotation of the organ in its descent and the hilum is directed forward.

The **epididymis** is the rounded, elongated body with expanded ends which arches over the lateral side of the posterior border and the upper end of the testicle. It is composed of a main portion, or **body;** an upper, larger, expanded extremity, termed the **globus major,** or **head of the epididymis,** and a lower, smaller expansion, the **globus minor,** or **tail of the epididymis.**

The head of the epididymis surmounts the posterior part of the upper end of the testicle, and is closely joined thereto by the vasa efferentia (*ductuli efferentes*), the ducts of the testicle that enter the globus major. The body and tail of the

epididymis are loosely attached to the posterolateral aspect of the testicle by areolar tissue.

The **tunica vaginalis** is a serous sac which invests the testicle, and part of the head and body of the epididymis, and extends upward into the spermatic cord for one centimeter (three-eighths of an inch). It is the lower and unobliterated portion of the processus vaginalis of the peritoneum. It acts as a bursa for the protection of the testicle and the head of the epididymis. Its *parietal portion* lines the envelope of the testicle formed by the three spermatic fasciæ. The *visceral portion* covers the testicle except part of its posterior margin, the globus major, and the lateral side of the body of the epididymis, and is in relation with the contents of the lower one centimeter of the spermatic cord. A deep depression of this tunic exists between the testicle and the body of the epididymis, laterally and above, and is called the *digital fossa* (*sinus epididymis*). The visceral portion closely adheres to the dense white tunica albuginea of the testicle and gives it its glistening appearance.

Hydrocele of the tunica vaginalis is a distension of the tunica vaginalis with serum. A congenital hydrocele depends for its existence upon the presence of the tunica vaginalis of the cord which allows for a communication between the abdominal cavity and the tunica vaginalis testis. On account of the relation between the testicle and the tunica vaginalis the testicle lies in the lower posterior part of the swelling, and is not endangered in tapping the hydrocele; but in inversion of the testicle this organ lies in the lower anterior part of the swelling and might be injured. Therefore, it is advisable to locate the testicle, or to determine that it is not in the anterior portion of the swelling, before tapping a hydrocele.

Hydrocele of the cord is a collection of fluid in an unobliterated portion of the funicular process. As this closed sac is usually found in the inguinal canal, it is often mistaken for a hernia or an undescended testicle. But if the cord is drawn downward, the cyst is fixed and presents the characteristics of hydrocele elsewhere.

In the radical operation for hydrocele, sometimes practised by the author, a longitudinal incision is made over the tumescence, and the skin, the dartos, the external spermatic, or intercolumnar, fascia, the cremasteric fascia, the internal spermatic, or infundibuliform, fascia, and the parietal layer of the tunica vaginalis are divided. The parietal layer of the tunica vaginalis is then dissected out and removed, thus destroying the cavity of the tunica vaginalis, the site of the hydrocele.

The Jaboulay operation consists in splitting the parietal layer of the tunica vaginalis which forms the sac, turning it inside out, and folding it about the testicle and cord. It is stitched in this position so that the smooth endothelial lining

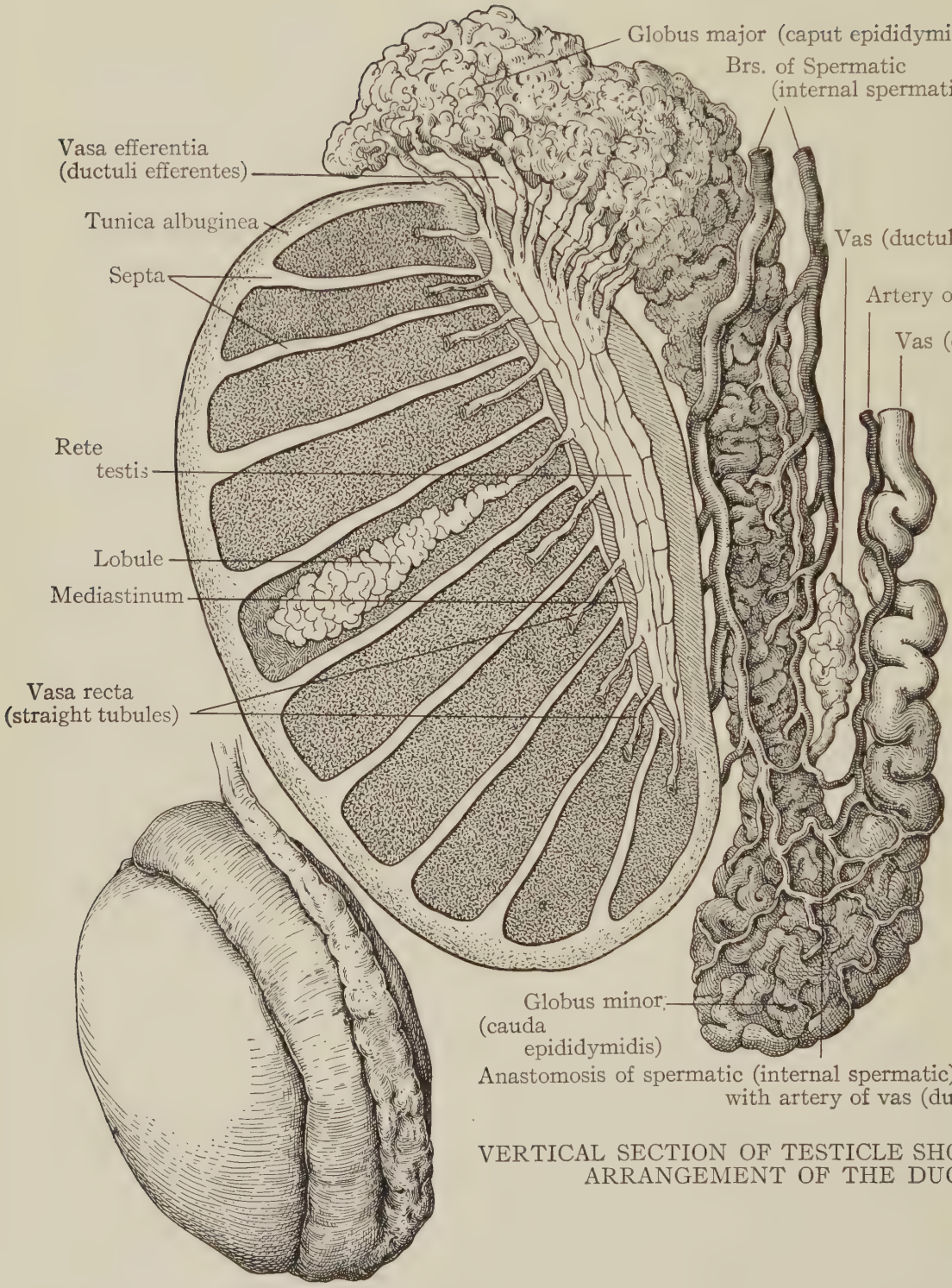

VERTICAL SECTION OF TESTICLE SHOWING TH ARRANGEMENT OF THE DUCTS

TESTICLE AND EPIDIDYMIS

will be brought in contact with the connective tissue of the internal spermatic, or infundibuliform, fascia to which it becomes adherent.

The Andrews bottle operation consists in dissecting out the hydrocele sac from its bed. At the extreme upper end of the funnel an incision is begun on the anterior border and continued downward for two centimeters (seven-eighths of an inch). The opening is enlarged by a little stretching. The sac is emptied and the testis pushed through the opening. The small buttonhole closely surrounds the cord.

Structure of the Testicle and Epididymis (Plate CCCCLXIV).—The testicle is invested by the *tunica albuginea*, which is a dense, firm, inelastic, fibrous, white structure, which forms the true outer coat of the testicle. The tunica albuginea is about one and one-half millimeters thick throughout most of its extent, being thickest at the posterior margin of the gland under the epididymis, where it is invaginated and forms the *mediastinum testis*. It sends off centripetally directed processes, called *trabeculæ*, which separate the interior of the testicle into compartments, within which lie the lobules of the testicle. The tunica albuginea is lined by the *tunica vasculosa*, which is chiefly composed of a plexus of blood-vessels. These lobules of the testicle are composed of the convoluted seminiferous tubules from the epithelium of which the spermatozoa are formed. The important internal secretion of the testis is formed, on the other hand, by the interstitial cells. These tubules end in straight tubules, *vasa recta*, in the back part of the testicle, where the apices of the lobules converge. The straight tubules inosculate in the form of a net-work at the back of the organ, forming the *rete testis*, from the upper part of which emerge a series of tubes, called *vasa efferentia* (*ductuli efferentes*); the tubules next become convoluted over the top of the testis, and are known as the *coni vasculosi*, or lobules of the epididymis; the tubules of the coni vasculosi (*lobules of the epididymis*) end in an arched collecting tubule surmounting them, called the *duct of the epididymis;* the entire mass of vasa efferentia (*ductuli efferentes*), coni vasculosi (*lobules of the epididymis*), and collecting tube forming the *globus major*, or *head of the epididymis*. The duct of the epididymis becomes much convoluted, is about four and six-tenths meters (fifteen feet) long, descends behind the testis, and forms the *body and tail of the epididymis*. Behind the lower end of the testis it doubles upon itself in the globus minor, and becomes the vas, or ductus deferens, which ascends back of the epididymis to become part of the spermatic cord. From the tube, where it forms the globus minor, and quite near the beginning of the vas (*ductus*) deferens, are given off one or more offshoots, ending in blind extremities, called *vasa aberrantia* (*ductuli aberrantes*).

The testicle is not fully developed until puberty, and it retains its functional activity well into advanced life.

Blood Supply.—The blood supply of the testicle is derived from the spermatic (*internal spermatic*) artery. Its veins empty into the pampiniform plexus, the veins of which unite to form the spermatic vein.

Nerve Supply.—The nerve supply of the testicles is derived from the spermatic plexus, which is indirectly derived from the solar (*celiac*) plexus and from the hypogastric plexus, through the sympathetic nerves which follow the internal spermatic artery.

Acute epididymitis is usually a complication of gonorrhea, while **chronic epididymitis** is very often evidence of some constitutional disease, such as tuberculosis. The direct connection from the urethra to the epididymis explains the localization of gonorrheal infection in this area.

Acute orchitis, or inflammation of the testicle, is signalized by a dull, sickening pain, produced by pressure of the nerves against the inelastic tunica albuginea which retards swelling of the organ.

Chronic orchitis is presumptive evidence of some constitutional disease, generally either syphilis or tuberculosis. Syphilis more frequently affects the testis first, and the epididymis later, while the reverse is true in tuberculous disease.

Fungus is the term applied to a papillomatous growth of granulations projecting through a perforation in the tunica albuginea in suppuration of the testicle. It takes this form because of the unyielding character of the tunica albuginea. This is also known as a hernia testis and is analgous to hernia cerebri.

Atrophy of the testicle is natural in old age, but may occur prematurely as the result of disease. Senile atrophy is produced by fatty degeneration of the seminiferous tubules. Atrophy often occurs after varicocele operations and after ligation of the vas (*ductus*) deferens.

Dermoid cysts sometimes develop in the testicle. They are developmental curiosities, and should be removed.

Monorchism, or absence of one testicle, occasionally occurs. **Anorchism,** or absence of both testicles, is exceedingly rare and the diagnosis should not be ventured unless a careful search is made for bilateral **non-descent** of the testes. The testicle may be arrested in its descent anywhere from the kidney to the scrotum. It is frequently arrested on the abdominal or inguinal side of the internal (*abdominal inguinal*) ring. This is known as *cryptorchism.* The testicle may leave its normal route and be found either at the root of the penis under the skin of the abdominal wall, or in the perineum at the side of the central raphe, or in Scarpa's (*femoral*) triangle where it simulates a femoral hernia in position. The perineal type is the one most commonly seen.

Torsion of the testicle, including the cord, has been frequently reported. It more often affects imperfectly descended glands but is not confined to these. The cause most likely resides in a congenital defect, since a testicle which has descended properly and possesses a normal mesorchium cannot be twisted. In severe cases the entire testicle becomes gangrenous.

Castration is the operation of removal of the testicles. It is a simple procedure, very ancient, and was formerly almost as commonly practised on men in the East as it is upon the lower animals in the Occident. It was a notable practice among the Mohammedans, who castrated their male slaves before placing them as servants in the harems.

Castration is performed by making an incision over the testicle, usually in a longitudinal direction. The skin, dartos, external spermatic fascia, cremasteric fascia, internal spermatic fascia, and the parietal layer of the tunica vaginalis are divided and the testicle brought into view, care being taken not to injure the scrotal septum. The testicle is drawn well downward, and the finger passed upward along the spermatic cord. The spermatic cord is freed from its surrounding structures, and its constituent vessels are ligated separately or *en masse.* These vessels are: the cremasteric (*external spermatic*) artery which lies in the fascial investment of the cord; the spermatic (*internal spermatic*) artery, in front of the vas (*ductus*) deferens, surrounded by the spermatic, or pampiniform, plexus of veins; the artery of the vas (*ductus*) deferens, close to the vas (*ductus*) deferens; some small veins, and the spermatic duct. The proximal part of the spermatic cord is anchored in the wound and the cord is divided; the testicle is then removed and the wound closed. In castration for malignant disease the operation may have to be much more extensive.

Excision of the testicles is sometimes followed by atrophy of the prostate, a fact established for many years, and which formerly was advocated as a cure for enlarged prostate, but experience proved that little was gained by the operation.

Sterility of the male results from obstruction of the ejaculatory duct, the vas (*ductus*) deferens, or the duct of the epididymis, or from inability of the testis to secrete spermatozoa, a condition which may be temporary or permanent and is physiologic as a senile change after the seventieth year.

Spermatorrhea is a term generally used to designate a passive flow of semen without sexual excitement and without orgasm. It is due to a weakened condition of the ejaculatory apparatus, so that the semen is not retained in the seminal vesicles, but is permitted to flow into the urethra as fast as it is formed. Excessive venery and abnormal sexual gratification are its most frequent causes, although it may result from organic defects of various kinds.

The **spermatic cord** is the pedicle by which the testicle is suspended in the scrotum; it extends from the upper end of the testis to the internal abdominal (*abdominal inguinal*) ring. It is composed of: (1) the vas (*ductus*) deferens, which can be distinctly felt as a firm and rounded cord back of the vessels and nerves; (2) the spermatic (*internal spermatic*) artery (a branch of the aorta), the artery of the vas (*ductus*) deferens (a branch of the superior vesical), and the cremasteric (*external spermatic*) artery (a branch of the deep (*inferior*) epigastric artery); (3) the spermatic veins surrounding the artery and forming the pampiniform plexus; (4) the lymphatics which accompany the vessels and empty into the lumbar glands; (5) the sympathetic nerves, which are branches of the renal, the aortic, and the hypogastric plexuses; (6) the remains of the processus vaginalis in the form of a small fibrous cord; (7) the internal cremaster muscle of Henle, consisting of longitudinal fibers of pale muscle tissue; (8) fat and connective tissue derived from and continuous with the subserous areolar tissue. The constituents of the spermatic cord diverge as they are followed internally from the internal abdominal (*abdominal inguinal*) ring. The spermatic cord passes through the inguinal canal to reach the scrotum and is sometimes abnormally followed by an indirect inguinal hernia.

Varicocele is an enlarged or varicose condition of the spermatic veins or pampiniform plexus. The fact that these veins are but poorly supported by the lax tissues of the scrotum, and the slight degree of compression to which they are subjected in the inguinal canal, help to explain the frequency of varicosity of these veins. This condition may cause atrophy of the testicle. The varicose plexus of veins eventually, or even at the beginning, may sag at the bottom of the scrotum upon the affected side (most often the left), so that on inspection and palpation the scrotum resembles a bag of worms. The condition is not dangerous except that it often begets morbid fears on the part of the patient, usually the result of suggestion. A large varicocele, associated with relaxation of the scrotum, causes a dull, heavy dragging sensation in the external genitals. In the old radical operation for varicocele a longitudinal incision is made over the mass of veins; the skin, the dartos, the external spermatic fascia, the cremasteric fascia, and the internal spermatic fascia are divided and the mass of veins is separated from the spermatic duct and the spermatic (*internal spermatic*) artery. Two ligatures, preferably of catgut, are then thrown around the mass of veins and the spermatic (*internal spermatic*) artery and securely tied, the ligatures being placed about two and a half centimeters (one inch) apart. The intervening portions of the veins and the spermatic (*internal spermatic*) artery are removed and the ends of the ligatures tied together. The wound is closed in the ordinary manner. In the Bevan operation the veins are exposed through a two and a half centimeter

PLATE CCCCLXXV.

SURFACE OF FEMALE PERINEUM.

(one inch) transverse incision just below the external (*subcutaneous inguinal*) ring. The dilated veins of the cord are separated from the vas (*ductus*) and its vessels. The spermatic (*internal spermatic*) artery should be saved if possible. Six centimeters (two and one-half inches) of the veins are excised and the ends ligated and tied as above.

The **hydatids of Morgagni** (**appendices testis**) are two small bodies attached to the upper part of the testicle and the globus major. They each measure from one-half to one centimeter (one-fourth to three-eighths of an inch) in length and contain clear fluid. One is sessile and the other is pedunculated. The former, appendix testis, is the remnant of the upper end of the embryonic structure called Müller's duct. The latter, appendix epididymis, arises through secondary pinching off of the vasa efferentia (*ductuli efferentes*).

The **paradidymis, or organ of Giraldés,** is an irregular yellowish patch, about one centimeter (three-eighths of an inch) in breadth, situated in the lower part of the spermatic cord above the head of the epididymis, and covered by the visceral portion of the tunica vaginalis. It is composed of blind tubules, and is partly the remnant of part of the Wolffian body and partly vasa efferentia (*ductuli efferentes*). This is rarely seen in adults. The cysts are among those classed as *encysted hydrocele of the epididymis*, or *spermatoceles*, which may also arise from the seminiferous tubules and their vasa aberrantia (*ductuli aberrantes*). As a rule, such cysts contain spermatozoa, but these may be absent.

FEMALE PERINEUM (Plate CCCCLXXV)

Dissection.—The subject is placed upon the table in the same manner and position as described in the dissection of the male perineum.

Definition.—The perineum includes all those structures which fill the outlet of the pelvis.

Boundaries.—This space, as in the male, is quadrangular, bounded superficially in front, by the upper border of the os pubis, at the sides and behind, by the thighs and buttocks. The deep boundaries are the same as those of the male.

This general space is subdivided into two triangles by a line drawn transversely from one tuberosity of the ischium to the other. The posterior is called the **anal triangle**; the anterior, the **urethro-vaginal triangle,** or the **perineum proper.** The anatomy of the anal triangle, including the ischio-rectal fossæ, is the same as in the male.

The **mons veneris** (**mons pubis**) is a cushion of fat and areolar tissue covered with rather firmly adherent integument and hair; it rests upon the external surface of the symphysis and the bodies of the pubes. The area covered

by hair ends abruptly above, at about the upper border of the mons veneris (*mons pubis*). In the male the hair line is usually prolonged upward in the median line as far as the umbilicus. The mons veneris (*mons pubis*) divides at its lower part into the two labia majora, the point of separation constituting the **anterior commissure of the vulva.** The **labia majora** are prolonged downward and around the pudendal, or urogenital, cleft to unite below at the **posterior commissure of the vulva.** The labia majora, which, like the mons veneris (*mons pubis*), are largely composed of fatty tissue covered with integument and hair, contain some smooth muscle fibers, vessels, and nerves. They are the female representatives of the scrotum. The medial surfaces of the labia majora are covered by delicate skin, which contains large sebaceous follicles.

The fatty tissue of the labia majora may develop excessively, thereby forming enormous lipomata. The labia majora, like the scrotum in the male, may be affected by elephantiasis.

The **labia minora,** or **nymphae** (Plate CCCCLV), are two small cutaneous folds placed medial to the labia majora. They form the prepuce and the frenulum of the clitoris, and extend downward and lateralward from the sides and dorsum of this organ for about four centimeters (one and a half inches), to become continuous with the skin of the labia majora and the mucous membrane of the vagina. They may be concealed by, or project from the labia majora. The labia minora are covered with delicate integument; they contain sebaceous, but no mucous glands, and therefore are cutaneous, rather than mucous folds. Venous spaces and smooth muscle fibers in their interior produce an appearance similar to that of erectile tissue.

The **pudendal,** or **urogenital, cleft** separates the labia of the two sides and extends anteroposteriorly. In the erect position of the body it is almost horizontal. It corresponds to the raphe of the scrotum in the male.

The **clitoris,** about four centimeters (one and a half inches) long, is situated at the upper part of the urogenital cleft and, with the exception of its glans, is hidden by the labia minora, which form the *prepuce* and *frenulum* of the clitoris. Its structure is similar to that of the penis, differing from the latter in having a smaller corpus spongiosum, which does not transmit the urethra, and is cleft posteriorly where it forms the bulbs of the vestibule. It is provided with a *suspensory ligament,* and consists of a *glans,* a *body,* and two *crura.* The *prepuce of the clitoris* is continuous with the labia minora. Despite the small size of the clitoris as compared with the penis, it has proportionately a much greater nerve supply.

The **vestibule** is the triangular interval at the anterior part of the floor of the urogenital cleft, the apex of which is at the clitoris. Its lateral boundaries

are formed by the labia minora, and its base by the upper margin of the orifice of the vagina.

The **external urinary meatus,** or **external orifice of the urethra,** is immediately above the center of the base of the vestibule. It is about two and one-half centimeters (one inch) below the clitoris, and just above the orifice of the vagina. The mucous membrane projects at its orifice and forms a papilla which can usually be felt.

The **orifice of the vagina** is situated immediately below the vestibule. It may be partly closed by a fold of mucous membrane, the *hymen,* and when this has been ruptured its remnants, the *carunculæ myrtiformes* (*carunculæ hymineales*)—small projections of mucous membrane—are found around the vaginal orifice. The hymen is variable in form. It may be semilunar, annular, cribriform, or fimbriated. In imperforate hymen the menstrual fluid is retained in the uterus and the vagina.

The **ducts of the vulvo-vaginal,** or **Bartholin's, glands** (**greater vestibular glands**), are situated, one at each side of the vaginal orifice toward its posterior portion, between the hymen and the labia minora.

The **fourchette** (**frenulum labiorum pudendi**) is a small, transverse, crescentic fold of skin connecting the labia majora posteriorly, and is situated just anterior to the posterior commissure of the vulva. It is usually ruptured in the first labor.

The **fossa navicularis** is the depression between the fourchette (*frenulum labiorum pudendi*) and the vaginal orifice.

The **perineal body** is the cuneiform mass of fibro-elastic and muscle tissue, located between the lower part of the rectum and the vagina. The edge of the wedge is directed upward and the base, which measures about two and a half centimeters (one inch), is directed toward the skin. It is composed of the central tendon of the perineum or central part of the base of the triangular ligament (*urogenital diaphragm*), and fibers of the sphincter vaginæ (*bulbo-cavernosus*), transverse perineal, external sphincter ani, levator ani, and deep transverse perineal muscles.

Rectal Examination.—The index-finger introduced into the rectum will recognize the resistance caused by the external and internal sphincter ani muscles; beyond these can be felt the external os uteri, the cervix and the body of the uterus, and, lastly, the appendages of the uterus, namely, the round ligaments, the Fallopian (*uterine*) tubes and the ovaries. This examination should always be made when dealing with obscure affections in the pelvis of the female. The vagina is the avenue through which digital exploration of the female pelvis is most commonly made, but to make the examination more complete the possibilities of the rectal avenue should not be forgotten. This holds true also with

regard to certain diseases in the iliac and hypogastric regions of the abdomen. It is the method of choice when attempting to examine the pelvic organs of a virgin.

Vaginal Examination.—When the index-finger is introduced into the vagina, the urethra is felt as a cord extending above the anterior vaginal wall from the vestibule to the neck of the bladder; the base of the bladder and anterior surface of the cervix uteri are palpated at the anterior fornix of the vagina; then the cervix and the external os uteri are felt. The body of the uterus, the ovaries, and the Fallopian (*uterine*) tubes can be palpated at the side of the cervix. The ovaries are more readily palpated than the Fallopian (*uterine*) tubes. Behind the posterior wall of the vagina the rectum can be easily recognized, and the terminal part of the sigmoid flexure can be made out through the posterior fornix of the vagina, especially if those parts of the intestine contain feces. At the posterior fornix of the vagina the body and the fundus of a retroverted uterus, tumors of the ovaries, distended Fallopian (*uterine*) tubes, collections of fluid, and the most tender point in a terminal appendicitis with the appendix directed into the pelvis may be palpated.

The **urethro-vaginal triangle** embraces the external genitalia. The **vulva,** or **pudendum,** includes the mons veneris (*mons pubis*), the labia majora, the labia minora, the clitoris, the vestibule, the external urinary meatus, the orifice of the vagina, upon each side of which are the orifices of the glands of Bartholin (*greater vestibular glands*), the fourchette (*frenulum labiorum pudendi*), the fossa navicularis, the posterior commissure, and the urogenital cleft.

In *bimanual examination* the uterus can be engaged between the finger in the vagina and the fingers of the other hand on the lower part of the abdomen, provided the bladder is approximately empty and the uterus is in its normal position. If a *speculum* is introduced into the vagina, the cervix uteri can be observed. In a virgin uterus the external os uteri is round, while in a parous woman it is transversely elliptical. The anterior lip of the cervix is shorter and thicker than the posterior lip.

Dissection.—In making a dissection of this region the vagina and rectum should be partly distended with oakum or any suitable material, and the adjacent surfaces of the labia majora and the margins of the anus approximated by stitches. The skin is removed in one flap from behind forward, and the superficial fascia from before backward, as in dissecting the male perineum. These tissues are supplied with vessels and nerves from the same sources as in the male.

The **superficial fascia** consists of a superficial and a deep layer. The superficial layer is much richer in fat than in the male, and is continuous with the superficial fascia covering the anal triangle and with the same layer of the super-

PLATE CCCCLXXVI.

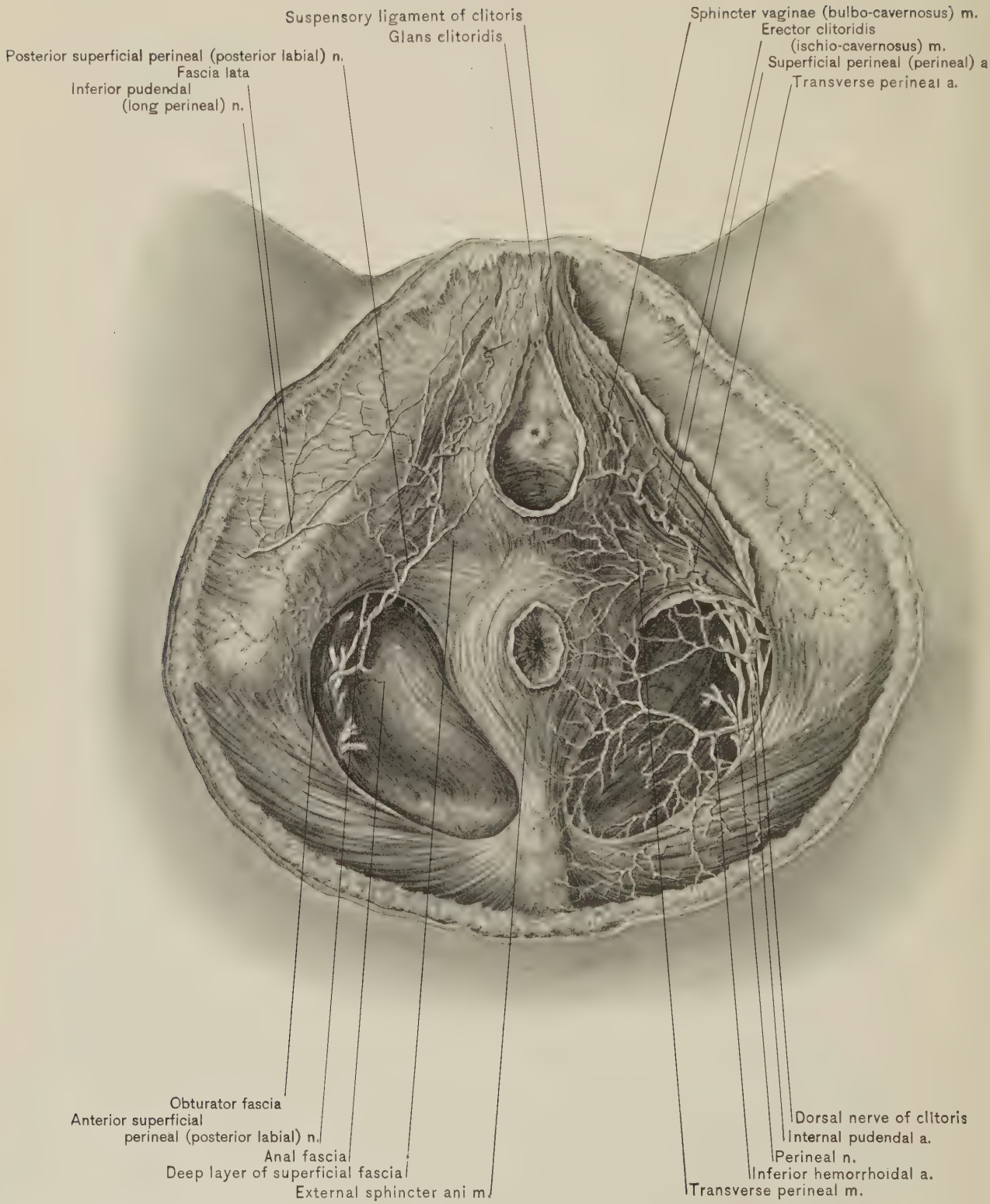

SUPERFICIAL PERINEAL INTERSPACE OF FEMALE PERINEUM.

PLATE CCCCLXXVII.

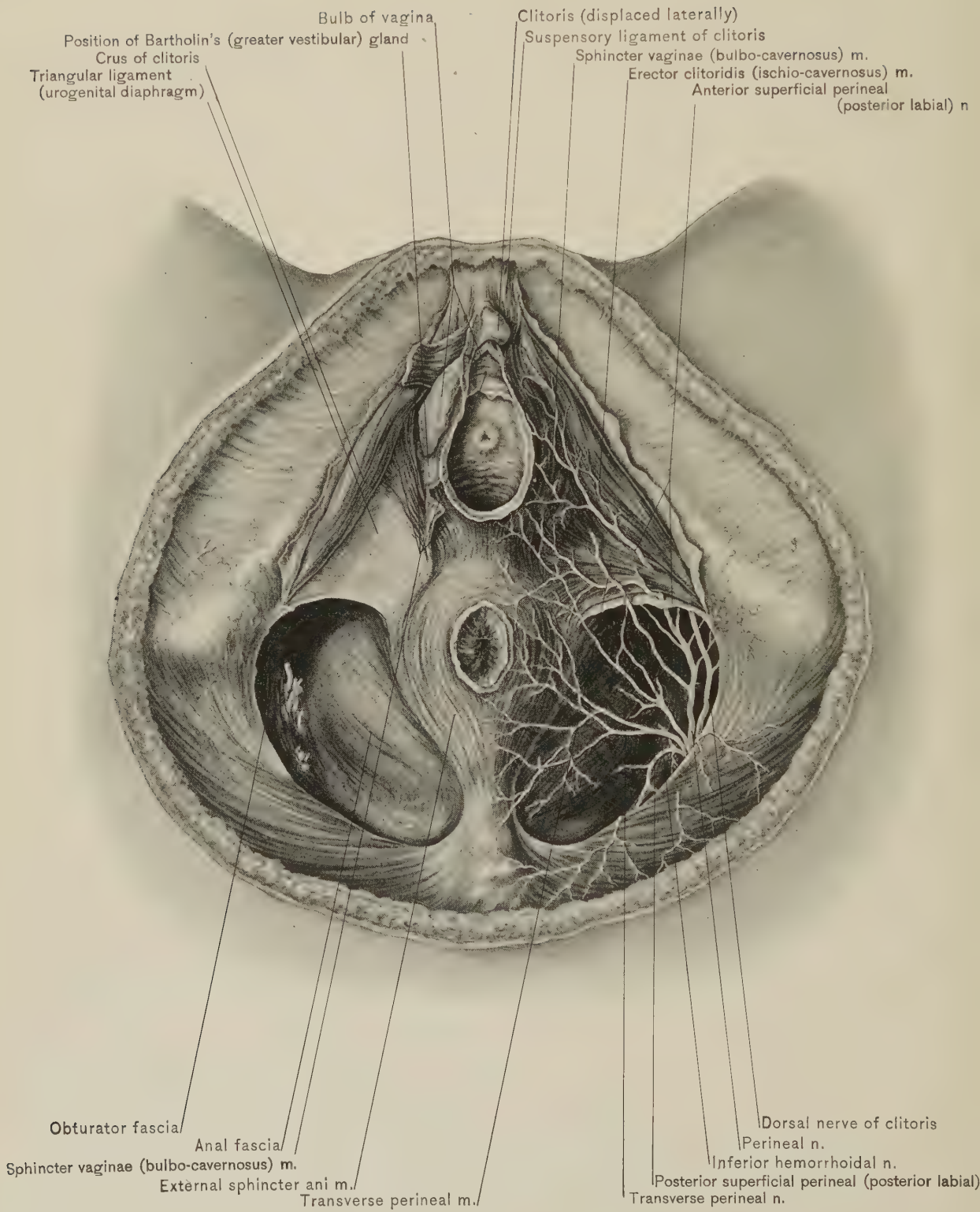

TRIANGULAR LIGAMENT (UROGENITAL DIAPHRAGM) AND SUPERFICIAL PERINEAL INTERSPACE OF FEMALE.

ficial fascia of the thighs and the abdomen. As in the male, the deep layer is found only in the perineum proper, and its attachments are similar to those of Colles' fascia (*membranous layer of superficial fascia*). It is not so strong as in the male, and medially it is continuous with the **dartos of the labia majora.** The unstriped muscle fibers forming the dartos are not so abundant as in the male. Medially, the dartos is divided by the urogenital cleft, and is continuous with the fibrous coat of the vagina.

The superficial fascia of the perineum bulges and is thickest at each side of the urogenital cleft, forming the labia majora. This mass of fat is widest and fullest at the side of the orifice of the vagina and narrowest at the side of the vestibule. The mass is the *pudendal sac*, which is the homologue of the sac formed by the dartos of the scrotum. It contains fat, overlies the site of the bulb of the vagina, and marks the position at which a pudendal hernia appears. The narrow anterior end of the sac is the neck. At this end it is joined by the frayed end of the round ligament of the uterus and the suspensory ligament of the clitoris.

The **superficial perineal interspace** (Plates CCCCLXXVI and CCCCLXXVII) of the female perineum is situated between the deep layer of the superficial fascia and the interior layer of the triangular ligament (*urogenital diaphragm*). There are two such spaces—one upon each side of the urogenital cleft. In the male, on the other hand, there is one superficial perineal interspace, partly subdivided by an incomplete vertical septum. A collection of fluid in one of the superficial perineal interspaces will distend the labium majus and thence pass upward to the anterior abdominal wall, as in the male. The *contents* of the superficial perineal interspace are: the sphincter vaginæ (*bulbo-cavernosus*), the transversus perinei, and erector clitoridis (*ischio-cavernosus*) muscles, the bulb of the vagina, the superficial perineal (*perineal*) vessels, the anterior superficial perineal (*posterior labial*) nerve, the transverse perineal vessels and nerve, the dorsal artery and vein, and the nerve of the clitoris. In the female perineum, as in the male, there is a muscular triangle on each side formed by the sphincter vaginæ (*bulbo-cavernosus*), erector clitoridis (*ischio-cavernosus*), and transversus perinei muscles.

Dissection.—Reflect the deep layer of the superficial fascia mediolaterally to expose the structures situated in the superficial perineal interspace.

The **superficial perineal (perineal) artery,** larger in the female than in the male, is a branch of the internal pudendal. It pierces the deep layer of the superficial fascia at its junction with the base of the triangular ligament (*urogenital diaphragm*), enters the superficial perineal interspace, and passes between the erector clitoridis (*ischio-cavernosus*) and sphincter vaginæ (*bulbo-cavernosus*)

muscles, supplying the contiguous parts. It anastomoses with the external pudendal arteries, which are branches of the common femoral artery.

The corresponding veins accompany the artery and empty into the internal pudendal vein.

The **transverse perineal artery** is a branch of the superficial perineal (*perineal*) or of the internal pudendal, and passes transversely medialward under the transverse perineal muscle to the perineal body, anastomosing with the transverse perineal artery of the opposite side and with neighboring vessels.

Venæ comites accompany the artery and empty into the internal pudendal vein.

The **artery of the bulb of the vestibule** is a branch of the internal pudendal, corresponding to the artery of the bulb of the penis; it passes transversely medialward to terminate in the bulb.

The veins accompanying the artery empty into the internal pudendal vein.

The **superficial perineal (posterior labial) nerves** and the **inferior pudendal (long perineal) nerve** are similar, in origin and distribution, to the corresponding nerves in the male.

The **sphincter vaginæ (bulbo-cavernosus) muscle,** the homologue of the accelerator urinæ (*bulbo-cavernosus*) in the male, *arises* from the perineal body. It consists of three sets of fibers anterior, middle, and posterior. The anterior fibers join those of the opposite side upon the dorsum of the clitoris in an aponeurosis, a few fibers being inserted into the suspensory ligament of the clitoris; the middle fibers join those of the opposite side beneath the clitoris in an aponeurosis, which extends across the vestibule above the urethra; the posterior fibers are attached to the triangular ligament (*urogenital diaphragm*). Some of the most posterior fibers are inserted into the middle of the ischio-pubic ramus between the crus clitoridis and the triangular ligament (*urogenital diaphragm*).

Action.—To approximate the labia majora, thus closing the urogenital cleft, and to assist in erection of the clitoris.

The **superficial transverse perineal muscle** *arises* from the ramus of the ischium immediately in advance of the tuberosity and passes medialward and slightly backward, to be *inserted* into the perineal body, blending with the other superficial transverse perineal, the external sphincter ani, the sphincter vaginæ (*bulbo-cavernosus*), the deep transverse perineal and the levator ani muscles.

Action.—To fix the perineal body.

The **erector clitoridis (ischio-cavernosus) muscle,** the homologue of the erector penis (*ischio-cavernosus*) muscle, is in relation with the crus clitoridis, and its origin and insertion are similar to those of the erector penis (*ischio-cavernosus*) muscle.

Action.—Similar to that of the erector penis (*ischio-cavernosus*) muscle.

Blood and Nerve Supply.—The blood and nerve supply of the sphincter vaginæ (*bulbo-cavernosus*), the erector clitoridis (*ischio-cavernosus*), and the transverse perineal muscles are derived from the same sources as their homologues in the male.

Dissection.—Separate the contiguous borders of the sphincter vaginæ (*bulbo-cavernosus*)and the erector clitoridis (*ischio-cavernosus*) muscles, and displacing the superficial perineal (*perineal*) vessels and superficial perineal (*posterior labial*) nerves and the inferior pudendal (*long perineal*) nerves, expose a portion of the inferior layer of the triangular ligament (*urogenital diaphragm*). Now remove the sphincter vaginæ (*bulbo-cavernosus*), erector clitoridis (*ischio-cavernosus*), and the superficial transverse perineal muscles, reflect the sphincter vaginæ (*bulbo-cavernosus*) and the erector clitoridis (*ischio-cavernosus*) forward, and the superficial transverse perineal medialward. This dissection exposes the triangular ligament (*urogenital diaphragm*) and the bulbs of the vestibule and small elevations in the ligament produced by Bartholin's (*greater vestibular*) glands.

The **bulbs of the vestibule,** the homologues of the bulbs of the penis, are two small pyriform erectile bodies situated one upon each side of the vestibule, behind the labia minora, beneath the sphincter vaginæ (*bulbo-cavernosus*) muscles, and on the superficial surface of the inferior layer of the triangular ligament (*urogenital diaphragm*). They are about two and one-half centimeters (one inch) in length, and are composed of a plexus of veins communicating with the veins of the clitoris. Each bulb is surrounded by a fibrous capsule derived from the inferior layer of the triangular ligament (*urogenital diaphragm*). The narrow anterior extremities of the two bulbs unite at the lower part of the root of the clitoris and extend forward as the slender corpus spongiosum. Rupture of one of the bulbs of the vestibule, as the result of an injury, gives origin to a hematoma, known as a **pudendal hematocele;** it most frequently occurs in pregnant women.

Bartholin's (greater vestibular) glands are two compound, racemose glands which are the homologues of Cowper's (*bulbo-urethral*) glands in the male, but differ from the latter in size and situation. Bartholin's (*greater vestibular*) glands are placed on the deep surface of the inferior layer of the triangular ligament (*urogenital diaphragm*), and are invested by a capsule formed by fibers from the deep surface of the ligament, whereas Cowper's (*bulbo-urethral*) glands lie in the substance of the compressor urethræ (*sphincter urethræ*) muscle. They are larger than Cowper's (*bulbo-urethral*) glands, and are placed on each side of the orifice of the vagina behind the bulbus vestibuli and about the middle

of the base of the labium majus, on the deep surface of the inferior layer of the triangular ligament. They are about the size of a small bean, and measure one centimeter (three-eighths of an inch), anteroposteriorly. Their ducts, two centimeters (seven-eighths of an inch) in length, open upon the inner aspect of the posterior part of the labia minora external to the hymen or carunculæ myrtiformes, where their orifices are marked by a small red depression at each side of the urogenital cleft. The glands are fully developed at birth but they remain small until puberty. They then enlarge and maintain their size during the period of sexual activity. After the menopause they undergo atrophy. Abscesses of these glands and cystic dilatations of their ducts sometimes occur. These abscesses are almost always due to gonorrheal infection.

The **triangular ligament** (**urogenital diaphragm**) **of the female perineum** (Plate CCCCLXXVII) is similar to that ligament in the male; it consists of two layers: an *inferior layer*, or *triangular ligament proper*, and a *superior layer* derived from the obturator division of the pelvic fascia. It is larger in the female than in the male, on account of the greater size of the outlet of the female pelvis, but it is weaker in the female because it is pierced by the vagina. Where the ligament is pierced by the vagina, it blends with the fibrous coat of that canal. The inferior layer is pierced by the vagina, the urethra, the anterior superficial perineal (*posterior labial*) nerve, the superficial perineal (*perineal*) vessels, the artery of the bulb, and of the corpus cavernosum, the dorsal artery, and the nerve of the clitoris. The dorsal vein of the clitoris passes between the transverse perineal ligament and the subpubic (*arcuate pubic*) ligament.

The **ischio-perineal ligament** is that strong portion of the triangular ligament (*urogenital diaphragm*) attached laterally to the medial sides of the ischiac rami just in advance of the tuberosities, extending medially to be lost in the perineal body.

Dissection.—Next search for the prominence formed in the inferior layer of the triangular ligament (*urogenital diaphragm*) by Bartholin's (*greater vestibular*) glands. After examining these glands, reflect the inferior layer of the triangular ligament (*urogenital diaphragm*) backward as far as the posterior margin of the compressor urethræ (*sphincter urethræ*) or deep transverse perineal muscle, thus removing the superficial wall of the deep perineal interspace. Then trace the artery of the bulb, and reflect the bulb forward.

The **deep perineal interspace** (Plate CCCCLXXVIII) of the female perineum, like the superficial interspace, is subdivided into two lateral portions by the vagina; these two lateral parts communicate across the vestibule above the urethra. The contents of this space are the urethra, Bartholin's (*greater vestibular*) glands, the deep transverse perineal muscles, the internal pudendal vessels, the

PLATE CCCCLXXVIII.

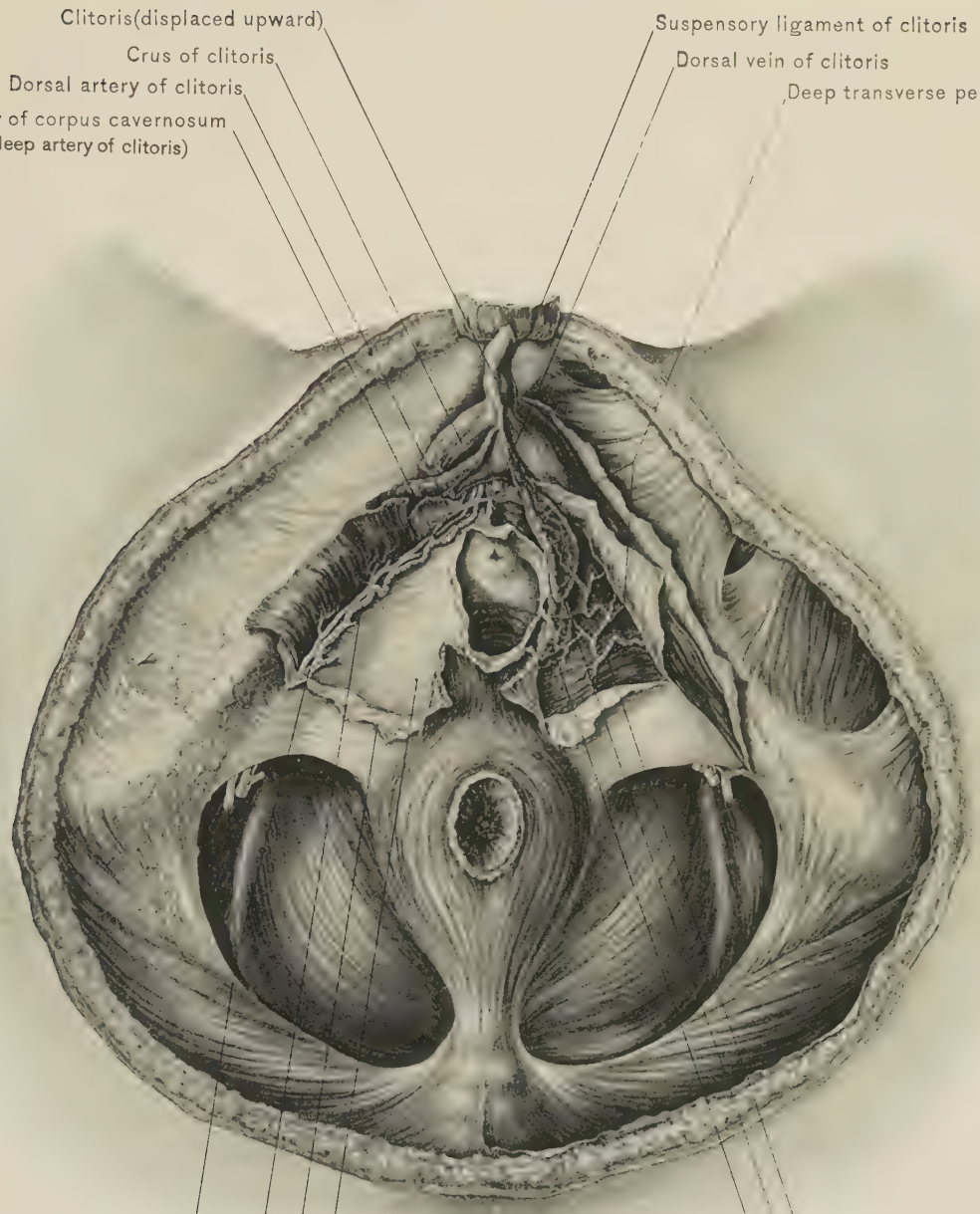
Clitoris(displaced upward)
Crus of clitoris
Dorsal artery of clitoris
Artery of corpus cavernosum (deep artery of clitoris)
Suspensory ligament of clitoris
Dorsal vein of clitoris
Deep transverse perineal m.
Dorsal nerve of clitoris
Internal pudendal a.
Inferior layer of triangular lig. (inferior fascia of urogenital diaphragm)
Superior layer of triangular lig. (superior fascia of urogenital diaphragm)
Artery of bulb
Bulb of vagina (bulb of vestibule)
Gland of Bartholin (greater vestibular gland)

DEEP PERINEAL INTERSPACE OF FEMALE PERINEUM.

PLATE CCCCLXXIX.

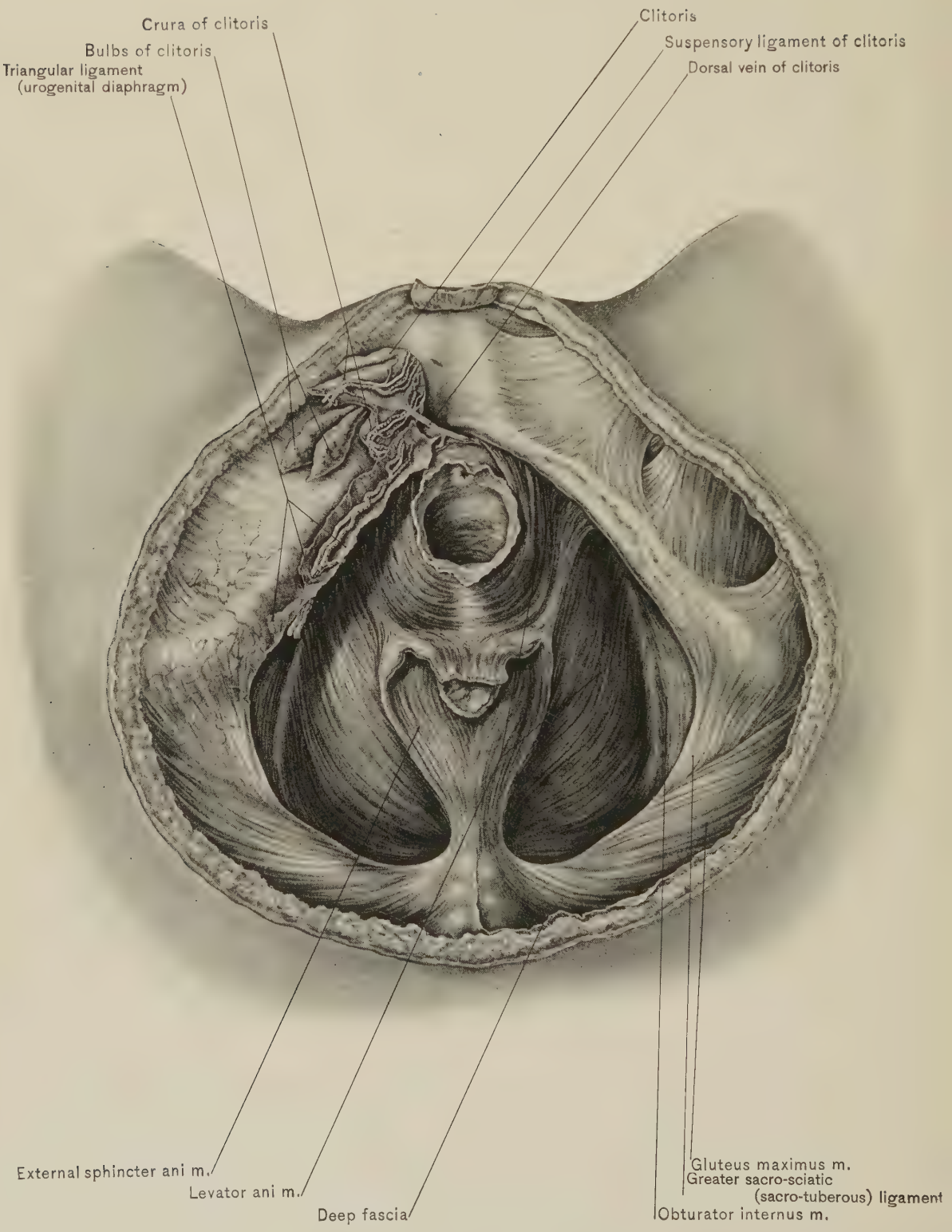

INFERIOR SURFACE OF LEVATOR ANI MUSCLE OF FEMALE.

PLATE CCCCLXXX.

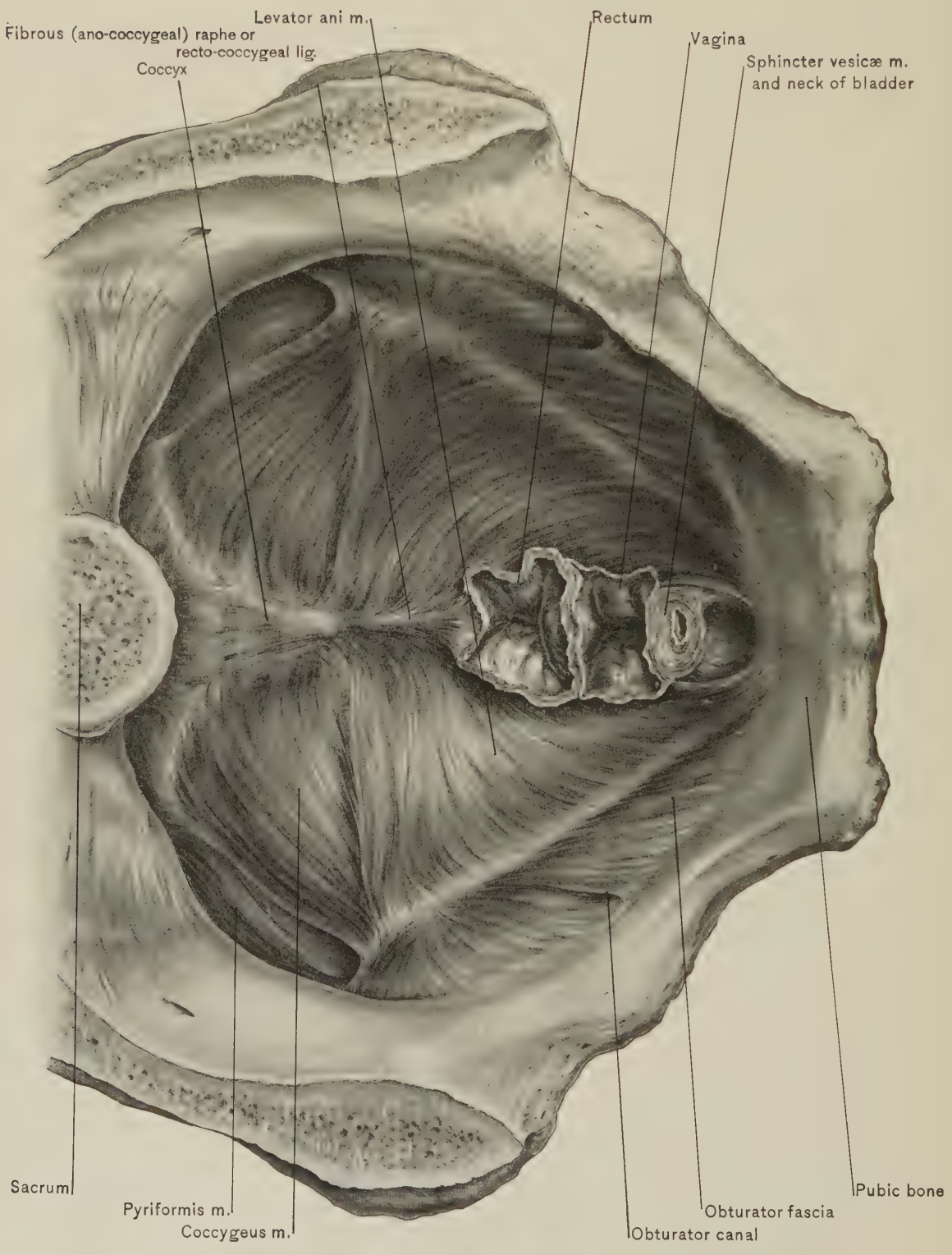

MUSCLES IN FLOOR OF PELVIS—SUPERIOR VIEW.

arteries of the bulbs and of the corpora cavernosa, the dorsal arteries, and the nerves of the clitoris.

The **deep transverse perineal muscle** is situated in the posterior part of the deep perineal interspace. It *arises* from the medial surface of the inferior ramus of the ischium. Its posterior fibers pass medioposteriorly for *insertion* into the perineal body; its anterior fibers pass medialward for *insertion* into the side of the vagina, and partly to unite with fibers of the opposite side.

Blood and Nerve Supplies.—Same as for the homologue in the male.

Action.—To draw the perineal body and the lower part of the posterior vaginal wall forward and support the pelvic floor.

The **compressor (sphincter) urethræ** muscle is a constrictor of the urethra in the male only. It *arises* from the medial surface of the inferior pubic ramus, and the transverse ligament of the pelvis. The most medial fibers run similar to those of the male, forming a ring around the urethra. The lateral fibers extend to the junction between the urethra and the vagina or are *inserted* into the walls of the vagina as it traverses the deep perineal interspace. They partly cover Bartholin's (*greater vestibular*) gland.

Blood and Nerve Supply.—Same as in the male.

Action.—To constrict the membranous urethra and flatten the vaginal walls.

The internal pudendal vessels, the artery of the bulb, the artery of the corpus cavernosum, the dorsal artery, and the nerve of the clitoris follow a course so like the corresponding structures in the male that their further description is unnecessary. The **dorsal vein of the clitoris** takes a course similar to that of the dorsal vein of the penis, and finally empties into the lower part of the vesical plexus of veins after communicating with the internal pudendal vein.

Dissection.—To expose the superior layer of the triangular ligament (*urogenital diaphragm*) remove the deep transverse perineal muscle and the vessels and nerves of the deep perineal interspace.

The **superior, or deep, layer of the triangular ligament (fascia superior of urogenital diaphragm)** is like that of the male, except that it is perforated by the vagina and blends with the fibrous coat of that canal. It is pierced by the vagina, the urethra, the internal pudendal artery and veins, and the dorsal nerve of the clitoris.

Dissection.—The superior layer of the triangular ligament (*urogenital diaphragm*) is next removed. As the anal fascia has been removed in dissecting the ischio-rectal fossæ, the whole of the inferior surface of the levator ani muscle is now exposed.

The **levator ani muscle** (Plates CCCCLXXIX and CCCCLXXX) in the female differs from the corresponding muscle in the male only at its

anterior portion, which closely embraces the sides and posterior wall of the vagina, whereas that part of the muscle in the male embraces the prostate gland. posterior wall of the vagina, whereas that part of the muscle in the male embraces the prostate gland.

Nerve Supply.—Same as in the male.

Action.—Its action is similar: to assist in supporting and compressing the pelvic viscera.

The **female urethra** is only about four centimeters (one and a half inches), in length, and extends from the neck of the bladder downward and forward to the external urinary meatus. As in the male, the meatus is the smallest point in the urethra. It is much shorter, less curved, and somewhat larger in diameter than the male urethra. The urethra is directed downward and forward in front of the anterior vaginal wall close under the pubic arch, against which it is readily rolled by the finger in vaginal examinations. It is nearest to the vaginal wall in its upper portion. With the body in the erect position it is nearly vertical, and in the recumbent position nearly horizontal. It is slightly curved, with its concavity upward and forward. It is somewhat less than one centimeter (three-eighths of an inch) in diameter, but, having an inner mucous lining arranged in longitudinal folds, it can be well dilated and thus permit the removal of vesical calculi through it. It is not surrounded in any part by structures of such density as occur in the male urethra. Coitus has been known to be practiced in it instead of the vagina. Adjacent to this mucous membrane is a thin layer of erectile and yellow elastic tissue, and outside of all is a thick layer of circular and longitudinal muscle fibers, the former being external to the latter.

An urethral caruncle is a small, red, highly vascular tumor which protrudes from the external meatus. It is usually attached to the posterior urethral wall.

Inguino-labial hernia is a protrusion of some part of the intra-abdominal contents through the inguinal canal of the female along the round ligament of the uterus to the labium majus.

In a **pudendal hernia** the protruding mass reaches the labium majus by passing between the vagina and the ramus of the ischium. Although this form of hernia is uncommon, it should be borne in mind, because it is apt to be mistaken for abscess or hematocele or cyst of one of the Bartholin's (*greater vestibular*) glands.

Hydrocele of the pudendum is analogous to hydrocele of the tunica vaginalis testis, and originates in the canal of Nuck (*vaginal process of peritoneum*), which is in relation with the round ligament of the uterus in the inguinal canal, and is formed by the processus vaginalis of the peritoneum.

Lacerations of the female perineum may occur during labor. In the simple forms the perineum is ruptured in the median line at the posterior commissure of the vulva. The structures torn in incomplete lacerations are the vaginal wall,

the skin, and the perineal body. In such lacerations the edges of the wound are separated by tension produced by the superficial transverse perineal, deep transverse perineal, and levator ani muscles. If the rent is not sutured and repaired immediately, the wound heals by granulation, the floor of the pelvis is weakened, and disease and discomfort incident to prolapse of the uterus and other pelvic organs supervene. Compensation for the defect is partially provided by forward displacement of the perineal body and the anus by the deep transverse perineal and levator ani muscles, if these muscles have not been ruptured. Complete lacerations extend through the sphincter ani muscles and anterior wall of the rectum, causing incontinence of feces. The perineal body, the deep transverse perineal muscle, or the levator ani muscle may be ruptured subcutaneously. In lacerations at the side of the vaginal orifice one of the bulbs of the vagina may be torn, and a deep suture may be required to check the resulting persistent hemorrhage.

INDEX

In this Index the references in **heavy-face type** are to the pages containing plates illustraring the subject named. References in regular type are to the text.

A

Abdomen, ascites, 233
blows upon, 305
examination, 251
fascia, superf., 261, 260, 266
form, 233
linea alba, 234
lineæ albicantes, 234
semilunares, 237
lymphatics, 638
palpation, 234, 251
pendulous, 233
regions, 335
skin, 234
surface anatomy, 234
the, 233
tympanites, 233
veins, superf., 263
walls, openings, 332
Abdominal abscess, 326
aorta, 507
bifurcation, 251
compression, 251
line for, **241**
pulsation, 251
cavity, 327, 331
contents, 331
divisions, 331
intercostal N., 284
muscles, incision, 292
parietes, 256
ring, external, 239, 268, 270, **271, 275, 295**
inguinal, 306, **314**
internal, 239, 306, **314**
sympathetic, 521
viscera, diagram, **243, 245, 247, 249, 334**
locations, 251
relations, 378
wall, abscess, 292
cutaneous N., 264
fascia, deep, 265
Abdominal wall, incisions, 325
limits, 238
lymphatics, 638
superf., 263
nerve supply, 324
thickness, 256
transverse section, **281**
wounds, 325
Abernethy's fascia, 565
Abscess, abdominal, 326
abdominal wall, 292
appendiceal, 451
Bartholin's gland, 724
ischio-rectal, 659
liver, 385
lung, 213
perinephric, 490
peripleuritic, 151
psoas, 538
renal, 407
vertebral, 407
Accelerator urinæ M., 661, **549, 581, 658**
Accessory liver, 473
pancreatic duct, 458
Acetabular lig., 3
Acetabulum, 543, **558**
Acromio-clavicular joint, 98
Acro-uterine lig., **615**
Adductor brevis M., 73
longus M., **73, 83**
magnus M., **73, 75, 605, 658**
tendon, **10**
Adhesions, greater omentum, 357
Aggregated lymph nodules, 437
Air passages, foreign bodies, 172
Alcock's canal, 560
Ampulla, bile duct, 414, 478, **459, 461**
of Vater, 414, 478, **459, 461**
calculus, 463
rectum, 580
Amputation, Chopart's, 62, 66
foot, 62
Hey's, 66
hip-joint, 77
knee-joint, 71
Lee's, 71
leg, 68, **70**
Lisfranc's, 62, 64
penis, 695
phalanges, 62
Pirogoff's, 62, 68
Stokes-Gritti, 72
Syme's, 62, 67
Teale's, 71
thigh, 72, **73**
toes, 62
Anal canal, 580
fascia, 560, 561, 654, 656, **718, 720**
triangle, 645, 713
Anastomosis, longest, 124, 302
Anastomotica Magna A., 83
Andrews bottle oper., 707
Anesthesia, splanchnic, 523
Aneurysm, aorta, 224
abdominal, 512
ascending, 164
descending, 165
transverse, 165
Angle of Ludwig, 112
penis, 549, 691, **581**
Angulus Ludovici, 98
Ankle-joint, 18
blood supply, 20
dislocation, 41
effusion, 23
excision, 51
movements, 20
nerve supply, 20
synovial membrane, 19
Annular lig., anterior, ankle-joint, 20
external, ankle-joint, 20

Annulus fibrosus, 230
ovalis, 192, **190**
Ano-coccygeal body, 580, 656
lig. 580
raphe, 637
Anomalies, ribs, 115
Anorchism, 708
Anteflexion, uterus, 612
Anteversion, uterus, 612
Anus, 647, **650**
congenital defects, 647
fissure, 647
imperforate, 584, 647
white line, 646
Aorta, **150, 157, 170, 178, 183, 185, 190, 196, 217, 219, 226, 429**
abdominal, 507, **459, 533**
aneurysm, 512
bifurcation, 251, **329, 361, 372, 568**
branches, 508
compression, 251, 515
ligation, 515
line for, **241**
pulsation, 251
relations, 507
aneurysm, 224
arch, **143, 183, 185**
ascending, 163
aneurysm, 164
bulb, 163
descending, 164
aneurysm, 165
sinus, 163
thoracic, 162, 216, **173, 185**
transverse, 163
aneurysm, 165
Aortic arch, 163
N. plexus, 524, **518, 527, 598**
opening, diaphragm, 535
sinus, 163, 197
valve, 198, **173, 199**
position, 108, **107**
Apex-beat of heart, 108
Aponeurosis, external oblique M. 270, **266, 271, 290, 295, 297, 303**
internal oblique M., 280, **290, 303**
transversalis M., 291, **290**
Appendectomy, 449
Appendices epiploicæ, 406
Appendicitis with abscess, 451
Appendicular A., 427, 441
veins, 427
Appendiculo-ovarian lig., 367, **552, 627**
Appendix, auricular, 191, 193, **190, 196**
epididymis, 713
epiploic, 369, **372, 374**
testis, 713, **700**
vermiform, 402, see Vermiform appendix.
Arbor vitæ, 613
Arch, aorta, **183, 185**
crural, 274
femoral, 274
foot, function, 34
lateral, 33
longitudinal, 32
transverse, 33
lumbo-costal, lateral, 535, **533**
medial, **533**
Arcuate lig., 673
external, **533**
internal, **533**
Arcus tendineus, 560, **586**
Arteria aberrans, 128, 224
Arteries, rectum, 583
Artery, anastomotica magna, **83**
appendicular, 427, 441
axillary, **126**
azygos of vagina, 573
bronchial, 223
of bulb, 575, 646, 669, 722, **725**
carotid common, 167, **143, 157, 183, 185, 520**
celiac, 240, 482, 491, 508, **514**
cervical, 570, **571**
circular of cervix, 570
colic, left, 431, 511, **429**
middle, 427, **359, 372, 424**
right, 359, 427, **372, 424**
comes nervi phrenici, 123, 156, **157**
coronary, 417, **185, 454, 466, 482, 502, 508, 514**
anterior, 165
left, 165, 188, **190, 196**
right, 165, 188, **196**
of corpus cavernosum, 670, **725**
spongiosum, 575
cortico-medullary, **499**
costo-cervical, 127
cremasteric, 305, 511, **275**
cystic, 417, 509, **412**
deep of penis, 670
diaphragmatic, 224
dorsal of clitoris, 575, **725**
penis, 575, 663, **671**
dorsalis pedis, ligation, 94
epididymal, 511
epigastric, deep, 240, 302, **287, 293, 314, 329, 355, 359, 361, 547, 552, 554, 566, 568, 627**
line for, **241**
inferior, 240, 302, 566, **126, 287, 293, 314, 329, 355, 359, 361, 547, 554, 568**
line for, **241**
superficial, 262, **260**
superior, 121, 123, 124, 302, **287, 293**
esophageal, 224
fallopian, 511
femoral, 5, 565, **83, 275, 568**
deep, **73, 75**
ligation, 81, **83**
superf., **73, 75**
ligation, 85
funicular, 618
gastric, **366, 412, 454, 459, 466, 482, 502, 514**
left, 415, 508, **482, 514**
right, 416, 509, **454, 482, 514**
short, 464
gastro-duodenal, 416, 509, **454, 482, 514**
gastro-epiploic, left, 425, 464, 510, **412, 420, 454, 482, 514**
right, 418, 509, **412, 454, 482, 514**
genu suprema, **83**
gluteal, 577, **568, 615**
inferior, 576, **571, 615**
superior, 577, **568, 605**
hemorrhoidal, inferior, 656, **654, 658, 718**
middle, 570, **568, 571, 615**
superior, 431, 511, **429, 568, 571, 615**

Artery, hepatic, 415, 474, 509, **366, 383, 412, 420, 454, 459, 466, 471, 482, 502, 514**
hypogastric, 202, 568, 569, 571, 605
obliterated, 327, **329, 547**
ileo-colic, 359, 374, 427, **424**
iliac, 573
circumflex, deep, 291, 566, **126, 293**
superf., 263, **260**
common, 561, **424, 429, 547, 554, 568, 571**
bifurcation, **241**
left, 562
line for, 251, **241**
right, 562
external, 565, **314, 329, 374, 376, 403, 552, 568, 571, 615, 633**
line for, 251, **241**
internal, 569, **568, 571, 605, 615**
ilio-lumbar, 576, **568, 571, 615**
infracostal, lateral, 124
innominate, 101, 165, **143, 170, 178, 183, 185**
ligation, 166
intercostal, 127, 233, **170, 185, 219, 226**
anterior, 124, **121, 126, 293**
aortic, 128, **126, 293**
highest, 127
superior, 127
interventricular, 188, **190, 196**
intestinal, 428, 510
ligamentous, 511
lumbar, 511, **502**
mammary, internal, 101, 120, **121, 126, 139, 157, 293**
ligation, **100**
marginal, 188, **185, 196**
mediastinal, 123, **121**
posterior, 224
mesenteric, inferior, 240, 428, 511, **329, 361, 366, 372, 429, 454, 459, 491, 502, 547, 568**
Artery, mesenteric, superior, 240, 426, 464, **359, 366, 424, 429, 454, 459, 466, 491, 502**
musculo-phrenic, 123, 124, **121, 139**
obturator, 573, **275, 568, 571, 615**
abnormal, 574
anomalous, 305
ovarian, 511, 614, **454, 466, 571, 615**
pancreatic, 509, 510
pancreatica magna, 510
parvæ, 510
pancreatico-duodenal, inferior, 426, 464, 510, **424, 454**
superior, 416, 509, **454**
perforating, 124, **121, 126, 139**
pericardiac, 123, 224, **121, 139, 185**
pericardiaco-phrenic, 123, 156, **157**
perineal, 659, 721, **658**
superficial, 659, **718**
transverse, 660, 722, **658, 718**
peroneal, **70**
ligation, 90
phrenic, 508, **454, 459, 491, 502, 514**
inferior, 508
superior, 123
popliteal, **7**
ligation, 85
pubic, 305, 574
pudendal, external, superf., **260**
internal, 574, 605, 615, 670, **568, 571, 658, 671, 718**
pulmonary, 168, **157, 170, 190, 196, 208, 210, 221**
left, 168, **178, 183**
right, 168, **173, 183, 185**
pyloric, 416, 509, **412, 454, 482, 514**
inferior, 509
renal, 240, 510, **466, 491, 502**
supernumerary, 511
sacral, lateral, 568, 576, **571, 615**
Artery, sacral, lateral, inferior, 576
superior, 576
middle, 512, **568**
saphenous short, **70**
sciatic, 576, **568, 571, 615**
scrotal posterior, 660
sigmoid, 431, 511, **429**
spermatic, 308, 511, **329, 454, 466, 502, 568, 700, 702**
external, 305
internal, 511
spinal, 512
splenic, 398, 464, 509, **366, 395, 420, 422, 424, 454, 459, 466, 487, 502, 514**
sternal, 123, **121, 139**
subclavian, **126, 143, 157, 293**
left, 167, **183, 185**
right, **183, 185**
subcostal, 223
suprarenal, 240, **466**
inferior, 510, **491, 502**
middle, 510, **491, 502**
superior, 510, **491, 502**
sural, **70**
testicular, 511
thoracalis suprema, **126, 293**
thoracic, lateral, **293**
long, **126, 293**
superior, **126, 293**
thymic, 123
thyroidea ima, 166
tibial, anterior, 70, **91**
ligation, 90, **91**
posterior, 70, **88**
ligation, **88**
tubal, 511
umbilical, 569, **355, 359, 547, 571**
obliterated, **329**
ureteral, 511
uterine, 511, 570, 614, **571, 615**
vaginal, 573, **571, 615**
of vas deferens, 570, **700, 702**
of vermiform process, 427
vertebral, **157**
vesical, 573
inferior, **568, 571, 615**
middle, 570, **568, 571, 615**

Heavy-face type denotes plates illustrating the subject named

Artery, vesical, superior, 570, **568, 571, 615**
xiphoid, **121, 139**
Articular capsule, 1, **3**
knee-joint, 12
Articulation, see Joint.
Ascites, 337
Aspiration, pericardium, **110**
pleura, 111, **110**
Astragalo-scaphoid joint, 25
lig., 25, **22**
Astragalus, dislocation, 42
excision, 51
fracture, 61
Atresia, cervix, 612
vagina, 625
Atrium, left, 197, **196**
right, 191, **190**
Auerbach's plexus, 438
Auricle, left, 197, **173, 185, 190, 196**
right, 191, **173, 183, 185, 190, 196**
openings, 192
sinus, 191
Auricles, 187
Auricular appendix, 191, 193, **183, 190, 196**
Auriculo-ventricular furrow, 187
opening, left, 197
right, 194, **173**
Axillary A., **126**
line, 105
anterior, 105
posterior, 105
Azygos A. of vagina, 573
vein, 228, **143, 150, 173, 183, 185, 217, 219, 221, 226**

B

"Bachelor's button," 655
"Barrel-shaped" chest, 97
Bartholin's gland, 723, **725**
duct, 715
Bas fond of bladder, 555
Bassini's operation, 321
Bevan's incision, 478
operation, 710
Biceps femoris M., **73, 75**
tendon, **10**
Bicuspid valve, 198
position, 108, **107**
Bifurcate lig., 26
Bifurcation, aorta, abdominal, 251
iliac A., common, **241**
Bile duct, 413
ampulla, **459, 461**
common, 413, **383**
structure, 478
Biliary, calculus, 387
Billroth I operation, 392
II operation, 391
Bimanual examination, 716
Bladder, 555, 587, **329, 361, 366, 518, 547, 549, 552, 554, 558, 568, 571, 581, 586, 598, 609, 678**
base, 588
bas fond, 555, 588
blood supply, 592
body, 587
cervix, 588
coats, 590
exstrophy, 238
female, 631
blood supply, 632
fundus, 588
lig., false, 354, 590, 592
lateral, 556
posterior, 556
superior, 556
peritoneal, 354
true, 591
anterior, 561
lateral, 561, 590
superior, 590
lymphatics, 592
neck, 588
nerve supply, 592
peritoneum, 580
position, 256
rupture, 559, 592
structure, 590
summit, 587
tapping, 589
trigone, 571, **615**
veins, 592
"Blue baby," 193
Bougie, urethral, 693
Brachial N. plexus, **157, 520**
Brachio-cephalic V., 153
Broad lig. of uterus, 342, 350, 559, 617
contents, 617
Bronchi, 172
primary, 102
Bronchial A., 223
V., 224, **150, 178**
Bronchoscopy, 172
Bronchus, **170**
division, 213
eparterial, 214, **221**
Bronchus, hyparterial, **214**
left, 172, **143, 150, 173**
right, 172, **150, 173, 178**
foreign bodies, 172
Brunner's glands, 432
Bubo, 640
Bubonocele, 315
Bulb of aorta, 163
of corpus cavernosum, **663**
of corpus spongiosum, 646
of penis, 683, **581**
of urethra, 646, 683, **663**
of vagina, **725**
of vestibule, 723
Bulbo-cavernosus M., 581, 661, 718, 722, **549, 658, 720**
Bulbo-urethral gland, 669, **665, 690**
Bulbous urethra, 692
Bull's operation, 321
Bunion, 36
Bursa prepatellar, **7**
Bursæ, knee-joint, 16

C

Calcaneo-astragaloid joint, 23
posterior, 24
lig. antero-internal, 24
external, 24
internal, 24
posterior, 24
Calcaneo-cuboid joint, 25
lig., dorsal, 26, **22**
internal, **22**
interosseous, 26
long, 25
plantar, 26, **22**
Calcaneo-fibular lig. 19, **22**
Calcaneo-navicular lig. plantar, 24, 25, **22, 27**
Calcaneo-scaphoid lig. external, 24, 25, **22**
inferior, 25, **22, 27**
Calcaneus, dislocation, 42
excision, 51
fracture, 61
Calculus, biliary, 387
renal, 504
vesical, removal, 679
Calyx of ureter, 503
Canal, Alcock's 560, 656
anal, 580
cervical, 613
inguinal, 240, 306
of Nuck, 618
hernia, 318

Heavy-face type denotes plates illustrating the subject named

Canal, obturator, *573*, **275**, **586**, **636**, **730**
Cancer, see Carcinoma.
Capsula glomeruli, *503*
Capsular lig. knee-joint, 12, 7
tibio, fibular, superior, 17
vertebrae, 230
Capsule, ankle-joint, 18
of Bowman, *503*
kidney, *495*
prostate gland, *594*, **675**
suprarenal, *506*
Caput coli, 401
medusa, 418
Carcinoma cervix, 612
esophagus, *175*
excision, *175*
Cardiac dulness area, *105*
ganglion, **161**, **157**, **178**, **520**
lymph glands, 176
N., cervical, inferior, *159*
superior, *159*
sympathetic, **157**
inferior, 161
middle, 160
plexus, 161, **520**
great, 161
posterior, **217**
superf., 161, **157**, **178**
superior, 160
thoracic, *159*
valves, location, 108
position, **107**
vein, anterior, 188
great, 188, **185**, **196**
middle, 188
posterior, 188, **185**, **196**
Carotid A., common, **143**, **157**, **520**
left, 167, **183**, **185**
right, **183**, **185**
Cartilage, semilunar, 13
xiphoid, **139**
Caruncle, urethral, 732
Carunculæ hymeneales, *625*, *715*
myrtiformes, *715*
Castration, 709
Caudate lobe of liver, 474, **383**, **471**, **514**
process liver, 474
Cavernous, nerves, 601
N. plexus, 600
urethra, 692
Cavity, abdominal, 331
pleuro-peritoneal, 331
Cecostomy, *452*
Cecum, 401, **374**, **376**, **379**, **403**, **424**, **443**, **445**, **447**, **547**, **627**
non-descent, 401
position, *255*
topography, 401
types, 402
Celiac A., 240, *508*, **482**, **491**, **514**
axis, 240, *508*, **454**, **459**, **482**, **491**, **502**, **514**
ganglion, *522*, **518**, **520**, **598**
lymph glands, 641
N. plexus, *522*, *523*, **518**, **527**, **598**
Cellulitis, pelvic, *559*
Central tendon diaphragm, *535*, **533**
perineum, 646
V. of liver, 476
Cervical A., *570*, **571**
canal, 613
ganglion, inferior, **520**
superior, **520**
pleura, *145*
rib, 114, *115*
excision, *115*
Cervix, 611, **609**
atresia, 612
carcinoma, 612
Chancre, 694
Chancroid, 694
Chest, 94
see Thorax.
"Chimney-sweep's cancer," 697
Cholecystectomy, 479
Cholecystenterostomy, 480
Cholecysto-colostomy, 407
Cholecysto-duodenostomy, 480
spontaneous, *457*
Cholecystogastrostomy, 480
Cholecystostomy, 387, 478
"ideal," 478
Choledochostomy, 479
Chondro-sternal lig., anterior, 232
Chopart's amputation, 62, 66
Chordæ tendineæ, 194, **190**, **196**
Chordee, 694
Circular A., of cervix, *570*
Circulation, fetal, 201
Circumanal glands, 647
Circumcision, *695*
Cisterna chyli, 176, *227*, **226**
Clitoris, 714, 728, **554**, **609**, **712**, **720**, **725**
dorsal A., *575*
Clitoris, glans, 714
prepuce, 714
Club-foot, 34
Coccygeal N., **525**, **603**, **605**
plexus, 601
Coccygeus M., 637, **586**, **605**, **636**, **730**
Coccyx, **586**, **658**, **730**
Cock's urethrotomy, 646
Coley's operation, 321
Colic A., 427
left, 431, *511*, **372**, **429**
middle, 427, **359**, **372**, **424**, **429**
right, **359**, **372**, **424**
Colic flexure, left, 406
right, 406
Collateral patellar lig., 12
Colles' fascia, *651*, **654**, **658**, **663**
Colon, 405
accessibility to pressure, 410
ascending, 406, **359**, **372**, **374**, **376**, **379**, **403**, **424**, **443**, **445**, **447**
position, *255*
descending, 407, **361**, **372**, **424**, **429**
position, *255*
iliac, 408, *555*
position, *255*
pelvic, 408, *555*
sigmoid, 408
transverse, 406, **359**, **361**, **372**, **403**, **412**, **420**, **422**, **424**, **429**, **514**
position, *255*
ptosed, 406
Coloptosis, 406
Colostomy, *451*
iliac, *451*
lumbar, 368, *452*
Colporrhaphy, anterior, 626
Columnæ carneæ, 193, **190**, **196**
Columns of Bertini, 496, **499**
Comes arteriosus, nervi phrenici A., 123, 156, **157**
Commissure of vulva, anterior, 714
posterior, 714
Common bile duct, 413, 477, 366, **383**, **412**, **454**, **459**, **461**, **466**, **471**, **482**, **514**
reconstruction, *415*
surgery, 414
lig., anterior, 230

Heavy-face type denotes plates illustrating the subject named

Common lig. posterior, 230
tendon, perineal muscles, 646
Compressor urethræ M., 668, 731, **549, 581, 665, 671**
Congenital hernia, 311
diagram, **310**
phimosis, 684
Coni vasculosi, 707
Conjoined tendon, 279, 292, **275, 297, 299, 329**
Conus arteriosus, 193
Cord, spermatic, 240, 307, 710, **287, 293**
umbilical, hernia, 322
Corona of glans, 684
Coronary A., 417, 508, **185, 454, 459, 466, 482, 502, 514**
anterior, 165
left, 165, 188, **190, 196**
right, 165, 188, **196**
furrow, 187
lig., **7**, 14
of liver, 353, 386, **366, 381, 469**
N. plexus, **157, 518, 520, 598**
anterior, 161
left, 162
posterior, 162
right, 161
sinus, 191, **173, 196**
orifice, 192
valve, 191, 192
sulcus, 187
vein, 417, **454, 466, 482**
Corpus Arantii, 197, **199**
cavernosum, 683, **549, 581, 665, 658, 682, 690**
spongiosum, 683, **549, 581, 658, 663, 665, 682, 690**
bulb, 646
Corpuscles, renal, 496
Cortico-medullary A., **499**
Costal pleura, 145
Costo-cervical trunk, 127
Costo-chondral joint, 232
Costo-colic lig., **366**
Costo-phrenic sinus, 146
Costo-sternal lig., anterior, 232
posterior, 232
Costo-transverse lig., anterior, 231
middle, 231
posterior, 231
Costo-vertebral lig., anterior, 231
Cotyloid lig., **2, 3**
Cowper's gland, 669, **665, 690**
Cremaster M., 280, 283, **271, 295, 297, 299, 303**
blood supply, 283
nerve supply, 283
Cremasteric A.,, 305, 511, **275**
fascia, 283, 698, **314**
reflex, 283
Cruciate lig., anterior, 13, **7**
posterior, 13, **7**
Crura, diaphragm, 535
Crural arch, 274
N., 530, **275, 527**
anterior, 531, **518, 525, 527, 558, 598, 603**
line of incision, 80
Crureus M., **73, 75**
Crus, diaphragm, **533**
of penis, 683, **682, 690**
Cryptorchism, 708
Crypts of Lieberkühn, 437, 440
Cubo-cuneiform joint, 29
Cubo-metatarsal joint, 30
Cubo-navicular joint, 26
lig., 26
dorsal, **22**
Cubo-naviculo-cuneiform joint, 26
Cubo-scaphoid lig., dorsal, **22**
Culdesac of Douglas, 583
Cusp infundibular, 194
marginal, 194
septal, 194
Cutaneous N. anterior, 284
external, 530, **525, 527**
lateral, 529, 530, **266**
middle, **527**
of thigh, posterior, 607
Cyst, dermoid, testicle, 708
Nabothian, 613
pilonidal, 647
sacro-coccygeal, 647
urachus, 327
Cystic A., 417, 509, **412**
duct, 415, 477, **383, 412, 420, 454, 466, 471, 514**
obstruction, 387
vein, 417
Cystocele, 626

D

Dartos, 684, 697, **702**
labia majora, 721
Deltoid lig., 19, **22**
Delto-pectoral groove, 101
Descending colon, **361**
Development, femur, 52
fibula, 53
metatarsus, 53
patella, 53
phalanges, 54
tarsus, 53
tibia, 53
Diaphragm, 532, **150, 157, 170, 178, 219, 221, 366, 491, 520, 533**
action, 537
blood supply, 536
cerebral tendon, 535, **533**
crura, 535, **226**
crus, **527, 533, 540**
nerve supply, 536
openings, 535
position, 252
structures piercing, 95
urogenital, 662, **663, 665, 675**
superior, 586
Diaphragmatic A., 224
ganglion, 537, **518, 520, 598**
lymphatics, 137
N. plexus, 522, **527**
pleura, 145
tic, 156
Digital dilatation pylorus, 390
fossa, 704
Dislocation, 37
astragalus, 42
calcaneus, 42
femur, 38
fibula, 40
foot, 41
hip-joint, 37
knee, 40
metatarsal, 45
os calcis, 42
patella, 39
phalanges toes, 45
subastragaloid, 42
talo-calcaneal, 42
talus, 42
tarsus, 45
tibia head, 40
Diverticulum ilei, 238, 401
Meckel's, 238, 401
Dorsal A. of clitoris, 575, **725**
of penis, 575, 670, **671**
N. of clitoris, **718, 720, 725**
N. of penis, 607, 673, **658, 663, 665, 671**

Heavy-face type denotes plates illustrating the subject named

Dorsal V. of clitoris, 731, **554, 725, 728**
of penis, 579, 673, **549, 581, 663, 665**
Dorsalis pedis A., ligation, 94
line of incision, 80
Dorsi-lumbar N., **525, 527, 603**
Douglas' pouch, 342, 559, 583, **571**
floor, 350
Downe's operation, 322
Drainage, pericardium, 181
Duct, Bartholin's gland, 715
bile, 413
structure, 478
common bile, 413, 477, **366, 383, 412, 454, 459, 461, 466, 471, 482, 514**
reconstruction, 415
surgery, 414
of Cuvier, 155
cystic, 415, 477, **383, 412, 420, 454, 466, 471, 482, 514**
obstruction, 387
ejaculatory, 599, **549, 581, 586, 690**
epididymis, 707
of Gärtner, 622
hepatic, 415, 474, 477, **383, 412, 420, 454, 466, 471, 482, 514**
longitudinal of epoöphoron, 622
of pancreas, 458, **459, 461**
accessory, 458, **461**
prostatic, 595
of Santorini, 458
Skene's, 622
spermatic, 308, 555
thoracic, 176, **143, 150, 173, 178, 185, 219, 221, 226**
vulvo-vaginal gland, 715
of Wirsung, 458
Ductuli aberrantes, 707
efferentes, 703, 707
Ductus arteriosus, 201, **183, 196**
choledochus, 477
deferens, 308, 555, 596, 707, **314, 329, 361, 547, 558, 568, 586, 678, 700, 702**
Santorina, **461**
venosus, 201
Duodenal, fossa, inferior, 377
superior, 377
glands, 432
Duodenal, papilla, 478
Duodeno-hepatic lig., 358
Duodeno-jejunal flexure, 400, 401, 457, **366, 372, 454**
fossa, 377
Duodenotomy, 458
Duodenum, 399, 455, **359, 366, 372, 412, 424, 454, 487, 494**
descending, 456, **459, 461**
first ascending, 455
fistula, 400
surgery, 457
suspensory lig., 457
terminal ascending, 456
transverse, 456, **372, 459 461**
ulcer, 457
excision, 457
operations, 457
Dupuytren's fracture, 61
Duval-Barasty operation, 113

E

Ejaculatory duct, 599, **549, 581, 586, 690**
Elephantiasis scroti, 703
Emmett oper., 626
Emphysema, 215
"Empty intestine," 399
Empyema gall-bladder, 387
interlobar, 213
necessitans, 151
thoracis, 148
rupture, 151
Encysted hernia, 312
Endothoracic fascia, 119, 136
Ensiform cartilage, 112, 238, **121, 139, 178, 235**
Eparterial bronchus, 214, **221**
Epicardium, 179
Epididymal A., 511
Epididymis, 703, **700, 702, 706**
duct, 707
female, 630
structure, 707
Epididymitis, 708
Epigastric A., deep, 240, 302, 566, **126, 287, 293, 314, 329, 355, 359, 361, 547, 552, 554, 568, 627**
inferior, 240, 302, 566, **287, 293, 314, 329, 355, 359, 361, 547, 554, 568**
Epigastric A., superf., 262
superior, 123, 124, 302, **121 139, 287, 293**
hernia, 273
N. plexus, 522
V. deep, 521, **275**
inferior, 521
superf., 263, **260**
Epiploic appendix, 369, **359, 372, 374**
foramen, 352, **482**
Epispadias, 238, **696**
Epithelioma scrotum, 697
Epoöphoron, 630
Erector clitoridis M., 722, **718, 720**
penis M., 662, **658, 663**
spinae M., **329**
Esophageal A., 224
N. plexus, 156, 227, **217, 219, 518, 520, 598**
opening, diaphragm, 536
Esophagoscopy, 175
Esophagus, 175, 224, **143, 150, 170, 173, 178, 217, 219, 454, 466, 482, 491, 533**
blood supply, 176
caliber, 175
carcinoma, 175
excision, 175
foreign body, 175
nerve supply, 176
relations, 175
stricture, 175
thoracic, 175
Eustachian, valve, 192, **173, 190, 196**
Excision, ankle-joint, 51
astragalus, 51
calcaneus, 51
carcinoma, esophagus, 175
cervical rib, 115
hip-joint, 45
knee-joint, 46
lower extremity, 45
metatarsal, 52
os calcis, 51
patella, 51
phalanges, 52
pylorus, 391
talas, 51
Excisions, lines of, **44**
Expiration, forced, 120
Exstrophy of bladder, 238
Extensor digitorum longus M., **70, 91**
tendons, fibrous expansion, 11

External lateral lig., knee-joint, 12
oblique M., 265, **314**
aponeurosis, **290, 295, 297**
Extracapsular fracture, femur, 54
Extraperitoneal connective tissue, 325
urinary extravasation, 556
Extravasated urine, 652

F

Falciform lig. of liver, 353, 386, **271, 381, 469**
margin, **295**
Fallopian A., 511
tube, 630, **552, 554, 571, 609, 615, 627**
coats, 630
fimbriæ, 630
lymphatics, 631
removal, 631
False lig. of bladder, 354
Falx inguinalis, 279, 292, **275, 329**
Fascia, abdomen, superf., 261, **260, 266**
abdominal wall, deep, 265
Abernethy's, 565
anal, 560, 561, 656, **654, 718, 720**
Camper's, see "Camper's fascia."
Colles', 651, **654**
cremasteric, 283, 698, **314**
endothoracic, 119, 136
iliac, 537, **275, 558**
infundibuliform, 306, 698, **299, 314**
interabdominal, 279
intercolumnar, 273, 697, **295, 314**
intercostal, external, 116, 136
internal, 116, 136, **117**
middle, 136
ischio-rectal, 560, 561, 656
lata, **271, 295, 718**
lumbar, **290, 329, 454, 527, 533**
lumbo-dorsal, **290, 329, 533**
obturator, 560, 654, **558, 586, 636, 718, 720, 730**
pelvic, 559
diagram, **558**
perineum, superficial, 716
phrenico-pleural, 146
Fascia of pyriformis, 560
recto-vaginal, 561
recto-vesical, **586, 678**
renal, 490
Scarpa's, 261, 651
scrotal, 698
Sibson's, 108
spermatic, **700, 702**
external, 697, **273, 295, 314**
internal, 306, 698, **299, 314**
middle, 698
transversalis, 306, **275, 299, 314, 549, 558, 581**
urogenital diaphragm, 560
Fascial sheath, penis, 691
Fat, perinephric, 490
Female perineum, 713
thorax, 96
Femoral A., 5, 274, 275, 565, **83, 568**
common, line of incision, **80**
deep, **73, 75**
ligation, 81, **83**
line of incision, **80**
superf., **73, 75**
ligation, 85
line of incision, **80**
hernia, diagnosis, 239
nerve, 518, 531, **525, 527, 558, 603**
ring, **275, 329**
septum, 326
sheath, 538, **275**
vein, **83, 271, 275, 568**
deep, **73, 75**
superf., **73, 75**
Femur, development, 52
dislocation, 38
fracture, 54
condyle, 58
extracapsular, 54
intracapsular, 54
shaft, 57, **56**
Ferguson's operation, 321
Fetal circulation, 201
Fetus, peritoneum, 351
Fibula, development, 53
dislocation, 40
fracture, 58, **60**
Fibular collateral lig., 12, **10**
Fissure, anal, 647
of the ductus venosus, 473
gall-bladder, 473
Fissure, liver longitudinal, 468, **383, 471**
sagittal, left, 468, **471**
transverse, 473
umbilical, 473
prostatic, 595
vena cava, inferior, 473
Fistula, recto-vaginal, 626
umbilical, 238
urinary umbilical, 327
vesico-vaginal, 626
Fistula-in-ano, 647
complete, 659
incomplete external, 659
internal, 659
Flat chest, 97
Flat-foot, 34
Flexor digitorum longus M., 70, 88
hallucis longus M., **70**
Flexure, colic, left, 255, 406
right, 255, 406
hepatic, 255, 406
sigmoid, 255, 408
course, 409
splenic, 255, 406
Floating kidney, 490, 504
"Floating ribs," 114
Foot, amputation, 62
arch, function, 34
lateral, 33
longitudinal, 32
transverse, 33
articulations, 64
as a whole, 32
dislocation, 41
lig., **27**
synovial cavities, **27**
Foramen, epiploic, 352, **366, 482**
epiploicum, 338, **422**
ovale, 192, 201
vein of Galen, **190**
for vena cava, 536
of Winslow, 328, 352, **366, 422, 482**
hernia, 352
Foramina papillariæ, 503
Thebesii, 192, **190**
venarum minimarum, 192, **190**
Foreign body, air passages, 172
esophagus, 175
heart, 198
Foreskin, 684
Fornix, anterior, 622
posterior, 622

Fossa, digital, 704
duodenal, inferior, 377
superior, 377
duodeno-jejunal, 377, **372**
gall-bladder, 473
hernial of peritoneum, 315
ileo-colic, 377, **374, 376**
infraclavicular, 105
inguinal, 328, **329**
external, 328, **329**
internal, 328, **329**
medial, 328
middle, 328, **329**
intersigmoid, 370
ischio-rectal, 647, 655, **558, 654**
navicularis, 692, 715, **624, 688, 690**
ovalis, 192, **190**
pararectal, 580
peritoneal, 370
retrocecal, 378, **376, 379**
subcecal, 378, **376, 379**
supravesical, 328
Fourchette, 715, **624**
Foveæ inguinales, 328
Fracture, astragalus, 61
calcaneus, 61
Dupuytren's, 61
femur, 54
condyle, 58
extracapsular, 54
intracapsular, 54
shaft, 57, **56**
fibula, 58, **60**
malleolus, 58, **60**
metatarsus, 61
os calcis, 61
patella, 58
phalanges, 61
Pott's, 61
rib, 114
sprained, 61
sternum, 113
talus, 61
tarsus, 61
tibia, 58, **60**
trochanter, greater, 57
Frenulum labiorum pudendi, 715, **624**
of prepuce, 684
Fungus, 708
Funicular A., 618
process, 312
hernia into, 312
"Funnel-breast," 97
Furrow, auriculo-ventricular, 187
coronary, 187
interventricular, 187

G

Gall-bladder, 476, **355, 381, 383, 412, 420, 454, 469, 471, 514**
coats, 477
drainage, 387
empyema, 387
fossa, 473
fundus, **422**
hydrops, 387
operations, 478
position, 253, 328
relations, 386
structure, 477
Gall-stones, 387
Gallie's operation, 321
Gangliated trunk sympathetic, **598**
Ganglion, cardiac, 161, 520, **150, 157, 178**
celiac, 522, **518, 520, 598**
cervical, inferior, **520**
superior, **520**
diaphragmatic, 537, **518, 520, 598**
diaphragmaticum, 155
impar, 600
lumbar, 518, **598**
mesenteric, superior, **518, 520**
phrenic, 155, 537, 572, **518, 520, 598**
prostatic, 600
renal, **518, 520, 598**
semilunar, 522, **518, 527, 598**
left, **525**
right, **520**
thoracic, **518, 520**
of Wrisberg, 161, **150, 157, 178, 520**
Gastrectomy, 391
Gastric A., **366, 412, 454, 459, 466, 482, 502, 514**
left, 417, 508, **482, 514**
right, 416, 509, **454, 482, 514**
short, 464
crises, 324
juice, 483
lymph glands, 641
N. plexus, 523
V., **454, 466, 482, 514**
Gastric V., left, 417
right, 416
Gastrocnemius M. origin, **10, 70**
Gastro-colic lig., 388
omentum, 350, 354
Gastro-duodenal A., 416, 509, **454, 482, 514**
Gastro-enterostomy, 391, 489
Gastro-epiploic A. left, 425, 464, 510, **412, 420, 454, 482, 514**
right, 509, **412, 418, 420, 482, 514**
lymph glands, 642
V., **355**
left, **454**
right, **420**
Gastro-hepatic lig., 388
omentum, 341, **422**
Gastro-jejunostomy, 391
Gastro-mesenteric ileus, 426
Gastro-phrenic lig., 354, 358, 388, **366**
omentum, 358
Gastroptosis, 389
Gastro-splenic lig., 388, **366, 420, 422**
omentum, 388, 397, **366, 420, 422**
Gastrotomy, 390, 391, 485
Genital N., 530, **275**
Genitals, external, male, 683, **624**
Genito-crural N., 275, 530, **525, 527, 603**
Genito-femoral A., 530
N., **275, 525, 527, 603**
Genito-inguinal lig., 311
Genu suprema A., 83
Gimbernat's lig., 274, **275**
Girdle pains, 324
Gladiolus, 112
Gland, Bartholin's, 723
Glands, Brunner's, 432
duodenal, 432
intestinal, 437
intestine, small, 432
large, 440
of Littré, 693
Naboth, 613
solitary, 437
suprarenal, 506, **491**
urethral, 693
utricular, 614
vestibular, greater, 723
Glans clitoridis, 714, **624**
penis, 684, **682, 688, 690**
Glisson's capsule, 413

Globus major, 703, 707, **706**
minor, 703, 707, **706**
Gluteal A., 577, **568, 615**
inferior, 576, **571, 615**
superior, 577, **568, 605**
N. cutaneous, 601
inferior, 605, 607, **525, 603**
superior, 607, **525, 603, 605**
Gluteus medius M., **605**
maximus M., **605, 658, 663, 675, 728**
minimus M., **605**
Gonorrhea, 694
Gracilis M., 658, **73, 75**
Gray rami communicantes, 522
Great sac, 351
Greater omentum, 354, **355, 359, 361**
peritoneal cavity, 351
Groin, crease, 239
Gubernaculum testis, 311
Gullet, 175, 224

H

Hallux valgus, 36
Halsted's operation, 322
Hammer-toe, 36
Harris' veil, 370
"Harrison's Groove," 97
Heart, 182, **150, 178, 183, 185**
apex-beat, 108
capacity, 191
foreign bodies, 198
injuries, 198
position, 105, **104, 107**
size, 191
weight, 191
wounds, 198
Hematocele, pudendal, 723
Hematometra, 612
Hemiazygos V., **221, 226**
accessoria V., 228, **221, 226**
Hemorrhoidal A., inferior, 656, **654, 658, 718**
middle, 570, **568, 571, 615**
superior, 431, 511, 571, **429, 568, 615**
N., inferior, 607, 656, **654, 658**
plexus, middle, **518, 598**
plexus of veins, 579
Hemorrhoids, 656
Hemothorax, 148
Hepatic A., 415, 474, 509, **366, 383, 412, 420, 454, 459, 466, 471, 487, 502, 514**
duct, 383, 415, 471, 474, 477, **412, 420, 454, 466, 482, 514**
dulness, 252
flexure, 255, 406
lymph glands, 641
N. plexus, 523
vein, 474, 476, 521, **491**
Hernia, 315
adiposa, 273, 326
canal of Nuck, 318
congenital, 311
diagrams, **310**
encysted, 312, **310**
epigastric, 273
femoral, diagnosis, 239
foramen of Winslow, 352
into funicular process, 312, **310**
infantile, 312, **310**
inguinal, 312, 315
acquired, 318
diagnosis, 239
direct, 315
coverings, 316
external, 315
indirect, 315
internal, 315
oblique, 315, **314**
complete, 315
coverings, 316
incomplete, 315
operations, 319
pantaloon type, 320
radical cure, 321
reduction, 274
strangulated, operation, 320
stricture, 316
inguino-crural, 317
inguino-femoral, 317
inguino-labial, 732
intermuscular, 317
intraparietal, 317
labial, 318
lung, 214
mesenteric, 363
mesocolic of Cooper, 368
omental, 357
preperitoneal, 317
into processus vaginalis, **310**
pudendal, 732
reduction by taxis, 317
dangers, 318
Hernia, scrotal, 315
sigmoid, 377
straight, 318
testis, 708
into tunica vaginalis, 312, **310**
umbilical, 322
acquired, 322
cord, 322
infantile, 322
operation, 323
radical cure, 323
strangulated, 324
Hernial fossa of peritoneum, 315
sac, **314**
Hesselbach's triangle, 316, 327 **329**
Hey's amputation, 66
Hiccup, 537
Hilum, lung, **212**
Hip-joint, **1, 3**
amputation, 77
blood supply, 5
disease, pain, 6
dislocation, 37
excision, 45
hydrarthrosis, 6
ligaments, 1
accessory, 1
capsular, 1, **3**
cotyloid, 2
round, 2
transverse, 2, **3**
movements, 5
nerve supply, 5
pyo-arthrosis, 6
relations, 5
synovial membrane, 5
synovitis, 6
Hunter's canal, 83
Hydatid of Morgagni, 713, **700**
Hydrarthrosis hip, 6
Hydrocele, 704
congenital, 704
of cord, 704
oper. Andrews, 707
Jaboulay, 704
pudendal, 732
Hydronephrosis, 504
Hydrops gall-bladder, 387
Hydrothorax, 148
Hymen, 625, 715, **624**
imperforate, 715
Hyparterial bronchi, 214
Hypogastric A., 202, 569, **568, 571, 605**
obliterated, 327, **329, 547**

Heavy-face type denotes plates illustrating the subject named

Hypogastric lymph glands, 640
N. 264, 284, 529
plexus, 600, **518, 527, 598**
inferior, 600
V., 578, **568, 571**
Hypospadias, 696
perineal, 647
Hypostatic congestion, 215
Hysterectomy, 619
vaginal, 620

I

"Ideal cholecystostomy," 478
Ileo-cecal fold, 364, 377, **379**
fossa, 377
recess, inferior, 377
superior, 377
valve, 442, **443, 445, 447**
Ileo-colic A., 359, 374, 427, **424**
fold, 377, **374, 376**
fossa, 377, **374, 376**
lymph gland, 642
valve, 442
Ileum, 400, **374, 376, 379, 403, 443, 447, 547**
suspensory lig., 358
Ileus, gastro-mesenteric, 426
Iliac A., 573
circumflex, deep, 291, 566, **293, 568**
superf., 263, **260**
common, 561, **424, 429, 547, 554, 568, 571**
left, 562
ligation, 562
collateral circulation, 565
line for, 251
right, 562
external, **314, 329, 374, 376, 403, 552, 565, 568, 571, 615, 633**
ligation, 632, **564, 633**
line for, 251
internal, 569, **568, 605, 615**
colon, 255, 408
fascia, 537, **275, 558**
lymph glands, 640
nerve, 284, 529
spine, anterior superior, 239
Iliac vein, circumflex, deep, 521
superf., 263, **260**
common, 521, 577, **554**
external, 521, 578, **314, 329, 571, 615, 633**
internal, 578, **568, 571**
Iliacus M., 542, **403, 454, 527, 540, 558, 568, 605**
Ilio-femoral lig., 2, 3
Ilio-hypogastric N., 284, **266, 271, 287, 295, 303, 525, 527, 529, 603**
Ilio-inguinal N., 264, 284, 303, 529, **266, 271, 287, 295, 525, 527, 603**
Ilio-lumbar A., 576, **568, 571, 615**
lig., 454, **540**
V., 226, 579, **568**
Ilio-pectineal lines, 544, **275**
Ilium, 543
Imperforate anus, 584, 647
hymen, 715
rectum, 584
Incision, Kocher's, 292
McBurney's, 301
rectus abdominis M., 301
Infantile hernia, 312
umbilical, 322
Infarction of lung, 215
Infraclavicular fossa, 105
Infracostal angle, 238
lateral, 124
M., 119, **217, 219**
Inframammary region, 105
Infrascapular region, 105
Infrasternal angle, 238
Infundibular cusp, 194
Infundibuliform fascia, 306, 698, **299, 314**
Infundibulo-pelvic lig., 618, 629
Infundibulum, Fallopian tube, 630
Inguinal canal, 240, 306, **295, 297, 299**
contents, 307
fossa, 328, **329**
external, 328, **329**
internal, 328, **329**
medial, 328
middle, 328, **329**
hernia, 312, 315
acquired, 318
diagnosis, 239
direct, 315
coverings, 316
external, 315
indirect, 315
Inguinal hernia, internal, 315
oblique, 315, **314**
complete, 315
coverings, 316
incomplete, 315
operation, 319
pantaloon type, 320
radical cure, 321
reduction, 274
strangulated, operation, 320
stricture, 316
lig., 274, **235, 275, 290, 293, 297, 299, 303, 329, 568**
reflected, 274
lymph glands, 263
ring, abdominal, 239, 306
subcutaneous, 239, 270, **268, 271**
Inguino-crural hernia, 317
Inguino-femoral hernia, 317
Inguino-labial hernia, 732
Innominate A., 101, 165, **143, 170, 178, 183, 185**
ligation, 166
bone, 543
vein, left, 153, **178, 183, 185**
right, 153, **157, 178, 183, 185**
Interabdominal fascia, 279
Interarticular lig., 231
Interauricular septum, 192
Interchondral joints, 232
membranes, 116
Intercolumnar fascia, 273, 697, **295, 314**
Intercostal A., 127, 223, **170, 185, 219, 226**
anterior, 124, **121, 126, 293**
aortic, 128, **126, 293**
highest, 127
superior, 127, **219, 226**
fascia, external, 116, 136
internal, 116, 136, **117**
middle, 136
lymph glands, anterior, 137
external, 137
posterior, 137, 229
lymphatics, 137
membrane, anterior, 136
external, 116
posterior, 116, 136
muscle, action, 120
external, 116, **117, 121, 126, 293**

Heavy-face type denotes plates illustrating the subject named

Intercostal muscle, internal, 116, **117, 121, 126, 293**
nerve supply, 119, 120
N., 130, **219, 226, 287**
abdominal, 284
diagram, **132, 134, 285**
lower, 135
six, 284
upper, 135
spaces, 115
V., 129, **219, 226**
superior, 129, **170, 178, 183, 185, 219, 221, 226**
lower left, 130
upper left, 129
right, 129
Intercosto-brachial N., 135
Intercosto-humeral N., 135
Intercuneiform joint, 29
Interlobar empyema, 213
Intermetatarsal joints, 30
Intermuscular hernia, 317
Internal lateral lig., knee-joint, 11
oblique M., 279, **297, 303, 314**
aponeurosis, **290**
Interosseous lig., 231, **22**
inferior, 17
superior, 17
talo-calcaneal, 23
membrane, 17
Interphalangeal joints, 31
Intersigmoid fossa, 370
Interspinal lig., 231
Intertarsal joints, 23
Intertransverse lig., 231
M., **540**
Interventricular A., 188
furrow, 187
septum, **190**
vein, posterior, 188, **185, 196**
Intervertebral substance, 230
Intestinal A., 428, 510
glands, 437
lymph trunk, 642
lymphatics, 439
Intestine, "Empty," 399
large, 401
blood supply, 442
capacity, 410
coats, 439
glands, 440
nerve supply, 442
position, 255
wall, 439
Intestine, small, 399, **424, 429, 547, 549, 581**
blood supply, 437
coats, 431
divisions, 399
injuries, 439
length, 399
nerve supply, 437
obstruction, 400
position, 255, 399
villi, 432
wall, 431
wounds, 400, 439
"twisted," 400
Intra-abdominal pressure, 331
Intra-aponeurotic space, anterior, 651
Intracapsular fracture femur, 54
Intralobular V., 476
Intraparietal hernia, 317
Introitus vaginæ, 622
Intussusception, 442
Invagination, 442
Inversion uterus, 613
Ischio-capsular lig., 2
Ischio-cavernosus M., 662, 722, **658, 663, 718, 720**
Ischio-femoral lig., **540**
Ischio-perineal lig., 724
Ischio-rectal abscess, 659
fascia, 560, 561, 656
Ischio-rectal fossa, 647, 655, **558, 654**
Ischium, 543
Isthmus of uterus, 611

J

Jaboulay oper., 704
Jackson's membrane, 370
Jejunum, 399, **372, 422**
fistula, 400
suspensory lig., 358
Joint, acromino-clavicular, 98
ankle, 18
astragalo-scaphoid, 25
calcaneo-astragaloid, 23
posterior, 24
calcaneo-cuboid, 25
costo-chondral, 232
cubo-cuneiform, 29
cubo-metatarsal, 30
cubo-navicular, 26
cubo-naviculo-cuneiform, 26
foot, 64
hip, 1, **3**
interchondral, 232
Joint, intercuneiform, 29
intermetatarsal, 30
interphalangeal, 31
intertarsal, 23
knee, 6, **7, 10**
lower extremity, 1
medio-tarsal, 25
metatarso-phalangeal, 31
naviculo-cuneiform, 26
scapho-cubo-cuneiform, 26
scapho-cuboid, 26
scapho-cuneiform, 26
sterno-clavicular, 98
talo-calcaneal, 23, 24
talo-navicular, 25
tarso-metatarsal, 29
thorax, 229
tibio-fibular, distal, 17
inferior, 17
proximal, 16
superior, 16
Jugular V., internal, **178**

K

Kidney, 490, **366, 372, 454, 466, 491, 502**
blood supply, 503
calices, 503
capsule, 495
columns of Bertini, 496
diagram, **494**
floating, 490, 504
hilum, 496, **499**
infundibula, 503
lymphatics, 503
malpighian bodies, 496
movable, 490, 504
nerve supply, 503
pole, 496
position, 254, 410, 490
sections, **499**
sinus, 496, **497**
structure, 496
wandering, 490
Knee, dislocation, 40
Knee-joint, 6, **7, 10**
affections, 16
amputation, 71
blood supply, 14
bursæ, 16
effusions, 16
excision, 46
ligaments, 6
movements, 15
nerve supply, 15
pain, 16

Knee-joint, synovial membrane, 14
Kocher's incision, 292, 478

L

Labia majora, 714
minora, 714
Labial hernia, 318
N., posterior, 722, **718, 720**
Labium majus, **624, 712**
Labium minus, **609, 624, 712**
Labrum glenoidale, 2
Lacerated perineum, 625
Laceration perineum, 732
Lacteals, 439
Lacuna magna, 693, 688
Lacunæ, 693
Lane's kink, 370
Laryngeal N. recurrent, **143, 157, 217, 221**
left, 159
right, 159
Lateral lig. of liver, 353, 386
left, **469**
right, **469**
Latissimus dorsi M., **268, 278, 290, 329**
Lee's amputation, 71
Left lobe liver, 474, **469, 471, 514, 518**
Leg amputation, 68, **70**
Lembert suture, 485
Lesser omentum, 358
peritoneal cavity, 351
Levator ani M., 637, 674, 731, **558, 586, 605, 636, 663, 675, 678, 728**
prostatae M., 674
Levatores costarum M., 119
Lien, 392
Lieno-renal lig., 354, 397, **366**
Ligament, acetabular, 3
acro-uterine, **615**
annular anterior ankle-joint, 20
external ankle-joint, 20
ano-coccygeal, 580
appendiculo-ovarian, 367, **552, 627**
arcuate, external, **533**
internal, **533**
of pubis, 673
astragalo-scaphoid, 25, **22**
Ligament, bifurcate, 26
of Bigelow, 2
broad, 350, 617
contents, 617
calcaneo-astragaloid, external, 24, **22**
internal, 24
posterior, 24
calcaneo-cuboid, dorsal, 26, **22**
internal, **22**
interosseous, 26
long, 25
plantar, 26, **22**
calcaneo-fibular, 19, **22**
calcaneo-navicular, 25
plantar, 24, 25, **22, 27**
calcaneo-scaphoid external, 24, 25, **22**
inferior, 25, **22, 27**
capsular, hip-joint, 1, **3**
knee-joint, 12, **7**
vertebrae, 230
chondro-sternal, anterior, 232
collateral patellar, 12
common, anterior, 230
posterior, 230
coronary, 14, **7**
of liver, 353, 386, **366, 381**
costo-colic, **366**
costo-sternal, posterior, 232
costo-transverse, anterior, 231
middle, 231
posterior, 231
costo-vertebral anterior, 231
cotyloid, 2, **3**
cruciate anterior, 13, **7**
posterior, 13, **7**
cubo-navicular, 26
dorsal, **22**
cubo-scaphoid, dorsal, **22**
deltoid, 19, **22, 27**
duodeno-hepatic, 358
external lateral knee-joint, 12
falciform of liver, 353, **271, 355, 366, 381**, 386
fibular collateral, 12, **10**
gastro-colic, 388
gastro-hepatic, 388
Ligament, gastro-phrenic, 354, 358, 388, **366**
gastro-splenic, 388, **366, 420, 422**
genito-inguinal, 311
Gimbernat's, 274, **275**
head of fibula, 17
anterior, 17
posterior, 17
hip-joint, accessory, 1
ilio-femoral, 2, **3**
ilio-lumbar, **540**
infundibulo-pelvic, 618, 629
inguinal, 274, **235, 275, 290, 293, 297, 299, 303, 329, 568**
reflected, 274
interarticular, 231
internal lateral, knee-joint, 11
interosseous, 231, **22**
superior, 17
talo-calcaneal, 23
interspinal, 231
intertransverse, 231
ischio-capsular, 2
ischio-femoral, **540**
ischio-perineal, 724
lateral, 617
external, ankle-joint, 19
internal, ankle-joint, 19
of liver, 353, 386
malleolus, anterior, 17
posterior, 18
lieno-renal, 354, 397, **366**
liver, coronary, 342, **469**
falciform, **469**
lateral, 342
left, **469**
right, **469**
round, 386, **469, 471, 487**
triangular, 342
left, **469**
right, **469**
longitudinal anterior, 230
posterior, 230
lumbo-sacral, **540**
metatarsal transverse, 30
of neck of rib, 231
oblique popliteal, 12, **10**

Ligament, ovario-pelvic, 629
ovary, 619, 629
pectineo-femoral, **540**
perineal transverse, 667
peritoneal, 353
of bladder, 354
phrenico-colic, 354, 369, 397, **366**
phreno-colic, 407
plantar, long, 25, **22, 27**
short, 26, **22, 27**
posterior knee-joint, 11
Poupart's, 274, **126, 235, 275, 278, 290, 293, 297, 299, 303, 329, 568**
pubo-capsular, **2, 3**
pubo-femoral, **2, 3**
pubo-prostatic, 561, 591
pubo-vesical lateral, 590, 591
middle, 591
pulmonary, 147, 152, 213, **157, 170, 173**
recto-coccygeal, **636, 730**
recto-uterine, 618, **571, 615**
of rectum, 561
reflected inguinal, **299**
round of liver, 386, **355, 366, 381, 383**
uterus, 618, **571, 627**
sacro-iliac, superior, **540**
sacro-lumbar, **540**
sacro-sciatic, great, **658**
sacro-tuberous, **658, 675, 678, 728**
sacro-uterine, **571**
scapho-cuboid dorsal, 26
stellate, 231
sternal-anterior, 232
posterior, 232
sterno-pericardiac, 179
inferior, **121**
superior, **121, 139**
subpubic, 673
supraspinal, 230
suspensory of clitoris, **718, 720, 725, 728**
duodenum, 457
ileum, 358
jejunum, 358
liver, 353, 386, **355, 366, 381**
ovary, 629
Ligament, suspensory, penis, 262, **266, 271, 303, 549, 581, 691**
spleen, 354, 397
talo-calcaneal, anterior, 24
lateral, 24
medial, 24
posterior, 24
talo-calcanean, lateral, **22**
talo-fibular, anterior, 19, **22**
posterior, 19, **22**
talo-navicular, 25, **22**
teres uteri, **627**
tibial collateral, 11
tibio-fibular anterior, 17
posterior, 17
posterior-superior, **10**
transverse, **2**
distal, 18
knee-joint, 14, **7**
of Treitz, 457
triangular, 560, 724, **271, 299, 663, 665**
of abdominal wall, 274
of liver, 353, 386, **366, 381**
superior layer, 674
tubercle of rib, 231
tubo-ovarian, 630
umbilical lateral, 327
median, 327
middle, 590, 591, **552, 627**
utero-ovarian, 619, 629
utero-pelvic, 619
utero-sacral, 342, 619
uterus, broad, 342, 559
lateral, 342
round, 618, **554, 609, 615**
vena cava, 180
vertebral bodies, 230
vesico-uterine, 617
of Winslow, 11
Y. of Bigelow, **2**
Ligamenta alaria, 13
flava, 230
subflava, 230
Ligamentous A., 511
Ligaments, false, of bladder, 354
bladder, false, 590, 592
lateral, 556
Ligaments, bladder, false, posterior, 556
superior, 556
true, 591
anterior, 561
lateral, 561, 589
superior, 590
foot, **27**
tarsus, **22**
uterine, 617
uterus, false, 342
Ligamentum arcuatum externum, 535
internum, 532
laciniatum, 20
lacunare, 274, **275**
latum pulmonis, 147, 152, **213, 157, 170, 173**
mucosum, 13, **7**
patellæ, 11
radiatum, 231
teres, 1, 327, 386
femoris, **2, 3**
venosum, 473
Ligation, aorta, abdominal, 515
dorsalis pedis A., 94
femoral A., 81, **83**
superf., 85
iliac A., common, 562
external, 632, **564**
innominate A., 166
mammary A., internal, **100**
peroneal A., 90
popliteal A., 85
tibial A., anterior, 90, **91**
posterior, 89, **88**
Limbus fossæ ovalis, 192
Line, axillary, 105
anterior, 105
posterior, 105
for aorta, abdominal, **241**
epigastric A., deep, **241**
inferior, **241**
iliac A., common, 251, **241**
external, 251, **241**
stomach curvature, greater, 254
lesser, 254
mammillary, 105
midaxillary, 105
mid-clavicular, 105
mid-sternal, 105

Line of incision, crural N., anterior, 80
dorsalis pedis A., 80
femoral A., common, 80
superf., 80
musculo-cutaneous N., 80
peroneal N., superf., 80
saphenous N., 80
tibial A., anterior, 80
parasternal, 105
pleura, 111
scapula, 105
sternal, 105
Linea alba, 234, 273, **235, 266, 268**
incision through, 234
semicircularis, 237, 280, 291, **266, 268, 290**
terminalis, 544
Lineæ albicantes, 234
transversæ, 237, **235, 266, 268**
Lisfranc's amputation, 62, 64
Liver, 467, **355, 412, 420, 422, 469, 471, 487**
abscess, 385
accessory, 473
blood supply, 475
common duct, 477
fissure, 468
ductus venosus, 473
gall-bladder, 473
longitudinal, 468, **471**
sagittal, left, 468, **471**
transverse, 473
umbilical, 473
vena cava, inferior, 473
fossa gall-bladder, 473
lig., 385
coronary, 342, 353, 386, **381, 469**
falciform, 353, 386, **381, 469**
lateral, 342, 353
left, 386, **469**
right, 386, **469**
round, 327, 386, **379, 383, 469, 471, 487**
supensory, 353, 386, **381**
triangular, 342, 353, 386, **381**
left, **469**
right, **469**
lobe, caudate, 474, 383, **471, 514**
Liver, lobe, left, 474, **383, 454, 466, 469, 471, 514, 518**
quadrate, 474, **383, 471**
right, 473, 514, **383, 454, 466, 469, 471**
spigelian, 474, **383, 471, 514**
lobes, 473
lymphatics, 474
nerve supply, 475
outline, 252
position, 252, 328
relations, 378
rupture, 385
structure, 476
surfaces, 468
vessels, 474
Lobes, liver, 473
lungs, 212
Longitudinal fissure, liver, **471**
lig., anterior, 230
posterior, 230
Lower extremity, excisions, 45
joints, 1
Lumbar A., 511, **502**
fascia, **290, 329, 454, 527, 533**
ganglion, **518, 520, 598**
lymph glands, 640
trunk, 641
nerve, 524, **518, 525, 527, 598, 603**
plexus, 524, **525, 527, 603**
rib, 114, 532
spine, 531
triangle, 265, **268**
V., ascending, 516, **226, 502**
veins, 516
Lumbo-costal arch, lateral, 535, **533**
medial, 532, **533**
Lumbo-dorsal fascia, **290, 329, 533**
Lumbo-inguinal N., 530, **275**
Lumbo-sacral lig., **540**
N. plexus, 524
trunk, 531, 602, **525, 527, 603**
Lung abscess, 213
hernia, 214
left, 221, **204, 206, 219**
mediastinal surface, 210
right, **204, 206, 219**
mediastinal surface, 208
Lungs, 211, **143, 157, 173**
apex, 211
base, 211
blood supply, 214
border, anterior, 212
posterior, 212
color, 214
consistency, 214
diagram, **243, 245, 247, 249, 334**
emphysematous, 215
hilum, 212
infarction, 215
lobes, 212
nerve supply, 214
position, 108, **104**
relations, 108
roots, 213, **178**
surface, costal, 211
medial, 211
weight, 214
wounds, 215
Lunula, 197, **199**
Luxation, see Dislocation.
Lymph glands, abdominal wall, 639
cardiac, 176
celiac, 641
gastric, 641
gastro-epiploic, 642
hepatic, 641
hypogastric, 640
ileo-colic, 642
iliac, 640
inguinal, 263
intercostal, anterior, 137
external, 137
posterior, 137, 229
lumbar, 640
mammary, internal, 137, **121**
mediastinal, anterior, **121**
posterior, 229
mediastinum, superior, 176
mesenteric, 364, 642
mesocolic, 642
paracardial, 641
pelvic wall, 639
psoas, 641
sacral, 640
splenic, 642
sternal, **121**
subpyloric, 642
suprapancreatic, 642

Lymph glands, thoracic wall, 137
visceral, 641
Lymphatics, abdomen, 638
abdominal wall, 638
superf., 263
bladder, 592
diaphragmatic, 137
Fallopian tube, 631
intercostal, 137
intestinal, 439
kidney, 503
liver, 474
mediastinum, anterior, 141
ovary, 630
pelvis, 638
penis, 639
pericardium, 180
pleura, 148
prostate, 595
scrotum, 639, 698
spleen, 398
stomach, 392, 484
thoracic wall, 137
ureter, 504
uterus, 614
vagina, 625
vermiform appendix, 441

M

McBurney incision, 301, 450
point, 405
Malformations, penis, 696
rectum, 584
urethra, 696
Malleolus, fracture, 58, 60
Malpighian bodies, 496, 499
pyramids, 503
Mammary A., internal, 101, 120, 121, 126, 139, 150, 157, 293
ligation, 100
lymph glands, internal, 137, 121
region, 105
vein, internal, 127, 150, 178, 183, 185
Mammillary line, 105
Manubrium sterni, 112, 121
relations, 101
Marginal A., 188, 185, 196
cusp, 194
Margo acutus, 187
obtusus, 187
Mayo operation, 323
Meatus, external, 624
urinary, external, 684, 692, 715, 690
Meckel's diverticulum, 238, 401
Mediastinal A., 123, 121
posterior, 224
"flutter," 148
lymph glands, anterior, 121
posterior, 229
pleura, 145
Mediastinotomy, posterior, 175
Mediastinum, 138
anterior, 138, 139, 173
lymphatics, 141
neoplasm, 141
middle, 142, 179
posterior, 142, 216, 170, 217, 219, 221
lymph glands, 229
superior, 142
structures in, 157
testis, 707
Medio-tarsal joint, 25
Medullary pyramids, 503
Meissner's plexus, 438
Membrane, interchondral, 116
intercostal, anterior, 136
external, 116
posterior, 116, 136
Membranous urethra, 669, 691
Meniscus, lateral, 13
medial, 13
Mesenteric A., inferior, 240, 329, 428, 511, 361, 366, 372, 429, 454, 459, 491, 502, 547, 568
superior, 240, 426, 464, 510, 329, 359, 366, 424, 429, 454, 459, 466, 491, 502
ganglion, superior, 518, 520, 598
glands, 364
tuberculosis, 364
hernia, 363
lymph glands, 642
N. plexus inferior, 524, 518, 598
superior, 523, 518, 520, 598
vein, inferior, 428, 467, 329, 361, 424, 429, 466
superior, 426, 467, 329, 424, 454, 459, 466
Mesentery, 341, 358, 361, 372, 376, 379, 403, 547
of appendix, 364
attachment, 363, 366
openings, 363
position, 255
Mesentery, root, 329, 366
testicle, 311
Meso-appendix, 364, 442, 376, 379, 547
Mesocecum, 369
Mesocolic hernia of Cooper, 368
lymph glands, 642
Mesocolon, ascending, 367, 366
descending, 367, 329, 366
pelvic, 369, 410, 366
transverse, 341, 368, 406, 366, 372, 422, 429
Mesorchium, 311, 370
Mesosigmoid, 341, 369, 408, 410, 329, 366, 554
attachment, 409
Mesosternum, 112
Metasternum, 112
Metatarsal excision, 52
development, 53
dislocation, 45
fracture, 61
lig. transverse, 30
Metatarso-phalangeal joints, 31
Meyer's line, 36
Midaxillary line, 105
Mid-clavicular line, 105
Mid-sternal line, 105
Mitral valve, 198, 173, 196
position, 108, 107
Moderator band, 194, 190
Monorchism, 708
Mons pubis, 261, 713
veneris, 261, 713
Movable kidney, 490, 504
Mucous membrane intestine, small, 432
Muscle, accelerator urinæ, 661, 549, 581, 658
adductor brevis, 73
longus, 73, 83
magnus, 73, 75, 605, 658
band, longitudinal, 374, 376, 379
biceps femoris, 73, 75
bulbo-cavernosus, 661, 722, 549, 581, 658, 718, 720
coccygeus, 586, 636, 637, 730
compressor urethrae, 668, 731, 549, 581
cremaster, 280, 283, 303, 271, 295, 297, 299
crureus, 73, 75
erector clitoridis, 722, 718, 720

Muscle, erector penis, 662, 658, 663
spinae, 329
extensor digitorum longus, 70, 91
hallucis longus, 91
flexor digitorum longus, 70, 88
hallucis longus, 70
gastrocnemius, 70
gemellus, inferior, 605
gluteus maximus, 605, 658, 663, 675
medius, 605
minimus, 605
gracilis, 73, 75, 658
iliacus, 542, 403, 454, 527, 540, 558, 568, 605
infracostal, 119, 217, 219
intercostal, 117
action, 120
external, 116, 293, 117, 121, 126, 139
internal, 116, 117, 121, 126, 293
nerve supply, 119, 120
intertransverse, 540
intestine, small, 432
ischio-cavernosus, 662, 722, 658, 663, 718, 720
latissimus dorsi, 268, 278, 290, 329
levator ani, 637, 674, 731, 558, 586, 605, 636, 658, 663, 675, 678, 728
raphe, 581
prostatæ, 674
levatores costarum, 119
oblique, external, 265, 266, 268, 271, 278, 527
internal, 279, 126, 271, 278, 287, 293, 297, 303, 314, 527
aponeurosis, 280
obturator externus, 540
internus, 638, 558, 586, 605, 658, 675, 678, 728
of Oddi, 414
papillary, anterior, 190
compound, 196
posterior, 190
right, 190
pectinate, 190
pectineus, 73
Muscle, pectoralis major, 266
minor, 268
transverse, 658, 718, 720
deep, 668, 731, 725
superficial, 662, 772
peroneus longus, 70
plantaris, 70
origin, 10
psoas, 314, 329, 403, 558
magnus, 541, 502, 527, 533, 540
major, 541, 491, 527, 533, 540, 568, 605
minor, 542, 527, 540
pubo-vesical, 590, 549, 581
pyramidalis, 302, 287
pyriformis, 540, 605, 636
quadratus femoris, 540, 605
lumborum, 543, 329, 454, 491, 527, 533, 540
recto-coccygeal, 583
rectus abdominis, 301, 126, 275, 287, 290, 293, 329, 487
sheath, 280, 287, 290, 293
femoris, 73
sacro-spinalis, 329
sartorius, 73, 75, 83
semimembranosus, 73, 75
semitendinosus, 73, 75
serratus anterior, 266, 268, 287
magnus, 266, 268, 287
soleus, 70, 88
sphincter ani, 549, 581
external, 655, 554, 654, 658, 663, 675, 718, 720
internal, 583, 554
of bladder, internal, 590
urethræ, 668, 731, 549, 581, 665
vaginæ, 722, 718, 720
vesicæ, 636, 730
subcostal, 119
tibialis anterior, 70, 91
posterior, 70
trachealis, 171
transversalis, 291, 126, 287, 290, 293, 299, 314, 454, 527, 533, 568
aponeurosis, 291, 290
transversus abdominis, 533
thoracis, 120, 121, 139
Muscle of Treitz, 400
triangularis sterni, 120, 121, 139
vastus externus, 73
intermedius, 73, 75
internus, 73
lateralis, 73, 75
medialis, 73, 75
Muscularis mucosæ, 432, 483
Musculi papillares, 194
pectinati, 193
Musculo-cutaneous N., 70
line of incision, 80
Musculo-phrenic A., 124, 121, 123, 139
Myenteric plexus, 438

N

Nabothian cysts, 613
Naviculo-cuneiform joint, 26
Neck of penis, 684
Negro-heel, 34
Neoplasm, mediastinum, anterior, 141
Nephrectomy, 505
Nephrolithotomy, 506
Nephroptosis, 504
Nephrorrhaphy, 504
Nephrotomy, 506
Nerve, cardiac, cervical, inferior, 159
superior, 159
sympathetic inferior, 157
middle, 157
superior, 157
inferior, 161
middle, 160
superior, 160
thoracic, 159
cavernous, 601
coccygeal, 525, 603, 605
crural, 530, 275
anterior, 531, 518, 525, 527, 558, 598, 603
cutaneous, abdominal wall, 264
anterior, 284, 529
external, 530, 525, 527
lateral, 530, 266
middle, 527
of thigh, posterior, 607
dorsal of clitoris, 718, 720, 725
of penis, 673, 658, 663, 665, 671

Nerve, dorsi-lumbar, **525, 527, 603**
femoral, 531, 518, **525, 527, 558, 603**
genital, 530, **275**
genito-crural, 530, **275, 525, 527, 603**
genito-femoral, 530, **275, 525, 527, 603**
gluteal, cutaneous, 601
inferior, 607, **525, 603, 605**
superior, 607, **525, 603, 605**
hemorrhoidal, inferior, 607, 656, **654, 658**
hypogastric, 264, 284, 529
iliac, 284, 529
ilio-hypogastric, 284, 529, **266, 271, 287, 295, 303, 525, 527, 603**
ilio-inguinal, 264, 284, 529, **266, 271, 287, 295, 303, 525, 527, 603**
intercostal, 130, **219, 226, 287**
abdominal, 284
diagram, **132, 134, 285**
lower, 135
six, 284
upper, 135
intercosto-brachial, 135
intercosto-humeral, 135
labial, posterior, 722, **718**
laryngeal, recurrent, **143, 150, 157, 178, 217, 221**
left, 159
right, 159
lumbar, 524, **518, 525, 527, 598, 603**
lumbo-inguinal, 530, **275**
lumbo-sacral, 602, **527**
musculo-cutaneous, **70**
obturator, 530, **73, 525, 527, 568, 603**
accessory, 531, **525, 603**
pelvic, 599
perineal, 601, 607, 673, **654, 658, 718, 720**
anterior, 660
long, 660, 722, **525, 605, 654**
superficial, 722
transverse, **720**
peroneal, common, 602
Nerve, peroneal, deep, **70, 91**
superf., **70**
phrenic, 201, **143, 157, 173**
accessory, 155
left, 155
right, 155
plexus, aortic, 524, **518, 527, 598**
brachial, **520**
cardiac, **520**
cavernous, 600
celiac, 522, 523, **518, 527, 598**
coccygeal, 601
coronary, **518, 520, 598**
diaphragmatic, 522, **527**
epigastric, 522
esophageal, **518, 520, 598**
gastric, 523
hemorrhoidal middle, **518, 598**
hepatic, 523
hypogastric, 600, **518, 527, 598**
inferior, 600
lumbar, 524, **525, 527, 603**
lumbo-sacral, 524
mesenteric, inferior, 524, **518, 598**
superior, 523, **518, 520, 598**
pelvic, 600, **598**
left, **518**
right, **518**
phrenic, 522, **527**
prostatic, 600
pudendal, 601
renal, 523, **518, 520, 598**
sacral, 601, **518, 527, 568, 571, 598, 603, 605**
sciatic, **571, 615**
solar, 522, **518, 527, 598**
spermatic, 524
splenic, 523
suprarenal, 523
sympathetic, **598**
uterine, 601
utero-vaginal, 601
vaginal, 601
vesical, **518, 598**
popliteal, external, 602
internal, 602
Nerve, pudendal, 673, **525, 603**
inferior, 722, **525, 654, 718**
long, 660, **605**
pudic, **605**
pulmonary, 160
recurrent, **143, 150, 157, 178, 217, 221**
left, 159
renal, 229
sacral, 601, **518, 525, 598, 603, 605**
saphenous, **70, 73, 83, 527**
internal, **70**
sciatic, 602, **73, 75, 518, 525, 598**
great, 602
small, 607
scrotal, posterior, 660, **605, 658**
spermatic, external, 530, **275**
splanchnic, greater, 229, **219, 518, 520, 527, 598**
lesser, 229, **518, 520, 527, 598**
lowest, 229, **518, 520, 527**
smallest, 229, **598**
sympathetic, abdominal, **518**
gangliated trunk, **518**
thoracic, **518, 525, 527, 598, 603**
tibial, 602, **70**
anterior, **70, 91**
posterior, **70, 88**
vagus, **143, 150, 157, 170, 173, 178, 217, 219, 598**
left, 159, **518, 520**
right, 156, **518, 520**
Nucleus pulposus, 230
Nymphæ, 714

O

Oblique, M., external, 265, 266, **268, 271, 278, 290, 527**
aponeurosis, 270, **266, 271**
blood supply, 265
nerve supply, 265
internal, 279, **126, 271, 278, 287, 293, 527**
action, 283

Oblique, M., internal, aponeurosis, 280
blood supply, 280
nerve supply, 280
popliteal lig., 12, **10**
sinus, 179
vein of atrium, 155, 191
Marshall, 155, 180, 191
Obliterated hypogastric A., **355**
Obstetrical inlet, 544
outlet, 545
Obturator A., 573, **275, 568, 571, 615**
abnormal, 566, 574
anomalous, 305
canal, 573, **275, 586, 636, 730**
externus M., **540**
fascia, 560, **558, 586, 636, 654, 718, 720, 730**
internus M., 638, **558, 586, 605, 658, 675, 678, 728**
membrane, **275, 540**
N., 530, 531, **73, 525, 527, 568, 603**
accessory, 603, **525**
Omega loop, 408
Omenta, 354
Omental bursa, 338, 351
peritoneum, 350
hernia, 357
tuberosity, 474
Omentum, gastro-colic, 350, 354
vessels, 418
gastro-hepatic, 341, **422**
gastro-phrenic, 358
gastro-splenic, 397, **420, 422**
greater, 341, 354, 388, **355, 359, 361, 412, 420, 422, 429, 514, 549, 581**
adhesions, 357
cavity, 351
rent, 357
vessels, 418
lesser, 341, 358, **412**
Operation, amput., Chopart's, 62, 66
foot, 62
Hey's, 66
hip-joint, 77
knee-joint, 71
Lee's, 71
leg, 68, **70**
Lisfranc's, 62, 64
penis, 695
Operation, amput., phalanges, 62
Pirogoff's, 62, 68
Stokes-Gritti, 72
Syme's, 62, 67
Teale's, 71
thigh, 72, **73, 75**
toes, 62
Andrews bottle, 707
appendicectomy, 449
Bassini's, 321
Bevan, 710
Billroth I., 391
Billroth II., 391
Bull's, 321
castration, 709
cecostomy, 452
cholecystectomy, 479
cholecystenterostomy, 480
cholecystoduodenostomy, 480
cholecystogastrostomy, 480
cholecystostomy, 478
choledochostomy, 479
circumcision, 695
Cock's urethrotomy, 646
Coley's, 321
colostomy, 451
lumbar, 452
colporrhaphy, anterior, 626
Downe's, 322
duodenotomy, 458
Duval-Barasty, 113
Emmett, 626
Excision, ankle-joint, 51
astragalus, 51
calcaneus, 51
carcinoma, esophagus, 175
cervical rib, 115
hip-joint, 45
knee-joint, 46
metatarsal, 52
os calcis, 51
patella, 51
phalanges, 52
pylorus, 391
talus, 51
ulcer duodenum, 457
Ferguson's, 321
gall-bladder, 478
Gallie's, 321
gastrectomy, 391
gastro-enterostomy, 391, 489
gastro-jejunostomy, 391
gastrostomy, 391, 485
Witzel's, 485
Operation, gastrotomy, 390, 485
Halsted's, 322
hernia, inguinal, 319
strangulated, 320
umbilical, 323
hydrocele, 704
hysterectomy, 619
vaginal, 620
Jaboulay for hydrocele, 704
ligation aorta, abdominal, 515
dorsalis pedis A., 94
femoral A., 81, 83
superf., 85
iliac A., common, 562
external, 632, 564
innominate A., 166
mammary A., internal, 100
peroneal A., 90
popliteal A., 85
tibial A., anterior, 90, **91**
posterior, 89, 88
McBurney's, 450
Mayo, 323
mediastinotomy, posterior, 175
nephrectomy, 505
nephrolithotomy, 506
nephrorrhaphy, 504
nephrotomy, 506
paracentesis pericardium, 141
perineorrhaphy, 626
phrenicotomy, 156
Polyá, 391
Poole's, 181
prostatectomy, perineal, 679
pylorectomy, 391, 486
pyloroplasty, 390, 486
Rammstedt's, 391
resection rib, 151
splenectomy, 398
talipes calcaneus, 37
equino-varus, 35
equinus, 37
valgus, 36
varus, 36
tenotomy tendo Achillis, 20
thoracentesis, 129
thoracotomy, 151
ulcer duodenum, 457
urethrotomy, external, 646
varicocele, 710
Witzel's, 391

Heavy-face type denotes plates illustrating the subject named

Operation, Young's, 679
Orchitis, 708
Organ of Gilaldés, 713
Rosenmüller, 630
Os calcis, dislocation, 42
excision, 51
fracture, 61
Os uteri, external, 611
internal, 613
Ovarian A., 511, 571, 614, 466, 615
fimbria, 630
vein, 516, 629, 454, 466, 491
Ovaries, 626
Ovario-pelvic lig., 629
Ovary, 626, 554
blood supply, 629
lig., 619, 629
suspensory, 629
lymphatics, 630
nerve supply, 630
removal, 631
Oviducts, 630
Ovules of Naboth, 613

P

Pain, knee-joint, 16
Palpation, abdomen, 251
Pampiniform plexus, of veins, 308, 700, 702
Pancreas, 458, 359, 366, 420, 422, 424, 429, 454, 482, 514
accessory, 463
blood supply, 463
body, 458, 454, 459, 461
cyst, 463
duct, 458
accessory, 458
head, 458, 454, 459, 461
nerve supply, 463
position, 254
relations, 458
surgery, 463
tail, 458, 454, 459, 461
Pancreatic A., 464, 509, 510
duct, 459, 461
accessory, 461
parvæ A., 510
Pancreatica Magna A., 510
Pancreatico-duodenal A., inferior, 426, 464, 510, 424, 454, 466
superior, 416, 509, 454
vein, 416
Panniculus adiposus, 261
Pantaloon type hernia, 320
Papilla, duodenal, 414, 478
renal, 503
of Vater, 414, 478, 461
Papillary M., anterior, 190
compound, 196
posterior, 190
right, 190
Paracardial lymph glands, 641
Paracentesis, pericardium, 141, 181
Paradidymis, 713
Paraphimosis, 695
Pararectal fossa, 580
Parasternal line, 105
Paravertebral dorsal block, 136
Parovarium, 630
Patella, development, 53
dislocation, 39
excision, 51
fracture, 58
Patellar, synovial fold, 13, 7
Patellar-condylar joint, 15
Pectinate M., 190
Pectineo-femoral lig., 540
Pectineus M., 73
Pectiniform septum, 683, 688, 690
Pectoralis major M., 268
minor M., 268
Pelvic cavity, 332, 543, 374, 376
axis, 546
cellulitis, 559
colon, 408
diaphragm, fascia, 560
fascia, 559
diagram, 558
inclination, 544
N. plexus, 600, 518, 598
left, 518
Pelvis, aperture, inferior, 544
superior, 544
arteries, 561
contents, 546
diameter, anteroposterior, 544
conjugate, 544
intercrestal, 546
interspinous, 546
oblique, 544
transverse, 544
false, 544
female, 546, 552, 554
inlet, 544
lymphatics, 638
major, 544
male, 546, 547, 581
contents, 546
Pelvis, minor, 544
muscles, 637
nerves, 599
obstetrical inlet, 544
outlet, 545
outlet, 544
peritoneum, 556
sexual differences, 546
true, 544
cavity, 545
of ureter, 503
position, 254
veins, 577
viscera, 579
Penis, 683, 658
amputation, 695
angle, 691, 549, 581
bodies, 682
bulb, 683, 581
crus, 690
diseases, 693
dorsal A., 575
epithelioma, 695
fascial sheath, 691
glans, 684
lymphatics, 639
malformations, 696
neck, 684
root, 684
section, 685, 688
skin, 684
suspensory lig., 69, 262, 266, 271, 303, 549
Perforating A., 124, 121, 126, 139
Pericardiac A., 123, 224, 121, 139, 185
vein, 150, 178
Pericardiaco-phrenic A., 123, 156, 157
Pericarditis, 180
Pericardium, 179, 121, 139, 150, 157, 178, 217
aspiration, 110
blood supply, 180
drainage, 181
lymphatics, 180
nerve supply, 178
paracentesis, 141, 181
Perineal A., 659, 721, 658, 663
superficial, 659, 721, 718
transverse, 660, 722, 658, 718
body, 715, 554
center, 646
hypospadia, 647
interspace, deep, 668, 724

Perineal, interspace, superficial, 651, 721
lig. transverse, 667
muscles, common tendon, 646
transverse, **658**
deep, 668, 731, **725**
superficial, 662
nerve, 601, 607, 673, **654, 658, 663, 718, 720**
long, 660, 722, **525, 603, 605, 654, 718**
superficial, 722
transverse, **658, 720**
prostatectomy, 679
raphe, 646
Perineorrhaphy, 626
Perinephric abscess, 490
fat, 490
Perineum, 713
fascia, superficial, 716
female, 713, **712**
laceration, 732
male, 645, **644**
central tendon, 646
fascia, superficial, 651, **650**
surface anatomy, 645
Peripleuritic abscess, 151
Perirenal fat, 326
Peritoneal cavity, 338
greater, 351
lesser, 350, 351
fossæ, 370
ligaments, 353
of bladder, 354
sac, 336
Peritoneum, 336, **581**
above colon, 349, **346**
absorptive power, 337
at epiploic foramen, **348**
attachments, 338
below colon, **343**
fetus, 351
folds, 353
hernial fossa, 315
parietal, 336
pelvic, 556
processes, 353
reflections, 338
traced vertically, 340
transverse course, 342
vertical course, 341
visceral, 336
Peritonitis, 338
localized, 337
Peroneal A., **70**
Peroneal A., ligation, 90
N. anterior, **91**
common, 602
deep, **70**
superf., **70**
line of incision, **80**
Peroneus longus M., **70**
Pes calcaneus, 35
cavus, 35
equino-varus, 34
equinus, 35
valgus, 35
Petit's triangle, 265, **268**
Peyer's patches, 437, **436**
Phalanges, amputation, 62
development, 54
dislocation, 45
excision, 52
fracture, 61
Phimosis, 695
congenital, 684
Phrenic A., 508, **454, 459, 491, 502, 514**
inferior, 508
superior, 123
ganglion, 155, 522, 537, **518, 520, 598**
nerve, 201, **143, 157, 173**
accessory, 155
left, 155
plexus, 522, **527**
right, 155
V., 521, **466, 502**
left, **491**
Phrenico-colic lig., 354, 369, 397, **366**
Phrenico-pleural fascia, 146
Phrenicotomy, 156
Phreno-colic lig., 407
"Phthisical chest," 97
Phthisis, 215
"Pigeon-breast," 97
Piles, 656
Pilonidal cysts, 647
Pirogoff's amputation, 62, 68
"Pit of the stomach," 98, 237
Plantar lig., long, 22, 25, **27**
short, 26, **22, 27**
Plantaris M., **70**
origin, **10**
Pleura, 145, **157, 170, 178, 217, 219**
aspiration, 111, **110**
blood supply, 147
cervical, 145
costal, 145
diaphragmatic, 145
line, 111
Pleura, lymphatics, 148
mediastinal, 145
nerve supply, 147
space, complemental, 146
surgery, 148
tumors, 151
Pleural sac, 111
cavity, 145
Pleurisy, 148
Pleuritis, 148
Pleuro-peritoneal cavity, 331
Plexus, Auerbach's, 438
brachial, **157**
cardiac, 161
great, 161
posterior, **217**
superf., 161, **157, 178**
coronary, 191, **157**
anterior, 161
left, 162
posterior, 162
right, 161
esophageal, 156, 227, **217, 219**
gulæ, 156, 227, **217, 219**
Meissner's, 438, 483
pulmonary, anterior, 162, **178**
posterior, **170, 221**
solar, 240
submucous, 483
sympathetic thoracic, 229
of veins, hemorrhoidal, 579
pampiniform, **700, 702**
prostatic, 594
uterine, 579, 614
utero-vaginal, 579
vaginal, 579
vesical, 579
vesico-prostatic, 578, **592, 581**
Plica gastro-pancreatica, 352
ureterica, **571, 615, 690**
Plicæ circulares, 400, 432
palmatæ, 613
recti, 584
Pneumatocele, 214
Pneumonia, 215
Pneumonitis, 215
Pneumothorax, 148
Polyá operation, 391
Pons hepatis, 386, 473
Poole's operation, 181
Popliteal A., **7**
ligation, 85
N., external, 602
internal, 602

Heavy-face type denotes plates illustrating the subject named

Popliteal vein, 7
Popliteus tendon, 10
Porta hepatis, 473
Portal vein, 474, 366, 383, 412, 420, 454, 459, 471, 482, 514
sinus, 418
Posterior lig. knee-joint, 11
Pott's fracture, 61
Pouch, Douglas, 342, 583, 609
recto-uterine, 342, 583, 611, 609, 615
recto-vaginal, 583
recto-vesical, 583, 589
utero-vesical, 342, 609
vesico-uterine, 615
Poupart's lig., 274, 126, 235, 275, 278, 290, 293, 297, 299, 303, 329, 568
line for, 80
Precordial dulness, 105
Prepatellar bursa, 7
Preperitoneal fat, 325, 314, 581
hernia, 317
Prepuce, 684
of clitoris, 714, 712
sphincter, 691
Preputium clitoridis, 624
Presternum, 112
Processus vaginalis, 311
Prolapse, uterus, 613
vaginal walls, 626
Prostate gland, 555, 593, 648, 549, 581, 586, 678, 690
blood supply, 595
capsule, 594, 675
furrows, 594
lobes, 594
lymphatics, 595
nerve supply, 595
structure, 595
Prostatectomy, perineal, 679
Prostatic ducts, 595
fissure, 595
ganglion, 600
N. plexus, 600
plexus of veins, 594
sinus, 595
urethra, 595, 691
utricle, 595, 596, 549, 581, 690
Psoas abscess, 538
lymph glands, 641
magnus M., 541, 502, 527, 533, 540
Psoas major M., 541, 491, 527, 533, 540, 568, 605
minor M., 542, 527, 540
M., 314, 329, 403, 454, 558
Pubic A., 305, 574
tubercle, 239
Pubis, 543
spine, 239
Pubo-capsular lig., 2, 3
Pubo-femoral lig., 2, 3
Pubo-prostatic lig., 561, 591
Pubo-vesical lig., lateral, 590, 591
middle, 591
M., 590, 549, 581
Pudendal A., internal, 574, 670, 568, 605, 615, 658, 663, 665, 671, 718, 725
cleft, 714
hematocele, 723
hernia, 732
N., 607, 673, 525, 603
inferior, 722, 525, 654, 718
long, 660, 605
plexus, 601
V., 579
external, superf., 260
internal, 673
Pudendum, 716
hydrocele, 732
Pudic N., 605
Pulmonary A., 168, 157, 183, 185, 190, 196, 208, 210, 221
left, 168, 178, 183
right, 168, 173, 178, 183
lig., 147, 152, 213, 157, 170, 173
N., 160
opening, 194
plexus, 162
anterior, 157, 178
posterior, 170, 219, 221
semilunar valves, 194
valve, 190
position, 108, 107
valves, 173
V., 150, 210, 221
left, 183, 185, 190, 196
right, 173, 178, 183, 185, 190, 196
Pylorectomy, 391, 486
Pyloric A., 416, 509, 412, 454, 482, 514
inferior, 509
sphincter, 484
Pyloric V., 416, 466
Pyloroplasty, 390, 486, 487
Pylorus, 484, 422, 482, 487
antrum, 387
digital dilatation, 390
excision, 391
Pyo-arthrosis, hip-joint, 6
Pyonephrosis, 504
Pyopneumothorax, 148
Pyothorax, 148
Pyramidalis M., 302, 287
Pyramids, Malpighian, 503
medullary, 503
renal, 503
Pyriformis M., 540, 605, 636, 730

Q

Quadrate lobe liver, 474, 383, 471
Quadratus femoris M., 540, 605
lumborum M., 543, 329, 454, 491, 527, 533, 540

R

"Rachitic rosary," 97
Rami communicantes, 525, 603
Rammstedt's operation, 391
Raphe levator ani M., 581
Receptaculum chyli, 176, 227, 439, 226
Recess, ileo-cecal, inferior, 377
superior, 377
Rectal examination, female, 647, 715
folds, transverse, 648
triangle, 645
Rectocele, 626
Recto-coccygeal lig., 636, 730
M., 583
raphe, 637
Recto-sigmoid curve, 408
tumors, digital examination, 409
Recto-urethral space, 679
Recto-uterine folds, 342
lig, 618, 571, 615
pouch, 342, 583, 611, 571, 609, 615
floor, 350
Recto-vaginal fistula, 626
pouch, 559, 583, 554
Recto-vesical fascia, 561, 586, 675, 678
fold, 592

Recto-vesical pouch, 341, 556, 583, 589
floor, 350
Rectum, 555, 580, **361, 366, 502, 518, 547, 549, 552, 554, 558, 568, 571, 581, 586, 598, 609, 615, 636, 678, 730**
ampulla, 580
arteries, 583
coats, 583
congenital defects, 647
embryology, 584
imperforate, 584
lig., 561
malformations, 584
position, 255
veins, 583
Rectus abdominis M., 301, **126, 275, 287, 290, 293, 329, 487**
blood supply, 301
incision, 301
nerve supply, 302
sheath, 280, 302, **281, 287, 290, 293**
femoris M., **73**
Recurrent N., 159, **143, 157, 217, 221**
left, 159
Reflected inguinal lig., 274, **295, 299**
Reflex, cremasteric, 283
Region, inframammary, 105
infrascapular, 105
mammary, 105
precordial, dulness, 105
sternal, 105
suprascapular, 105
supraspinous, 105
thoracic, lateral, 105
Regions of abdomen, 335
Renal abscess, 407
artery, 240, 510, **466, 491, 502**
supernumerary, 511
calculus, 504
corpuscles, 496
fascia, 490
ganglion, **518, 520, 598**
N., 229
plexus, 523, **518, 520, 598**
papillæ, 503
pyramids, 503
V., 503, 516, **466, 491, 502**
Resection, rib, 151
Rete testis, 707
testes, **706**
Retrocecal fossa, 378, **376, 379**
Retroflexion, uterus, 612
Retro-pubic space, 588, **549, 581**
Retroversion, uterus, 612
Ribs, 114
anomalies, 115
cervical, 114, 115
excision, 115
counting, 98
floating, 114
fracture, 114
lumbar, 114, 532
resection, 151
true, 114
Right lobe liver, 473, **469, 471 514**
Ring, abdominal, external, 239, **270, 268, 271**
internal, 239
femoral, **275**
fibrous of umbilicus, 273
inguinal, abdominal, 239
subcutaneous, 239, 270
Robson's point, 253
Roots of lungs, 213
Round lig. of liver, 327, 386, **355, 366, 381, 383, 469, 471, 487**
uterus, 618, **554, 571, 609, 615, 627**
Rupture, bladder, 559, 592
liver, 385
spleen, 398
urethra, 693
membranous, 692

S

Sac, peritoneal, 336
Sacral A., lateral, 576, **568, 571, 615**
inferior, 576
superior, 576
middle, 512, **568**
lymph glands, 640
N., 601, **518, 525, 598, 603, 605**
plexus, 601, 602, **518, 527, 568, 571, 598, 603, 605**
vein, middle, 579
Sacro-coccygeal cysts, 647
Sacro-genital folds, 341, 354, 556, 592
Sacro-iliac lig., superior, **540**
Sacro-lumbar lig., **540**
Sacro-sciatic lig., great, **658**
Sacro-spinalis M., **329**
Sacro-tuberous lig., **658, 675, 678, 728**
Sacro-uterine lig., **571**
Sagittal fissure liver, left, **471**
Saphenous A., short, **70**
N., **83, 527**
line of incision, 80
opening, **271, 295, 527**
V., external, **70**
great, **260, 271, 295**
internal, **70, 73, 88, 260, 271, 295**
Sartorius M., **73, 75, 83**
Scapho-cubo-cuneiform joint, 26
Scapho-cuboid joint, 26
lig., dorsal, 26
Scapho-cuneiform joint, 26
Scapula, line, 105
Scarpa's fascia, 261, 651
Sciatic A., 576, **568, 571, 615**
N., 602, **73, 75, 518, 525, 598, 603, 605**
small, 607
plexus, **571, 615**
Scoliosis, 98
Scrobiculus cordis, 98, 388
Scrotal A., posterior, 660
fasciæ, 698
hernia, 315
N., posterior, 660, **605**
Scroto-abdominal passageway, 261
Scrotum, 696, **658**
blood supply, 698
epithelioma, 697
integument, 697
lymphatics, 639, 698
nerve supply, 698
septum, **549, 581**
veins, 698
Semilunar cartilage, 13
external, 13
internal, 13
fold of Douglas, 280, 291, **290**
ganglion, 522, **518, 527, 598**
left, **520**
right, **520**
lines, **235**
valve, aortic, 198, **199**
nodule, 197
pulmonary, 194
Semimembranosus M., **73, 75**

Semimembranus tendon, **10**
Seminal vesicle, *555*, *596*, **558**, **586**, **678**
Semitendinosus M., **73**, **75**
Septal cusp, 194
Septum atriorum, 192
  crurale, 326
  femoral, 326
  interauricular, 192
  pectiniform, 683, **688**, **690**
  scrotal, **549**
  scrotum, **581**
  ventricular, 198
  ventriculorum, 193
Serratus anterior M., **266**, **268**, **287**
  magnus M., **266**, **268**, **287**
Sheath, rectus abdominis M., 280, 302, **281**, **287**, **290**, **293**
"Shoemaker's breast," 97
"Short-winded," *215*
"Shoulder-tip pains," *475*
Sibson's fascia, 108
Sigmoid A., 429, 431, *511*
  colon, 408
  flexure, *255*, 408, *555*, **361**, **429**, **547**, **549**, **552**, **581**, **627**
    course, 409
    volvulus, 410
  hernia, 377
Sinus of aorta, 163
  aortic, 163, 197
  auricle, right, 191
  coronary, 191, **173**, **196**
    orifice, 192
    valve, 192
  costo-phrenic, 146
  epididymis, 704
  kidney, 496, **497**
  oblique, 179
  pocularis, *595*, *596*, **549**, **581**, **690**
  portal vein, 418
  prostatic, *595*
  transverse, 180
  of Valsalva, 163, 197
Skene's ducts, 622
Skiagraphy, 323
Skin, abdomen, 234
Small intestine, 399, **359**, **361**
Smegma præputii, 684
Solar N., plexus, 240, *522*, **518**, **527**, **598**
Soleus M., **70**, **88**
Solitary glands, 437
"Soot wart," 697
Space of Retzius, *588*, **549**, **581**
Spasmodic stricture urethra, 694
Speculum examination, 716
Spermatic A., 308, *511*, **329**, **466**, **502**, **568**, **700**, **702**
    external, 305
    internal, *511*
  cord, 240, *275*, 307, 710, **126**, **266**, **287**, **293**, **295**, **297**, **299**, **700**
    coverings, 307
    formation, 311
    relations, 312
  duct, 308, *555*
  fascia, **700**, **702**
    external, 273, 697, **295**, **314**
    internal, 306, 698, **299**, **314**
    middle, 698
  N., external, 530, **275**
    plexus, *524*
  vein, *516*, **329**, **454**, **466**, **491**, **568**
    internal, *516*
Spermatocele, 713
Spermatorrhea, 709
Sphincter ani M., **549**, **581**, **663**
    external, *655*, **554**, **609**, **650**, **654**, **658**, **675**, **718**
    internal, *583*, **554**, **609**
  M. of bladder, internal, *590*
  prepuce, 691
  pyloric, 484
  urethræ M., 668, 731, **549**, **581**, **665**, **671**
  vaginæ M., 722, **718**, **720**
  vesicæ M., **636**, **730**
Spigelian lobe liver, 474, **383**, **471**, **514**
Spinal A., *512*
Spine, iliac, anterior superior, 239
  lumbar, *531*
  pubis, 239
Spiral valve, *415*, 477
Splanchnic anesthesia, *523*
  N., greater, 229, **219**, **518**, **520**, **527**, **598**
    lesser, 229, **518**, **520**, **527**, **598**
    lowest, 229, **518**, **520**, **527**
    smallest, 229, **598**
Spleen, 392, **366**, **420**, **422**, **454**, **466**, **494**
  blood supply, 398
  enlargement, *254*
  hilum, **395**
  hypertrophied, 398
  lateral surface, **393**
  lymphatics, *598*
  medial surface, **395**
  nerve supply, 398
  position, *254*
  rupture, 398
  surfaces, 397
  suspensory lig., 397
  weight, *254*
  wounds, 398
Splenectomy, 398
Splenic A., 398, 464, *509*, **366**, **395**, **420**, **422**, **454**, **459**, **466**, **482**, **502**, **514**
  flexure, *255*, 406
  lymph glands, 642
  N. plexus, *523*
  vein, 398, 464, **395**, **420**, **422**, **424**, **429**, **454**, **459**, **466**
Spongy urethra, 692
"Sprained ankle," 61
"Sprained fracture," 61
Status lymphaticus, *153*
Stellate lig., 231
Sterility, male, 709
Sternal angle, 98, 112
  A., 98, 112, 123, **121**, **139**
  lig., anterior, 232
    posterior, 232
  line, 105
  lymph glands, **121**
  region, 105
Sterno-clavicular joint, 98
  junction, 98
Sterno-pericardiac lig., 179
    inferior, **121**, **139**
    superior, **139**
Sternum, 112
  congenital defects, 114
  development, 112
  fracture, 113
  necrosis, 113
Stoke's-Gritti amputation, 72
Stomach, **355**, **359**, **412**, **420**, **482**, **487**, **514**, **518**, **520**, **598**
  acute dilatation, 389
  blood supply, 483, *592*
  body, 387
  cardia, **482**

Heavy-face type denotes plates illustrating the subject named

Stomach, cardiac end, 387
orifice, 253
coats, 480
cul-de-sac, greater, 387
fundus, 387, **482**
glands, 483
greater curvature, 387
injuries, 390
lesser curvature, 387
lymphatics, 392, 484
nerve supply, 392
position, 253
pyloric end, 387
orifice, 253
relations, 387, 388
structure, 480
surgical anatomy, 484
wounds, 390
Straight hernia, 318
Stricture, esophagus, 175
urethra, 694
"Subastragaloid dislocation," 42
Subcecal fossa, 378, **376, 379**
Subclavian A., **126, 143, 157, 293**
left, 167, **178**
right, **183, 185**
V., **150**
left, **178, 183, 185**
right, **183, 185**
Subcostal A., 223
M., 119
V., 129
Subcutaneous abdominal ring, 270
inguinal ring, **295**
Sublobular V., 476
Submucous plexus, 438
Subperitoneal fat, 325
Subpubic lig., 673
Subpyloric lymph glands, 642
Sulcus, coronary, 187
Suprapancreatic lymph glands, 642
Suprarenal A., 240, **466**
inferior, 510, **491, 502**
middle, 510, **491, 502**
superior, 510, **491, 502**
capsule, 506, **454**
gland, 506, **366, 454, 491, 502**
N. plexus, 523
V., 507, 521, **466, 502**
right, **491**
Suprascapular region, 105
Supraspinal lig., 230
Supraspinous region, 105
Supravesical fossa, 328
Sural A., **70**
Suspensorius duodeni, 457
Suspensory lig., of clitoris, **718, 720, 725, 728**
ileum, 358
jejunum, 358
liver, 353, **355, 366, 381, 386**
ovary, 629
penis, 262, 691, **266, 271, 295, 303, 549, 581**
spleen, 354, 397
Sustentaculum lienis, 369
Suture, Lembert, 485
Syme's amputation, 62, 67
Sympathetic ganglion, cervical, **157**
N., abdominal, **518**
gangliated trunk, **518**
plexus, **598**
thoracic, 229
trunks, pelvic, 599
system, abdominal, 521
Symphysis pubis, **549, 581**
Synovial membrane, ankle-joint, 19
hip-joint, 5
knee-joint, 14
Synovitis hip, 6

T

Talipes, 34
calcaneus, 35
operation, 37
cavus, 35
equino-varus, 34
operation, 35
equinus, 35
operation, 37
valgus, 35
operation, 36
varus, operation, 36
Talo-calcaneal dislocation, 42
joint, 23, 24
lig., anterior, 24
lateral, 24, **22**
medial, 24
posterior, 24
Talo-crural articulation, 18
Talo-fibular lig., anterior, 19, **22**
posterior, 19, **22**
Talo-navicular joint, 25
lig., 25, **22**
Talus, dislocation, 42
excision, 51
fracture, 61
Tarso-metatarsal joint, 29
blood supply, 30
movements, 30
nerve supply, 30
Tarsus, development, 53
dislocation, 45
fracture, 61
ligaments, **22**
Taxis, 317
Teale's amputation, 71
Tendinous inscriptions, 237, 301, **235, 266, 268**
Tendo Achillis, 20
rupture, 20
tenotomy, 20
calcaneus, 20
patellæ, 11
Tenotomy, tendo Achillis, 20
Testes muliebres of Galen, 626
Testicle, 703, **314, 700, 706**
atrophy, 708
blood supply, 708
dermoid cysts, 708
descent, 311
hilum, 703
inversion, 703
mesentery, 311
nerve supply, 708
non-descent, 708
section, **702**
structure, 707
torsion, 709
undescended, 703
Testicular A., 511
Thebesian valve, 191
Thigh amputation, 72, **73, 75**
Thoracalis suprena A., **126, 293**
Thoracentesis, 129
Thoracic aorta, 162, **173, 185, 216**
A., lateral, **126, 293**
long, **126, 293**
superior, **126, 293**
cavity, 138
duct, 176, 221, 227, **143, 150, 170, 173, 178, 185, 219, 226**
esophagus, 175
ganglion, **518, 520**
inlet, 95
N., **518, 525, 527, 598, 603**
outlet, 95
region, lateral, 105
wall, 112
lymph glands, 137
lymphatics, 137
movements, 112

Thoracotomy, 151
Thorax, 95
aperture, inferior, 95
superior, 95
"barrel-shaped," 97
cross-section, 143, 173
diameter anteroposterior, 96
transverse, 96
vertical, 96
expansion, 96
female, 96
fetus, 96
flat, 97
from behind, 102
"funnel-breast," 97
joints, 229
normal, 97
openings, 94
"pigeon-breast," 97
"shoemaker's breast," 97
surface anatomy, 98
unilateral changes, 97
Thymic A., 123
V., 150, 178
Thymus gland, 152
Thyroid V. inferior, 183
Thyroidea ima A., 166
Tibia, development, 53
fracture, 58, 60
head dislocation, 40
Tibial A. anterior, 70
ligation, 90, 91
line of incision, 80
posterior, 70, 88
ligation, 89, 88
collateral lig., 11
N., 602, 88
anterior, 70, 91
posterior, 70, 88
Tibialis anterior M., 70, 91
Tibio-condylar joint, 15
Tibio-fibular joint, blood supply, 18
distal, 17
inferior, 17
movements, 18
nerve supply, 18
proximal, 16
superior, 16
lig., anterior, 17
posterior, 17
superior, 10
Toes, 35
amputation, 62
Torsion, testicle, 709
Trabeculæ carneæ, 193, 190, 196
Trachea, 171, 170, 178, 204, 206, 219, 221
bifurcation, 98, 143
blood supply, 172
nerve supply, 172
Tracheal ring, first, 204
last, 204
"Tracheal tug," 172
Trachealis M., 171
Transpyloric plane, 253
Transversalis fascia, 306, 275, 299, 314, 549, 558, 581, 633
M., 291, 126, 287, 290, 293, 299, 314, 454, 527, 533, 568
aponeurosis, 291, 290
blood supply, 292
nerve supply, 292
Transverse colon, 359, 361
fissure, liver, 473
lig., 2, 3
distal, 18
knee-joint, 14, 7
perineal M., 720, 718
superficial, 722
rectal folds, 648
sinus, 180
vein, 153
Transversus abdominis M., 533
thoracis M., 120, 121, 139
Treve's bloodless fold, 364
Triangle, anal, 713
Hesselbach's, 327
lumbar, 265, 268
of Petit, 265, 268
urethro-vaginal, 713, 716
Triangular lig., 560, 662, 675, 271, 295, 299, 663, 665, 671, 720, 724, 725, 728
abdominal wall, 274
liver, 353, 386, 366, 381
left, 469
right, 469
superior layer, 674
Triangularis sterni M., 120, 121, 139
Tricuspid valve, 194, 190
position, 108, 107
Trigone, vesical, 591, 615
Trochanter, greater, fracture, 57
"True ribs," 114
Tubal A., 511
Tube, Fallopian, 630, 571, 615, 627
uterine, 630, 571, 615, 627
Tuber omentale, 474, 383, 471
Tubercle of Lower, 193
Tuberculosis, mesenteric glands, 364
Tuberculum intervenosum, 193
Tuberosity, omental, 474
Tubo-ovarian lig., 630
Tumors, recto-sigmoid, digital examination, 409
Tunica albuginea, 683, 707, 706, 726
vaginalis, 311, 704, 314, 700, 702
hernia into, 312
hydrocele, 704
testis, 698
vasculosa, 707, 702
"Twisted intestine," 400

U

Ulcer, duodenum, 457
excision, 457
operations, 457
Umbilical A., obliterated, 361, 569, 329, 355, 359, 547, 571
cord, hernia, 322
fissure, 473
fistula, 238
hernia, 322
acquired, 322
infantile, 322
operation, 323
radical cure, 323
strangulated, 324
lig., lateral, 327
median, 327
middle, 590, 591, 552, 627
urinary fistula, 327
vein, 202
Umbilicus, 238, 403, 554
fibrous ring, 273
Undescended testicle, 703
Urachus, 327, 587, 329, 355, 366, 552, 627
cysts, 327
Ureter, 503, 593, 454, 466, 491, 499, 502, 547, 552, 571, 586, 615, 627
blood supply, 504
calyx, 503
coats, 504
lymphatics, 504
nerve supply, 504
orifice, 590

Ureter, pelvis, 503
position, 254
Ureteral A., 511
Urethra, 691, **554, 671, 675, 678, 688, 690**
bulb, 646
cavernous, 692
diseases, 693
female, 632, 732
malformations, 696
membranous, 669, 691, **549, 665**
rupture, 692
prostatic, 595, 691
rupture, 693
spongy, 692
stricture, 694
Urethral bougies, 693
bulb, 683
caruncle, 732
crest, 595, **690**
glands, 693
Urethrismus, 668
Urethritis, specific, 694
Urethrotomy, external, 646
Urethro-vaginal triangle, 713, 716
Urinary fistula, umbilical, 327
meatus, external, 684, 692, 715, **690**
Urine, extravasated, 652
extravasation, 262
Urogenital cleft, 714
diaphragm, 662, 724, **663, 665, 671, 675, 725, 728**
fascia, 560
superior, 674
superior, **586**
triangle, 645
Uterine A., 511, 570, 614, **571, 615**
N. plexus, 601
plexus of veins, 614
tube, 630, **552, 554, 571, 615, 627**
vein, 614, **571, 615**
Utero-ovarian lig., 619, 629
Utero-pelvic lig., 619
Utero-sacral lig., 342, 619
Utero-vaginal, N. plexus, 601
plexus of veins, 579
Utero-vesical fold, 592
lig., false, 342
pouch, 342, 350, 559, **554, 609**
Uterus, 555, 608, **554, 571, 576, 615**
anteflexion, 612
anteversion, 612
blood supply, 614
body, 608, **609**
cavity, 613
coats, 613
fundus, 608, **552, 609**
inversion, 613
isthmus, 611, **609**
lig., broad, 342, 559, 617
false, 617
lateral, 342
posterior, false, 342
round, 618, **554, 571, 615**
true, 617
ligaments, 617
lymphatics, 614
os internal, 613
peritoneum, 613
prolapse, 613
retroflexion, 612
retroversion, 612
section, **609**
veins, 614
walls, 613
Utricular glands, 614
Uvula of Lieutaud, 591, **615**
vesicæ, 590, **571**

V

Vagina, 621, **554, 609, 730**
atresia, 625
blood supply, 625
lymphatics, 625
nerve supply, 625
orifice, 715
section, **609**
wounds, 626
Vaginal A., 573, **571, 615**
examination, 716
hysterectomy, 620
N. plexus, 601
plexus of veins, 579
process, 618
veins, 625
walls, prolapse, 626
Vagus N., 227, **143, 150, 157, 170, 173, 178, 598**
left, 159, **217, 221, 518, 520**
right, 156, **217, 219, 518, 520**
Valve, aortic, 173
position, 108, **107**
Valve, bicuspid, 198
position, 108, **107**
coronary sinus, 191, 192
eustachian, 192, **173, 190, 196**
of Heister, 415, 477
Houston, 648
ileo-cecal, 442
ileo-colic, 442
mitral, 198, **173, 196**
position, 108, **107**
position, 108, **107**
pulmonary, **190**
semilunar, aortic, 198, **199**
pulmonary, 194
spiral, 415, 477
of Thebesius, 192
tricuspid, 194, **107, 190**
position, 108
vena cava, 192, **173**
Valves, cardiac, location, 108
position, **107**
pulmonary, **173**
Valvulæ conniventes, 400, 432, **433**
Varicocele, 308, 710
Vas aberrans, **706**
deferens, 596, 707, **314, 329, 361, 547, 558, 568, 586, 678, 700, 702, 706**
Vasa aberrantia, 707
brevia, 425, 464, 510, **420**
efferentia, 703, 707
intestini tenuis, 428, 510, **424**
recta, 707
Vastus externus M., **73**
intermedius M., **73, 75**
internus M., **73**
lateralis M., **73, 75**
medialis M., **73, 75**
Vein or veins, abdomen, superf., 263
azygos, 227, **143, 150, 170, 173, 178, 183, 185, 217, 219, 221, 226**
lower left, 228
upper left, 228
brachio-cephalic, 153
bronchial, 224, **150, 178**
cardiac, anterior, 188
great, 188, **185, 196**
middle, 188
posterior, 188, **185, 196**
central of liver, 476
coronary, 417, **454, 466, 482**
cystic, 415

Heavy-face type denotes plates illustrating the subject named

Vein or veins, dorsal of clitoris, 731, 554, 725, 728
of penis, 579, 549, 581, 673
epigastric, deep, 521, 275
inferior, 521
superf., 263, 260
femoral, 83, 266, 271, 275, 568
deep, 73, 75
superf., 73, 75
of Galen, 188, 192
foramen, 190
gastric, 454, 466, 482, 514
left, 417
right, 416
gastro-epiploic, 355
left, 425, 454
right, 425, 420
hemiazygos, 222, 170, 221, 226
accessoria, 228, 170, 221, 226
hepatic, 474, 476, 521, 491
hypogastric, 578, 568, 571
iliac, circumflex, deep, 521
superf., 263, 260
common, 521, 577, 554
external, 521, 578, 314, 329, 571, 615, 633
internal, 578, 568, 571
ilio-lumbar, 579, 226, 568
innominate, 150
left, 153, 178, 183, 185
right, 153, 157, 178, 183, 185
intercostal, 129, 219, 226
superior, 129, 150, 178, 183, 185, 219
left, 170
lower left, 130
upper left, 129
right, 129
interventricular, posterior, 188, 185, 196
intralobular, 476
jugular, internal, 178, 183, 185
lumbar, 516
ascending, 516, 226, 502
mammary, internal, 127, 150, 183, 185
of Marshall, 130
mesenteric, inferior, 428, 467, 329, 424, 429, 466
Vein or veins, mesenteric, superior, 426, 467, 424, 454, 459, 466
oblique of atrium, 155
of left atrium, 191
of Marshall, 155, 180, 191
ovarian, 516, 629, 466, 491
pancreatico-duodenal, 416
pelvis, 577
pericardiac, 150, 178
phrenic, 521, 466, 502
left, 491
popliteal, 7
portal, 417, 474, 383, 412, 420, 454, 459, 471, 482, 514
sinus, 418
pudendal, 579
external superf., 260
internal, 673
pulmonary, 150, 170, 210, 221
left, 183, 185, 190, 196
right, 178, 190, 196
pyloric, 416, 466
rectum, 583
renal, 516, 466, 491, 502
sacral, middle, 579
saphenous, deep, 260
external, 70
great, 271
internal, 70, 88, 260, 271
scrotal, 698
spermatic, 329, 466, 491, 568
internal, 516
splenic, 398, 420, 464, 395, 422, 424, 429, 454, 459, 466
subclavian, 150
left, 178, 183, 185
right, 183, 185
subcostal, 129
sublobular, 476
suprarenal, 507, 521, 466, 502
right, 491
Thebesian, 191
thymic, 178, 150
thyroid, inferior, 183, 185
transverse, 153
umbilical, 202
uterine, 614, 571, 615
vaginal, 625
Vein or veins, of vermiform appendix, 427
vertebral, 183
vesico-prostatic, 549
Vena azygos, 154
major, 154, 227, 143, 150, 170, 173, 178, 183, 185, 217, 219, 221, 226, 502
minor, 228, 217, 221, 226
tertia, 228, 170, 221, 226
Vena cava, ascending, 515
descending, 154
foramen, 536
inferior, 192, 515, 568, 183, 185, 196, 217, 226, 329, 366, 381, 383, 454, 459, 466, 469, 471, 491, 502, 514, 533
lig., 180
superior, 154, 192, 143, 170, 173, 178, 183, 150, 185, 190, 196, 226
valve, 192, 173
portæ, 417
Venæ cordis minimæ, 192
Venereal warts, 694
Ventricle, left, 197, 173, 185, 196
right, 193, 173, 185, 190
Ventricles, 187
Ventricular septum, 198
Vermiform appendix, 402, 376, 379, 443, 445, 447, 547, 552, 627
artery of, 427
blood supply, 441
coats, 440
lymphatics, 441
nerve supply, 442
position, 255, 402, 403
removal, 449
retroperitoneal hernia, 405
structure, 440
surgical anatomy, 442
veins, 427
process, 402
"Vertebra prominens," 102
Vertebral abscess, 407, 157
A., 157
bodies, ligaments, 230
V., 183
Verumontanum, 595, 690

Heavy-face type denotes plates illustrating the subject named

Vesical A., 573
inferior, 570, **568, 571, 615**
middle, 570, **568, 571, 615**
superior, 570, **568, 571, 615**
N. plexus, **518, 598**
plexus of veins, 579, **554**
trigone, 591
Vesico-prostatic plexus of veins, 578, 592, **581**
veins, **549**
Vesico-uterine lig., 617
pouch, **571, 615**
Vesico-vaginal fistula, 626
Vestibular gland, greater, 723, **725**
Vestibule, 714, **624**
Vestigial fold of Marshall, 80
"Vicious circle," 489
Villi, intestinal, 432
Viscera, abdominal, locations, 251
relations, 378
perforation, 357
Visceral lymph glands, 641
Volvulus, 410
Vulva, 716
Vulvo-vaginal gland duct, 715

W

Wandering kidney, 490
White line, 560, 646, **586**
Witzel's gastrostomy, 485
operation, 391
Womb, 608
Wounds, abdominal wall, 325
spleen, 398
Wyeth's needles, 77

X

Xiphoid A., **121, 139**
cartilage, **121**
process, 112, 238, **139, 178, 235**

Y

Y ligament of Bigelow, 2
Young's oper., 679

Z

Zona orbicularis (of Henle), 1

Heavy-face type denotes plates illustrating the subject named

LANE MEDICAL LIBRARY

To avoid fine, this book should be returned on or before the date last stamped below.

FEB - 1 1940

FEB 18 1941

V 15 1945

NOV 15 1945

FEB -5 1946

AUG 13 1948

NOV 7 1950

MAY 18 1950

FEB 12 1954

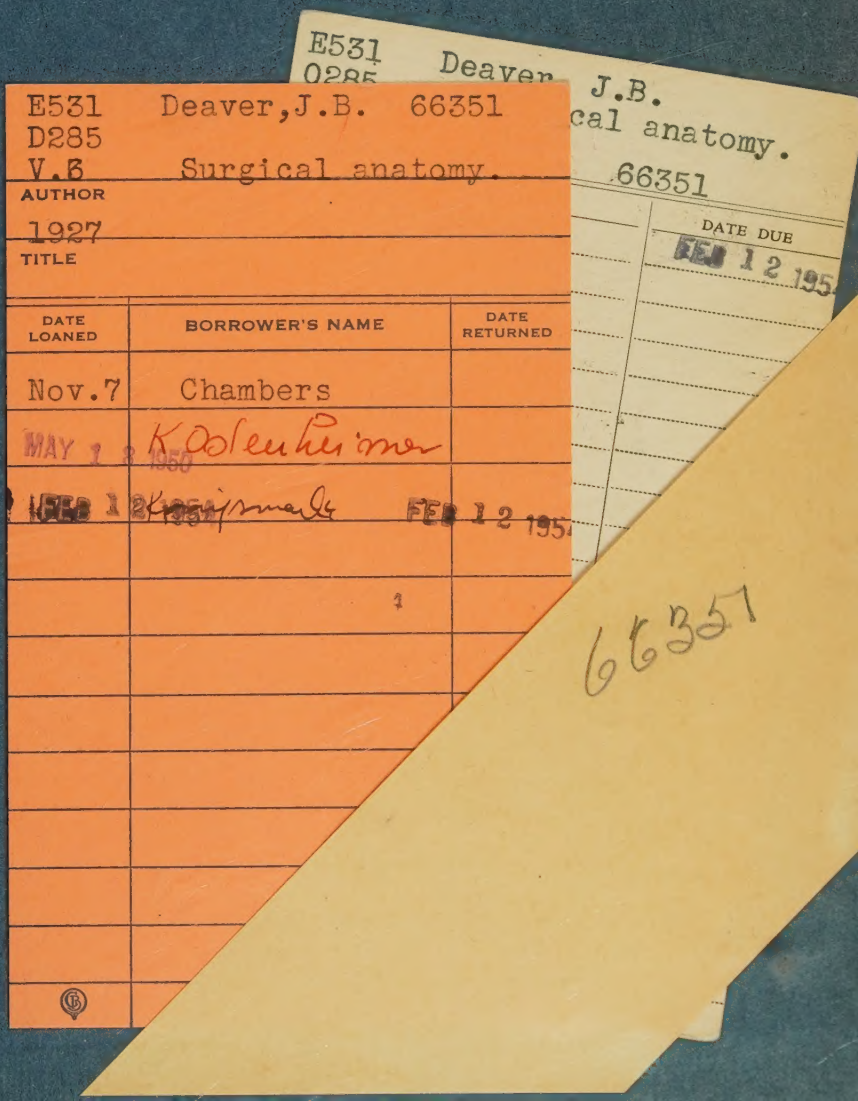

E531 Deaver, J.B.
D285 cal anatomy.
V.6 Surgical anatomy. 66351
AUTHOR
1927
TITLE

DATE LOANED	BORROWER'S NAME	DATE RETURNED
Nov.7	Chambers	
MAY 1 8 1950	K. Odenheimer	
FEB 1 2 1954	[illegible]	FEB 1 2 1954

DATE DUE
FEB 1 2 1954

66351